Digitized by Illinois College of Optometry

Digitized by Illinois College of Optometry

Carl E. Sharrard Memorial Library
Illinois College of Optometry

Digitized by Illinois College of Optometry

Digitized by Illinois College of Optometry

DISEASES OF THE EYE

AND

OPHTHALMOSCOPY

LIBRARY
of the
NORTHERN ILLINOIS
COLLEGE OF OPTOMETRY
4043-46 Drexel Boulevard
CHICAGO, ILL.

A HANDBOOK FOR PHYSICIANS AND STUDENTS

BY

DR. A. EUGEN FICK

UNIVERSITY OF ZÜRICH

AUTHORIZED TRANSLATION

BY

ALBERT B. HALE, A.B., M.D.

ONE OF THE OPHTHALMIC SURGEONS TO THE UNITED HEBREW CHARITIES; CONSULTING OPHTHALMIC SURGEON TO CHARITY HOSPITAL, CHICAGO; LATE VOL. ASST IMPERIAL EYE CLINIC, UNIVERSITY OF KIEL

WITH A GLOSSARY AND 158 ILLUSTRATIONS

MANY OF WHICH ARE PRINTED IN COLORS

PHILADELPHIA

P. BLAKISTON'S SON & CO.

1012 WALNUT STREET

1900

Digitized by Illinois College of Optometry

LIBRARY
of the
NORTHERN ILLINOIS
COLLEGE OF OPTOMETRY

COPYRIGHT, 1896, BY P. BLAKISTON, SON & Co.

Carl F. Shepard Memorial Library
Illinois College of Optometry
2093

PRESS OF WM. F. FELL & CO.,
1220-24 SANSOM STREET,
PHILADELPHIA.

Digitized by Illinois College of Optometry

WW 7 L17
15N.49
QD

00093

PREFACE.

He who writes a book is accustomed to make apology for himself in the preface. To this justly beloved custom I also yield, and, for my own apology, I wish to say that our best text-books of ophthalmology are too exhaustive; at least, this complaint is not seldom heard from the pupil to whom their purchase is suggested. So it seems that for a compactly written book, in spite of the number of others already at hand, there is still a place.

A text-book may be short and yet complete only at a sacrifice of some detail; the author should, perhaps, confine himself to a dry narrative of facts and rules; but to write such a book would certainly be no pleasure to me. I imagine rather a book that would present the connection of things, the whys and the wherefores. Something must be left out, however, and, in deciding on this something, I concluded that pathological statements or hypotheses should receive mention only so far as they were necessary for illustration of diseased conditions; and, further, that a text-book could not replace but could only supplement the clinical study of diseases and operations and the uses of the ophthalmoscope, and that a merely introductory idea of many subjects must be sufficient. I have omitted authorities, since a complete list would be too heavy a ballast, and an incomplete one, as often seen—half a dozen bracketted names after a statement,—is certainly, at least for the reader, without value. Only when a name came unbidden to my pen or needed mention as a voucher for accuracy, have I woven it in.

To make the book easier for the reader I have used a goodly number of colored illustrations and have introduced them into the text; this was a difficult matter, and the reader will probably understand why I have not been altogether successful in reproducing the exact colors with perfect accuracy.

2092

[In writing the book, I had a particular pleasure in omitting superfluous words; but I was soon obliged to decide to put many of them back again in order to make the sense clear. Generally speaking, therefore, I have used only those Germanized words which Hirschberg and other friends of ophthalmological purity of speech have authorized. (This refers, of course, to the German edition.—TRANSLATOR).]

A. E. FICK.

ZÜRICH, *June, 1894.*

Digitized by Illinois College of Optometry

VORWORT DES VERFASSERS.

Im Frühjahr 1895 schrieb mir Herr Dr. Hale, dass er mein Lehrbuch der Augenheilkunde ins Englische zu übersetzen wünsche. Mit Vergnügen erklärte ich mich einverstanden, nicht bloss weil die Uebersetzung eine Anerkennung meiner Arbeit ist, sondern weil ich auf diese Art Gelegenheit fand, an meinem Buche dies und jenes zu ändern und Erfahrungen zu verwerthen, die seit der ersten Niederschrift von mir oder Anderen gemacht worden sind.

Die englische Ausgabe ist also eine Uebersetzung des von mir *vermehrten und theilweise geänderten* deutschen Textes. Hoffentlich ist es mir gelungen, die Aenderungen so zu treffen, dass sie gleichzeitig *Verbesserungen* sind.

A. E. Fick.

Zürich, *Juni, 1896.*

Digitized by Illinois College of Optometry

TRANSLATOR'S PREFACE.

I am responsible for the translation of this work. Except for the few pages relating to heterophoria, I have tried to translate the author's language so as to convey in English the exact idea expressed by the German.

I hope the profession will criticize both the German and the English impartially, so that we may add to the accuracy of ophthalmology. But I may say that my own best criticism of the book, which, of all German literature on Diseases of the Eye, seems to me to be most suitable for English-speaking students, is evidenced by the fact that I have assumed the loving labor of translating it.

My thanks are especially due to Dr. George Reuling, of Baltimore, for his many courtesies, to Dr. W. Franklin Coleman, of the Chicago Post-Graduate Medical School, for his encouragement, and to my cousin, Mr. William Buel Hale, for his kindly aid in helping the book through the press.

ALBERT B. HALE.

CHICAGO, *August 16, 1896.*
Venetian Building.

Digitized by Illinois College of Optometry

CONTENTS.

PART FIRST.

THE METHODS OF EXAMINATIONS.

PAGE

Introduction, ... 15

A. THE FUNCTION TESTS.

I. Acuteness of Vision, Refraction, and Accommodation, ... 17
1. The Principles of Vision, ... 17
2. Accommodation, ... 24
3. Shortsightedness, Myopia, Acuteness of Vision, ... 28
4. Hypermetropia, ... 37
5. Range of Accommodation and Presbyopia, ... 41
6. Astigmatism, ... 47
II. Light-Sense, ... 53
III. Color-Sense, ... 57
IV. Indirect Vision and Field of Vision, ... 61
V. Binocular Vision and Squint, ... 70
1. Projection of Retinal Images, ... 70
2. Eye Movements, ... 76
3. Strabismus (Squint), ... 83

B. OBJECTIVE METHODS OF INVESTIGATION.

I. Reflection from the Cornea—Keratoscopy, ... 96
II. Focal or Oblique Illumination, ... 98
III. The Ophthalmoscope, ... 101
1. Theory, ... 101
2. Description of the Ophthalmoscope, ... 114
3. Use of the Ophthalmoscope, ... 117
(A) Transillumination, ... 118
(B) Examination of the Fundus of the Eye, ... 119
(C) Estimation of Refractive Conditions, ... 125
(D) Demonstration of Differences of Level in the Fundus, . . 135
IV. Measurement of Tension, ... 137

Digitized by the Illinois College of Optometry

PART SECOND.

THE DISEASES OF THE EYE.

PAGE

Introduction, ... 141

I. Diseases of the Lids, ... 143
1. Diseases of the Skin of the Lid, ... 143
2. Diseases of the Lid Edge, ... 149
3. Diseases of the Tarsus, ... 154
4. Malpositions of the Lids and Lid Edges, ... 156
5. New Growths, ... 165

II. Diseases of the Lacrimal Apparatus, ... 167
1. Diseases of the Lacrimal Glands, ... 169
2. Diseases of the Lacrimal Passage, ... 170

III. Diseases of the Conjunctiva, ... 181
1. Diffuse Inflammations, ... 183
2. Inflammations With Formation of Follicles, ... 196
3. Circumscribed Diseases, ... 206
4. Injuries and Their Consequences, ... 214
5. Tumors, ... 218
6. Extremely Rare Diseases, ... 219

Diseases of the Cornea, ... 220
I. Inflammations of the Cornea, ... 221
1. General Considerations, ... 221
2. Inflammations With the Formation of Ulcer, ... 222
3. Inflammations Without the Formation of Ulcer, ... 240
II. Injuries, ... 247
1. Wounds, ... 247
2. Foreign Bodies (Corpora Aliena), ... 249
3. Burns, ... 251
4. Frigeration, ... 251
III. Corneal Opacities of a Non-Inflammatory Nature, ... 251
IV. Protrusions of the Cornea, ... 257

Diseases of the Sclera, ... 262
1. Inflammations, ... 262
2. Protrusions, ... 263
3. Wounds, ... 265
4. New Growths, ... 265

Diseases of the Middle Tunic of the Eye (*Tunica Media*, *Tunica Uvea*), ... 265
1. Anatomical Introduction, ... 265
2. Physiological Introduction, ... 268
A. Diseases of the Iris, ... 271
1. Hyperemia, ... 271
2. Inflammations, ... 271
3. Injuries and Foreign Bodies, ... 280
4. New Growths, ... 282
5. Congenital Malformations, ... 283
6. Changes in Size and Motility of the Pupil, ... 284
B. Diseases of the Ciliary Body, ... 286
1. Cyclitis, ... 286
2. Paralysis and Spasm of the Ciliary Muscle, ... 288

Digitized by the Pacific College of Optometry

PAGE

C. Diseases of the Choroid, ... 290
1. Sclerochoroiditis Anterior, ... 290
2. Choroiditis Exudativa, ... 290
3. Chororetinitis Syphilitica (Foerster), ... 294
4. Choroiditis Suppurativa, ... 295
5. Tuberculosis of the Choroid, ... 296
6. Sarcoma of the Choroid, ... 297
7. Rupture of the Choroid, ... 300
8. Detachment of the Choroid, ... 300
9. Congenital Defects in the Choroid (Coloboma Choroideæ), ... 301
10. Nodules (Warts), ... 301

Diseases of the Retina and Optic Nerve, ... 301
Introduction, ... 301
A. Diseases of the Retina, ... 306
1. Hyperemia, ... 306
2. Retinal Hemorrhage, ... 307
3. Inflammations, ... 308
4. Occlusion of the Retinal Vessels, ... 311
5. Pigment Degeneration (Retinitis Pigmentosa), ... 313
6. Detachment of the Retina, ... 315
7. Glioma Retinæ, ... 318
8. Injuries, ... 320
9. Changes Due to Age, ... 321
10. Medullated (Opaque) Nerve-Fibers, ... 321
B. Diseases of the Optic Nerve, ... 322
1. Choked disc (Stauungspapille), ... 322
2. Inflammation of the Optic Nerve (Neuritis Optica, Papillitis), . . . 324
3. Retrobulbar Neuritis, ... 326
4. Atrophy, ... 327

Diseases of the Lens, ... 331
Introduction, ... 331
I. Cataract, ... 333
1. General, ... 333
2. Different Forms of Cataract, ... 335
3. Causes of the Formation of Cataract, ... 343
4. Treatment of Cataract, ... 344
5. Treatment—Before and After, ... 351
6. Cataracta Secondaria, ... 354
II. Aphakia, ... 356
III. Changes of Position of the Lens, ... 358

Diseases of the Vitreous, ... 360
Introduction, ... 360

Errors of Refraction, ... 362
I. Hyperopia (Farsightedness), ... 363
II. Myopia (Shortsightedness), ... 367
III. Astigmatism, ... 376
1. Regular Astigmatism, ... 376
2. Irregular Astigmatism, ... 379
3. Anisometropia, ... 381

Amblyopia and Amaurosis, ... 383
1. Amblyopia without Lesion, ... 383
2. Intoxications, ... 389
3. Weaksightedness as a Sign of Cerebral Disease, ... 390

Digitized by Illinois College of Optometry

PAGE

Glaucoma, ... 392
1. Introduction, ... 392
2. Varieties of Glaucoma, ... 395
(A) Primary Glaucoma, ... 395
(B) Secondary Glaucoma, ... 400
3. Pathological Anatomy, ... 401
4. Theories, ... 402
5. Prognosis and Treatment, ... 403

Entozoa—Parasites in the Eye, ... 407
I. Cysticercus, ... 407
II. Filaria (Thread-worms), ... 411

Injuries to the Eyeball, ... 411
1. Injuries by Puncture and Incision, ... 412
2. Injuries by Blunt Instruments, ... 413
3. Foreign Bodies Within the Eye, ... 415
4. Sympathetic Inflammation of the Eye, ... 418

Appendix, ... 423

Disturbances in the Movements of the Eyes, ... 425
I. Strabismus Paralyticus (Paralytic Squint), ... 425
1. Diagnostic Signs, ... 425
2. Location and Causes, ... 434
3. Prognosis, ... 438
4. Treatment, ... 439
II. Strabismus Concomitans, Concomitant Squint, with Particular Reference to Convergent Squint, ... 440
1. Vision in Strabismus, ... 440
2. Causes, ... 443
3. Treatment, ... 445
4. After-treatment and Results, ... 448
III. Latent Strabismus, with Particular Reference to Divergent Squint, ... 449
IV. Nystagmus, ... 455

Diseases of the Orbit, ... 457
Introduction, ... 457
1. Injuries, ... 458
2. Inflammations, ... 459
3. Disturbances of the Circulation, ... 461
4. Tumors, ... 466

APPENDIX A :—
Abbreviations used in Ophthalmology, ... 469
Table for Converting Metric Weights into Troy Weights, ... 470

APPENDIX B :—
Etymologies, ... 471

INDEX, ... 477

Digitized by Illinois College of Optometry

PART FIRST.

THE METHODS OF EXAMINATIONS.

INTRODUCTION.

Observation is the basis of all investigation. But observation in the narrower sense need not be particularly treated here. To recognize certain diseases, those of the conjunctiva for example, by merely looking at them, it is only necessary to see them often enough in order to have their essential characteristics well impressed on the memory. In this way we recognize many diseases of the lids, of the conjunctiva, of the cornea, and of the iris. Yet ophthalmology would cut a poor figure if observation as a method of examination could go no farther. Observation alone, without accessories, would leave us in the lurch when we come to the finer changes in the cornea, in the anterior chamber, or in the iris; very little could be done in diseases of the lens or of the vitreous humor, and nothing at all in diseases of the retina, choroid, or optic nerve. Luckily, however, ophthalmology possesses other excellent means, not alone to bring into view the finest changes in those parts of the eye lying superficially, but also to pierce into its interior and to make retina and choroid the object of closest scrutiny.

These methods are:—

(1) **Keratoscopy** and **Ophthalmometry**[1]—inspection of the images reflected from the surface of the cornea;

(2) **Focal illumination**, and

(3) **The Ophthalmoscope**.

The *first* method gives us information as to the character of the surface of the cornea, its smoothness and curvature. By means of the *second* we see the finest—indeed, by the aid of a lens, the microscopically minute—changes in the cornea, in the anterior chamber,

[1] Better still, **Keratometry**.

Digitized by Harvard College Library

iris, lens, and in the anterior part of the vitreous; and by the *third*, the ophthalmoscope, the posterior part of the interior of the eye lies open to our vision.

Touch, as well as observation, is equally important to the ophthalmologist. We feel of the eye, either directly, whereby we obtain information as to whether or not it is harder or softer than a healthy one; or indirectly with an instrument, the ophthalmotonometer, which, when applied, proves exactly whether or not the internal tension of the eye is, in mercury millimeters, greater or less than that of a healthy eye. The preceding methods of investigation are called *objective*.

Others, in contrast to them, are called *subjective*, and are designated as **Function tests.** These attempt to answer the question as to what the patient's eyes are capable of doing. The most important service is the recognition of the form of external objects—their relation in space. The more exactly this function is performed, the more acute is vision. But since this *acuteness of vision* can be measured only after the eye's refractive power has been determined, the principles of refraction must first be considered.

Besides relations in space the eye possesses two other functions, light perception and color perception. By *light-sense* is commonly understood the ability to distinguish light from darkness, or rather, light from less light. By *color-sense* is understood the ability to respond to light waves of different lengths by individual visual impressions which we call red, yellow, green, blue, etc. Disturbances of light perception are investigated by means of Masson's disk, or the photometer; disturbances of color perception by various methods that endeavor to present to the patient objects which can be distinguished only by their color, not by their form or brightness; if the patient be color-blind, then these objects obviously appear alike to him.

These three functions of the eye, acuteness of vision, light-sense, and color-sense, are to be tested both directly (at the center) and indirectly (at the periphery). This examination of the extent of the visual field or for any gaps in it, is of distinct importance; the method employed is called **Perimetry**.

Finally, the harmony of action in both eyes must be tested—*monocular and binocular vision;* and all defects therein must be noted.

Digitized by Google

TREATISE

ON

OPHTHALMOLOGY.

A. THE FUNCTION TESTS.

1. ACUTENESS OF VISION, REFRACTION, AND ACCOMMODATION.

1. THE PRINCIPLES OF VISION.

Every point of light sends luminous rays into every direction in space. If a pencil of these rays falls upon an even surface which is sensitive to light and able to communicate this impression through a nerve to the brain, the abode of consciousness, then light will be perceived, though by no means will every point of light be seen. A second point, which also sends a pencil of rays to the sensitive surface, would increase the impression of brightness, but would not be distinguishable from the first. In order to make this possible, that is, to establish vision, two conditions must be fulfilled:—

(1) In front of the sensitive surface there must be a dioptric apparatus which collects the divergent rays and unites them as an image on this perceptive surface, and—

(2) The perceptive surface must be a mosaic, the individual parts of which can be stimulated by luminous rays, and this stimulation must be carried to the brain without affecting the other parts of this surface.[1]

These two essential conditions are, as a matter of fact, fulfilled in the eye of man (and of vertebrates in general). The cornea, the aqueous, lens, and the vitreous form together a dioptric system which has under certain conditions the property of uniting a homocentric entering pencil of rays into an image on the retina, the light-

[1] This does not imply that any point of the retina is completely independent of other points. Compare *pp. 36, 58.*

Digitized by Illinois College of Optometry

perceptive tissue of the eye. Each luminous object can be considered as consisting of an infinite number of luminous points; each of these luminous points reproduces its own image on the retina, and from these infinite images a picture on the retina is constructed geometrically identical with the luminous object. This fact can be demonstrated in the following manner: Get the fresh eye of a white rabbit; after carefully clearing from the bulb all shreds of muscle and other tissue, hold the eye with the cornea toward a bright, easily recognized object, say the window or, even better, a good-sized gas flame in a dark room. Now, by looking at the back of the eye, one can see, because it has no pigment and is comparatively transparent, the inverted and much reduced retinal image of the gas flame.

If the form of the gas flame is not recognizable on account of the great reduction in the size of the image, then take two gas flames at a distance of one meter from each other, and hold before the one a red, before the other a green glass; then there is seen on the back of this rabbit's eye a red and a green point, the red standing at the right when its gas flame was at the left, and *vice versa*. This is obviously a proof that these little points must be the inverted images of the gas flame.

The second condition, the mosaic construction of the sensitive retina, is also fulfilled in the human and the vertebrate eye, but without a microscope this fact cannot be so easily proved as the first. In the chapter on "Diseases of the Retina" a picture of the human retina is given, magnified about 350 times. This picture, in at least the two outermost retinal layers, shows the mosaic structure; the innermost of these, the rods and cones, are to be considered, of course, as the sensitive nerve elements. A dioptric system giving images geometrically similar to the external objects, but inverted and smaller, must have the following properties:—

(1) Each refracting medium must be transparent and homogeneous, *i. e.*, of equal refractive index in all parts.

(2) The refractive surfaces of all the media must be spherical.

(3) The focal points of all refractive surfaces must lie on the same plane; in other words, the systems must be concentric.

Even if these three conditions are fulfilled, exact images will result only from such objects as send rays nearly perpendicular to the surface of the cornea. Physics gives us this law: "A homocentric pencil of rays in passing through a centered system of spherical refracting surfaces will form an exact image only when the angle of entrance is small." By the angle of entrance is meant

that angle which the entering ray makes with the perpendicular to the refractive surface.

Since, on the one hand, the human cornea is strongly curved, and, on the other hand, is an appreciable segment of a sphere, a point of light at infinity, even if on the axis, sends a pencil to the cornea whose peripheral rays form a large angle of entrance, and consequently cannot produce an image at the same point as do the central rays. Therefore, even the most favorably situated point cannot be reproduced in an exact image. But the iris stretched behind the cornea prevents the entrance of the peripheral rays of any pencil, and these do not, therefore, reach the interior of the eye at all.

Any point of light not on or near the axis of a dioptric system sends even those rays lying nearly in front of the pupil at a rather obtuse angle, and they cannot, therefore, in any way form an exact image. As we shall see below, however, these oblique rays are formed into an image owing to the special construction of the crystalline lens.

The three properties just mentioned are only approximately correct in the human eye.

Under (1). That the transparency is not perfect can be demonstrated on the cornea in the following manner: In the dark room place a lamp opposite a man, and with a convex lens unite a pencil of rays at their focal point on the cornea; this spot will then seem gray because there is enough light reflected from the corneal cells to be perceived by the observer (see *p. 98, 99*).

The incomplete transparency of the lens can be still easier perceived in the same way, or can be demonstrated on the cadaver without any apparatus: Open the eye of a man over forty and place it in water; then the middle part, the so-called nucleus, appears more or less yellow, according to the age of the individual. This fact proves that the transparency of the lens is by no means perfect.

The vitreous is much clearer, although there are always small areas through which the light does not pass. One can best demonstrate this on one's own eye entopically; some persons, when using the microscope, notice these physiological defects of the vitreous as little strings of beads or individual circles with a bright center; in my own eye I can see them best in damp weather; with the eyelids closed they can sometimes be seen by turning the face toward a bright surface. Of course, a clear, smooth field of vision is the best background for perceiving these little opacities, which move about in the vitreous and are consequently called mouches volantes.

Under (2). The spherical curve of the refractive surfaces is not mathematically exact in the eye; the surface of the cornea, which is the most important, is, in fact, so little the arc of a circle that the difference can be perceived without much trouble.

As is well known, a reflection of some light will always be caused when a pencil of rays passes from one transparent medium to another. If the refractive surfaces of both media are spherical, and the convex side is turned toward the weaker refracting medium (the air), then upright images of distant objects will be formed which are the smaller the shorter the radius of curvature of this surface is; consequently, the size of the images

gives us a key to the radius of curvature of the reflecting surfaces. A corneal image can be obtained as follows: Cut from stiff paper a piece about 20 *cm.* square; make a hole in the middle 6 to 8 *mm.* diameter, and place a man with his back to the window and hold the paper about 30 *cm.* in front of one of his eyes. If the observer looks through the hole at the cornea of this man, and if he at the same time looks at the hole, then at exactly the middle of his cornea will be seen a very much reduced image of the piece of white paper. Then ask him to look at the upper or lower edge of the paper, when the image of the paper will be reflected, not from the center of the cornea, but from the edges, and appears very much different, that is, larger and longer, a proof that the edges of the cornea are flatter than the middle.

Exact measurements have shown that the corneæ differ in different men. Some have the curvature of one ellipsoid, others of another, but they all differ from the mathematical figure by obvious irregularities, to be discussed later.

The anterior and posterior surfaces of the lens are also curves lacking mathematical accuracy, but as the measurement of the images reflected from them is much more different than in the case of the cornea, these irregularities are not so well known. In practice, however, the small parts of the anterior and posterior surfaces of the lens used in ordinary vision can be regarded as spherical.

Under (3). Considering a corneal surface and the anterior and posterior lens surfaces spherical, the three nodal points ought to be in one plane, but, according to Helmholtz's measurements, lately confirmed by Tscherning, this is not the case. The human eye is "decentered," although in so slight a degree as to be practically of no value.

Let us now follow the course of a pencil of light through the dioptric system of the eye in order to obtain, theoretically, an idea of what has resulted from this experiment on the white rabbit's eye. Take the simplest case of an eye without any lens. In such an eye there is only one refracting surface, the cornea, and two refractive media, air and water. The refractive index of the cornea, of the aqueous, and of the vitreous can all be considered as that of water.[1]

In such an eye looking toward a point of light on its axis at infinity, the rays falling on the cornea will be united in an image lying about 31 *mm.* behind the apex of the cornea, that is, behind the retina. This point is called the posterior focal point of the system (*p*, *f*, of *Fig. 1*). If the object is brought closer to the eye on its axis, the convergence of the rays in the anterior of the eye becomes less, or, in other words, the image passes at first gradually and then more rapidly toward the right, supposing the object to be

[1] According to Krause, the refractive index of

water	=	1.3342	
cornea	=	1.3507	
aqueous	=	1.3420	
vitreous	=	1.3485;	taking that of
air	=	1.0	

Digitized by Illinois College of Optometry

moved at the same rate of speed; finally, this point of light will come so close to the eye that the refraction of the rays on entering the cornea is just enough to make divergent rays parallel (the red lines of *Fig. 1, A*). In other words, the image now lies toward the right at infinity. The point on the axis from which divergent rays proceed parallel within the eye is called the anterior focal point of the eye (*a, f*, of *Fig. 1*).

If the position of the anterior and posterior focal points is known, it is easy to draw the image of any object whatever. Let *p* (*Fig. 1, B*) be a given object; take two rays diverging from it and find their meeting-point. Since all other rays of a homocentric pencil must pass through this meeting-point (assuming that the point *p* is not too far from the axis), then the desired image lies obviously

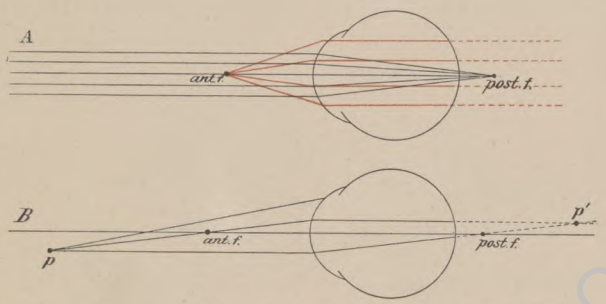

FIG. 1.—PASSAGE OF LUMINOUS RAYS THROUGH AN APHAKIC EYE.

at this meeting-point. Let us take for example those rays whose course we already know:—

(1) The ray parallel to the axis, which must strike the posterior focal point of the second medium, and

(2) The ray passing through the anterior focal point, which must run parallel to the axis in the second medium. At the meeting-point of these two rays lies *p'*, the image of *p*.

In a normal eye with a lens the conditions are by no means so simple, for it is easy to see that the form of the lens and the fact that its refractive index[1] is greater than that of water increase the converging power of the whole system. Consequently, both the anterior and posterior focal points are closer to the apex of the cornea.

[1] The refractive index of the lens, assuming it to be homogeneous = 1.4545, or 1.4541.

1343

Digitized by the Ohio College of Optometry

A physiologically normal eye is one having the anterior focal point 13 *mm.* in front of, and its posterior 22 *mm.* behind, the apex of the cornea. Since 22 *mm.* is also the distance of the fovea centralis retinæ from the apex of the cornea, *a normal eye is one whose posterior focal point lies on the retina.* This is called an emmetropic eye, to distinguish it from the ametropic eye, in which the posterior focal point lies either before or behind the retina.

The question now is, whether it is possible, by means of the anterior and posterior points alone, to find in this compound system the image formed by the rays from a certain object. Let us take in this case, also, two construction rays from the pencil, one passing through the anterior focal point and consequently running in the vitreous parallel to the axis, the other striking the cornea parallel to the axis and consequently reaching the posterior focal point in the vitreous. We see at once, however, that these two

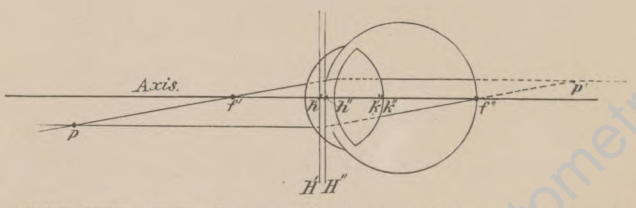

FIG. 2.—CONSTRUCTION OF THE IMAGE BY MEANS OF THE FOCI AND PRINCIPAL PLANES.

diverging rays are, in this case, far from sufficient. To determine any line two points are necessary; but here we have only one point for each ray of exit. The case of the eye without a lens is somewhat different (*Fig. 1*), for there the point on the surface of the cornea on which the entering ray fell was also a point of the ray of exit, but in a compound dioptric system that is not to be taken for granted, and by mathematical analysis it is found not to be the case. It is also clear that the two cardinal points, the anterior and posterior foci of a compound system, are not enough to give us the image of an object. We need a second pair of cardinal points, the two points, h', h'' (*Fig. 2*), and the two principal planes, H', H'', which, in the physiological eye, lie 2 or 2.5 *mm.* behind the apex of the cornea.[1]

[1] The first principal point lies 1.94 *mm.*, the second 2.36 *mm.*, behind the corneal apex, a distance apart of scarce 0.5 *mm.*

Digitized by the College of Optometry

By means of this we can now find the image, p', of the object, p, as follows: Prolong the entering ray, pf', to where it strikes the first principal plane; continue it parallel to the axis as far as the second principal plane, where it becomes in its new position a ray of exit. The second point in this ray of exit is determined by the fact that the ray must run in the vitreous parallel to the axis. Now, prolong a ray coming from p parallel to the axis in the first meridian as far as the first principal plane, advance its point of contact, still parallel to the axis, into the second principal plane, thus giving us again a point on the ray of exit, and prolong it through the posterior focal point. The image, p', lies at the intersection of these two rays.

With the unusually short distance of the two principal planes from each other, it is permissible to neglect it altogether and to consider them as one. The construction of the image is thereby essentially simplified, and differs from that of an aphakic eye (*Fig. 1*) only by the fact that the principal plane in the former case plays the part of the corneal surface in the latter; that is to say, it gives us the principal point of the entering ray, which we can consider as belonging also to the ray of exit.

In practice, especially in using the ophthalmoscope or in studying the laws of refraction and projection, we have still a third pair of cardinal points, the anterior and posterior nodal points (k' and k'' of *Fig. 2*). These points lie 6.95 *mm.* and 7.37 *mm.* behind the corneal apex, separated, in this case, less than 0.5 *mm.* Their significance is due to the fact that rays in the air, which would strike the first nodal point in the vitreous, are continued in this medium parallel to their original direction, as if they came from the second nodal point; consequently, by ignoring the slight interval between them, we have the following deduction: *rays of entrance striking the nodal point are continued practically unrefracted through the whole system.* Considering this fact, the nodal point has been named the "point of intersection of the rays of direction." This point becomes in the normal eye practically the posterior pole of the lens. Knowing this point of intersection, we can determine the image when we have the distance of the object from the corneal apex. In the emmetropic eye, when the object lies at infinity, or with such a short focal distance,[1] practical infinity, as we may call

[1] The anterior and posterior focal distances are respectively the distances of the anterior focus from the anterior principal plane, and that of the posterior from the posterior principal plane.

anything at 5 *mm.* or beyond, the image is formed with nearly absolute accuracy on the retina. To determine the location of this image, prolong rays from the object to the nodal point and extend them to the retina; where these rays strike the retina we find the image, because all rays falling on the cornea must here intersect the rays of direction. If, according to this, a diagram is made of a distant line on a piece of paper, we find that the image of the line is smaller and inverted. What was true of the rays in one plane (say in the drawing, *Fig. 2*) is necessarily true of all rays outside the drawing which strike the cornea. Simple reflection will show, therefore, that all objects in space must be reproduced on the retina of an emmetropic eye as inverted, reduced, and geometrically exact images.

Imagine an emmetropic eye looking toward a house at a great distance; prolong lines from the corners of this house to the point of intersection of the rays of direction and continue them to the retina. Any two such rays of direction will give us a plane; in any such plane we have these two retinal points and the nodal point forming a triangle similar to that formed by the nodal point and the two original points on the object. As all lines are necessarily proportionate in the two triangles, we must conclude that the house in the image is geometrically symmetrical to the house taken as object.

2. ACCOMMODATION.

In the previous section we have discussed the first condition of vision, that is, the impression on an emmetropic eye of an optical image similar to the object. Now we know from daily experience that the normal eye can see with equal distinctness near as well as far objects; this is possible in the emmetropic eye only when a change takes place for near vision. Before we investigate what this change consists of and how it is accomplished, we must show, of course, that this change is indispensable, for it is not possible to see a near and far object with equal distinctness at the same time, as either the near object is clear or the far one hazy, or *vice versa.*

Physiology illustrates this by means of "Scheiner's experiment."[1] The following experiment is less troublesome: Take two cards, one with large, the other with small print; cut out of the latter a number of words and so place it that words of the coarser print on the other card at a greater distance will show through

[1] Described in most text-books of physiology. Sometimes of importance in demonstrating a cataract operation.

Digitized by Illinois College of Optometry

these holes; the observer, sitting at a proper distance before the cards and trying to read, will at once notice that when reading the near type the farther will look as if covered with tissue paper and is unreadable, while if the eye looks through a hole at a word on the far card, the near type is indistinct.

This change in the eye, called **Accommodation**, can be brought about in two ways, either by displacement of the retina backward (in *Figs. 1* and *2* toward the right), or by a change in the dioptric apparatus, this last necessarily implying a change of refractive strength, or, in other words, a shortening of the focal distance.

That accommodation for near objects by displacement of the retina backward (lengthening of the bulb) can take place has been asserted by various ophthalmologists recently, Schneller among the number. Considering the softness of most eyes and the circumstance that a displacement of the retina of only 0.6 *mm.* backward would suffice to accommodate an emmetropic eye from infinity to 0.5 *m.*, this idea is not altogether improbable. Nevertheless, even the advocate of this idea confesses that a backward displacement of the retina can take place only with the severest strain on accommodation and convergence, which is not a normal process. It can be said, therefore, with all certainty, that this extension of the axis during ordinary accommodation plays no part.

If accommodation for a near object is brought about in the dioptric apparatus, the following possibilities must be considered:—

(1) Increase of the refractive index.

(2) Advance of the lens, that is, its approach toward the cornea.

(3) Increased curvature of the refracting surfaces.

The *first* possibility need not be examined, since the short time necessary for accommodation gives no chance for a change in the density of the refractive media. The *second* possibility, accommodation through advance of the lens toward the cornea, cannot be so lightly dismissed, and has had, as a matter of fact, numerous advocates of the highest scientific rank. But exact experiments show that although the anterior lens surface does approach the cornea during accommodation, this slight change of position is never enough to account for the reduced focal distance that takes place. A positive visible displacement of the lens will be necessary, and as this does not happen we can dismiss the idea.

The *third* possibility remains, accommodation by means of increased curvature of the refractive surfaces of the cornea and lens.

Digitized by the Internet Archive of Ophthalmology

Various experiments have conclusively proven that the cornea is not altered during accommodation. If this were so, measurements of the corneal images would show that they become smaller by increased corneal curvature for accommodation. They do not, however. Moreover, the cornea can be practically removed from the dioptric apparatus by covering it with water, and yet accommodation is not at all affected. If experiments on the cornea give negative results, exactly the reverse is true of those on the lens. Here we find during accommodation an actual reduction in the size of the image reflected from the anterior lens surface, a sufficient proof that this surface has meanwhile been increased in curvature.

The images reflected from the cornea and from the anterior and posterior lens surfaces are called Purkinje-Sanson's figures. *Fig. 3* shows them as they would appear to the reader looking into the eye from in front and to the left of the patient, and seeing the reflection of a candle in front and to the right of him. The image marked *8* is upright, since it comes from the cornea (with a radius of 8 *mm.*). It is bright because its refractive index differs greatly from that of air.[1]

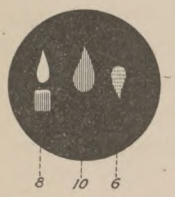

FIG. 3.—PURKINJE-SANSON'S FIGURES. (*According to Helmholtz.*)

The image marked *10* is also upright, is larger than the first and much dimmer, so dim, in fact, that its demonstration is often difficult for the beginner. It comes from the anterior lens surface, that has a radius of 10 *mm.* Its dimness is due to the fact that the difference between the index of refraction of the lens and that of the aqueous is very small. Finally, the image marked *6* is inverted, is the smallest, and is somewhat lighter than that marked *10.* Its inversion is due to the fact that it is reflected from the posterior lens surface acting as a concave mirror;[2] the small size is explained by the strong curvature of this concave mirror, whose diameter is only 6 *mm.*

It is not so easy to demonstrate these images on the lens, but I shall later (see *p.* 100) give a method by means of which these Purkinje-Sanson images can be made evident to the most inexperienced.

---

[1] A greater difference between the refractive indices of the media implies brighter reflection from the surfaces.

[2] With reference to the path of the luminous rays.

Digitized by Illinois College of Optometry

The attempt to measure the lens is still more difficult. Helmholtz, with the aid of his ophthalmometer, first did this successfully. His measurements conclusively prove Kramer's demonstrations that during accommodation the greater curvature takes place at the anterior lens surface (see *Fig. 4*). This reduction in curvature can amount to about 4 *mm.* The posterior lens surface is likewise increased in curvature during accommodation, but only to the extent of 0.5 *mm.*, so small a change and such an uncertain measurement that no attention need be paid to it.

Finally, we must investigate in what manner this increased curvature takes place. We know that the accommodation is subject to the will, and that all involuntary motions of the body are the result of muscular action; consequently, a muscle connected by a nerve with the brain must be the mechanism that produces this change

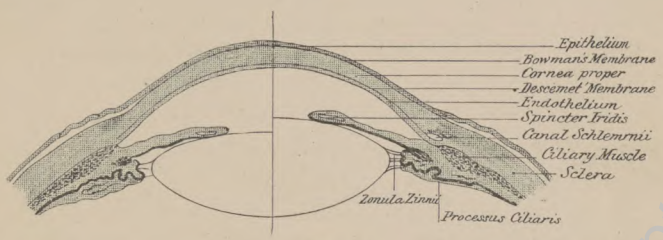

FIG. 4.
The left half represents the eye at rest, the right during accommodation.

in form. We have such a muscle in the interior of the eye, close to the lens, though it is unstriated instead of striated. Probably a good explanation of the fact that a muscle is the cause of this action was given by Bruecke and Bowman within a comparatively recent period. This musculus ciliaris (*Fig. 4*) surrounds the equator of the lens like a ring; if the muscle contracts, thereby making the ring smaller, one can imagine the ring pressing on the equator, and the lens must then yield at the anterior pole, that is, toward the pupil. This view finds an earnest advocate in Heinrich Mueller. Proof was, however, not conclusive, for Helmholtz showed that the action of the ciliary muscle was not direct upon the lens, but indirect through the Zone of Zinn (see *Fig. 4*). Numerous measurements have shown that a lens is thicker antero-posteriorly after extraction from the eye than it was before; the lens, therefore, is not in a condition of physical equilibrium so long as

Digitized by the Internet Archive of Optometry

it is in the eye, being flattened on account of the tension that the fibers of the Zone of Zinn exert on the lens capsule.

But the Zone of Zinn is attached to the ciliary processes, and a contraction of the ciliary muscle must, therefore, narrow the diameter of the attachment of the Zone of Zinn. The zone being thus relaxed, the lens is allowed to grow rounder by its own elasticity.

This description may be, perhaps, too schematic in explaining the action of such a complicated muscle.

Schoen, assuming that each one of the three sets of muscular fibers plays according to its course its individual part in accommodation, has developed a specific theory to explain accommodation, but it has not yet been accepted by many ophthalmologists.

In opposition to the Helmholtz theory of accommodation stands that of Tscherning. Helmholtz ascribes accommodation for near objects to relaxation of the Zone of Zinn, while Tscherning declares the opposite to be true, namely, that tension on the Zone of Zinn allows the anterior surface of the lens to be more strongly curved, at least in the neighborhood of the anterior pole. The edges of the lens are likewise, so says Tscherning, flattened by tension on the zone; but these edges lie behind the iris and are, therefore, of no use in vision. How a contraction of the ring-like ciliary muscle can put the zonula on the stretch I cannot explain to the reader, for I do not understand it myself.

3. SHORTSIGHTEDNESS, MYOPIA, M. ACUTENESS OF VISION, V.

In the preceding section it was explained that the emmetropic eye has the power of independently accommodating for a near object. But there are plenty of eyes that even at rest are adjusted for only certain distances this side of infinity; such eyes are shortsighted, and the condition is known as **Myopia.**

The word myopia means that shortsighted people generally half close the eyes when looking at a distant object. The word "shortsightedness" ought, therefore, to be preferred, because it describes the condition itself and not a mere physical property.

If a shortsighted eye at rest looks at *r cm.* distance, and receives an image of it *on* the retina, then the image of every point beyond must lie in front of the retina; a point at infinity, therefore, has its image in front of the retina. If a point lies at ∞ infinity and on the axis of a lens, its image lies at the focal distance of the lens; consequently we can call shortsightedness that refractive condition of an eye at rest in which the focal distance is in front of the retina (*Fig. 5, c*).

What can explain the fact that the focus does not lie upon the retina? There are several possible explanations.

Digitized by Illinois College of Optometry

We first think of the dioptric apparatus, as several deviations from a normal condition can cause a shortening of the focal distance:—

(1) A too high refractive index. Shortsightedness of this kind does actually exist, and at least that myopia which here and there precedes a cataract is explained by many ophthalmologists as a thickening of the lens and nucleus and a consequent increase in refractive power.

(2) An unusual position of the lens, such as a forward luxation, can cause shortsightedness. As an example, we often see myopia just before the development of senile cataract, which is explained by many observers as an increase in the size of the lens and a consequent advance toward the iris. In glaucoma, also, and in a certain form of choroiditis, some American ophthalmologists report

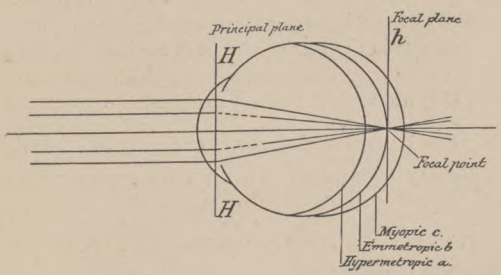

FIG. 5.—POSITION OF THE RETINA.
(*a*) In front of, (*b*) at, and (*c*) behind the focus.

that an increased collection of fluid behind the lens presses it forward, and that the shortsightedness disappears as soon as the exciting disease is cured.

(3) Finally, the dioptric apparatus can be abnormal if the refracting surfaces are of too strong a curvature. A case is mentioned by v. Reuss of a myope whose corneal radius was only 6.5 *mm.* (compared with 7.7 to 8.0 *mm.* of the normal eye). Even if all the shortsightedness could not be explained thereby, there is no doubt that part of it was due to this cause.

The variations in corneal measurements within physiological bounds have naturally some influence on the position of the image; anything less than 7.7 *mm.* would, of course, increase a shortsightedness due to other causes, but numerous measurements have proven that in shortsightedness the corneal radius is, indeed, rather smaller than it is under other conditions.

(4) The anterior lens surface with a strong curvature much

oftener causes shortsightedness, but it is only apparent, as it is due to a spasm of the muscle of accommodation, which the patient overlooks. As soon as the muscle is paralyzed by atropin this apparent shortsightedness disappears.

(5) The above are, however, but infrequent causes of myopia. The vast majority of cases of every degree depends not upon the anomalies of refraction, but upon the fact that the retina lies back of the focus of the lens (see *Fig. 5, c.*). In myopia of a high degree a lengthening of the globe is so noticeable as to be apparent in life to the uneducated observer, and, of course, the fact of this increase in length has been time and time again demonstrated on the cadaver. This form of shortsightedness is called *axis-myopia*, in contradistinction to the much less frequent curvature myopia.

Lately Fukala has advanced the view, with very good support, too, that the highest degree of shortsightedness depends upon both the increased length of the globe and increased refractive power of the lens; he supposed also that ordinary shortsightedness has as a cause some change in the lens as well as in the length of the globe. This much at least is certain, that myopic eyes have been found which must have had the unheard-of length of 42 *mm.* (! !) if that were the only explanation of the trouble.

The next step is to get a measure for shortsightedness and from it to form a rule by means of which this measure can be applied to any given case.

Shortsightedness is manifestly greater in proportion as the retina lies behind the focal point of the optical system. In other words, —a shortsighted eye being one in which divergent rays proceeding from the point R and passing through the optical system form an image on the retina,—it is obvious that shortsightedness is the greater the nearer the point R lies to the eye. This point R is called the far point (*punctum remotum*) of the eye. Shortsightedness is small if R is a long way off; it is large if R is near; that is, M *is inversely proportional to the distance of the far point.*

The ophthalmic formula is as follows: $M = \frac{1}{r}$. Here M signifies the myopia or shortsightedness, r the distance of R from the anterior principal point. It is a matter of indifference how this distance is measured. Convenience and simplicity have finally settled on the meter as the unit of measure, consequently that eye has a M of 1 when its far point lies at 1 *m.* ($M = \frac{1}{1} = 1$).

Since the position of the far point determines the degree of shortsightedness, in finding this far point we at once measure the M. Take any object that requires good accommodation to perceive

Digitized by the Internet Archive in 2010 with funding from

it, a fine point, for instance, and from a distance bring it toward a patient's eye till he can see it clearly. You have now found the far point of this eye. Such a simple expedient is often resorted to, but its general application has one great disadvantage. Print, to be read at a moderate distance, accurately and with absolutely correct accommodation, must be very small, but, unfortunately, fine print, in spite of perfect accommodation, cannot be easily read beyond a certain distance. Therefore in practice we must use print of different sizes for each particular distance. Since this is hardly convenient, we generally resort to another method of measurement, which depends on the fact that **by introducing a concave lens into parallel rays** (rays from infinity) **we can give them such a**

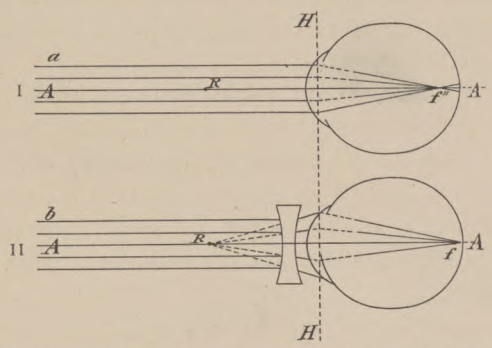

FIG. 6.—MEASUREMENT OF SHORTSIGHTEDNESS BY A NEUTRALIZING CONCAVE LENS.

divergence that they form an image on the retina of a myopic eye.

Fig. 6 illustrates this method. In I is a section of a myopic eye on whose cornea a pencil of parallel rays falls. This pencil comes from a point of light to the left lying on the axis at infinity. Imagine these rays extended to the principal plane, *H H*, and prolonged to the focal point, *f''*. (These lines are dotted at first to indicate that in the anterior of the eye the path of the rays is in reality different from that in the figure.) From *f''*, the posterior focus, the rays diverge again and consequently form upon the retina in the place of an image a mere light spot, which is round if the pupil is round. Now then, by putting a concave lens before the eye we see, in II, that the rays strike the cornea divergently and can be made just divergent enough to appear to come from *R* (the far point); they therefore form an image on the retina and not, as before, at the focus, *f''*.

Digitized by Illinois College of Optometry

Without farther explanation, it is evident that the same thing can be accomplished with concave lenses of different focal lengths according as one approaches or withdraws the point *R*. If now the concave lens is so close to the shortsighted eye that the distance between the concave lens and the principal plane can be neglected, then *the focal length of this neutralizing concave lens will be exactly equivalent to the distance of the far point of the shortsighted eye.* The reciprocal value of the focal distances of the concave lens is therefore the measure of the myopia. We have then the following rule for measuring myopia by a concave lens: Let the patient look at some object at infinity (in practice 6 *m.*), hold in front of his eye concave lenses of gradually increased strength (of shorter focal distance); the weakest lens with which the shortsighted person sees this object distinctly is the measure of the distance of his far point, that is, of the myopia.

In doing this we have overlooked two conditions not yet mentioned; the first concerns the customary nomenclature of the lens with respect to their focal distances, the second concerns the important question as to how we are to know that the patient actually does see an object distinctly. For the mere statement that such is the case is, at least in those not accustomed to close observation, very untrustworthy.

The lenses used by the oculist for estimating refractive conditions are found in the ordinary test-case. These are numbered, but the numbers do not denote, as one might expect or as was formerly the custom, the focal distances, but their reciprocal values, that is, their converging (convex) and diverging (concave) power. For the sake of simplicity we have adopted Nagel's proposal to use the meter-lens, *i. e.*, a convex lens of 1 meter focal distance, the converging power of this lens being called a **Diopter**, denoted by *1.0 D*. Since the converging power of a lens is inversely proportional to its focal distance, a lens of *2.0 D* strength has a focal distance of 0.5 (½) *m.*, 50 *cm.*; a lens of *0.5 D* strength has a focal distance of $\frac{1}{0.5} = \frac{1}{\frac{1}{2}}$, or 2 *m.*, etc.

When lenses were distinguished by their focal distances these were given sometimes in French, sometimes in English inches. 36 French inches = 40 English inches = 1 *m.*; or 0.36 Paris inch = 0.40 English inch = 1 *cm.* If we wish to convert diopters into the old nomenclature of inches, find the focal distance of the lens in centimeters and translate it into inches thus: a lens of *2.0 D* = $\frac{1}{2}$ *m.* = $\frac{100}{2}$ *cm.* = 50 *cm.*; but 50 *cm.* is equal to 18 French or 20 English inches, and the number of the lens would be

$\frac{1}{18}$ or $\frac{1}{20}$ respectively. To get the focal distance of the lens in the old inch system, divide the 36 French or 40 English inches (= 1 *m.*) by the dioptric strength of the lens, thus: a lens of *2.0 D* = 2) 36 or 40, = 18 or 20 inches. Reverse the process to get from the old nomenclature into the new, thus: a number $\frac{1}{20}$ English = 20) 40 = 2; a $\frac{1}{20}$ is a lens of *2.0 D*.

Concave lenses are also reckoned in diopters. A concave lens of 1 *m.* (negative) focal distance has a divergent power of 1 diopter, or is *—1.0 D.* If we find in any case that vision is made normal by a concave lens of *—3.0 D*, then $\frac{1}{r} = 3$, that is, the myopia of that eye = 3 diopters and is expressed as M = *3.0 D.*

The other condition not yet mentioned concerns some expression for the acuteness of vision (**Vision = V**) under proper accommodative circumstances. Naturally the vision of an eye is better the nearer the retinal images (π_1 and π_2, *Fig. 7*) of two points (p_1 and p_2) come to each other before they cease to be distinguishable. The measurement of the distance of the two points, π_1 and π_2, can be ex-

FIG. 7.
Acuteness of vision is measured by the smallest angle within which an object is recognizable.

pressed by a simple proportion composed of the distance of the points p_1 and p_2 from each other, of the distance of p_1 and p_2 from the nodal point, K, and of the distance of K from the retina; since this last distance is constant (= 15 *mm.*) we need only say that the size of $\pi_1\ \pi_2$ is directly proportional to the size of $p_1\ p_2$ and inversely proportional to the distance of $p_1\ p_2$ from K; that is, the size of $\pi_1\ \pi_2$ is proportional to the "visual angle" at which $p_1\ p_2$ is seen. The formula is $\pi_1\ \pi_2 = \frac{L}{d}$, when L = the length of the object, $p_1\ p_2$, and d = its distance from K; the smaller $\pi_1\ \pi_2$ is, the sharper is vision; that is, V is inversely proportional to $\pi_1\ \pi_2$, so the formula becomes $V = \frac{d}{L}$.

In putting this into practice we determine V by means of letters of different lengths placed at certain distances and by finding the smallest letters that can at any distance be distinctly recognized. Experiment has shown that *the normal eye recognizes letters five*

Digitized by Illinois College of Optometry

times as long as they are broad when they are at such a distance that they can strike the eye at a visual angle of 5 minutes. The vision of such an eye is arbitrarily put down as *1*. Now, to be able to compare with the least trouble the vision of any eye with that of the normal, we use letters that we already know can be recognized at the proper distance by eyes whose $V = 1$, in other words, at such a distance that their length appears to fill the angle of *5* minutes and their breadth the angle of *1* minute; this distance expressed in meters is called D. Since this D is necessarily directly proportional to the size of the letter, we can express the size of the letter by D. The formula for visual acuity then becomes the following generally used one: $V = \frac{d}{D}$, or in words, the vision of an eye is equal to the distance, *d*, of the smallest recognizable letter divided by that distance, D, in which a normal eye (with $V = 1$) ought to read the same letter. For example, the smallest letter that a patient can read with one eye at *6 m.* distance is an *E* whose D = *30 m.* (ought to be read at *30 m.*); then the *V* of this eye $= \frac{6}{30} = \frac{1}{5}$. If with the other eye he can read at *6 m.* a letter whose D = *4*, then the *V* of this eye $= \frac{6}{4} = \frac{3}{2}$, better than normal.

To estimate *V* we make use of letters, as has been already said; since if the patient recognizes the letters it is proof enough that he recognizes their form. In case the patient cannot read we use hooks, ⊓ ⊔ ⊏, ⊐ ⊓ E, and ask him to tell us whether the lines run up or down or to the right or left. There are test-cards published with rows of letters, figures, and hooks of different sizes; every row is marked with a figure which tells us the D of that particular size. Each card generally has a letter with D = *60* at the top and D = *6* or D = *5* at the bottom.

Although we have supposed that a healthy eye has $V = 1$, the statement must be modified to some extent, for it is obvious that not all healthy eyes can have the same acuity of vision. As *V* depends not only upon the quality of the dioptric apparatus, but also upon that of the retina, of the optic nerve, and of the brain, it is easy to imagine personal differences within physiological limits. *V* is not always *1* in the normal eye. In youth it is, as a rule, better than *1*. $V = \frac{9}{6}$ or even $= \frac{12}{6}$ is not uncommon, and there have been reports of $V = \frac{42}{6.5}$, 6½ times the normal! This hap-

Digitized by Harvard College Library

pened among the Kalmucks. With increasing years visual acuity gradually declines. This is, as a rule, the result of small opacities in the lens or of other such pathological changes; but even if there is nothing of this nature, the acuteness of vision of the old is less than that of the young. How great this physiological defect in the aging eye on the average is, cannot be stated without further investigation.

Donders and his pupil, de Haab, assert that from the thirtieth year on visual acuity sinks one-tenth every ten years, and between the fiftieth and sixtieth years even two-tenths, till the visual acuity in the eightieth year is only one-half the normal. This "Haab's law" has not withstood the test of investigation. H. Cohn has examined 100 persons more than sixty years of age to find that the decrease in visual acuity in the normal eye was extremely slight, and confined to the tenth decade. Boerne and Walther examined 400 persons to find that in the healthy eye there was a slight and uniform decrease in acuity from the fortieth year on; but that in the senile eightieth year acuity of vision was still $\frac{6}{9}$.

To determine the near point of V we use printed test-cards that must be read, not merely spelled out by the patient. This print is also furnished in different sizes, marked with figures to designate at what distance the eye with $V = 1$ ought to read them. This is the case in the publications of Snellen and Schweigger, but not in the popular one of Jaeger.

If a patient's V is so poor that he cannot read letters, let him try to count fingers spread out in front of a dark background (say the physician's black coat). Fingers are about equal to letters with $D = 60$, so that a patient who can read fingers at 2 m has $V = \frac{2}{60}$. If he cannot count even fingers, try the movement of the whole hand. The smallest degree of V can only distinguish light from darkness.

To read a connected word close to the eye is not, without some further explanation, comparable to the ability to distinguish letters by their form, even assuming the condition fulfilled that individual letters appeared in one case as well as in the other at the same visual angle. In a word of several letters each letter need not be recognized by its form; it may be guessed by the connection; it not infrequently happens that the proper letter is supplied when in reality an improper one was in its place by a misprint. Moreover, reading may be made difficult by the fact that the letters are placed too close to each other. It is not scientific to make the test depend on these two circumstances alone.

Digitized by Harvard College of Optometry

Several investigators, and recently Guillery, have shown that Snellen's method of estimating visual acuity is neither practically nor theoretically free from deception. It is a daily experience that not all the letters of one row can be read at the same distance; the letters *E*, *R*, *B*, for example, require the observer to be closer to them than do the equally large but simpler constructed letters *F*, *T*, *A*, *V*. Moreover, it has been theoretically suggested that the visual acuity of an eye is inversely proportional to the surface area of the retinal image of an object and not to the visual angle at which it appears.

The first source of deception must be acknowledged, and in recent editions of test-cards, especially Schweigger's, allowance has been made for it. It can be altogether avoided if hooks are used instead of letters, a test method that for other reasons has been recommended by many ophthalmologists. The second source of deception I consider of no value. The idea that a letter is the easier recognizable the greater the area of its retinal image, has not been proved even by its advocate, and facts are against it. Indeed, the opposite is the true view, for the principle of the estimation of visual acuity depends with logical necessity upon the interval between two luminous points, only one dimension being considered, therefore. The proposition that the area of the retinal image is a determinative factor must rest on the implied notion that retinal areas separated by a space are of mutual support to each other in vision. According to my investigations this notion is correct as far as concerns light and color sensations, but in the recognition of objects, or, in other words, in reference to space perception, there is no mutual support of separate retinal areas, or it is present in a degree not worth mentioning.

After this digression let us return to the problem of measuring myopia by means of lenses.

The patient is placed with his back to the window; the wall opposite should be well lighted and on it at 4 to 6 *m.*, according to the size of the room, should hang the test-cards. They cannot, of course, be placed at infinity, but calculation shows that rays from 6 *m.* or even 4 *m.* are so slightly divergent in passing through a pupil only a few millimeters in diameter, that we can neglect this fact without noticeable error and consider the rays practically parallel.

A pupil of 4 *mm.* diameter receives from a luminous point at 4000 *mm.* rays that enter at an angle of only 3 minutes. This angle is about the $\frac{1}{100}$th of the angle represented in *Fig.* 7, *p.* 33. If one tries to imagine such an angle one can easily see that it is practically neglectable. The same conclusion can be reached thus: a luminous point at infinity has its image at the focus of the lens; one at 4000 *mm.* has its image at 0.07 *mm.* behind the focus; the rays in this case therefore forming an image practically at the focal point. Or we can easily allow for the error arising from the fact that the test-card is not at infinity, since a patient accommodating for the test-card at 5 *m.* has an error of only $\frac{1}{5} = 0.2\ D$, an amount so small that it is scarcely to be measured by any lens in the ordinary test case. At 4 *m.* this error is just $\frac{1}{4} = 0.25\ D$.

Now ask the patient to read without glasses. If he is short-sighted he can recognize only the largest letters. For example, he is found to read without glasses at 4 *m.* only letters that ought to

Digitized by the Internet Archive College of Optometry

be read at 30 ($D = 30$) or even at 60 ($D = 60$) *m*. Then give him a concave lens, beginning with the weakest and increasing till the strongest is found that improves his vision. The weakest concave lens with which he sees best measures the myopia present. A stronger lens cannot be used, for in that case there would be an effort at accommodation to overcome the extra divergence, and this lens would then indicate the myopia plus any additional but not yet measured accommodation. Atropin would, of course, paralyze this accommodation, so that a paralyzed (atropinized) eye would see less distinctly as soon as too strong a concave lens were used.

4. HYPERMETROPIA, H.

A second refractive condition of an eye is called **Hypermetropia**, or farsightedness, a term not quite intelligible without further explanation. A hypermetropic eye is not able without accommodation to produce on the retina an image from a luminous point at infinity or theoretically this side of infinity; and this image can be formed on the retina only in case the homocentric pencil of rays falls upon the cornea convergently. Since all objects of the outer world send either parallel or divergent rays to the cornea, a hypermetropic eye must be unable, when not accommodating, to see either near or far objects. If, therefore, the hypermetrope can read and write and accomplish other work, the credit of seeing larger objects at any rate, even though their retinal images are indistinct, must be due to the power of accommodation.

If in hypermetropia rays of a certain convergence meet at the retina, then rays parallel at the cornea must form an image behind the retina. An eye is therefore hypermetropic when its focal point lies behind the retina.

The fact that in hypermetropia the posterior focal point and retina do not coincide can be explained in several ways.

(1) Let us consider the dioptric apparatus. Is it possible that too low a refractive index of the transparent media of the eye explains this increase in focal distance? This is not absolutely impossible. The hypermetropia of the new-born and children may partly at least depend upon insufficient density of the nucleus of the lens; nothing exact is known about this, however, and it is not even an undisputed fact that children are born hypermetropic, or are changed during youth to hypermetropes of a lesser degree or to emmetropes or to myopes. Moreover, there is the apparently contradictory fact that hypermetropia sometimes depends upon too great a refractive index. To understand this we must remember one fact in the anatomy of the lens; the human crystalline lens has a

Digitized by Illinois College of Optometry

stratified structure, the middle part, the so-called nucleus, being surrounded by strata like an onion, each stratum having a lesser density than the one lying next to it internally, and a greater density than the one next to it externally. The nucleus is therefore to be considered as surrounded by concavo-convex layers with refractive indexes decreasing from within outward. *Fig. 8* shows the hollow side of each layer with a smaller radius of curvature than that of the convex side; consequently each layer considered by itself, that is, as having the same medium in front of and behind it, acts as a diverging, not as a converging lens, the divergence being greater the higher the refractive index is. It is therefore clear that the converging power of the whole lens will be the greater the less the refractive index of the periphery of the lens is. Now during life the lens undergoes changes which can be explained by the deposit of new-formed lens cells in the region of the lens equator and by the so-called nuclear sclerosis. The lens nucleus becomes thicker and denser with increasing age, but larger as well, because the peripheral layers become more and more like the nucleus, or they may melt completely into it. An increased density of the periphery, or, what is the same thing, a melting together of periphery with nucleus, will lower the converging power. In can be seen, therefore, that the physiological changes of age in the lens periphery are able to increase the focal distance of the eye, or, for example, an emmetropic eye may become hypermetropic.

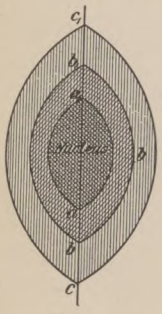

FIG. 8.

The menisci bounded by the lines *ab* and *a'b'*, and by the arcs *aa'* and *bb'*, have a smaller refractive index than the nucleus, but a greater index than the two outer menisci, *c'c bb'*.

Hypermetropia can also be produced by too great a refractive index in the vitreous; for luminous rays in passing out of the lens into the vitreous are refracted convergently proportional to the difference between the refractive indexes of the two media. If the refractive index of the vitreous increases and thereby approximates that of the lens, then the converging power of the eye must decrease. Such a case has been described by Landolt. A woman with diabetes had at the same time a moderate hypermetropia that disappeared when the sugar disappeared and returned with the return of sugar. Landolt's explanation is, that while sugar was present the vitreous became sugary, its refractive power being thus increased.

(2) Hypermetropia can be caused by too weak a curvature of the refractive surfaces in the cornea and lens. The cornea can be flattened by scars, particularly those made at its edge in operations; the cornea is, however, not only flattened, but also loses some of its spherical shape, thus producing the condition of astigmatism, which we shall discuss later, and which has such an influence on vision that in comparison the hypermetropia dependent on corneal flattening is of minor significance.

A pure hypermetropia does, however, result rather frequently from a flatness of the lens. It has been mentioned that during life the lens undergoes changes in density (which implies an increased refractive index); the same is true of its form, which implies an increased surface curvature. The lens of the new-born has an antero-posterior diameter of *4.0* to *4.5 mm.* and a breadth of *6.0 mm.*; the mature lens has also antero-posterior diameter of *4.0* to *4.5 mm.*, but is *9.0* to *10.0 mm.* in breadth. This shows that the lens in youth has a stronger curvature, in age a weaker one. We can therefore ascribe the frequent change in advancing life from emmetropia to hypermetropia both to increasing thickness in the cortex and to a flattening of the lens itself.

Naturally the hypermetropia is very intense when the lens is altogether lacking. This is the case in lensless, "aphakic" eyes the result of congenital conditions, of injuries, or

Digitized by Google

of cataract operations. In an aphakic eye otherwise normal the focus lies, as has been said (*p. 21*), nearly *1 cm.* behind the retina.

Although there are cases of hypermetropia due to faults in the lens, they are infrequent in comparison with that kind of hypermetropia depending on a lack of coincidence of focus and retina in an eye that is in every respect normal.

(3) *Hypermetropia is generally due to the fact that the eye is too short.* Anatomical measurements have established this fact, and in pronounced cases it can even be recognized in the living body. If a hypermetrope is asked to turn his eye strongly inward, the globe becomes visible up to the equator, and the sharp curve (its small size, therefore) is quite apparent; this is particularly noticeable upon examining a myopic eye at the same time, when the oval shape of the latter and its lesser curvature toward the equator come out in distinct contrast.

The degree of hypermetropia is obviously measured by the convergence which must be given to the luminous rays at the cornea in order to form an image on the retina. That point toward which rays must tend, when passing through the refractive media of the eye, in order to form an image *on* the retina, is called the *far point* of that eye (*R* in *Fig. 9*); but since the convergence of rays is estimated by the position of the far point, we can say that hypermetropia is inversely proportional to the distance of the far point, or $H = \frac{1}{r}$, not forgetting, of course, that in this case the far point is virtual or negative and lies behind the eye. In accordance with the explanation in the previous section, it is understood that we measure r in meters, and that therefore $H = +1$ is the hypermetropia of an eye whose far point lies *1 m.* behind the principal plane of that eye.

The degree of hypermetropia is found by selecting that convex lens which gives to parallel rays the convergence necessary to focus them at the far point of the eye. But it is obvious that convex lenses of different strengths can do this so long as attention is paid only to making the focus of the lens identical with that of the eye. In Fig. 9, for example, let *S S* be a lens whose focus is at *R*, that is, a lens which converges parallel rays to a focus at *R*. If we place the lens further from the eye at *A* (toward the left), then its focal distance, *A R*, would have to be much longer, and its refractive power much less than that of a lens at *S S*. We must therefore have a defin-

Digitized by the Internet Archive in 2010 with funding from University of California

ite place at which to put the lens. Theoretically this would be at the principal plane of the eye, but since this is obviously impossible, the rule has been established to put the lens as close to the cornea as possible; by doing this the distance of the lens from the principal point of the eye can be neglected, and the distance from *S S* to *R* can be considered equal to the distance of the far point (punctum remotum) of the hypermetropic eye, which is, exactly speaking, only the distance from *R* to the principal plane. Now then, that lens which, placed close to the patient's eye, makes parallel rays converge to an image at the far point, *R*, or, in other words, which enables that eye to see distinctly, is the lens which measures the hypermetropia, assuming, of course, that the patient makes no effort at accommodation, a condition which is not as a rule realized.

The hyperope who can see distinctly objects at a distance (infinity) only when he shortens the focal distance of his eye by the help of his accommodating power, is so accustomed to this act

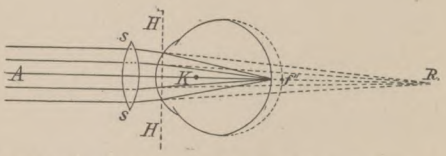

FIG. 9.—MEASURE OF HYPERMETROPIA BY MEANS OF A NEUTRALIZING LENS.

that he brings it into play even when the converging lens held before his eye makes this act superfluous. Thus it happens that hyperopes accept weak lenses and refuse strong ones, although it may be proven later on that the stronger was the proper lens to correct the hypermetropia. *Hypermetropia is therefore partly voluntary (manifest) and partly involuntary (latent) as a rule.*

To demonstrate as nearly as possible the total hyperopia, proceed as follows: Let the patient read the letters on the test-card as far as he can without glasses; then have him shut the eye under examination;[1] when the eye is shut the muscle of accommodation is relaxed; now place a convex lens in front of his eye and let him then open it. This proceeding reduces to a minimum the effort to accommodate, corresponding to the strength of the lens used. Continue thus to keep the eye shut at every change of lens, and as

[1] It is understood that only one eye is examined at a time, the other being closed meanwhile.

Digitized by Illinois College of Optometry

a rule the greater part of the manifest hyperopia will be overcome. Only in very young persons is the opposite usually the case. (Concerning the influence of age, see "Hyperopia.") If the patient continuously wears the lens corresponding to his manifest hyperopia, a second test can be made after a few weeks, and probably by this time the former latent hyperopia will now be changed to a manifest hyperopia, for the less frequent claim on the involuntary effort to accommodate has materially relaxed the "spasm of accommodation" which was there before.

To estimate the total hypermetropia at the first trial we must paralyze the muscle of accommodation by atropin or homatropin. This is not to be indiscriminately resorted to, for atropin paralyzes not only the musculus ciliaris (the muscle of accommodation) but also the sphincter iridis. The result is a strong dilatation of the pupil and an unpleasant dazzling, preventing the patient from doing any work close to the eye. These disadvantages are particularly distressing after atropin, the effect of which scarcely disappears even after eight days, while the effect of a moderate dose of homatropin may have nearly passed off within a day or so. It must be remembered, too, that atropin while paralyzing the muscle of accommodation may destroy its proper and normal tone, so that a hypermetropia may be produced that in reality does not exist.

5. RANGE OF ACCOMMODATION AND PRESBYOPIA.

It has been shown that the far point of an emmetropic eye lies at infinity, that of a myopic eye at a finite distance before, that of a hyperopic eye at a finite distance behind, the retina. Every eye, no matter what its refractive condition is, can, with the help of accommodation, see objects nearer than its far point. The nearest point which an eye can see when its total accommodation is called into play, is called the *near point* (punctum proximum), *N* in *Fig. 10. The dioptric value of that change which an eye undergoes in accommodating from its far point to its near point is called the range of accommodation and is designated by A.*

We must now determine how to measure this change which an eye undergoes in accommodating from any point, *a*, to a nearer point, *b*. A. Fick [1] and later Donders [2] proposed as a measure of this

[1] "Die medicinische Physik." Braunschweig. S. 306. 1856.
[2] *Arch. f. Ophth.* IV., 1, S. 305. 1858.

accommodation the strength of that convex lens which would adjust an eye to the nearer point without effort on its own part. This proposal has been since then universally adopted. Suppose a convex lens placed in the principal plane of the eye; then its refractive strength and with it also the range of accommodation can be expressed by the formula $A = \frac{1}{N} - \frac{1}{F}$.[1]

The formula $A = \frac{1}{N} - \frac{1}{F}$ is derived from the formula in physics used for lens $\frac{1}{f} = \frac{1}{a} + \frac{1}{b}$, or, translated into words, the reciprocal value of the focal distance of a lens (its refractive strength) is equal to the reciprocal value of the distance of the object plus the reciprocal value of the distance of the image from the lens. This will be understood from *Fig. 10*. *M* denotes a myopic eye whose principal plane is marked *H H;* the far point is *F* and the near point *N*. Imagine a convex lens, *S S*, placed in the principal plane, its strength being just enough to make divergent rays from *N* convergent, so as to appear to come from *F*. In the above formula, *N* now is the same as *a*, the distance of the object, and *F* the distance of the image, *b;* but since *F* does not lie in the direction

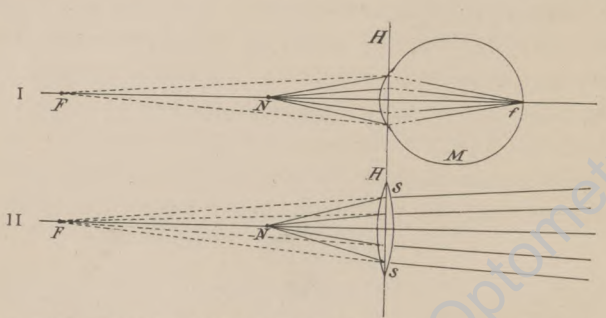

FIG. 10.—MEASUREMENT OF THE RANGE OF ACCOMMODATION BY A CONVEX LENS.

of the luminous rays but in a prolongation backward, the image is in this formula virtual, and —*F* must be substituted for *b*. The formula then becomes

$$\frac{1}{f} = A = \frac{1}{N} + \frac{1}{-F} = \frac{1}{N} - \frac{1}{F}.$$

Let us now apply the general formula of the range of accommodation to particular refractive cases. The far point in emmetropia lies at infinity, ∞ ; then $\frac{1}{F} = 0$. The far point in hypermetropia lies behind the eye and is negative ; $\frac{1}{F}$ becomes $\frac{1}{-F}$. If the minus sign be placed in front of the equation it indicates that the range of accommodation in hypermetropia $= \frac{1}{N} + \frac{1}{F}$. If we remember, more-

[1] N and F in this formula signify Near and Far points.

Digitized by Illinois College of Optometry

over, that the hypermetropia of an eye is equal to the reciprocal value of the distance of its far point ($= \frac{1}{F}$), and the myopia of another eye $= \frac{1}{F}$, then we can express A for each particular case in the following manner :—

$$A_{(e)} = \frac{1}{N}$$

$$A_{(m)} = \frac{1}{N} - M$$

$$A_{(h)} = \frac{1}{N} + H,$$

or, in words : The range of accommodation of an emmetropic eye is equal to 1 divided by the distance of its near point ; the range of accommodation of a myopic eye is equal to 1 divided by the distance of its near point minus its myopia ; the range of accommodation of a hypermetropic eye is equal to 1 divided by the distance of its near point plus its hypermetropia.

How do we get the near point of an eye ? The simplest method is obviously to approach a test-type to the eye till it can no longer be read ; the shortest distance from the principal plane at which a letter can be read must be the near point, but since large type can be read by an eye even when it is not exactly accommodated for it, we must select a letter suitable to the supposed near point and proportionate to the estimated acuteness of vision. Suppose we find that an eye can read Snellen *0.5* (that is, Snellen's type which a normal eye reads at *0.5 m*) at even 15 *cm.*, we must test again with perhaps Jaeger's *No. 1*, or with " diamond type," such as is seen on the second-hand of watches. If we find that such fine type cannot be read at 15 *cm.* we conclude that the near point lies somewhere beyond the 15 *cm.*

The principal point lies close to the plane which passes through the sclero-corneal border. We can therefore measure the distance from the corneal margin when the eye is looking straight ahead, and call it the distance of the near point.

In all text-books of ophthalmology and physics that I have examined, the statement is found that the near point is at " some distance in front of the eye." This is too indefinite. Donders[1] measured to the near point from the anterior nodal point. I consider this incorrect, for my analyses on *pp. 21 et seq.* have clearly shown that only the (anterior) principal point is to be considered. v. Graefe devised a special instrument for the estimation of the near point, the rod-optometer. It consists of a frame in which several

[1] " Anomalien der Refraktion und Accommodation," II. Auflage, S. 26 u. 32.

Digitized by the Internet Archive College of Optometry

black wires are stretched parallel to each other. On the frame is a tape-measure which can be wound up on a spool by a spring. The spool is held at the temple of the eye to be examined, and the frame is approached to the eye till the wires can no longer be distinguished; then it is withdrawn to the point where they become clearly visible again, and this distance from the edge of the cornea is read off on the tape measure. Another kind of optometer is in more general use than v. Graefe's, for it furnishes a short cut to the estimation of the refraction of the eye as well as of the visual acuity. Most of these consist of a convex lens of known strength and a series of photographically reduced test-types. *Fig. 11* explains the principle: *S S* is a convex lens of *10.0 D*. Such a lens has a focal distance of $\frac{1}{10}$ *m.*, that is *0.1 m.* or *10 cm.* Suppose at the point *F*, *10 cm.* from the lens, we place the test-type; now an emmetropic eye behind the lens can see the print distinctly without using accommodation. If the eye cannot read unless the type is brought nearer to the lens, then the eye must be myopic, and the myopia must be the stronger the nearer the print must be brought to the lens. Again, if the type can be read further from the lens than at *F* (toward the left in *Fig. 11*), the eye must be hyperopic. For example, an eye can read that type corresponding to his *V* at *4 cm.* from *F* (to the left), that is, at a distance of *14 cm.* from the lens; the image of the letters produced by *S S* must be then *35 cm.* to the right of the lens, for if *f* is the focal distance

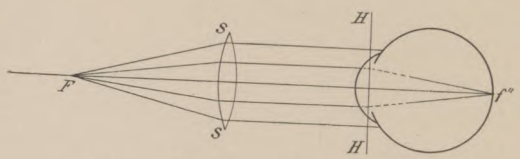

FIG. 11.—PRINCIPLE OF THE OPTOMETER.

of a lens, *a* the distance of the object, and *b* that of the image, by applying the formula $\frac{1}{f} = \frac{1}{a} + \frac{1}{b}$ we have the following equation:—

(1)
$$\frac{1}{10} = \frac{1}{14} + \frac{1}{x}$$
$$\frac{1}{10} - \frac{1}{14} = \frac{1}{x} = \frac{14 - 10}{140} = \frac{4}{140} = \frac{1}{35}.$$

The distance of the lens, *S S*, from the principal plane, *H H*, must be considered, but if we make this just *10 cm.* the problem becomes very simple. In that case every centimeter that the type is moved from *F* toward the right indicates *1.0 D* of myopia, every centimeter of *F* toward the left indicates *1.0 D* of hyperopia. In the example above, for instance, the image lies *35 cm.* to the right of *S S*, or *25 cm.* behind the principal plane, *H H*; consequently the refractive condition of the eye $= \frac{100}{25} = 4.0\ D\ H$, or with test-type *4 cm.* to the left of *F* refraction equals *4.0 D* of *H*.

That this rule is universally applicable can be shown as follows: in

(1) *b* is the distance of the image from the lens, *S S*, and equals

(2)
$$b = \frac{a \times 10}{a - 10}.$$

Moreover, the refraction of the eye to be examined, expressed in Diopters (*y*), is:—

(3)
$$y = \frac{100}{\mp b \pm 10},$$

Therefore
$$\mp b = \mp 10 + \frac{100}{y},$$

Digitized by Illinois College of Optometry

Consequently

$$(4)' \qquad \frac{a \times 10}{a - 10} = +10 + \frac{100}{y}$$

$$(4)'' \qquad -\frac{a \times 10}{a - 10} = -10 + \frac{100}{y}$$

$$(5) \qquad y = a - 10 \text{ or } -a.$$

The practical significance of the range of accommodation lies in the fact that the range of accommodation is dependent,[1] not upon the refractive condition of the eye, but upon the age. For as age increases, the range of accommodation decreases, this decrease in the range of accommodation with increasing age depending upon the changes in the lens mentioned on *p. 38*. These changes are, to be sure, only completed in advanced life, but they commence in childhood. The contents of the lens capsule grows denser and stiffer and the result is that the lens grows porportionately sluggish and shows less tendency to assume a spherical shape when the Zone of Zinn is relaxed during contraction of the muscle of accommodation. We see, consequently, a decrease in the range of accommodation already beginning at a time when the rest of the body, including also this muscle of accommodation, has not yet reached maturity, not to mention passing beyond it. The following table shows the relation of range of accommodation to age:—

Age in years.	*A* in Diopters.	Age in years.	*A* in Diopters.
10,	14	45,	3.5
15,	12	50,	2.5
20,	10	55,	1.75
25,	8.5	60,	1
30,	7	65,	0.75
35,	5.5	70,	0.25
40,	4.5	75,	0

If we can guess at the range of accommodation from a man's age we ought conversely to guess his age from his range of accommodation, and this can be done, although such conclusions are not of rigid or official trustworthiness. The above figures are merely averages and do not exclude deviations, either upward or downward, in individual cases. This is plain when we study the not uncommon fact that in some persons the range of accommodation in one eye differs from that in the other.[2]

---

[1] Only in very high degrees of Ametropia is A less than might be expected from the patient's age.

[2] Schmidt-Rimpler, *Arch. f. Ophth.*, XIV, 1, p. 119.

Carl F. Shepard Memorial Library
Illinois College of Optometry
2092

The decrease in range of accommodation by increasing age has, as a consequence, a withdrawal of the near point from the eye (the far point, too, is withdrawn, but only in advanced life and to a slight extent). As soon as the near point reaches a distance of *25 cm.* the working power of the eye begins to suffer; one holds anything a little further off in order to see it clearly, one prefers to read books and to look at objects in a good, strong light, for then the pupils contract and rays of dispersion are shut out,—in fact, a man whose near point is withdrawn to 25 *cm.* suffers from that condition called oldsightedness, or **presbyopia.**

It is evident that presbyopia can begin at different periods of life in different conditions of refraction. An emmetrope at about forty-two years becomes presbyopic; a hyperope with *2.0 D* at thirty-four years, a myope with *2.0 D* not till fifty-four years. Indeed, a myope with M = *4.0 D* never becomes presbyopic, for even after the loss of the total range of accommodation where the near and far points coincide, he can yet see distinctly at *25 cm.*

The troubles of oldsightedness can be removed by extending their sphere of accommodation.

Take, for example, an emmetrope of forty-two and forty-three years. He can accommodate from infinity to *25 cm.* (equal to *4.0 D*); at a distance of *33 cm.* he could see plainly if he had accommodative power of $\frac{100}{33} = 3.0\ D$, this being ¾ of his entire range of accommodation. Now an eye can read continuously and without trouble only at a distance that requires at the most about ⅔ of its accommodative power. In the above case, therefore, we give a convex lens of *1.0 D*. By the aid of this, which brings his far point to $\frac{100}{1} = 100\ cm.$, added to his accommodative power of *3.0 D*, his near point is brought to $\frac{100}{4+1} = 20\ cm.$; to read at *33 cm.* demands an adjustment equal to *3.0 D*, but if *1.0 D* of this is supplied by the lens, the patient need use only *2.0 D* of accommodation, that is, ½ of his range of accommodation.

The above explanations show clearly that the same range of accommodation may have a very different significance according as it belongs to an emmetropic, a myopic, or a hyperopic eye. For example, an emmetrope with *A* = *5.0 D* controls all space from infinity to $\frac{1}{5} = 0.2\ m. = 20\ cm.$ in front of his eye; his sphere of accommodation is therefore endless. A myope of *M* = *4.0 D* with *A* = *5.0 D* controls only the small interval from his far point at $\frac{1}{4}\ m.$ to his near point, $\frac{1}{4+5}\ m.$, that is, *0.25 m.* to *0.11 m.*, or from *25* to *11 cm.*; his field is therefore only *14 cm.* Finally, a hyperope of *H* = *4.0 D* with *A* = *5.0 D* controls all space from his far point, $\frac{1}{-4}$ to his near point, $\frac{1}{5-4}$, that is, from *25 cm.* behind his eye to

Digitized by Illinois College of Optometry

everything in front of his eye within *100 cm.* Every hyperope can therefore accommodate for all objects between infinity and *100 cm.;* the field of his accommodation, like that of the emmetrope, is immeasurably large, but does not come closer than *100 cm.* to his eye, and is consequently defective at just those distances for which exact adjustment is of prime importance. Indeed, when a hyperope is fifty years old and has still an $A = 2.5\ D$ at his disposal, his whole range of accommodation does not suffice to adjust his eye for infinity (parallel rays), to say nothing of anything nearer to him. Such a condition is called *absolute presbyopia.*

Many presbyopics do not even ask for glasses. Nature helps them out in this by making the pupil grow narrow and narrower with increasing age, a condition that, in spite of false dioptric adjustment, produces a tolerably sharp vision.

The fact that the pupils grow narrower with increasing years can perhaps be explained thus: anyone having a range of accommodation of *9.0 D* reads at *33 cm.* distance from the eye by using $\frac{1}{3}$ of this range of accommodation, but with only *4.0 D* of accommodation at his disposal he must use for the same purpose $\frac{3}{4}$ of his energy. The contraction of the pupil which takes place during accommodation proportions itself doubtless to the impulse given by the will to the ciliary muscle, but is not related to the effect of this impulse on the form of the lens. It is therefore plain that, neglecting other conditions, the pupils will be the narrower the smaller the range of accommodation is.

6. ASTIGMATISM, As.

Astigmatism indicates that condition in which a homocentric pencil of rays falling on the eye will not form an image at all, neither in front of, nor at, nor behind the retina. There may be several causes for this. A slight haziness or any such unevenness in the cornea or lens suffices to distort rays from their prescribed course; such *irregular astigmatism*, as it is called, will be discussed later. We are now treating of that condition which depends on a distinct deviation of one or all of the refractive surfaces from the spherical form, which is called *regular astigmatism.* To get an idea of this deviation, take a symmetrically shaped egg (an ostrich egg is a good one), cut it through both lengthwise and sidewise; the surface of that half cut lengthwise is an ellipse, of that half cut sidewise is a circle. The circumferences of the ellipse and of the circle cross each other at two points; at one of these points put one leg of a compass and describe a circle on the surface of the egg. The shell circumscribed by this circle is only a small part of the whole, but we can speak of its two principal meridians, although strictly speaking one of them describes an ellipse. Now

Digitized by Illinois College of Optometry

notice that the diameters of each of these two principal meridians are different; such a surface is therefore called "meridionally asymmetrical." If we image that this meridionally asymmetrical piece of egg-shell is the refracting surface (the cornea) between air and aqueous, such an eye would have a regular astigmatism. We may further suppose the above meridian-asymmetrically curved cornea, with its sharper curved principal meridian, *pp*, *Fig. 12*, to be perpendicular and the weaker curved principal meridian, *hh*, horizontal; now let us determine what is the refraction of a homocentric pencil of rays in passing through this cornea. The object lies toward the left at infinity on the optical axis of the eye; a pencil of rays parallel to this axis falls on the cornea, *phph*; the rays that fall on the horizontal meridian, *hh*, are marked in red; their meeting point is at *f''*. The rays that fall on the sharper curved perpendicular meridian, *pp*,

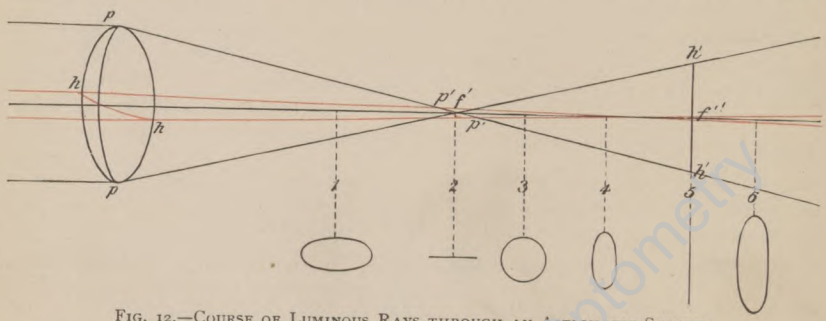

FIG. 12.—COURSE OF LUMINOUS RAYS THROUGH AN ASTIGMATIC SYSTEM.
The images of the lines and the ellipses are for the sake of clearness drawn below their true position.

obviously must have their meeting point at a shorter distance, say at *f'*. The question now is, what kind of image appears if we collect all the rays passing through the cornea on a screen (the retina at *f'*) or some other point on the axis of the eye at *f''*? The answer to this question can be found by mathematical investigation, but as this is rather complicated, we must be satisfied with the answer alone, convincing ourselves of its correctness by a simple experiment with a spherico-cylindrical lens. We find that the rays coming from the left in passing through the meridian-asymmetrical cornea are so refracted that there results a horizontal line on a screen placed at *f'*, "the anterior linear focus," and on a screen at *f''* a perpendicular line, "the posterior linear focus." If the screen be placed anywhere between *f'* and *f''* there results a circle as at *3* or an ellipse as at *4*, but never a true image, and also

Digitized by the Internet Archive of Optometry

the same thing results in case the screen is in front of, as at *1*, or behind, as at *6*.

If the object is approached with uniform speed from infinity, the lines, $p'p'$ and $h'h'$, separate from each other toward the right, at first very slowly but with increasing speed. This unavoidable separation of these "linear foci" from the retina can, however, be compensated for by accommodation, that is, by shortening the focal distance so that near objects can throw their image lines on the retina, or at least very close to it; this is also the case when the object lies not on the axis, but reasonably close to it.

We can give an idea, but not a demonstration, of the origin of "linear foci" in the following manner: Imagine the cornea, *hphp*, *Fig. 12*, cut into segments by perpendicular planes, all of which pass through the middle point of the arc, *hh*. These segments are all perpendicular, all have the same diameter as *pp*, and are placed the more obliquely to the optic axis the further they lie away from *pp*. The pencil of rays which falls upon the principal meridian, *pp*, will form an image at f', a second pencil which falls on a segment of the cornea lying to the right of *pp* likewise forms an image at the same distance, f', not, however, in the plane of the entering rays but rather inward from it; the more inward the stronger the curvature of *hh* is, or, in other words, the more obliquely the perpendicular corneal segment is to the entering plane of the pencil. The result is that near f' is a series of images which lie the closer to each other the less the difference in curvature between *pp* and *hh*. If this distance is *o*, that is, if the refracting surface is spherical, then all these points of the single pencil of rays must unite at f', or the pencil forms an image!

A similar process of reasoning shows that at f'' there results a perpendicular linear focus, only that here the focal points of the rays entering above *hh* form images below f'', and those of the pencil beneath form images above f''.

If we remember the statement (at *p. 17*) that acute vision is possible only in case every object forms a geometrically exact image on the retina, it is clear that an astigmatic eye must see indistinctly, no matter where the receiving screen (the retina) may be; but the distortion of the retinal images differs greatly according to the forms of the object and according to the relation of the retina to the focal area. Let the luminous object be a horizontal line at infinity and place the retina at the position of the anterior linear foci; in such a case the horizontal line will obviously appear nearly as distinct as to a normal eye. Then every point of the linear object will form a linear image, $p'p'$; these linear images lie one over the other and produce a complete image, which, apart from its being somewhat lengthened, is of exactly the same shape as in the normal eye. If, however, the object is a perpendicular line it will

Digitized by the Internet Archive of Optometry

appear of normal length but distorted in width by *pp*; consequently a square appears oblong and a circle an ellipse.

The relation of the retina to the focal interval of the meridianally asymmetrical system distinguishes the kind of astigmatism and its classification. If the retina is to the right of *f''* (*Fig. 12*), we have to do obviously with an eye generally myopic in both meridians but of different degree in each; such a condition is called "compound myopic astigmatism" (*astigmatismus myopicus compositus*). If the retina is at *f''*, there is emmetropia in the horizontal meridian and myopia in the perpendicular, simple myopic astigmatism (*astigmatismus myopicus simplex*). If the retina is in front of or at *f'*, we have in the first case compound hyperopic astigmatism (*astigmatismus hyperopicus compositus*), and in the second case simple hyperopic astigmatism (*astigmatismus hyperopicus simplex*). Finally, if the retina lies between *f'* and *f''*, we have myopia in one meridian (here the perpendicular) and hypermetropia in the other meridian (here the horizontal),—a condition called mixed astigmatism (*astigmatismus mixtus*).

Astigmatism can be diagnosticated in the following manner: In Snellen's test-cards there is one with groups of lines, each group having three lines of the same size parallel to each other and with the spaces between of the same width as each line; at each group is a number designating the distance at which the line of that particular thickness ought to be perceived at an angle of 5'. For example, the thinnest lines are marked *6.5*, designating that a normal eye ought to distinguish these lines from each other at *6.5 m.*, no matter whether they are placed perpendicular, horizontal, or diagonal. With astigmatism it is otherwise! An eye suffering from simple myopic astigmatism, having the retina at *f''* (*Fig. 12*), in looking at the card from *6.5 m.* can count the lines distinctly only when they are perpendicular. If the card is turned 90°, bringing the lines horizontal, they appear to this eye to run together as blurred lines.

If astigmatism is thus proved to be present, the next step is to find the direction of the principal meridians. Snellen provides for this purpose the card of rays or spokes, as in *Fig. 13*. If this card is approached from a distance toward an eye with, say, compound myopic astigmatism, a certain position will be reached where the posterior linear focus (*h' h'* of *Fig. 12*) which at first lay in front of the retina will now fall on it; at this moment the perpendicular

Digitized by University of Illinois Urbana-Champaign

ray appears black (because clear), but all the rest seem gray (because they are blurred); and more gray and blurred the nearer the ray approaches the horizontal. The ray that first appears clear and sharp indicates the direction of the principal meridian of greater refraction. If some oblique ray instead of the perpendicular one is the first to become clear, it indicates an exceptional case of astigmatism where the principal meridians are oblique.

The test with the figure of rays is obviously applicable to all cases of astigmatism, since each astigmatic eye can be made myopic by holding an ordinary spherical convex lens in front of it; that is, a compound myopic astigmatism can be induced.

Finally, the astigmatism must be measured. From what has been already said, it is evident that **the measure of astigmatism must be the difference between the degrees of refraction in the two principal meridians.** If, for example, one meridian has $M = 1.0\ D$ and the other $H = 1.5\ D$, then $As = 2.5\ D$. The most direct way to measure astigmatism would be to measure the refraction of each meridian separately, and as a matter of fact we can do this by means of the stenopaic slit. This little instrument consists of a piece of metal formed like a spectacle glass, with a small slit in it. If this slit is held in front of the eye, all rays are shut out except that thin pencil entering through the slit and through a segment of the cornea corresponding to it. We estimate by means of ordinary spherical lenses the refraction of one meridian, turn the slit around $90°$, and repeat in the same way the measurement for the second meridian thus exposed.



FIG. 13.—SNELLEN'S CARD FOR TESTING ASTIGMATISM.

It is evident that in choosing the width of this slit we lie between Scylla and Charybdis; if the slit is too narrow, say *1 mm.* or less, then too much light is shut out and very disturbing phenomena of diffraction occur; if the slit is wider, say *2 mm.*, then one meridian is not altogether isolated, but a segment is exposed in which the asymmetry of this meridian becomes active again. We conclude from this that another method is more serviceable, namely, that *astigmatism is measured by the neutralizing cylindrical lens. Figs. 14* and *15* show these lenses. Imagine the retina to be at the first

Digitized by Illinois College of Optometry

linear focus of the dioptric system (f' in *Fig. 12*), and let it be desired to form an image of the red rays likewise at f'. It is plain that this can be accomplished by placing in front of the cornea a convex cylindrical lens with its axis perpendicular, because luminous horizontal rays (from right to left) in passing through such a lens are refracted toward the axis, while those from above downward (perpendicular) are not refracted; and in case the lens has a focal distance of x (where $\frac{1}{x} = \frac{1}{f'} - \frac{1}{f''}$), all rays will consequently be united at f'. The rule, therefore, for estimating astigmatism by means of neutralizing cylindrical lenses runs as follows: After determining the presence of astigmatism and the position of the principal meridians in the manner above mentioned, and after determining by a preceding test [1] whether myopia or hypermetropia is present, try on a myopic eye a concave cylinder with axis perpendicular to the meridian of greater curvature; the cylinder with which the

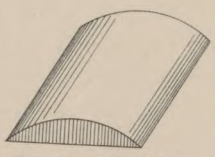

FIG. 14.—A CONVEX CYLINDER.

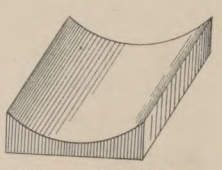

FIG. 15.—A CONCAVE CYLINDER.

best V is contained measures the degree of myopic astigmatism present. Try on a hypermetropic eye a convex cylinder with axis perpendicular to the meridian of lesser curvature; the cylinder with which the best V is obtained measures the degree of hyperopic astigmatism present. If there is mixed astigmatism, concave and convex cylinders must be tried with axes as above, till the best V is obtained.

Such examinations require patience and a grasp of the theory of the subject on the physician's part. In many cases, especially of hyperopic astigmatism, a good result cannot be obtained without atropin or homatropin, since every effort of accommodation, though it may not change the astigmatism itself, must alter the relation of the image to the retina; a given lens will therefore seem to effect a good result at one moment and a bad result at another.

[1] Generally we use for preliminary tests as to the nature of a case the objective methods of examination described on *p.* 97.

Digitized by Illinois College of Optometry

II. LIGHT SENSE.

By **light sense** we mean that ability of the eye to distinguish different intensities of light, and it is therefore the essence of all vision, since even the letters and figures of a Snellen's test-card are obviously recognized by the difference between the black of the letters and the white of the background. Consequently the acuteness of vision of an eye cannot be estimated without calling the light sense into play. The converse, however, is possible, for we can estimate the light sense without reference to the acuteness of vision. Since Fechner's time a distinction is customarily made between the *sense of stimulation* and the *sense of contrast.* The sense of stimulation expresses the power to distinguish the effect produced by the smallest possible quantity of light when all else is absolutely dark. The sense of contrast expresses the power to distinguish the effect produced by the smallest possible difference in intensities between two unequally illuminated objects. This has been called a superfluous refinement, as the ability to distinguish a shade of light from absolute darkness is only a step in the functional distinction of more from less light; but it is worthy of consideration that to a certain extent there is an influence of one illuminated area of the retina upon another, and it is therefore a different matter whether I compare the illumination of two objects or whether I distinguish one single bright spot in an otherwise absolutely dark space.

Moreover, it is maintained (though disputed by some) that in certain diseases absolute and relative functional activities are modified quite independent of each other, but the most convincing argument against any essential unity between them lies in the fact that the sense of stimulation becomes greater with a decrease in the illumination.

The sense of stimulation can be tested by Foerster's photometer. This consists of a box $\frac{1}{3}$ *m.* long, $\frac{1}{4}$ *m.* broad, and $\frac{1}{6}$ *m.* high, painted black on the inside. On one side are two peek holes, *a a*, for the eyes to be tested, with a curtain, *b b*, to shut off either eye at will. Next to these holes is a window, *c*, covered with oiled paper and so arranged by movable shutters, *d d*, that by turning the screw, *e*, a square hole of any desired size is adjusted at the window. The size of this hole can be read off on the scale, *f*, which is connected rigidly to the upper shutter and slides on a standard below. The

Digitized by the College of Optometry

little window, *c*, admits light from a candle placed in a separate compartment, *g*, so that no light is thrown directly upon the eye under examination. On the wall opposite the peek holes there are black marks, *h h h*, on a white ground. The test consists in determining that size of window at which the black marks on the white ground become noticeable. The size of the window is the measure of the amount of light entering the box, and this amount of light that makes the marks visible measures the sense of stimulation of the retina. For example, if one eye can see the black marks when the size of the window is *2 sq. mm.*, while another does not see them till the window is *20 sq. mm.*, the functional activity of this last eye is

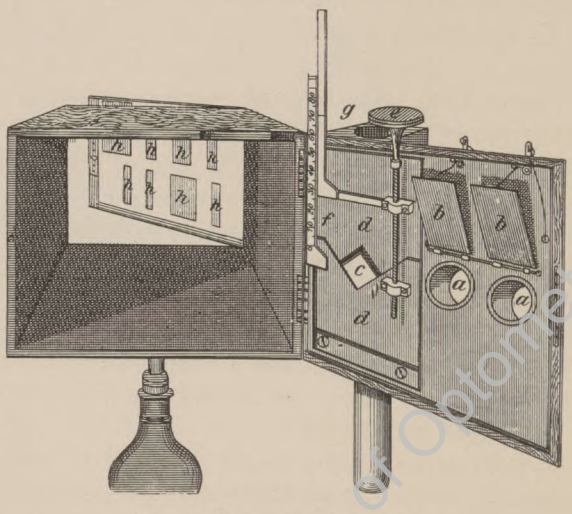

FIG. 16.—FOERSTER'S PHOTOMETER.
Represented here with the doors open. When in use both doors are closed.

ten times greater, its light sense *ten* times smaller than that of the first eye.

In experimenting with this instrument it will soon be noticed that the retinal activity in the same eye is distinctly affected by the conditions of illumination under which it was placed immediately before the trial. If a patient is led from daylight into the dark room where the instrument is, and tested at once, the size of the window (*c*) must be quite large in order to make the marks visible, but at every repetition of the test the opening will be smaller, until finally, after something like half an hour, each test will give approximately the same result. We conclude from this that with the

Digitized by Illinois College of Optometry

exclusion of all extraneous light a change takes place in the eye, consisting of an increase in the sensitiveness to light (measured as above). This change in the eye implies an adaptation to extraneous illumination, or the lack of it. In passing from light to darkness this adaptation takes place at first very quickly, but soon becomes slower, though an essential equilibrium is never obtained even after prolonged seclusion in darkness. The same conclusion is reached from the circumstance that even in complete darkness we are conscious of continually changing subjective light phenomena.

This act of adaptation every one has doubtless observed in his own case. In going some summer's day from the brightness of sunlight into a dark room protected by curtains and blinds, one can at first see nothing at all ; but objects in the room soon become visible, and after a quarter of an hour one can see in the dim light as well as in the daylight before. We have only presumptions of what this adaptation depends on. One circumstance, though probably not the essential one, is the play of the pupil that widens in the dark, and to that extent admits more light into the eye from any illuminated object. It is probable that the essential factor in the process of adaptation is to be found in the retina ; we can imagine on the one hand a movement of the pigment of the epithelial cells (external retinal layer, *Fig. 110*), and, on the other, a new formation and collection of visual purple in the outer elements of the rods.

The sense of contrast of an eye can be measured by Masson's disk. This instrument is constructed as follows : A black disk and a white one of equal size have in the center a hole through which passes an axle. Both disks have a slit from the center to the circumference, and the disks are movable, so as to admit of forming with the uncovered parts a black and white disk which can be adjusted to give any required proportion of black or white. If now the axle is revolved with the two disks, the resulting effect is no longer black and white, but gray, and becomes grayer in proportion as white preponderates over black, or *vice versâ*. If a third and smaller black disk is now fastened upon the axle, when this is revolved we see an interior black disk surrounded by a gray edge. The relative functional activity for light perception, that is, the sensitiveness of the retina to contrast, can be measured by the amount of white in the large white disk, which can be left uncovered by the large black disk before the gray edge around the central black disk ceases to be distinguishable.

Besides Masson's disks and Foerster's photometer, there are other methods for testing the light sense, by which the acuteness of vision is estimated at the same time. A mere mention of the principle must suffice.

Digitized by the Internet Archive in 2007 with funding from Microsoft Corporation

In the ordinary Snellen's test-cards the black letters are about sixty times less bright than the white background.[1] Now, this relationship can be changed by using, instead of black letters, gray letters of different shades on either white or black ground. The less the difference required between the brightness of the letters and that of the background, to make the letters discernible to the eye, the greater is the sensitiveness of the retina.

Finally, the method may be tried of testing by Snellen's cards in reduced light, either in a darkened room or by placing smoked glasses before the eye to be tested.

In these experiments three functions come into play—

(1) *Vision.*

(2) *Light-sense.*

(3) *Adaptation.*

At the first glance this might seem inappropriate, but these different functional tests admit of determining one condition, or at least of investigating its degree, that is, the condition of *hemeralopia* or night-blindness. This is present when sight is relatively worse in diminished light than would be the case in a healthy eye with the same illumination. Hemeralopics are therefore about as helpless as the blind in the evening twilight or in the light of street lamps, although in good daylight they may have normal vision. Hemeralopia was formerly called a reduction in the sense of light with slow adaptation, but recently Kuschbert, and especially Treitel, have declared that it depends particularly upon diminished adaptation or a total absence of that function. Supposing that this view is correct, the hemeralopic must have in good daylight equally as good contrast sense of the retina as the healthy eye has, that is, he must be able to distinguish as different in brightness two objects which differ only $\frac{1}{186}$ in their objective illumination; this does not seem, by any means, to be always the case.

The demonstration of hemeralopia is often unnecessary, since the patient probably comes to the physician complaining of night-blindness.

---

[1] According to photometric comparisons between black and white papers made by Aubert.

Digitized by Illinois College of Optometry

III. COLOR-SENSE.

Color-sense is taken to mean that ability of the visual apparatus to respond with sensations of special and individual character to stimulation by light of various wave-lengths. Light rays with wave-length *.00069 mm.* give the sensation of red; rays of *.00039* give the sensation of violet; rays of wave-lengths between these give sensations of yellow, green, blue, etc. We make the most extensive use of this power of our eye. Not only does the artist who revels in the glorious coloring of a good painting, or the lover of nature who delights in a fair landscape or a gay flower garden, use their color-sense for enjoyment, but others also employ it in soberer professional duties. Mosaic workers, weavers, decorators, railway and marine employees can hardly carry on their vocations without the ability to distinguish colors. We can comprehend, therefore, why the ophthalmologist is often asked whether or not the color-sense is normal.

One might suppose that the answer to this question needed no physician's help, but that it would suffice to lay before the patient any colored objects, like bits of paper, and to have him select the colors by name. This is a great error. Indeed, it is often very hard to detect this failure in color-sense—to demonstrate color-blindness or a diminished color-sense, color-amblyopia. The color-blind have learned, often without realizing it, to conceal their shortcomings, and by heightened attention and the use of the light-sense to satisfy all the demands of existence with reference to the recognition and designation of colored objects. A man, for example, who is incapable of perceiving red—"red-blind"—does not see a beech leaf before him in its real coloring, although when questioned as to its color he may answer "red-brown." He knows that beech leaves are sometimes red, and recognizes this leaf by its lesser brightness quite as well as the normal person perceives the proper color. It is particularly difficult to unmask color-blindness or color-dulness when the patient, through fear of losing some position or other, calls all his wit into play in order to stand the test. It must be noted, however, that the uneducated are easily led astray by embarrassment or perhaps by mere lack of words, and unintentionally give a false name to a color. Most methods of testing for color-blindness, therefore, avoid mentioning the names of colors, but demand that individual colors be distinguished from each other.

Digitized by Illinois College of Optometry

A simple and practical, but by no means a very sensitive, method is Seebeck's[1] "*wool test.*"

It consists of a collection of various colored worsteds about *10 cm.* long, and the thickness of the finger. It contains, besides the spectral colors of red, orange, yellow, green, blue, and violet, the mixed colors, purple, rose, and gray, and there are four or five different shades of each color. In good daylight give the patient the bright *green* worsted in his hand with the other skeins scattered on a white or black, or at any rate on a colorless ground, and without calling the colors by name ask him to sort out all the colors like the sample without reference to the degrees of tints. One with normal sense disposes of this problem in a few moments, sorting out all the greens without hesitation or delay. But the color-amblyopic acts quite differently. The greens of the collection that are the same as the sample skein he matches very naturally, but at dark green he stumbles, calls it a match, and puts it back again; then he picks out a gray, and finally even a red is laid indecisively by the green sample. This settles the question. In matching red and green and gray he has shown himself as red-green blind! If, however, he has withstood the first test well, let him proceed to the second and more difficult one, in which he must match all the dark and light shades with a *rose* skein. Rose is, like purple, a mixture of red and blue. The red-blind patient cannot detect reds, and matches blues with the sample; the blue-blind matches red with it. In the same way a red-blind patient matches blues with violet, the blue-blind matches red with it.

A second test, depending upon the confusion of colors consists in having the patient read colored letters on a background of equal brightness in tone but of the complementary color, so that the letters must be distinguished by the specific color effect, not by a background of less or greater brightness. This is a very exacting test to withstand satisfactorily. Stilling, who devised it, was so successful with his pseudo-isochromatic cards that even the normal eye had difficulty in deciphering the letters. The surface of the card is divided into small squares or into quadrate fields with rounded corners (*Fig. 17*). The color of most of the squares is a delicate green, but there are some of a delicate red forming the letter E; there is thus a red E on a green background, which for one who is red-green blind is invisible.

[1] Often called Holmgren's, but Holmgren first applied it extensively.

Digitized by Harvard University Countway Library

A third method depends on the fact that a gray object on a red ground appears green, on a green ground red, on a blue ground yellow, and on a yellow ground blue—the effect of contrast giving it the complementary color.

This fact can be made use of by means of H. Meyer's test, which consists in covering with tissue paper a piece of gray paper lying on



FIG. 17.—EXAMPLE OF A STILLING CARD.

a colored background. The "induced" color shines through the tissue paper, often with a greater intensity than that of the primary background, but is apparent only to the eye possessing normal color-sense.

This method has been made use of by A. Weber, v. Bezold, and Pflueger as a test for color-blindness. Pflueger's cards for testing

FIG. 18.—EXAMPLE OF A PFLUEGER CARD.

the color-sense have gray figures, letters, or marks on a colored and equally bright ground (*Fig. 18*).

The patient is to decipher these through one or two sheets of tissue paper. The normal eye sees the gray figures by contrast in the complementary color, and recognizes them without difficulty. The color-blind, on the contrary, sees nothing at all of the letters

Digitized by Illinois College of Optometry

through the tissue paper. H. Cohn, who has had great experience in testing for color-blindness, declares that Pflueger's cards are the surest and quickest means of detecting total defect or even dulness of color-sense.

The three methods mentioned above are for the purpose, and generally have the result, of determining the presence of color-blindness or color-amblyopia. The ophthalmologist needs at times, however, a method for measuring the color-sense of the patient. Donders has suggested such a method. The principle of it lies in the fact that the color of an object is recognized by a normal eye only when this colored object is seen at not too small an angle. The minimum visual angle is different for different colors; supposing that colored areas are placed on a black ground, the necessary visual angle increases in the direction of the spectrum, that is, for red it is the smallest, for violet the largest. If one places on a blackboard colored squares or disks of equal size, the normal eye recognizes each color at its particular distance, and a color-amblyopic eye recognizes and names those disks for whose color it has not a normal sensitiveness only at shorter distances and at a greater visual angle. Obviously, then, color-sense is the duller the smaller the distance at which a color is first distinguished.

Donders expresses this by the formula: $k = \frac{1}{m^2} \times \frac{d^2}{D^2}$, in which k signifies the color discriminating power (to be tested), m the diameter of the test object, d, as in the formula for V, the distance of patient from the test-card; but D loses the significance of the formula $V = \frac{d}{D}$, and is by Donders used to signify the distance at which a normal eye with $k = 1$ ought to recognize the color of an object of *1 sq. mm.* surface area. To these different values of D in the V formula and in the k formula are to be ascribed so many confusing statements by authors.

Another difference between the formulæ for color-sense and for acuteness of vision is the fact that m, d, and D are squared (as above); this rests on the circumstance that the essential measure for color-sense is to be found in the amount of color reflected sufficiently to produce a color sensation, and in this case the amount of color reflected increases as the surface of the object, therefore as the square of the diameter.

Donders' method has been recently taken up, developed, and warmly recommended by Wolfberg. He uses red, yellow, green, and blue cloth disks on a black ground; the smallest red and yellow circular disks have a diameter of *2 mm.*, the smallest dark green and blue a diameter of *7 mm.* There are other disks of *18 mm.* diameter, and finally squares *100 mm.* on a side. The abbreviations are respectively: r^2, yl^2, gr^7, bl^7, etc. By means of these colored disks and a table worked out by Wolfberg it is said to

be possible not only to measure in a very short time the color-sense present, but also to diagnosticate whether discoverable dulness of color-sense rests upon errors of refraction, or upon cloudiness of refractive media, or upon diseases of the nervous apparatus. For example, an eye with a $V = \frac{5}{12}$ ought to recognize r^2 in *3.25 m.*, and bl^7 in *3.5 m.*, in case the imperfect vision depends upon short-sightedness; an eye with $V = \frac{5}{12}$ recognizes r^2 and bl^7 only within *2 m.*, when the imperfect vision depends upon cloudiness of the refractive media; and, finally, if an eye with $V = \frac{5}{12}$ does not recognize r^2 and bl^7 further than *2 m.* it certainly points to defect of color-sense.

It is clear that this method of investigation must be extremely valuable in cases where the question is whether any other disease besides cloudiness of the lens is present, or whether the parts of the eye back of the cloudy lens are healthy or not. Nevertheless, the trustworthiness of the whole method has been strongly denied by Herzog. The personal differences in color-sense, as H. Cohn showed more than twelve years ago, are extraordinarily great—always greater than the differences in vision. If, therefore, the ophthalmologist cannot conclude from the $V = \frac{5}{5}$ that an eye is normal in every respect (for it might have $V = \frac{5}{3}$ with a weak concave or convex lens), then it is still less admissible to conclude that the eye is normal in every respect even though r^2 and bl^7 can be recognized at *5.5 m.* Wolfberg himself acknowledges that a good daylight illumination is indispensable for the success of his color test, and since this cannot always be controlled, the practical application of Wolfberg's tests is essentially restricted.

I do, to be sure, make use of this test in cataract cases and in diseases of the fundus, but I confess I do not get the continued good results that Wolfberg claims.

IV. INDIRECT VISION AND FIELD OF VISION.

In the previous section the dioptrics of the eye and the functions of the retina have been discussed for direct vision only. An object is seen directly when it lies on a line connecting it with the nodal point and the macula lutea of the eye. In this fourth section we must examine acuity of vision, perception of light, and perception of color for indirect or peripheral vision.

Digitized by the Illinois College of Optometry

The difference between direct and indirect vision can be illustrated in the following manner: Lay on a printed sheet an unprinted sheet with a point in the center; look at this point and for an instant draw the unprinted sheet away; if the sheet is moved back and forth quickly enough there is no time, even if the eye is moved, to trace out the whole line or even a word; consequently only so many letters will be recognizable as lie at the spot of clearest vision. At a distance of about *30 cm.* we could read only four or six letters of ordinary type; therefore, in case the glance is directed to the end of a long word the word itself cannot be read.

Another experiment, applicable off-hand, will illustrate the importance of indirect vision. Look through a tube of any kind and hold the other eye shut; direct vision has not been impaired, but at the same time one is nearly in the condition of a blind person when it comes to finding one's way about the room, on account of the complete absence of peripheral illumination. Indirect vision, therefore, serves to give us a general idea of our surroundings and to call our attention to important things that we at once look at and then, by means of direct vision, observe more accurately.

The examination of the visual acuity of the peripheral parts of the retina must, in any case, begin by determining the refractive condition of the eye with reference to this retinal zone. On *p. 18* it has been explained that in general a centered system of spherical refracting surfaces produces images only of such objects as lie close to the axis of this system. What images result from objects that do not fulfil this condition; that is, that lie at a distance from the axis? The question is relatively easy to answer in the case of an aphakic eye when there is only one refracting surface. The answer is that a homocentric pencil of rays falling on the cornea from the side is refracted astigmatically. In case the object lies at infinity and the cornea has a curvature sufficiently strong to make the eye emmetropic, the posterior focal point of a pencil of rays would fall in front of the retina and only extremely indistinct vision would be possible. Complicated calculations have shown that with the conditions that accompany the really emmetropic eye, that is, with the proper refraction at the cornea and at the anterior and posterior lens surfaces, the posterior focus will lie on the retina; indeed, taking into consideration the fact that the lens is of a stratified structure, the result is that the linear foci fall exactly on the retina; in other words, the eye, thanks to the numerous refracting surfaces, is periscopic—that is, sharp retinal images are produced even from objects lying at one side. With the aid of the ophthalmoscope the

Digitized by the Cornell University Library

peripheral parts of the fundus can likewise be seen clear and undistorted, a fact that harmonizes with these theoretical deductions. To be sure, one sees quite well the peripheral parts of the aphakic eye, although theoretically this ought not to be the case.

In the emmetropic eye the periphery of the retina is easily examined, and, as Parent has found, is somewhat more astigmatic than the region of the macula. Axis myopic eyes may have some hypermetropia at the periphery, a fact easily understood when we consider the smaller transverse diameter of the longer bulbus. In hyperopic eyes, on the other hand, the difference between the transverse and the longitudinal diameters is but slight.

The first requisite of good vision is therefore complied with, as far as concerns the periphery of the retina, but the acuity becomes proportionally less as the edge of the retina is approached.

According to Becker, the retinal image of any surface that is seen at a visual angle of 1° covers exactly that part of the retina which has $V = 1$. From here toward the periphery the acuity of the vision of the retina decreases in the following manner:—

1.5° toward the periphery $V = \frac{3}{4}$
2.0° " " " $V = \frac{3}{5}$
2.5° " " " $V = \frac{3}{6}$

These figures correspond to angles above, below, to the right, to the left from the center of the retina. Further toward the periphery V decreases more rapidly above and below than to the right and left. At an area on the retina = 45° from the center V is only $\frac{1}{100}$.

Earlier investigators, Foerster and Aubert, have also found a similar reduction of V in the peripheral areas of the retina.

The explanation of the reduced sharpness of vision at the periphery lies obviously in the arrangement of the retina, since a great distinctness in seeing side objects is unnecessary for us. Consequently but little account need be taken by the ophthalmologist of peripheral vision.

It is remarkable that light perception in the retinal periphery is in inverse proportion to the acuity of vision of the same parts. Light sense measured by its function of stimulation from the macula lutea toward the edge of the retina becomes greater instead of less. We are convinced of this, if, in coming from daylight into a dark room, we look at a weakly illuminated object, say a small piece of luminous phosphorus. Looked at directly, it is invisible; but when we turn partly away from it, it springs into view!

Digitized by Illinois College of Optometry

This fact has long been known to astronomers, and was referred to by Arago. It was noticed that certain dim stars, the moons of Uranus, for example, were visible only when one directed the telescope to one side of them.

This weak functional activity of the macula lutea was explained as depending on slow adaptation, but investigation has shown that even after several hours' rest in a dark room, the light sense of the retinal center still remains the less, that of the periphery the greater. Recently one investigator (Mueller-Lyer) has had the self-denial to keep his head stuck in a dark box for eight hours, and the reward for his endurance was the conviction that even then the retinal periphery remained more sensitive to light than the center.

The fact that the center of the retina is less sensitive to light than its periphery depends most probably on the histological structure of the retina itself. In the center of the retina there are only cones. Now, according to J. v. Kries, we have in the rods and cones two distinct apparatuses lying side by side, these differing not only anatomically but functionally. The rod apparatus can conduct only light sensations, but is so perfectly adapted for this purpose that it responds to light stimulations which have no effect on the cone apparatus. The consequence is that the rod apparatus plays its principal part in weak illumination, and is therefore most completely developed in animals that seek their food at night, like the mouse, bats, cats, moles, and owls. Conversely the cone apparatus is capable of responding both to light and color sensations, but a stronger stimulation is needed for it; for this reason the eye perceives the outer world with the cone apparatus when the illumination is strong, and it appears in all its colors; when the illumination is weak the world is perceived with the rod apparatus and appears colorless, although light waves of various lengths are still sent into the eye.

Quite different results are obtained, as Treitel says, if light perception is measured in daylight by the sense of contrast in the retina. There is in this case a steady decline, as in visual acuity, in passing from the macula lutea toward the periphery. But the suspicion arises that in thus measuring light perception some part must always be played by visual acuity. Light perception seems then to have a certain dependence on vision, rising and falling with it. The sense of stimulation of the retina can be estimated quite independently of vision.

The color sense decreases with visual acuity from the center to the periphery of the retina. This decrease is so sharp that the

Digitized by the College of Physicians

color of a green card *1 cm.* square at *35 cm.* distance is no longer recognized as green if the image falls 30° to the temporal side of the macula lutea. The statement is, therefore, often heard that the periphery of the retina is color blind; the green blind zone is the largest, beginning 30° or 20° from the fovea centralis; the red blind zone is narrower; while the smallest and nearest to the edge of the retina are the yellow and blue zones. All this is true, however, only when it is taken for granted that the test object is of definite size, distance, and strength of light and color. If there is an increase in the visual angle at which the test object is seen, or if the strength of its light and color is increased, or if both conditions are present, then the color-blind zone narrows. Many observers claim that the extreme edge of the retina is sensitive to color if the stimulation is strong enough and the illuminated retinal area large enough.

For the ophthalmologist's purpose the chief question concerns the size, boundaries, and possible localized defects of the field of vision.

The field of vision *of an eye is that portion of space from which an eye at rest can receive impressions of light.* A diagram of this portion of space may be projected upon any desired spherical surface described about the nodal point of the eye. The extent of the field of vision is modified on the one hand by the anatomical structure of the bulb, on the other hand by the surroundings of the eye itself.

In regard to the former point, the size of the pupil is first thought of. Investigation has shown that with a wide pupil the field of vision is somewhat (about 2°) larger than with a narrow pupil, other conditions being equal; this is easy to understand. It is less easy to understand that the field of vision becomes larger when the surface of the iris advances, for instance, during accommodation for a near object. This advance of the iris is, however, connected with a contraction of the pupil that reduces the field of vision. Furthermore, the extent of the retina must be considered. In myopia it happens the luminous rays entering very obliquely reach the fundus, but are not perceived; in this case the border of the field of vision would not be defined by the obliquity of the ray as it enters the eye, but would depend on how far the retina extends toward the front of the bulb.

Finally, it must be borne in mind that the fovea centralis does not

lie exactly at the center of the retina but somewhat to the temporal side of it. Reckoned from the fovea centralis, the nasal side of the retina is larger than the temporal side; consequently the field of vision from the point of fixation extends more toward the temporal side than it does toward the nasal side; for, as will be explained later in detail, the temporal side of the field of vision refers to the nasal side of the retina, and *vice versa*.

The eye's surroundings may take up part of the field of vision. A prominent nose or a protruding arch of the temporal bone may usurp the field of vision; indeed, deep-set eyes may be affected by the maxillary part of the socket. Such modifications may appear as limitations when the field of vision is measured, and care must therefore be exercised to avoid confusion on that score. If the glance is outward, the nose may have no influence upon the field. A droop of the upper lid will effect a noticeable reduction in the extent of it above.

Measurements of the field of vision are generally made by Foerster's perimeter [1] or one of its modifications. Originally this was arranged as follows (*Fig. 19*): On a standard is fixed a pillar, *a*, at whose upper end the lower edge of the orbit is leaned. If the right eye is to be examined, the chin is rested against an arm at the left, *b;* if the left eye, on an arm at the right; this arm is adjustable, since the distance of the chin from the eye differs in different persons. To keep the eye at rest the patient is told to fix a point on a level with the eye fastened at about *35 cm.* distance on another pillar, *c*. This fixation point is at the same time the axis about which is turned the arc of a circle, *d d*, divided into degrees. This arc has a diameter of about *35 cm.*, its middle point lying above the pillar, *a*, at the nodal point of the eye. If this arc is revolved about the horizontal axis, identical in this case with the visual line of the eye, it describes a spherical surface about the nodal point of the eye. On this arc is adjusted a movable square disk, white or colored, and the patient is requested to tell without moving his eye when the disk is visible and when invisible. This test is repeated at various positions of the arc, which can be read off on a scale, *s*, at its axis; the disk can in turn be placed at every part of the field

[1] Aubert was the first to use an instrument for measuring the visual field; this was later perfected by Foerster, who called it a perimeter and introduced it into ophthalmic practice. Foerster's perimeter has had innumerable modifications, the latest being the so-called "self-registering," which diagrams the field as it is marked out.

Digitized by the Internet Archive in 2007

of vision. As a rule, however, it is sufficient to place the arc in only a few positions, say the horizontal, the perpendicular, and four to six oblique ones. The result of each trial of a new position of the arc, that is, the areas where the disk is or is not visible, is entered on a diagram such as is shown in *Fig. 20*.

This diagram of the field of vision represents the spherical surface described by the arc of the perimeter about the nodal point of

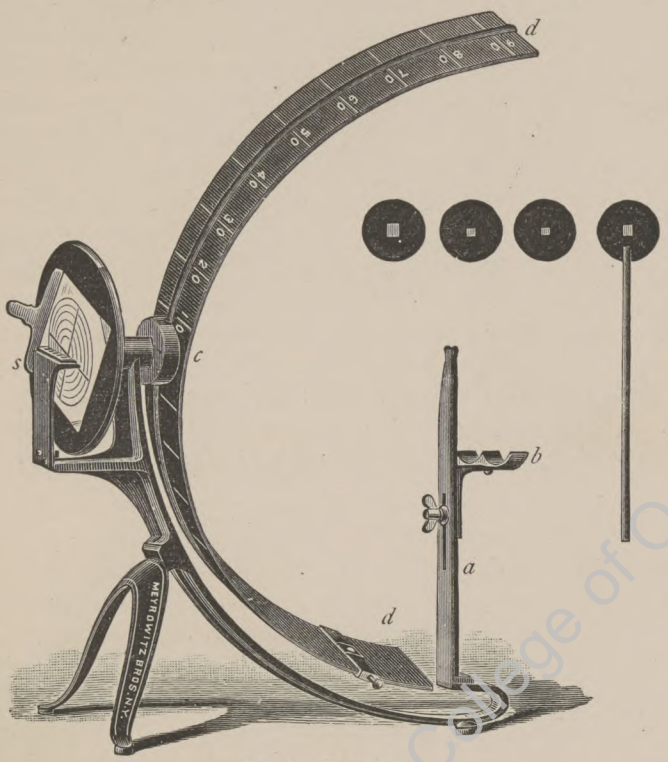

FIG. 19.—PERIMETER.

the eye. Around *F* are nine circles marked *10*, *20*, *30*, to *90*, corresponding to the parallels of latitude of a sphere. The middle point, *F*, of the diagram is the intersection of the lines marked *0*, *20*, *40*, *60*, *80*, *to 360*, corresponding to parallels of longitude. By means of circles in the one case and the diameters of circles in the other, it is possible to register any point designated on the arc of the perimeter.

Digitized by Illinois College of Optometry

In *Fig. 20* are shown the outlines of the normal field of vision of the right eye, no allowance being made for the nose or upper lid. As we see, the field extends *90°* toward the temporal side, and

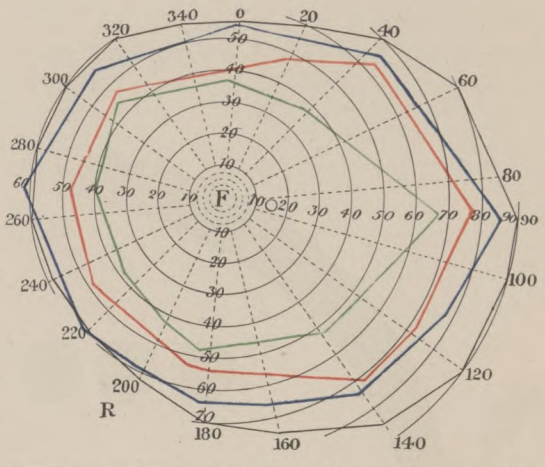

FIG. 20.—NORMAL FIELD OF VISION OF THE RIGHT EYE FOR WHITE AND THREE COLORS.

only *60°* toward the nasal side; *55°* upward and *70°* downward. By combining this right visual field with a corresponding left visual field, we get such a result as is shown in *Fig. 21*, repre-

FIG. 21.—COMPLETE FIELD OF VISION FOR THE TWO EYES (*b*Lue is the field for the left eye, *R*ed for the right).

senting the total field of vision for the two eyes. The *R*ed line indicates the field for the *R*ight eye, the b*L*ue that for the *L*eft eye. The total surface circumscribed by the red and blue lines is the

Digitized by Illinois College of Optometry

complete field of vision; but in each separate area is a small portion belonging to one eye alone, the right portion to the right eye, the left to the left eye.

At the temporal side of the fixation point (*Fig. 20*), between *10* and *20*, a small circle is shown in the diagram. This corresponds to the place of entrance of the optic nerve; as it has no retinal elements and as the nerve fibers alone are not sensitive to light, this appears in the field as the physiological dark spot, *scotoma*, Mariotte's or the *blind spot*. There are other but smaller blind areas in the visual field which probably correspond to points of division in the retinal vessels.

In practising measurements of the field of vision, one must struggle with the difficulty of overcoming the tendency shown by ignorant patients to look at the test disk as soon as their attention is directed to it. As this would destroy all accuracy, it is necessary to keep a constant watch over the patient's eye, and in order to do this it is best to sit opposite the patient, so as at once to repeat any measurement in case the eye has moved at all from the fixation point.

It is also difficult to give the disk an equal illumination at every position. If the patient sits with his back toward the window, sometimes the disk passes into the shadow of his head, and sometimes the light from the window falls on it, not directly, but obliquely.

It must be further mentioned that the field of vision is rather larger if the disk is moved from the center to the periphery until it disappears, than if it is moved in the opposite direction. One eye must, of course, be closed while the other is being examined.

By means of this method of examination we obtain diagrams of visual field that are in some diseases diagnostic. A field narrowed concentrically is a sign of one disease, a round scotoma of another, a segment scotoma of a third, and so on, as will be illustrated later.

Ordinarily, the field for white is taken, but it is often of interest to discover any possible defects in the color fields; in doing this we use a red, a green, a yellow, or a blue disk at the end of the arc, and ask the patient to tell when he sees the color as it approaches the fixation point. The normal fields for color are given in *Fig. 20*. This diagram shows the outlines for color in Aubert's right eye, a soft colored paper of *64 sq. mm.* on a black

Digitized by University of Illinois College of Optometry

ground in the daylight at *20 cm.* distance from the eye being used as a test object. The color of larger test objects, as, for example, a red disk of *32 mm.* square, or *1024 sq. mm.* in area, or a blue one of *16 mm.* square, or *256 sq. mm.*, would be detected at the extreme edge of the visual field.

It is possible to select shades and tints of red and green disks in such a way that the red and green fields are alike; the same is true for properly selected blue and yellow fields.

V. BINOCULAR VISION AND SQUINT.

1. PROJECTION OF RETINAL IMAGES.

Any object in space looked at by a healthy eye forms a dioptric image at the fovea centralis of each eye. These images are perceived, but the cause of the perception is to be ascribed not to the

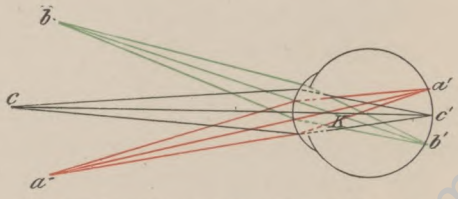

FIG. 22.—PROJECTION OF THE IMAGE IN ONE EYE.

place of sensation, the retina, but to the outer world, and the sensation of each eye is projected to the same place; both sensations are fused so that one single image is perceived. This fact is as easy, or, if you please, as hard, to explain as is the fact that an object felt with two fingers is perceived as one. It must never be forgotten that our senses are but the raw material from which, by means of personal and inherited experience, conceptions of objects in the outer world are formed.

An image is formed, however, not only of the object looked at, but also simultaneously of every other object that appears in the same field of vision. Are the retinal images of objects not looked at also fused into one? Let us examine the case of monocular vision. The point looked at, *c* (*Fig. 22*), forms its retinal image at *c'*, the points *a* and *b* their images at *a'* and *b'*. The projection takes place exactly in the path of the rays of direction; consequently, *c'* is projected to *c*, *a'* to *a*, and *b'* to *b*, or in general: *the*

Digitized by Illinois College of Optometry

projection of monocular vision is outward on the line connecting image and nodal point. This proposition can be demonstrated by the following experiment: shut one eye and place a prism before the other; try now to grasp a finger or any object placed in front of it; the effort will always be made to one side, toward the left if the base of the prism is toward the right; too high if the base is below, and so forth.

Fig. 23 explains this condition. If the prism were not introduced into the path of the rays, the point *c* would be imaged as in *Fig. 22* at the fovea centralis at *f;* but in passing through the prism the rays are diverted so that the retinal image is misplaced below to *c'*. When *c'* is connected with the nodal point *k*, and this line is extended outward, *c''* results as the apparent position of the object *c*. Even if the eye behind the prism is revolved so as to bring the image *c'* at the fovea centralis, *f*, the same error would be made in outward projection, for after the movement of the eyeball, which would bring the point *f* to *c''*, where the position of the image of *c* is, the connecting line between the fovea centralis and the nodal point would still give the same result as in *Fig. 23*, *c' k c''*.

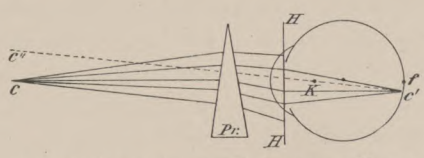

FIG. 23.—FALSE PROJECTION THROUGH A PRISM.

In the projection of the retinal images there must also be considered the impression that is formed of the position of one's eyeball, irrespective of the correctness or falsity of this impression. There is very plain evidence of this in some diseases of the eye muscles. If, for example, that muscle which turns the right eye toward the temple is paralyzed, and if the patient attempts to grasp an object at his right when his left eye is closed, he always goes to the side and to the right of it. In consequence of the paralysis of the external oblique the patient makes a disproportionate effort to look at an object by turning the eye toward the right, and as a result his estimation falls too far to the right of a line connecting the retinal images and the nodal point. This is obviously the case not only for the point looked at, but also for everything else within the visual field. Therefore we speak of "false projection in the visual field."

Retinal images are projected not only in certain directions but also to definite distances. For this distance of the projected image there seems to be some feeling of measurement in that effort which

must be made to adjust the eye for looking at it (that is to say, the convergence connected with accommodation in any eye). However, one can very easily convince oneself that even those objects lying beyond the far point are estimated at their proper distance in monocular vision. This, of course, is possible for us only in the case of well-known objects. The church tower at home, for example, produces on the retina of the observer an image that becomes greater as he approaches it. From the size of this retinal image the observer estimates very well the distance of the church. But if an altogether unknown test object is selected, and if in addition care is taken to exclude from the field of vision well-known objects that might serve as a comparison, then estimations of distances without the associated adjustment necessary will be inexact or impossible.

We can therefore conclude that the projection of the retinal images, even of one eye, is a very complicated mental process, in which the location of the optical images on the retina, the subjective conception of the eye's position and accommodation, and finally our knowledge of the object seen, all play an important part.

Still more complicated is the case in binocular vision. Look at a distant object, say test letters hanging on the wall opposite, and place a pencil in the direction of vision: the pencil now appears double, and these false images now appear in a false position. If one eye is covered, one of the false images disappears and the other apparently jumps into the correct position. The above rule concerning projection in monocular vision is, therefore, not quite applicable in binocular vision, since the left eye may cause the right one to err, and *vice versa*. This misleading influence of the covered eye upon the uncovered one may be demonstrated even in monocular vision.[1]

The examination of the conditions under which, in binocular vision, only one object is seen, has brought to light the following facts:—

(1) Images of a particular object formed on both foveæ centrales become fused into only one visual perception; the foveæ centrales are therefore cover or "identical points of the retina."

(2) Any other object is seen as one when each of the images it forms upon the retina lies an equal number of degrees above, below,

[1] Helmholtz, "Physiologische Optik," 1st Edition, *p. 612.*

Digitized by Illinois College of Optometry

to the right, or to the left of its fovea centralis. That point in the right eye, then, which lies on the horizontal meridian 10° toward the right, that is, at the temporal side of the fovea centralis, is identical with a retinal point in the left eye which lies 10° horizontally toward the right, that is, at the nasal side of its fovea centralis. The easiest way to get an idea of these "identical points" on the retina is to imagine both eyeballs fused into one, so that the fovea centralis of one eye and the perpendicular meridian passing through it fall on the fovea centralis and the perpendicular meridian of the other eye, when all "identical points" of the retinæ will lie together.[1]

In some positions of the eye it is easy to determine those points in space which are referred to the identical points of the two retinæ. When vision is directed toward infinity all points in space at infinity naturally become identical, since rays of direction for the right and left eyes are parallel and in both eyes lead to points lying equally distant and in the same direction from the foveæ centrales. As a matter of fact, the distance between the eyes is so small that anything beyond *50 m.* can be considered as infinity.

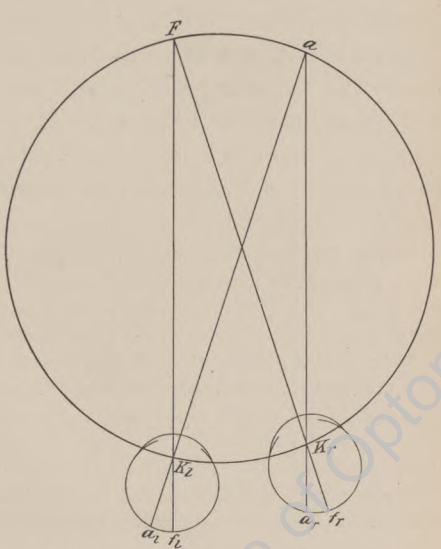

FIG. 24.—MUELLER'S HOROPTER CIRCLE.

In the case, too, when the two eyes look at a point lying on the same horizontal plane but at a finite distance, it is easy to determine the **horopter.** *The horopter is the geometric figure drawn through all points in space which are imaged at identical points on the retinæ.* In a horizontal plane[2] the horopter describes a circle which is drawn through the point of fixation, F, and the nodal points of both eyes, K_l and K_r, "Mueller's horopter," *Fig. 24.* Each point

[1] The geometrical do not correspond exactly to the physiological points, but the difference is so slight that it may be neglected here.

[2] In the perpendicular plane there is also a horopter, but it need not be discussed here.

Digitized by Illinois College of Optometry

on this circle, a for example, forms images a_l and a_r at an equal number of degrees distance from the foveæ centrales, f_l and f_r.

Angle $a\ K_l\ F$ = angle $a\ K_r\ F$
being angles of the same arc $a\ F$ of the circle.
Angle $a\ K_l\ F$ = angle $f_l\ K_l\ a_l$
and angle $a\ K_l\ F$ = angle $f_r\ K_r\ a_r$;
therefore, angle $f_l\ K_l\ a_l$ = angle $f_r\ K_r\ a_r$.

For all other positions of the two eyes the matter is very complicated and has no immediate significance in this analysis.

From what has been said we see that in binocular vision some objects are perceived singly, others double, but that does not as yet give us a general rule for binocular projection. The most important fact in this connection is that projection is made as if from the "double eye" which was imaged as a fusion of the two eyes into one (*Fig. 25*). If, in this double eye, the retinal images of an object lie at one and the same spot, the object appears single; if the images lie at different spots, the object appears double.

Fig. 25 illustrates this. The red or right eye and the blue or left eye fix a point, a, which is imaged on the fovea centralis of the left eye, f_l, and of the right eye, f_r. In fusing these eyes into the red-blue eye, f_l and f_r lie together at f_d; a is seen single and projected correctly through K_d to its proper location.

Meanwhile, a point, b, within the horopter circle, $a\ K_l\ K_r$, is imaged in the left eye at b_l, in the right at b_r, and, therefore, further from its fovea centralis. If I now pick up the arc $f_l\ b_l$ and carry it to the double eye (to the right of f_d), and do likewise with the arc $f_r\ b_r$, I obtain in the double eye two distinct images of the point, b. Projected through the nodal point, K_d, they give the false images, B_r and B_l, lying to the left and right of the true object, that is, crossed or heteronymous; in other words, the false image of the right (red) eye lies to the left, and the false image of the left (blue) eye lies to the right.

Constructing the same diagram for the point, c, lying without the horopter circle, we get in the double eye the separate images, c_r and c_l, which are projected through the nodal point, K_d to γ_r and γ_l. The false image of the right eye lies to the right, that of the left to the left; the images are on the same side of the eye, homonymous.

Applying this construction (*Fig. 25*) to ophthalmic examination, there results the rule that *objects between the fixation point and the observer appear double and heteronymous* (*crossed*), *those beyond the fixation point appear double and homonymous;* or in other words: **in eyes converging more than is necessary for monocular fixation an object produces double and homonymous images, in eyes not converging enough or in eyes diverging an object produces double and heteronymous (crossed) images.**

This proposition forms the groundwork for the study of squint,

Digitized by Harvard College Library

and must be for the ophthalmologist as much a matter of memory as is for the mathematician his twice one is two.

Just one word more concerning the fact that we are not continually annoyed by double images of objects seen at one side, a confusion possible from the above explanation. We have a great abhorrence of double images. We avoid them even by turning the

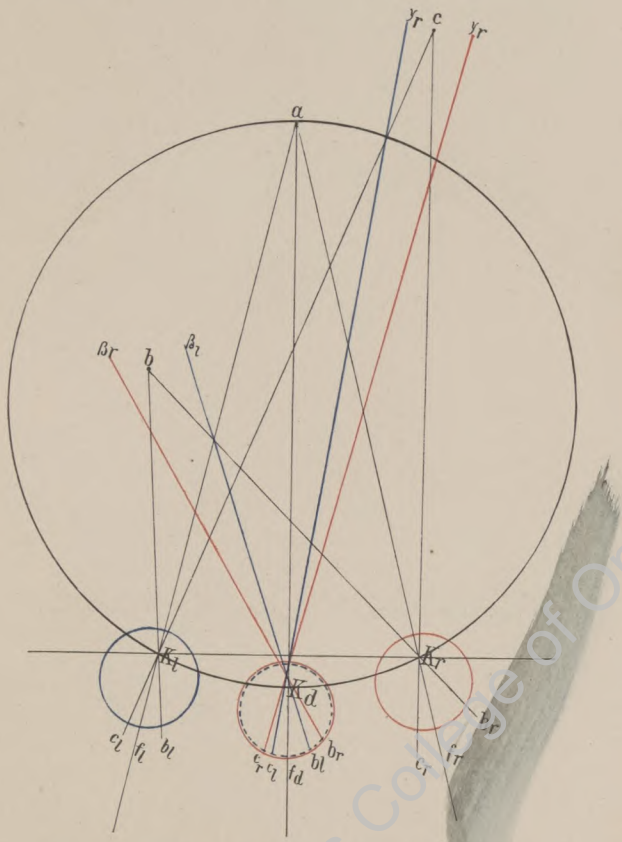

FIG. 25.—PROJECTION OF RETINAL IMAGES. (*After Martini.*)

eyes into an uncomfortable position. But this process is not applicable to the double vision just mentioned. We therefore avoid double images by the simple act of "exclusion" of one or the other of them. This neglect is a mental process not yet quite explained, the force of which can be appreciated when we consider that many persons are unable to see even physiological double images.

Digitized by Illinois College of Optometry

2. EYE MOVEMENTS.

It has just been explained that both visual lines must cross at the fixation point if it is to be seen directly and single. In order to satisfy this condition in the various locations and distances of any fixation point the eyes must be movable. Since the eye, disregarding the shape of the cornea, is a sphere, and since displacements of the whole sphere are excluded, we need consider only movements of the sphere about its middle point.[1] The movements geometrically possible about every straight line passing through the middle point and considered as the axis of rotation, are only in part performed. These movements are accomplished by means of the four rectus and the two oblique muscles: the rectus exter-

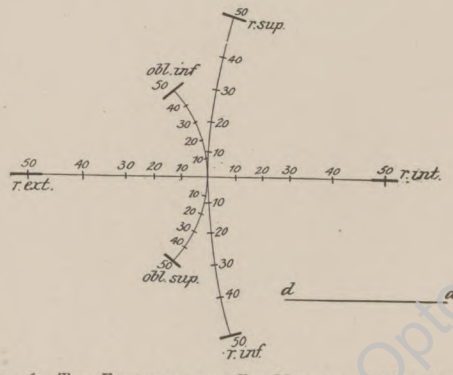

FIG. 26.—THE EFFECT OF THE EYE-MUSCLES. (*After Hering.*)

nus, internus, superior, and inferior; the obliquus superior and inferior. The action of each muscle, supposing it to act by itself, can be illustrated as follows: let an eye look at a point exactly opposite on a perpendicular wall; if now one of the eye muscles contracts, the eye is moved and looks at another point; the visual line therefore describes on the wall a tracing diagrammatic of the effect of this muscle. *Fig. 26* shows this diagram when the rotation point of the eye is distant from the surface of the paper the length of the line *d d*. The numerals placed along these lines indi-

[1] In reality, the point of rotation is not at the center of the eye but at a point lying *1.29 mm.* back of it. This is true for the emmetropic eye; in the ametropic eye the condition is somewhat different. For practical purposes we may consider the eye as a sphere and its center the point of rotation.

Digitized by Illinois College of Optometry

cate in degrees the angle through which the eye has moved when it looks at the point indicated by the number.

The effect of the internal and of the external rectus is easy to describe, both muscles simply carrying the visual line horizontally inward or outward. It is more complicated in the case of the four other muscles. The line belonging to the superior rectus passes upward and in a gentle curve inward. The oblique mark at the end of this tracing indicates that simultaneously a rotation of the eyeball takes place about the visual line, "circular rotation," and the position which the previously horizontal meridian assumes in consequence of this circular rotation. The effect of the inferior rectus corresponds to it; it rotates the eye strongly downward, a little inward, and causes a circular rotation in the opposite sense to that of the superior rectus. And, finally, the oblique muscles: The inferior oblique turns the eye upward, strongly outward, and rotates it in a powerful degree in the opposite direction to that of the superior rectus. The superior oblique turns the eye downward and outward with a rotation opposite to that of the inferior rectus.

In *Fig. 26* it will be observed that an absolute elevation of the visual line is not effected by the superior rectus alone. The inferior oblique takes part in this result, for the factors of movement outward and inward are thus neutralized, and there remains only the upward movement of the eye. In the same way an absolute depression of the visual line is effected by the combined action of the inferior rectus and the superior oblique.

The effects of muscular action change essentially according to the position of the eye. In *Fig. 27* both eyes are in the *primary position*, that is, parallel, horizontal, and directed straight ahead.[1]

Suppose the right eye turned 39° outward (to the right), the superior rectus in this new position becomes a pure elevator, its function of circular rotation is lost, and when elevating the visual line from this new position the opposing circular rotation of the inferior oblique is not compensated for, and the elevation is consequently not absolute but connected with circular rotation to the right, the so-called positive rotation. The contrary is seen if the right eye is turned inward (to the left); now the circular rotation of the superior rectus is increased, its power of elevation diminished; since the rotatory factor of the other elevator, the inferior oblique, is at the same time lessened, the elevation of the right eye from this new position is connected with appreciable circular rotation to the left, the negative rotation.

[1] The exact definition of primary position is somewhat different, but the above is approximately correct and exact enough for our purpose.

Digitized by the College of Optometry

These changes in effect, in consequence of a changed position, are of great practical importance in the case of the oblique muscles and the inferior and superior recti, since the diagnosis of paralysis of individual muscles is often possible only by the application of our knowledge of these facts.

In the previous section it was shown that both eyes act as a single organ, so far as projection of retinal images is concerned. The same is true for eye movements. If a nervous impulse is given to elevate the left eye, the same impulse goes also to the rectus superior and inferior oblique of the right eye; or if an impulse to the internal rectus causes the left eye to glance to the right, an equal impulse

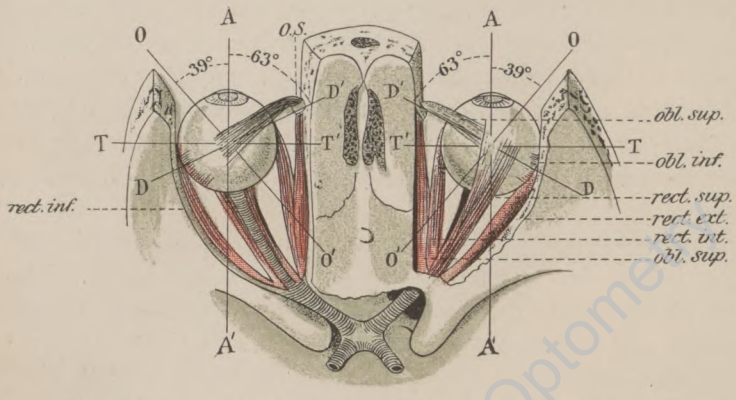

FIG. 27.—THE EYE-MUSCLES FROM ABOVE. (*According to Landolt; drawn by L. Schroeter.*)
A A′. Visual line. D D′. Axis of rotation for the superior and the inferior rectus. O O′. Axis of rotation for the oblique muscles. T T′. Axis for elevation and depression. The point of intersection of these axes is the point of rotation for the eye.

goes to the external rectus of the right eye, as these two muscles effect the same purpose in the two eyes. Finally, each eye must be capable of convergence and divergence to assume the position in *Fig. 25*, for example. The two interni in one case, the two externi in another case, act in harmony. Through the intricate nervous mechanism of the twelve eye muscles the eyes are capable of three kinds of movements and combinations of them:—

(1) Movement of the visual line in a horizontal plane—

(*a*) to the right { rectus internus of the left eye. / rectus externus of the right eye.

(*b*) to the left { rectus externus of the left eye. / rectus internus of the right eye.

Digitized by Illinois College of Optometry

(2) Elevation and depression of the visual line—
  (*a*) elevation, both rectus superior and obliquus inferior acting in common.
  (*b*) depression, both rectus inferior and obliquus superior acting in common.
(3) Convergence and divergence—
  (*a*) convergence, both recti interni acting together.
  (*b*) divergence, both recti externi acting together.

We make the most extensive use of these eye movements. Anything noticed to the side of us at once arouses our interest; involuntarily, often unwillingly, the eye is turned thither so as to bring the object opposite the fovea centralis. The rapidity and exactness of this movement is astonishing. As a rule, the head is turned at the same time, so that, as Ritzmann has estimated, a movement of *50°* toward an object is composed of *30°* of eye movement and *20°* of head movement. The attempt to look toward an object by moving the eyes alone can by many be accomplished only after several unsuccessful efforts.

The movements of convergence and divergence need particular mention. They are inseparably connected with movements of accommodation. For example, if two normal eyes look at a point ¼ *m.* away, an effort of accommodation is made in both eyes equivalent to *4.0 D*, and such a convergence of the eyes takes place that the visual lines cross on the fixation point, even if there is no need of this position, one eye being covered or useless, perhaps.

If both eyes look straight ahead and then at a point *1 m.* distant on the plane of the eyes and at the middle line of the body, each of the two visual lines describes an angle called by Nagel *meter-angle* (*MA*), which is chosen as the measure of that convergence of the visual lines. Expressed in degrees, a meter-angle shows a different value according as the distance of the eyes from each other is greater or smaller. The distance apart of the rotation points of the eyes is called the basal-line. A basal-line of *64 mm.* gives to a *MA* the value of *1° 50′*; of *54 mm.* the *MA* is *1° 32′ 45″*. The converging power of each eye in looking at a point is inversely proportional to the distance of this point. If the fixation point lies, for example, at ½ *m.*, the converging power of the eye is *2 MA*; if it lies at ⅓ *m.*, the converging power is *3 MA*, and so forth.

The connection between accommodation and convergence, when binocular fusion is concerned, is quite elastic. If an emmetrope reads fine print ¼ *m.* off, each eye is capable of accommodation of *4.0 D* and a convergence of *4 MA*. The eyes are, however, capable of seeing at ¼ *m.* distance with both convex and concave lenses, that is, they are able to do without accommodation

(with convex lenses), or of intensifying it (with concave lenses), although convergence of the visual axes (to *4 MA*) remains unchanged. The interval within which this is possible is called *relative range of accommodation*, that is, the range of accommodation available when the eyes are in a definite position. This relative range of accommodation owes its practical importance to the fact that the eyes can, without discomfort, be adjusted much longer for distances at which the positive part of the relative range of accommodation is large in comparison to the negative part. The greatest possible increase in refractive power (measured by a concave lens) with unchanged convergence is called the positive part of the relative range of accommodation; the amount measured by a convex lens is called the negative part.

In case the eyes are directed to the far point, there can logically be no negative part present; in case they converge to the near point, no positive part is present.

Within the near point for binocular vision accommodation is very slight, though convergence is still possible, but the accord between accommodation and convergence ceases. Accommodation is still possible, but it is effected only by means of a convergence to a point nearer than that accommodated for. *Fig. 28* illustrates this, showing at the same time the condition of relative range of accommodation in a normal eye. The abscissæ denote degrees of convergence expressed in meter angles. The ordinates denote the power of accommodation expressed in diopters. The points of the diagonal, *DD*, represent the different powers of accommodation normally belonging to the different degrees of convergence given in the proper abscissæ. The line *p p' p''* represents the relative near points, the line *r r' r''* the relative far points. The distance apart of any two points on a perpendicular plane of the curves *p p' p''* and *r r' r''* is the relative range of accommodation for the degree of convergence designated by the abscissæ; *p'* is the near point for binocular vision, *p''* the absolute near point. This is attained only with a convergence of *18 MA*, although accommodation amounts to only *10.0 D*. The relative range of accommodation at the absolute near point is *0*.

Of course, the measure of the relative range of accommodation varies considerably in different persons according to the use to which they put their eyes.

If accommodation can be exercised to a certain degree with unchanged convergence, then convergence can logically take place without accommodation. The extent to which convergence can be increased or decreased with unchanged accommodation is called the *range of fusion*. The term refers to the circumstance that movements of convergence and divergence are made in the interest of fusion, that is, of fusing two retinal images into one mental perception.

Digitized by Illinois College of Optometry

Fig. 28, illustrating the relative range of accommodation, serves also to illustrate the range of fusion. Let us look, for example, at the ordinate marked *6.0 D* and the line through it parallel to the abscissa; we notice that this parallel cuts the near point curve, *p p' p''*, at *p*, the far point curve, *r r' r''*, at *r'*. In other words, the abscissæ belonging to the interval *p r'* express in meter angles all those degrees of convergence connected with an effort at accommodation of *6.0 D;* the abscissa of the point p = 2.2 MA, that of the point r' = 10 MA; the range of fusion for an accommodation of 6.0 D is, therefore, 10. — 2.2 = 7.8 MA, the negative interval being 6.0 — 2.2 = 3.8 MA, and the positive interval being 10 — 6 = 4 MA.

The correctness of this can be proved by experiment. A man with normal vision can, in this case, still accomplish binocular fusion even if he looks through a prism. On account of the deflec-

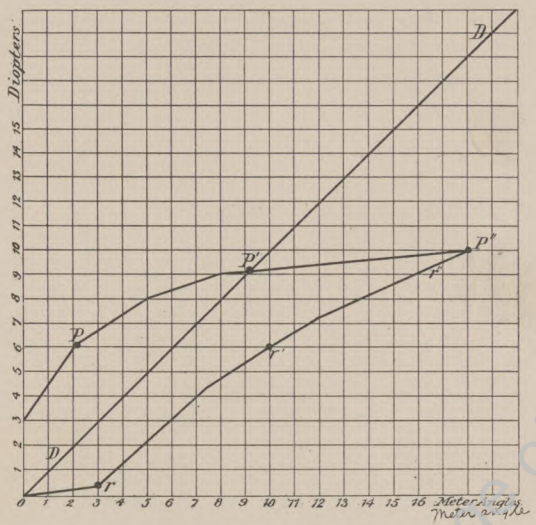

FIG. 28.—RELATION BETWEEN ACCOMMODATION AND CONVERGENCE. (*After Donders.*)

tion given to the rays by a prism, one eye must turn behind the prism in order to image on its fovea centralis the object looked at by the other eye. This turning behind the prism is the same as an increase in convergence in case the prism is placed with base toward the temple, the so-called "*position of adduction*," or it is a decrease of convergence when the base is toward the nose, the so-called "*position of abduction*." The close connection between relative range of accommodation and relative range of fusion finds also a practical expression in the fact that one's eyes can be continuously used without discomfort only for such distances as

Digitized by Illinois College of Optometry

leave quite an appreciable interval in which to apply the relative range of fusion.

We can speak also of an absolute range of fusion indicating the absolute play of convergence without reference to any condition accommodation. This, too, has a negative and a positive interval. The negative interval, that is, the possible divergence, is measured by the strongest prism in the position of abduction through which a person with normal vision can still, when looking at infinity, accomplish binocular fusion; on the average this is a prism of 5°, corresponding to a real divergence of 2.5° in the visual lines. The positive part of the absolute range of fusion is decidedly greater;

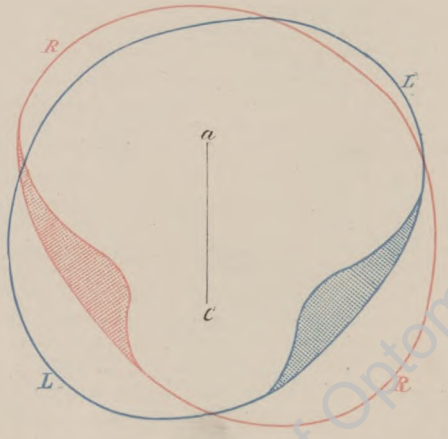

FIG. 29.—FIELD OF EXCURSION. (*According to Helmholtz.*)
(b*L*ue for the *L*eft eye, *R*ed for the *R*ight eye.)

in the case represented in *Fig. 28*, for example, this was equal to *18 MA* or *33*° of adduction for each of the two eyes (when *1* meter-angle = *1*°.*50'*). The absolute range of fusion is distinguished from the absolute range of accommodation by the fact that it is not influenced by age.

The impulse to binocular fusion is so strong that even prisms with their bases above or below can be overcome through a compensating movement of the eyes downward or upward, but the fusion interval in this direction is a very restricted one and has no practical significance.

The territory that we can cover by eye movements alone without moving the head is called the **field of excursion.** According

Digitized by Illinois College of Optometry

to Helmholtz, this excursional field of the eye extends upward and downward *45°*, to the right and left *50°*. Aubert and Foerster obtain somewhat different results, namely: upward *30°*, downward *57°*, inward *44°*, outward *38°*. The personal differences within physiological limits are obviously considerable and to a great part dependent upon exercise.

Fig. 29 gives an idea of the extent of this visual excursion for the two eyes, supposing them to be at the distance *a c* from the surface of the paper; the drawing and distance are therefore reduced in the same degree. The surface bounded by the blue line, *LL*, contains all points looked at by the left eye; the surface bounded by the red line, *RR*, all points looked at by the right eye. The area covered by both surfaces, *LL* and *RR*, represents the excursion of binocular vision; the two colored surfaces indicate the lapses caused by the prominence of the nose.

3. STRABISMUS (Squint).

In normal binocular vision the visual axes intersect at the fixation point. It sometimes happens, however, that only one eye fixes while the visual axis of the other misses the fixation point. This condition is called **strabismus** (squint). The angle made by the squinting or deflected axis with the line it would assume in normal vision is called the *angle of squint.*

Ordinarily the angle of squint is described as the angle between the actual position of the visual line and what ought to be the normal line in that particular case. By visual line is understood the line connecting the rotation point, *D*, and the fixation point, *F* (the *F* in *Fig. 30* is supposed to lie at infinity to the right). The visual line and the visual axis can, moreover, be considered as identical without appreciable error. In what follows, therefore, we shall cease to use the term visual line, for the determination of which a point in the outer world is needed, and confine our attention to the visual axis, which can always be determined by two points in the eye, the nodal point, *K*, and the fovea centralis, *f*.

The visual axis is the physiological axis of the eye. It does not coincide, as might be expected, with the anatomical or symmetrical axis, but lies more or less to one side of it. It is a rule that the physiological axis cuts the cornea at a point lying to the nasal side of the center of the cornea. The matter is still more complicated by the fact that the symmetrical axis of the eye does not exactly coincide with the symmetrical axis of the cornea, that is, with the longest diameter of the corneal ellipsoid. This last cuts the cornea somewhat more to the temporal side than the symmetrical axis of the eye (see *Fig. 30*). To this circumstance is to be ascribed the fact that an angle, α (alpha), is distinguished from an angle, γ (gamma). By alpha, α, is understood the angle between the physiolog-

ical axis of the eye and the long axis of the corneal ellipsoid. This definition has lost somewhat in market price, since it is now known that the cornea is by no means in every case curved as an ellipsoid. By gamma, γ, is understood the angle between the visual line and the symmetrical axis of the eye. Since the visual line and the visual axis are parallel to each other (if the fixation point lies at a distance), and since the deviation of the long axis of the corneal ellipsoid from the symmetrical axis of the eye may amount to several angular minutes, it is therefore quite permissible for all practical purposes to consider angle α and angle γ as indentical, that is, as the angle between the physiological and the anatomical axes.

On the average this angle amounts to $5°$, but can be larger or smaller, or even negative, that is, the physiological axis may, in an exceptional case, cut the cornea at the temporal side of its center. In emmetropia angle α (or angle γ) on the average $= 5°$, in hyperopia $= 6.5°$, in myopia $= 2°$ to $2.75°$.

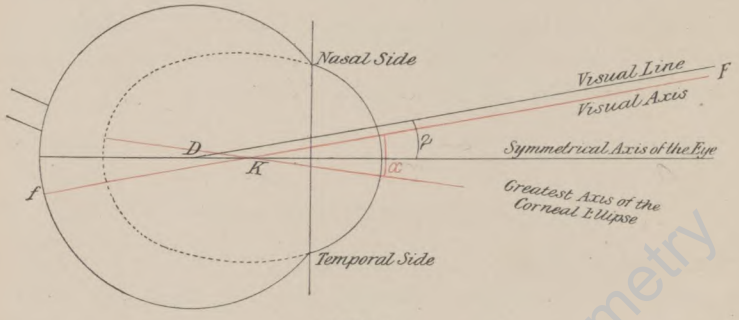

FIG. 30.

In order to give a better perception, the angles, α and γ, are drawn much larger than is really necessary.

The task of the examining physician is now a threefold one:—

(1) To prove the presence of squint;

(2) To demonstrate on what the squint depends, that is, what muscle is at fault and what is the diseased condition underlying it;

(3) To measure the extent of the squint (the angle of squint).

The first problem will often be solved by the patient himself or his relatives, if the squint is at all remarkable. The patient comes to the physician because his environment seems to him distorted. The laity generally distinguish two kinds, inward and outward squint, *strabismus convergens* and *strabismus divergens*. There are, however, numerous cases in which the squint is not demonstrable without particular investigation, either because the angle of squint is very small or because the squint is ordinarily suppressed for the sake of binocular vision. This last is called *latent squint*, to distinguish it from *manifest squint*. If the physician wishes to find out whether he has a case of squint, he proceeds as follows: The

Digitized by Illinois College of Optometry

physician, standing opposite, holds a finger in front of the patient and asks him to look at the end of it. If the patient does not squint, the visual axes of both eyes intersect at the finger in front of him, even if one eye is covered, the nervous association of accommodation and convergence providing for this (*p. 79*). If one eye and then the other be covered in turn, no movement is visible, since the covered eye is always properly adjusted. It is quite different in squint. At the request to look at the finger in front of him, the patient does so with only one eye. If now the fixing eye is suddenly covered, then the other—the deviating eye—makes a movement in order to bring an image of the finger on the fovea centralis. This movement of adjustment proves the presence of squint. Suppose the patient to be looking at the finger with both eyes open; if the physician now covers the left eye and notices that the right does not change its position, he concludes that the right eye was properly adjusted. The physician now covers the right eye and uncovers the left, and notices that the left eye makes a downward movement of adjustment; this proves that the left eye had deviated upward—that there was present in the left eye an upward squint (*Strabismus sursum vergens*). An upward movement of adjustment would have indicated a downward deviation of the left eye, a downward squint (*Strabismus deorsum vergens*).

A downward movement is, however, impossible unless the inferior rectus of the other (the right) eye contracts at the same time with equal force; that is, the right eye covered by the hand turns downward, and consequently itself assumes the position of squint with reference to the finger in front of it, the so-called secondary deviation. If the left eye is now covered and the right uncovered, the latter overcomes the secondary deviation by another movement of adjustment upward.

This method of investigation supposes the squinting eye to have sufficient acuity of vision to be able to fix the finger in front of it. If such is not the case, a small deviation of the visual axis is of no practical value, and a large deviation is apparent without the test just described.

The second problem, the investigation of the muscle at fault, must take into consideration the fact that squint can be caused, on the one hand, by a weak or a paralyzed muscle, and, on the other hand, by an over-powerful muscle.

(*a*) **Strabismus paralyticus.** Let us consider the first of the

above conditions. Suppose a muscle, for example the internal rectus of the left eye, to be paralyzed; then both eyes in looking straight ahead into space will probably have a correct position; but as soon as the patient looks to the right or attempts convergence, the left eye remains at a standstill and the right eye alone obeys the impulse from the brain; there results an absolute or a relative divergence of the visual axes. This squint, dependent on inaction of a muscle or group of muscles, is called the squint of paralysis, Strabismus paralyticus. From what is said above, we gather that when we suspect a squint from paralysis we must test the extent of movement in each eye separately. The test is a continuation of the finger-test just described. The physician tells the patient to follow the finger with his eye when he moves it horizontally toward the right and left. Under normal circumstances the eye should be able to follow the finger toward the temporal side until the external edge of the cornea reaches the external angle of the palpebral fissure, or toward the nose until the internal edge of the cornea dips under the lacrimal caruncle. If this is not possible, we assume that paralytic squint is present, especially if the examination of the other eye shows no lack of muscular activity; that is, we can be sure that the limited excursion of the one eye is not merely an apparent one dependent possibly upon an unusual size of the palpebral fissure.

If one internal or external rectus is found to be paralyzed the examination can end here; for to measure the angle of squint is in this case of no service, because it is inconstant in paralytic squint. Squint is not present at all in that territory for which the paralyzed muscle is not called into play, and increases in proportion as the eye endeavors to look toward the side of the paralyzed muscle. This is also true for the secondary deviation of the sound eye. It is greater the more the unsound eye exhausts itself in the effort to fix a point lying within the territory of the paralyzed muscle; it is altogether lacking if the unsound eye can fix a point without calling into play this paralyzed muscle.

The simplicity of the demonstration of a paralysis of a rectus internus or externus is due to the fact that a movement to the right and left is essentially dependent on these muscles alone. In elevation or depression of vision the relations are otherwise, as we know. Since elevation of the visual axis is carried out by means of the superior rectus and inferior oblique, inaction of one of these mus-

Digitized by Google Original from Columbia University

cles renders only absolute elevation impossible. In case the superior rectus of the left eye is paralyzed and that eye tries to look upward, it will appear to lag behind the other and at the same time will show a noticeable circular rotation. This kind of circular rotation should indicate, theoretically at least, which of the two muscles still functionates, but since the circular rotation is not pronounced, and consequently is not very easy to detect in a moving eye, some more sensitive test must be applied; fortunately, we have this in the "double image test." If the rule given on *p. 74* is inverted and generalized, we obtain the following important deduction that *the position of the two eyes can be determined from the position of the double images.*" The presence of homonymous double images proves that the visual axes converge to a point lying nearer than the object which appears double; and the presence of heteronymous (crossed) double images proves that the visual axes converge to a point lying beyond the object which appears double, this point being toward infinity either in the positive sense, in front of the eye, or in the negative sense, behind it. If the image of the right eye is lower than that of the left, the right eye must be directed upward, and so forth. A circular rotation of the eye will be betrayed by an oblique position of one of the two double images.

In this method of testing much depends on bringing a patient to a clear perception of the double images, usually an easy matter in the case of paralytic squint. This form generally attacks adults who have been accustomed for years to perceive the retinal images of both eyes, and who are therefore not able at once to neglect the image of one eye. The test is made by showing the patient, in rather neutral surroundings say, a dark room, a bright object (a candle is one of the best), held at a distance of *2* or *3 m.*[1]

To ascertain at once to which eye each image belongs, it is a good plan to place a red glass in front of the eye with the better vision; this eye sees, therefore, a darker red flame, the other sees a lighter yellow flame, and the difference in acuteness of vision is thus more easily compensated for.

If the double images are homonymous, the eyes converge, as has been said. This convergence may depend on paralysis of the right externus as well as on paralysis of the left externus. Which

[1] If the double images are very wide apart it is of advantage to bring the candle to about *1 m.* If they are near together, the reverse is true, and the test should be made at *4* to *6 m.*

Digitized by Illinois College of Optometry

of the two is paralyzed is shown when the candle is moved horizontally from right to left, or from left to right. If the candle is moved into the field reached only by the paralyzed muscle, the double images flit apart; if in the other direction, they flit together; but if they remain the same distance apart, the squint is not due to paralysis.

If one of the double images stands obliquely to the other and perpendicular one, we know—

(1) That the oblique image belongs to the paralyzed eye;[1]

(2) That a superior or inferior rectus or a superior or inferior oblique must be at fault,[2] for only these four muscles are concerned in circular rotation.

There are other signs which distinguish a sound from an unsound eye. If the candle is moved in the direction of the paralyzed muscle, one of the double images appears to flit away from the other, the flitting image belonging to the unsound eye. The explanation is plain if we consider that when the candle is moved, its image in the sound and, as we assume, fixing eye always falls upon the fovea centralis, while the image in the unsound eye, either totally or in part unable to continue its fixation, passes across the retina. This test can be a deceptive one, either because the patient does not observe carefully enough to tell which of the double images appears to move, or because he is accustomed to fix with the paralyzed eye. In this case we must make use of the position of the double images to find out which eye is unsound, since that is the unsound eye in which the image is nearest to the edge of the visual field,—that is, the furthest left, if the left half of the field is tested; the furthest upward, if the glance is directed upward, etc. Let us take an example: Suppose a muscle on the left side is paralyzed, the externus of the left eye; then in looking toward the left there must be convergence, homonymous images, and the image of the left (the unsound) eye must be the further toward the left. Suppose the right internus is paralyzed; then in looking toward the left there must be divergence and heteronymous images; in this case also the image further to the left belongs to the unsound eye, this time the right one.

[1] Exceptions are not unusual and will be explained later.

[2] There are exceptions here also. If the patient looks obliquely, *e. g.*, upward to the right, or downward to the left, etc., there is a moderate obliquity, even if only an externus or an internus is paralyzed.

Digitized by Harvard College Library

(*b*) **Strabismus concomitans.** It has been said that squint may be due to the action of a too strong or of a too weak muscle. In cases of this kind the visual field of the squinting eye is not reduced but remains unchanged or displaced. For example, in inward squint due to a too strong internus, the eye cannot be turned so far outward as it would be normally, but the adductive power of this eye is increased by a certain amount, so that the total area covered appears about normal horizontally. Squint with normal or only displaced field is called concomitant or muscular, Strabismus concomitans.

If the first test (*p. 84*) proves that squint is present, and if the double image test (*p. 88*) proves that it is not due to paralysis, we can be sure that the squint is muscular or concomitant. To decide whether this is manifest or latent squint, we proceed as follows: The patient must fix the finger in front of him; now cover one eye. If the open eye is quiet while the covered eye makes a movement that is corrected as soon as it is again uncovered, there is obviously a latent squint, for if the movement of correction is made by the covered eye when the fixation point remains unchanged, the conclusion must be drawn that the eye squints when covered, in order to restore muscular equilibrium; when it is uncovered, however, it returns to the usual position for the sake of restoring single vision in the two eyes. It is worthy of note that many patients of this class do not perceive the double images, although they should appear at the instant the movement of correction is effected.

Since muscular squint is treated by operation, it is important to solve the third problem, that is, to measure the degree of squint. There are two methods used. One attempts to find a linear measure of the deviation and is applicable to manifest squint; the other measures by neutralizing prisms and is preferably applied to latent squint.

The linear measure is taken as follows: Suppose the case is of muscular, manifest, inward squint; let the patient fix the finger with the right eye; while the fixation is quietly maintained, make an ink mark on the under lid of the left eye exactly below the external edge of the cornea. Now cover the right eye; then the left eye, which has hitherto deviated inward, makes a movement of correction outward, and as it continues to look at the finger, held, of course, in the same place, make a second mark on the lower lid

Digitized by Illinois College of Optometry

also exactly under the external edge of the cornea. The distance of these two points from each other measures the amount of squint present; we call a squint, therefore, one of *3* or of *6 mm.*, etc. This measurement can also in the same way be applied to the other non-squinting eye; in doing this we measure the secondary deviation of the sound eye, which in muscular squint is just as great as in the primary deviation of the squinting eye.

A somewhat purer and more accurate result can be obtained by measuring the squint with the Laurence strabometer, *Fig. 31.* This is held under the squinting eye, and the line in the millimeter scale lying exactly below the external corneal edge is noticed; then the squinting eye is made to fix, thus inducing the external edge to lie above another line in the scale; the distance between these two lines can then be read off and indicates in millimeters the degree of squint.

FIG. 31.—STRABOMETER.

A third method of measurement is that of Hirschberg. At about *35 cm.* hold a candle exactly in front of the patient's face, and while looking over the flame observe its reflections on the two corneæ. If the patient fixes with both eyes, an image of the flame is seen in each eye at the middle of the cornea, but if one eye deviates inward, the image in this eye lies outward from the middle of the cornea; if the image lies at the edge of the cornea, there is a squint of *6 mm.*, for half the width of the cornea is just *6 mm.*

It must be understood that all these methods give only approximate results, though they are sufficiently accurate for all practical purposes. To obtain greater exactness the angle of squint must itself be measured. For this purpose we need a perimeter, and the corneal image of the candle flame just mentioned. The squinting, that is, the left, eye is placed at the middle point of the perimetric arc, while the sound eye looks straight ahead at infinity. If no squint were present, the left eye would look exactly at the fixation point on the perimetric arc; but if there is a squint, we can, by advancing the flame along the arc until it is reflected exactly at the center of the cornea, find out that point of the circle toward which the eye is directed on account of its squint. The position of the flame is read off on the perimetric arc and gives immediately the angle of squint. In this method, as well as in that of Hirschberg, it is assumed that the visual axis passes exactly through the center of the cornea. This is not the case (see *Fig. 30, p. 84*). In both methods there is, therefore, a radical error which can occasionally exert a disturbing influence. Measurements made with the strabometer are free from this error.

In order to understand the method of measuring squint with neutralizing prisms, we must call to mind certain physical facts. In

Digitized by the Internet Archive of Optometry

a prism the angle opposite the base is called the refracting angle (α in *Fig. 32*). Its size determines the amount of deviation experienced by luminous rays in passing through a prism when the angle of entrance of the rays and the refractive index of the glass are given. For prisms of ordinary glass with a small refracting angle (α) the angle of deviation equals half the angle of refraction ($\beta = \frac{1}{2}\alpha$), assuming that the rays fall perpendicularly upon the side of the prism. Let us suppose that the left eye (*L*, *Fig. 33*) is looking straight ahead at a fixation point at infinity, and that the right eye deviates inward. The object fixed by the left eye will be imaged in the right eye to the inner side of the fovea centralis, f_r, say at *a*,

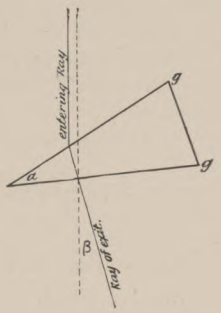

FIG. 32.—DEVIATION OF LUMINOUS RAYS THROUGH A PRISM.

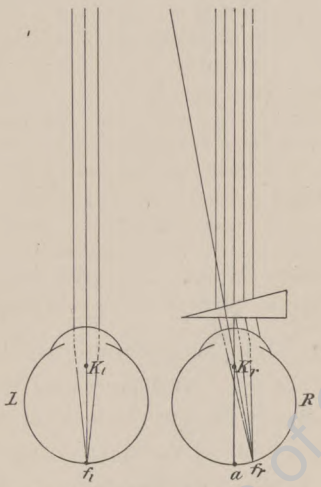

FIG. 33.—NEUTRALIZING THE SQUINT BY MEANS OF A PRISM.

and in the double eye (*Fig. 25, p. 75*) will be displaced toward the right. If now a suitable prism is placed with the edge inward in front of the right eye, then the luminous rays will be refracted toward the right, and will form an image at the fovea centralis, f_r. Consequently the eyes, in spite of the squint, will see this distant object as a single image. But, as can be seen in *Fig. 33*, the most suitable prism is the one in which the angle of deviation is equal to the angle $a\,K_r\,f_r$, obviously the angle of squint. We conclude, therefore, that within certain limits the position of squint is neutralized by a prism with a refracting angle double the squint angle.

The measure is taken as follows: After the diagnosis has shown

the presence of a muscular, latent squint, either upward, downward, outward, or inward, the physician places in front of one of the eyes prisms of increasing strength, the apex toward the direction of the deviation (*Fig. 33*). That prism with which the two eyes obtain normal vision, that is, the prism in looking through which there is no deviation when the eye is covered and no movement of correction when the eye is uncovered, is the neutralizing prism, and as such is a measure of the squint. This method is called A. Graefe's equilibrium test.

There is another equilibrium test introduced by Graefe the elder, the v. Graefe's equilibrium test. It is made as follows: A strong prism apex upward or downward is used to overcome single binocular vision. The person to be tested, since he cannot overcome such a strong prism in this position, sees double, and the double images stand one exactly above the other, if muscular equilibrium is maintained; if it is not maintained, the eyes will now assume either a convergent or a divergent position, since there is no necessity for a proper convergence to the fixation point. Consequently the double images are seen displaced not only perpendicularly but also horizontally. The amount of horizontal displacement can now be measured by a second prism. For this purpose prisms of increasing strength are held before one eye, with the apex toward the temple if the images are heteronymous (crossed) and toward the nose if homonymous, until the patient says that the images are again perpendicular one above the other. The prism giving this result measures the amount of horizontal displacement.

This test is not always trustworthy, because in many persons the displacement of the false images in a deviating eye is a very uncertain quantity.

[American ophthalmologists, led by Dr. Stevens, of New York, have developed and perfected the old v. Graefe equilibrium test, not so much for the purpose of detecting latent or dynamic squint, as in the hope of demonstrating some weakness in muscle balance which could cause many of the symptoms, like headache, eye-strain, and exhaustion, classed under the term "muscular asthenopia," in contradistinction to the analogous symptoms due to accommodative asthenopia. The test is conducted by prisms, the same principle applying here as in the method explained above.

The nomenclature also has been elaborated by American ophthalmologists, but is devised to illustrate the direction in which the visual lines tend, rather than the simple effect of the muscles themselves. It is assumed that in a normal person the visual lines of the two eyes are parallel, and that binocular single vision (fusion) results, when fixation takes place for objects at and beyond 6 *m.*; this condition is called *orthophoria*. Now, in certain states of the physical system,—bad health, irregularity of the orbit or of the insertion of a muscle, or when there is a refractive error,—this paral-

Digitized by the Internet Archive in 2010 with funding from Boston Medical Library in Cooperation with Countway

lelism may be lost, and one visual line will then be in a different relation to the other; this general deviation is called **heterophoria.** A tendency of one visual line outward is called *exophoria;* inward, *esophoria;* upward, *hyperphoria.* (Hypophoria is not used, for, although theoretically probable, the alternate position of the other eye, hyperphoria, is always treated.) Before testing, all refractive errors should be corrected; atropin may or may not be used. Elaborate apparatus has been devised by Stevens and others, but the prisms furnished in a good case of lenses suffice for establishing a diagnosis.

The patient is placed as for the examination of the visual acuity, but instead of letters a light (candle) at *6 m.* is used, which is to be fixed by the patient. I tis best to place a red disk before the right eye (unless this be very amblyopic), since the contrast aids the patient in making accurate statements. Now place before the left eye a prism of *5°* to *10°*, base downward. The eye is rarely able to overcome a vertical prism, and all effort at fusion being thus destroyed, the result is diplopia, the two images of the candle-flame not lying in the same horizontal plane in any case, and lying in the same vertical plane only when parallelism of the visual lines is maintained—orthophoria. The red image is correctly projected and belongs to the right eye. Suppose the other image lies above and to the side of the red image. Applying the rule of projection on *p. 74*, it is evident that if the white and upper image (left eye) lies to the right of the red image (heteronymous diplopia), the visual lines must tend away from each other—exophoria—and the condition is weakness of adduction in the interni. If the white image lies to the left of the red image (homonymous diplopia), the visual lines must tend toward each other—esophoria—and the condition is weakness of abduction in the externi. Now place prisms of varying strengths in front of the right eye, base in (abducting) for exophoria, base out (adducting) for esophoria, until just that prism is found which causes the two images to lie exactly in the same vertical plane; parallelism of the visual lines is restored, and the prism effecting this is said to measure the muscular inefficiency.[1]

[1] The expression "to measure" is incorrect, since there is no constant loss of muscle equilibrium. The action of muscles is always relative and inconstant, and the test shows only the tendency of the equilibrium to be lacking or excessive by so many degrees.

Digitized by the Ohio College of Optometry

The simplest test for hyperphoria is with the Maddox rod, which consists of a small glass cylinder in an opaque disk, made to fit a trial frame. (A very neat Maddox rod is now made of red glass, the cylindrical portion being cut out of the glass; the disk thus combines in one both red glass and rod.) This disk is placed in the trial frame, and if the rod is horizontal, the candle-flame will be changed into a vertical beam of light; if the rod is vertical, the beam of light will be horizontal. Suppose the rod is placed vertical; there are now two lights, the beam belonging to one eye, the natural light to the other. If the beam passes directly through the center of the flame (or if the flame lies at the center of the beam), there is no upward or downward deviation. If the two lights are not in the same horizontal plane, there is hyperphoria, the lower light belonging, of course, to the eye which has the greater tendency to deviate upward. By placing the rod horizontal, the vertical beam may discover exophoria or esophoria, but the absence of signs therefore does not imply orthophoria, since a latent tendency to deviation may have been so overcome in the interest of fusion that the beam passes through the flame. The term hyperesophoria—tendency upward and inward—expresses the condition of homonymous diplopia with the two images in different horizontal planes. Hyperexophoria expresses the condition of heteronymous diplopia with the images in different horizontal planes.

All these preceding deviations are assumed to depend upon lack of equilibrium between the recti muscles. A similar disparity between the obliqui may be unmasked, as some ophthalmologists claim, by Savage's test, in which a double prism of several degrees each is used, mounted with bases together, in a trial-frame disk. This is held with axes vertical before one eye, while the other eye is covered. The object of fixation is a horizontal line *50 cm.* The line is distorted so as to appear as two parallel lines. When the other eye is uncovered, it should see between these two a third line parallel to them. Any loss of balance between the oblique muscles is said to be indicated if this third line is not parallel. Suppose the double prism to be before the right eye; there is left hyperphoria if the middle line is nearer the bottom; there is exophoria if it is more to the right and less to the left; there is esophoria if it is more to the left and less to the right. There is said to be insufficiency of the left superior oblique if the right ends of the middle and lower lines converge; insufficiency of

Digitized by the Internet Archive in 2010

the left inferior oblique, if they diverge. By changing the double prism the right eye may be similarly tested.

As the last trial is conducted at a distance of *50 cm.*, it is well to repeat the preceding prism tests for equilibrium, at the same (near) distance, using instead of the candle a small white cross on a black ground. The results thus found may or may not coincide with those found at *6 m.* These examinations should be supplemented by testing in each eye the strength of the prism that can be overcome by adduction (base out), and by abduction (base in), before double vision occurs. Muscular power varies, of course, in different eyes and on different occasions, but adduction will be from *25°* to *50°*; abduction from *5°* to *10°*.—H.]

Digitized by Illinois College of Optometry

B. OBJECTIVE METHODS OF INVESTIGATION.

I. REFLECTION FROM THE CORNEA.—KERATOSCOPY.

The surface of the cornea, being a separating surface between two transparent media, air and cornea, is a mirror, and on account of its curve a convex mirror that reflects virtual images of luminous objects; these images are upright, diminished, and lie apparently behind the cornea; they are commonly but improperly called reflexes. The size of such a reflection (mirror image) depends upon the size of the object, its distance, and upon the curvature of the corneal surface. The further off the object and the smaller the radius of the cornea, the smaller is the image. The shape of this image depends upon whether or not the corneal surface is spherical; if it is so, then the image is geometrically identical; if the cornea is astigmatic, that is, asymmetrically curved in any meridian, the image is regularly distorted. Finally, the sharpness and clearness of the image is proportional to the smoothness of the cornea, and is affected by any depressions or elevations in it. In case there are any holes, fissures, or vesicles, the image is irregularly distorted and dim. We can, therefore, on the one hand, recognize by means of these corneal reflections any small roughness, excavation, or prominence, and, on the other, estimate from the size, length, and breadth of the image the variations in radii.

To study any roughness or unevenness in the corneal surface, the physician turns his back to the window and places the patient in front of him; he then sees the reduced image of the window and window bars reflected from the patient's cornea. The patient is now asked to look at a finger held in front of him; by moving the finger in various directions the eye is brought into various positions so that gradually the physician has seen the image of the window reflected from every portion of the corneal surface. In this way the whole cornea is tested, and as any roughness would be apparent to the finger, in the same way an unevenness of the corneal surface is betrayed by an irregularity in the reflected

Digitized by Illinois College of Optometry

image, and the smallest loss or unevenness of the epithelium can be recognized without difficulty.

The second step, finding the corneal curvature, is carried out by means of various instruments and for various purposes. In practice it is seldom of value to determine the actual dimension of the radius of curvature; but, on the other hand, it is doubly important to know whether and in what degree the cornea is meridionally asymmetric. For this purpose the keratoscope was devised, that of Wecker-Masselon being perhaps the most used (*Fig. 34*). It consists of a blackboard *18 cm.* square, bordered by a white stripe about *15 mm.* broad. There is a hole in the center to look through. It is held by a handle about which the board turns at its middle and in its own plane, the amount of this rotation being read from

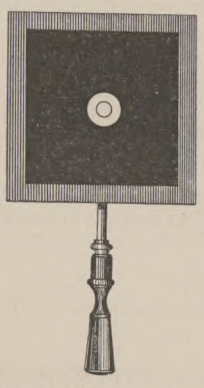

FIG. 34.—KERATOSCOPE OF WECKER-MASSELON.

FIG. 35.—SCALE FOR CORNEAL ASTIGMATISM.

a scale on the back of the board. The instrument is held about *20 cm.* in front of the eye. If the cornea is normal the reflected image of the white frame is a square, measuring on each side not quite $\frac{1}{3}$ of the corneal diameter, but if the cornea is meridionally asymmetrical the image of the frame loses its square shape; if the sides of the square frame are not parallel to the principal meridians of the cornea, the image is a rhomboid. By turning the board on its handle the white frame will finally take a position from which a rectangular image is reflected. When this position is found we have the direction of the principal meridians.

The instrument is handled as follows: The physician sits opposite the patient and adjusts the keratoscope so that the white square, illuminated from a window or a lamp, is imaged on the

Digitized by Illinois College of Optometry

cornea. The physician looks with one eye through the hole in the keratoscope at the eye of the patient, who is requested to look at the hole from his side of the instrument. If the image is rectangular it is compared with a series of ten rectangles printed on an accompanying card (*Fig. 35*) that illustrates the corneal images in astigmatic condition from *0* to *10.0* Diopters. The rectangle (the first one being a square) showing the closest resemblance to the corneal image may be taken as a measure of the corneal astigmatism present.

This Wecker-Masselon keratoscope can be had in a perfected form. If a square is reflected from an astigmatic cornea as a rectangle, then there must be some rectangle the image of which on this cornea will appear as a square. The square of the white frame may be changed by means of a screw adjustment into a parallelogram. This screw is turned until the image which first appears as a parallelogram is now reflected as a square, the change effected in the frame being the measure of the astigmatism present. In order to read in diopters without farther trouble the astigmatism thus found, the frame is arranged with an empirical scale and an indicator connected with the screw.

In many scientific problems it is of interest to determine the actual size of the cornea, that is, the radius of its curvature. This can be done by applying the following rule: If the distance of an object from a convex mirror is equal to infinity, the image lies at the (virtual) focus, that is, at one-half the radius ($\frac{1}{2}\ r$) behind the reflecting surface. When the corneal curve is sharp, objects at a few meters distance are images close to the focus, and the radius of the cornea may therefore be estimated by a simple proportion:—

If a, the size of the object,
b, its distance from the cornea, and
c, the size of the image, have been measured, we then have this ratio: $a : c = b : \frac{r}{2}$; consequently $r = 2\frac{cb}{a}$.

It is easy to measure a and b; while c can be measured by the Helmholtz or the more modern Javal-Schiotz ophthalmometer. This instrument and its use is explained in text-books of physiology or in exhaustive works on ophthalmology.

Many ophthalmologists use the ophthalmometer for purely practical purposes, especially for determining objectively the presence of astigmatism. I prefer to use the *Shadow Test*, *q. v.*

II. FOCAL OR OBLIQUE ILLUMINATION.

If two completely transparent media touch each other, a reflection of luminous rays occurs only at the surface of separation. But in case one of these media is not completely transparent, part of the rays will be reflected from within the medium itself, and the reflected rays will therefore be visible. For that reason corneal scars, on account of their opaqueness, appear as gray blotches. In many cases, however, there is so little light reflected that the lack of

Digitized by Illinois College of Optometry

transparency cannot be detected unless special methods are used. The method most suitable for these cases is a strong oblique illumination. By means of a lamp and a convex lens a very powerful light can be thrown upon the suspected area, and there are enough of the diffused rays returned to the observer to show him a gray spot which would be invisible with a weaker illumination. As the examination takes place in a dark room no other light falls upon the cornea except that from the lamp through the convex lens; there is, therefore, a strongly illuminated area on the cornea surrounded by an area of weaker illumination, this contrast favoring the recognition of any places from which the reflection is weak. And, finally, one's own eye can be aided by magnifying glasses, convex lenses of short focal distance being used for this purpose. The most desired magnification with a large field is obtained, however, only by lenses of special construction. The Hartnack spherical lens seems to me particularly commendable; it is small, handy, cheap, has a refractive strength of about 35 Diopters, and magnifies objects three to four dimensions.

More complete still, although dearer and less easy to handle, is the Zehender-Westien binocular lens, which magnifies objects tenfold and at the same time gives us stereoscopic vision. Aubert's binocular lens does the same thing.

To make this examination with oblique illumination we need a moderately dark room and such a source of light as is ordinarily furnished by a lamp or an adjustable gas bracket. The patient sits at ½ *m.* from the lamp, which is in front of him and a little to the left. The physician sits or stands in front of the patient and at his right. With one finger of his left hand he raises the upper lid of the eye under examination, holding the lens between his index finger and thumb. With the right hand he holds a convex lens of about *20* Diopters so as to throw an inverted reduced image of the flame exactly upon the surface of the cornea, bringing it, therefore, at the focus of the lens—hence the name, "*focal illumination.*"[1]

If the lens is approached to the eye the apex of the cone of rays falls upon different layers of the cornea. If the lens is moved upward, downward, to the right or to the left, any desired spot on the surface of the cornea can be illuminated focally. When the condition

[1] This is not exactly the proper term, for "focus" really means the focal point of an object lying on the axis at infinity.

of the cornea in all its parts has been investigated, the lens can be approached still closer to the eye in order to throw light into the aqueous, upon the iris, into the lens, and, if the pupil is wide enough, even into the vitreous.

Many diseased changes of the cornea stand out clearly by mediate illumination. For example, corneal blood-vessels lying in a faintly clouded cornea can be seen best if the iris behind these spots is illuminated. The luminous rays are thus reflected from the iris and penetrate the cornea from behind forward. In such manner small cell masses on the posterior surface of the cornea can be discovered, the so-called deposits on Descemet's membrane. If these are illuminated directly, their appearance will be obscured by the light thrown back from the corneal surface and from what cloudy areas there may be within the cornea; but they are seen with extraordinary clearness when illuminated from behind in the method just described.

In making use of oblique illumination we see certain phenomena of light in their physiological relations. These are, in part, images reflected from the three refracting surfaces of the eye, the cornea, anterior and posterior lens surfaces; and, in part, light diffusely reflected from the cornea and lens. The difference between these depends upon the fact that an area reflecting diffused light sends luminous rays in all directions, and they are thus visible to the observer irrespective of his relative position; while a mirror image sends out a definite cone of rays and is constantly visible to an observer only when his eye lies within its path. Another difference is this: Any part of the cornea or lens reflecting diffused light appears a delicate gray, or in some diseased conditions even white; while a mirror image, particularly that of the cornea, is quite bright—the very image of the yellow flame itself is seen. Whether the observer sees the images or is attracted more by the areas reflecting diffused light, depends somewhat upon the distance of the convex lens from the eye under examination. If, for example, the convex lens is so held that the image of the flame is focused in the air nearly in front of the cornea, no diffuse reflection is seen, but the images from the three refracting surfaces, the so-called Purkinje-Sanson images, appear more distinctly than in any other method of physiological demonstration. Oblique illumination is therefore undoubtedly the best method of demonstrating these three mirror images. If the convex lens is approached closer to the eye, the small and distinct mirror image from the posterior lens surface is changed to an indistinct yellow reflection, particularly apparent in the eyes of old persons, and called in many text-books, improperly, as I take it, "nuclear-reflex." This reflection is not from the lens nucleus, but from the posterior lens surface, and the yellow color is due to the amber-like appearance of the senile nucleus.

If the convex lens is held so close to the eye that the image of the flame falls in or behind the crystalline lens, one sees a gray phosphorescent streak of light in the depth of the pupil. This streakiness, as well as Purkinje-Sanson images, may be used to prove the presence of the lens. The cause of this streakiness has been explained as being due not only to the stratified structure of the lens, but also to the fact that the lens of itself is not absolutely transparent.

Digitized by Google

III. THE OPHTHALMOSCOPE.

1. THEORY.

The cornea and aqueous being transparent, it is easy to see the iris lying behind them. The lens and vitreous are also transparent, and yet the pupil is black, the background of the eye invisible. Why is this? Until the ophthalmoscope was devised the answer ran as follows: Luminous rays entering the eye through the pupil form an optical image on the retina and are completely retained within the eye, partly because they are used up in creating sensations of light, but chiefly because they are absorbed by the pigment cells of the retina and choroid. As a proof of this teaching there was adduced the fact that the pupils of so-called albinos, white rabbits, for example, did not appear black, but were red, therefore luminous.

This doctrine is easy to disprove, for the pupils of albinos appear red, not on account of light that has entered the eye through the pupil, but by means of luminous rays that have pierced the opaque coats of the eyeball, the sclera, choroid, and retina.

To prove the above statement, take a white rabbit, put a hemispherical watchglass over its eye, and fill the space between glass and cornea with water. The glass should be blackened till transparency is destroyed, except over a spot corresponding to the pupil. If now the old doctrine were true, the pupil would appear just as bright as before; but such is not the case, for the pupil is black, although perhaps not so black as the pupil of an ordinary rabbit. Now scratch the blacking off the edge of the glass in a semicircular spot about *4 mm.* diameter, making the cornea visible behind it. By means of a convex lens throw on this scleral area a strong beam of light (in a dark room) from a lamp; the pupil immediately appears bright red.

Or any eye, not an albino, may be illuminated thus: Take a rabbit, dilate the pupil with atropin, and put the animal into a box holding the body rather firmly, but allowing the head to project somewhat as from a tight collar. In front of the rabbit's head place a lamp with an untransparent chimney, but make a spot on it so that a beam of light can be thrown from the lamp in one direction only (in a thoroughly dark room, of course). The lamp flame and the orifice in the chimney are so adjusted that rays from the flame strike the rabbit's eye from below upward. If the observer places his head close to the lamp chimney and looks as nearly as possible in the direction of the connecting rays into the rabbit's pupil, he will find not only that the pupil appears red, but that the blood-vessels are visible within it.

The fact that any eye is illuminated if the observer looks in the same direction as luminous rays entering it from a flame was discovered in 1846 by Cumming, and independently in 1847 by Bruecke. v. Erlach and his friend Brunner in the winter of 1846–47

observed that they could illuminate the pupil with their spectacles when conditions were such that the person under examination saw in the spectacles of the observer the reflection of a lamp in a dark room. These phenomena were explained in 1851 by Helmholtz, and the ophthalmoscope was thereby discovered.

It is a universal law that a reciprocity exists in a dioptric system between the object and its image; that is, if the image be considered as the object, luminous rays will traverse the same path backward that they originally took, and consequently the image will be produced at the place of the original object. In the eye's dioptric system—cornea, aqueous, lens, vitreous—the image of an object falls upon the retina if the adjustment is correct. Since luminous rays are by no means totally absorbed by retina and choroid, that part of the fundus of the eye covered by the image of a point of

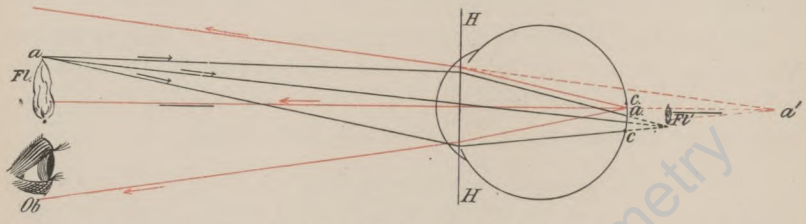

FIG. 36.—ILLUMINATION IN AN EYE.
The luminous rays entering the eye under examination are shown black, those returning from it are shown red.

light becomes in its turn a luminous object, light emerges from it, escapes in part through the pupil, and produces at the location of the original object an inverted, magnified, though very faint image of the illuminated area of the fundus of the eye. If by ordinary daylight we look into the pupil of an eye, our own pupils take the place of the bright object just mentioned; but since our own pupils are not a source of light, that very area of the eye's fundus which should reflect an image back into our pupils remains dark, and consequently the pupil of the person under examination cannot appear luminous.

It is obvious that there are two methods of making the patient's pupil luminous. One way is that of the experiment with the rabbit just described. The atropinized rabbit's eye is hyperopic, and therefore not adjusted for the flame, *Fl* (*Fig. 36*). The location of the flame's image is behind the retina at *Fl'*. On account of circles

Digitized by Univ. of Calif. Southern College of Optometry

of diffusion there is on the retina an illuminated area, *c c*. This area, considered as object, emits rays diverging as if they came from the far point of the hyperopic eye; for example, the point, *a*, sends out rays (marked red) which appear to come from *a'*: consequently they do not all return to their source at the flame, but some of them strike the observer's eye placed near the flame.[1]

Indeed, *Fig. 36* teaches us that the observer, if he accommodates for *a'*, ought to see a part of the fundus distinctly.

The first method of making the pupil luminous consists in illuminating the fundus by means of a source of light for which the eye under examination is not adjusted.

The second method consists in making one's own pupil luminous by any physical artifice, that is, by making it the source of light for the eye under examination. We can do this by means of a reflecting glass disk and a lamp flame. The observer (*Ob*, *Fig. 37*) and

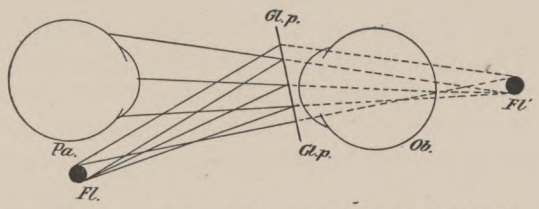

FIG. 37.—ILLUMINATION OF THE EYE BY MEANS OF A GLASS DISK.
The figure is supposed to be in the horizontal plane.

the patient (*Pa*) are opposite each other, and the flame (*Fl*) is in the same plane with their eyes. The observer holds the glass disk before the eye in such a way that a line perpendicular to the surface of the glass passes midway between *Pa* and *Fl*. Some of the luminous rays falling from *Fl* upon the glass are, according to the known law, reflected as if they came from *Fl'*; these pass, therefore, into the pupil of *Pa*, appearing to come from the pupil of *Ob*. But since only a part of the rays from *Fl* are reflected from *Gl* (another part passes through *Gl*, and can, therefore, be neglected in this experiment), and since, moreover, the rays entering the eye, *Pa*, are partly absorbed by the pigment cells, and still others of those returning from *Pa* are again reflected by *Gl*, it is evident that but

[1] If we trace the luminous pencil returning from the upper part of the illuminated field (the upper *c*), we find that *Ob* can be at quite a distance from the flame without getting outside the range of the returning cone of rays.

Digitized by the Internet Archive of Optometry

little light finally reaches the observer, and that the pupil of *Pa* will be but faintly luminous. Nevertheless, the experiment with a bright flame and a well-dilated rabbit's eye is easy to make. Here, again, it is possible to see the fundus distinctly if the eye of *Ob* is adjusted for the place from which luminous rays appear to come. We can, therefore, say that the fundus of the patient's eye is distinctly visible if the luminous rays appear to come from the pupil of the observer when his eye is adjusted for the apparent location of the fundus of the eye under examination.

The devices for illuminating the fundus to be examined will be referred to on *p. 114*, "Description of the Ophthalmoscope." Therefore, in the following theoretical explanations we may assume this illumination as already provided for. We need only discuss here the general conditions under which the fundus of an eye can be seen in its upright image.

Upright image. Direct method. The dioptric apparatus of the eye acts as a convex lens of short focal distance (*19.87 mm*). If the retina lies within the focal distance (*Fig. 38*, *H*) the eye is hyperopic, rays of exit from the fundus are at the cornea divergent, the image of the fundus, *a' b'*, is virtual, upright, and magnified. The observer can see it if he accommodates for the location of the image.

If the posterior focal point, *f*, lies exactly on the retina (*Fig. 38*, *E*) the eye is emmetropic, all rays emerge from the cornea parallel, an image is formed at infinity (that is, not at all). The observer can, however, see the fundus if he is emmetropic and does not accommodate, for in such a case all rays in passing through the refractive media of the eye form an image on the retina of his own eye.

Finally, if the retina lies behind the posterior focal point (*Fig. 38*, *M*) the eye is myopic, all rays emerge from the cornea converging to the far point of the eye under examination. The observer, supposed to be close in front of the cornea of the patient's eye, can receive on his own retina the image of the other's fundus only when he, himself, is hyperopic, and only when the (virtual) far point of the hyperopic observer coincides with *a'*, the actual far point of the myopic eye under examination.

Therefore, to be able to examine the upright image of the fundus of any eye, the observer must be capable of making his own eye emmetropic, hypermetropic, or myopic, at will. The last is the easiest. With the aid of accommodation the hyperope and the

Digitized by Illinois College of Optometry

emmetrope and, of course, the myope can adjust the eye for a near object, because the mechanism of accommodation can perceive by instinct that adjustment which will give the clearest vision. The myopic observer can make himself emmetropic by a neutralizing concave lens; the hyperope can accomplish the same result by a convex lens or by a proper effort at accommodation. Moreover, if the eye under examination is myopic, the emmetropic observer needs a concave lens to make him proportionally hyperopic; a

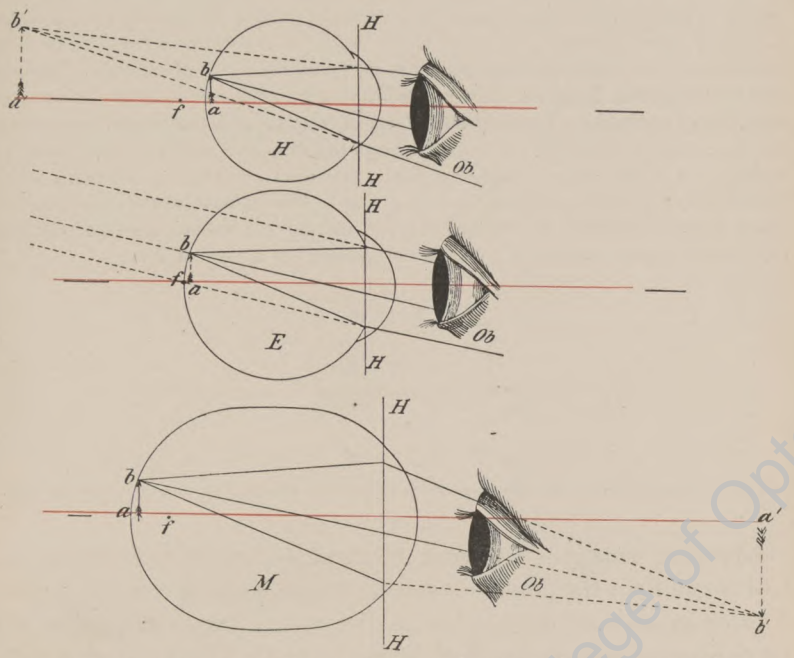

FIG. 38.—EXAMINATION OF THE UPRIGHT IMAGE, IN HYPEROPIA, EMMETROPIA, AND MYOPIA. *f* is the posterior focal point, the red line is the axis.

myopic observer needs for the same purpose a concave lens increased in strength by the amount of his own myopia; a hyperopic observer must increase his own hyperopia by such a concave lens or decrease it by such a convex lens as will make his (negative) far point coincide with the far point of the eye under examination.

Fig. 38 shows us that the refractive condition of the eye under examination influences the magnification at which the fundus of that eye appears to the observer. The stronger the hyperopia, the

Digitized by Illinois College of Optometry

closer to the actual fundus lies the virtual image of the fundus seen by the observer, and the less is the difference to him between the size of the object and the size of the image. In case the eye under examination is myopic, the relations are not quite so evident, but it can be shown by a simple construction that in this case the magnification is more pronounced than when the eye is emmetropic.

In *Fig. 39*, *Pa* is the eye of the patient and is at first emmetropic; the red arrow pointed downward represents an area of his retina. One ray from the tip passes apparently unrefracted through the nodal point, k_u; all others emerge from the cornea of *Pa* parallel to the first one. These rays, if they enter the pupil of an observer's eye adjusted for infinity, must intersect at a point of the retina of *Ob*, which is found by drawing through k_c a line (dotted red) parallel to the ray (continuous red) of entrance. Suppose *Pa* is now myopic; the black arrow pointed downward represents an area of his retina; rays passing out from the arrow tip would form an image, *r*, at the far point if the observer did not intercept them, but on passing through the refractive media of *Ob*, whom we assume now to be proportionately hyperopic, they form an image on his retina which must lie on the line of connection between k_c and *r*. We see now, that the black upright arrow is decidedly larger in *Ob* than the red one, that the former must be relatively increased in size the nearer *r* is; that is, the stronger the myopia of *Pa*.

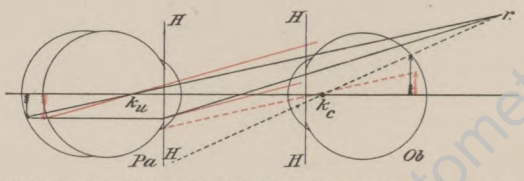

FIG. 39.—COMPARISON OF THE MAGNIFICATION IN AN EMMETROPIC EYE AND IN A MYOPIC EYE.

Inverted Image. Indirect Method.—*Fig. 38* (*M*) shows us that we can see the fundus of a myopic eye without concave lenses. The observer need only retire (to the right) from the patient till he is beyond the image, *a' b'*, which is in the air, inverted, actual, and magnified, when he will perceive it if he uses his accommodation for the location of this image. He sees an inverted image, and on this account the method is called the "examination of the inverted image." It is evident that this examination is possible without the use of other means only when the myopia is of a high degree, for the lower the myopia, the larger and consequently the dimmer will be the aerial image, *a' b'*, and, therefore, the smaller will be the area of the fundus, whose image is at one time visible to the observer. But there is a very simple method of making any eye artificially myopic; for this purpose we use a convex lens. Ruete first introduced this practice into ophthalmology, and since

Digitized by the Internet Archive of Optometry

then the examination of the inverted image has been generally applied. *Fig. 40* illustrates the principle for the three cases—hyperopia (*H*), emmetropia (*E*), and myopia (*M*).

The drawing indicates that the refractive condition of the eye under examination has an influence on the size of the resulting inverted image. The rays from the myopic eye, *M*, already convergent when they strike the convex lens, *S S*, are the soonest to be united at a focus, and, therefore, the smallest image is the result.

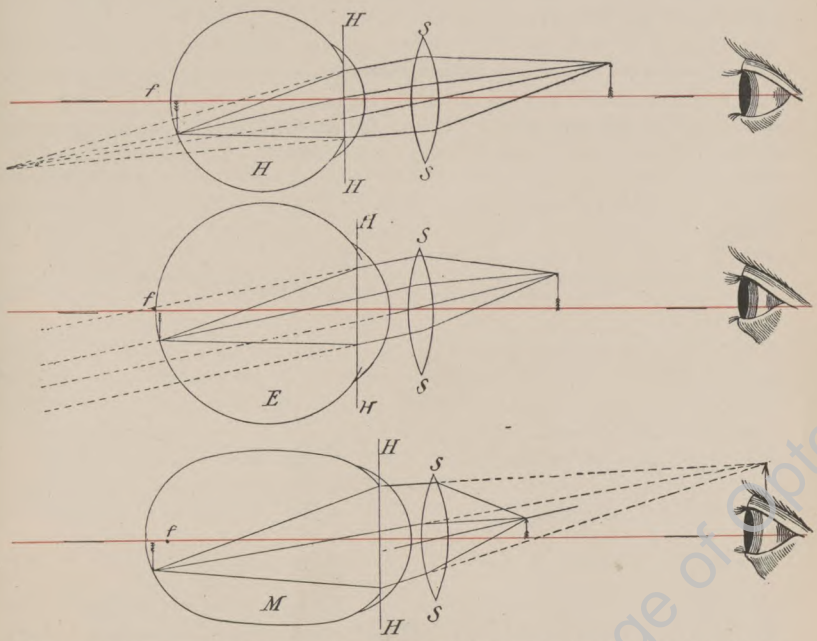

FIG. 40.—EXAMINATION OF THE INVERTED IMAGE, IN HYPEROPIA, EMMETROPIA, AND MYOPIA. *f* is the posterior focal point, the red line is the axis.

The rays from the hyperopic eye, *H*, divergent when they strike the convex lens, *S S*, are the last to be united, and therefore the largest image is the result. The rays from the emmetropic eye, *E*, are parallel when they strike the convex lens, *S S*, and the result is an image of a size midway between the two others.

Amount of magnification of the upright image. The upright image is a virtual one; consequently its size cannot be compared with the size of the actual image without some explanation. This comparison is, however, not essential, since we obtain a good answer to the question as to the ophthalmoscopic magnification by comparing the visual angle at which an object (the optic disc, for example) appears, if it is in one case examined at a

Digitized by the Illinois College of Optometry

definite distance as an anatomical preparation, and in another case as a living object seen through the refractive media of the eye under examination; that is, in the upright image.

This "definite distance" should be the distance of the observer's near point. At the near point of our eyes objects appear under the greatest practical visual angle; but the near point differs in different individuals according to the age, and we are accustomed by experience to bring objects that we wish to examine most exactly not precisely to the near point, but to a distance of *20* to *30 cm.*, youthfulness of the observer being assumed. The question as to the ophthalmoscopic magnification becomes therefore the following: What is the relation of the visual angle under which the virtual image of the optic disc appears, to that visual angle under which the disc itself appears at a distance of *25 cm.*? In case the patient (*Pa*, *Fig. 41*) and the observer (*Ob*, *Fig. 41*) are both emmetropic, the answer will be as follows:—

Let *a* (*Fig. 41*, *II*) be *250 mm.* from the principal plane, *H H*, and the size of the object, *a b*, be *1.5 mm.* The object then appears under a visual angle of $\frac{1.5}{250+5}$, since on the one hand, we have assumed the distance of the nodal point from the principal plane to be *5 mm.*, and on the other hand we can use the trigonometrical tangent instead of the angle itself, all angles being so small in this instance. But if *a b* is looked at through the

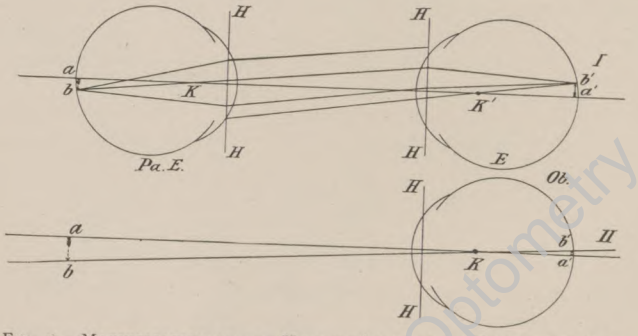

FIG. 41.—MAGNIFICATION OF THE UPRIGHT IMAGE IN AN EMMETROPIC EYE.

dioptric apparatus of the eye under examination (*Fig. 41*, *I*) acting as a lens, then, as the figure shows, the visual angle is equal to $\frac{b'a'}{K'a'}$. The similarity of the triangles, *b' a' K'* and *b a K*, makes $\frac{b'a'}{K'a'} = \frac{b\ a}{K\ a} = \frac{1.5}{15}$. This last equation is *17* times greater than $\frac{1.5}{255}$, and the magnification is, therefore, a seventeenfold one.

In the second case (*Fig. 42*), when the patient's eye is axis myopic, let the myopia be of *5 o D.* Then the disc lies *1.6 mm.* behind the posterior principal focal point, *f*, and the far point, *a'*, is *200 mm.* in front of the principal plane, *H H* (*Fig. 42*). Let the observer (*Ob*) be *40 mm.* away from the patient (*Pa*). Under these conditions the hyperopic *Ob*, having a virtual far point at *a'*, sees the arrow, *a b*, at a visual angle, $\frac{a''b''}{K'a''} = \frac{a'b'}{K'a'}$. The denominator, *K' a'*, with our assumption above, is equal to *200—40—5 = 155 mm.*, if we take the distance of the nodal point, *K'*, from the principal plane, *H' H'*, to be *5 mm.* The numerator can be determined by means of a pair of equal triangles, as shown in the figure (*a b K = a' b' K'*) to be $\frac{1.5}{16.6} \times 205\ mm.$ The equation then reads $\frac{1.5}{16.6} \times \frac{205}{155} = \frac{1}{8.3}$. Since *a b*, at a distance of *250 mm.*, appears to *Ob*, without the magnification of the patient's eye, at a visual angle of $\frac{1.5}{255} = \frac{1}{170}$, and since $\frac{1}{8.3}$ is *20.5* times greater than $\frac{1}{170}$, we find the desired magnification to be *20.5*.

Digitized by the College of Optometry

By a corresponding process we find the magnification for a case where the patient has *5.0 D* hyperopia and the (myopic) eye is *40 mm.* distant from *Pa* to be a fifteenfold one.

Amount of magnification of the inverted image. Assume the patient to be emmetropic. To obtain the inverted (aerial) image use a convex lens of *20.0 D* ($\frac{1}{20}$ *m.* = *50 mm.*) focal distance. Since rays emerging from an emmetropic eye are parallel, the aerial image, *a' b'*, *Fig. 43*, falls at the focal distance, *K' a'*, of the lens; and since, with the above

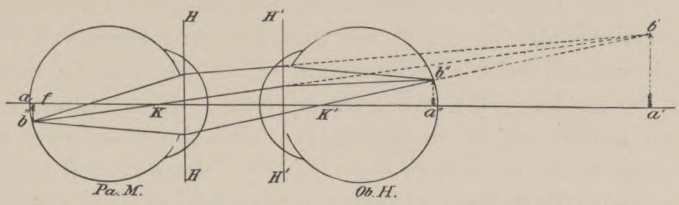

FIG. 42.—MAGNIFICATION OF THE UPRIGHT IMAGE FROM A MYOPIC EYE.

assumptions, the ray of direction, *b K*, in the emmetropic eye, *Pa*, is parallel to the ray of direction, *K' b'*, of the lens, *S S*, the triangle *a b K* being thus equal to the triangle *a' b' K'*, then $\frac{a\ b}{a\ K} = \frac{a'\ b'}{a'\ K'}$; and since

$$a\ b = 1.5\ mm.$$
$$a\ K = 15\ mm.$$
$$a'\ K' = 50\ mm.,$$

then $a'\ b' = \frac{1.5}{15} \times 50 = 5\ mm.$; in other words, the aerial image of *Ob* is *5 mm.* in size, about *3.3* times larger than the object, the disc. Since we are treating here of actual and directly comparable images, there is no need of considering the visual angle, and we can say at once that, with the above assumptions, the magnification is a *3.3*-fold one.

By *Fig. 43* we can further perceive that the distance of the lens, *S S*, from the emmetropic eye, *Pa*, is immaterial, and that the magnification increases with a weak lens and decreases with a strong one. Suppose a lens at *K'* with twice the refractive power of

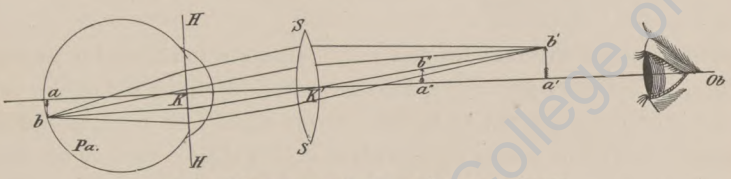

FIG. 43.—MAGNIFICATION OF THE INVERTED IMAGE.

S S; then the image, *b'' a''*, falls at *K' a''*, just half the distance of *K' a'*. Therefore the image, *b'' a''*, is half the size of *b' a'*, and the magnification only one and a half that of *S S*. If *Pa* has a myopia of *5.0 D* and the lens (*20.0 D*) is *40 mm.* from the principal plane of *Pa*, by the same reasoning we find an aerial image of the disc to be *4 4 mm.*, about a threefold linear magnification. With hyperopia of *5.0 D*, and the lens at *40 mm.* distance, the aerial image of the disc is *5.6 mm.* long, a *3.7*-fold magnification.

If the lens, *S S*, is placed so far from *Pa* that its focal point coincides with the anterior focal point of *Pa*, the refractive condition of *Pa* will have no influence upon the magnification; in emmetropia, hyperopia, and myopia it is the same. With the focal point of *S S* falling outside the focal distance of *Pa* the conditions change, the magnification is

Digitized by Illinois College of Optometry

weakest in hyperopia and strongest in myopia. (Farther analysis is unnecessary, since such problems are seldom applied in ophthalmoscopy.)

Ophthalmoscopic Field of Vision.—

(*1*) *Upright image.*

(*2*) *Inverted image.*

(*1*) *Upright image.* That part of the patient's fundus which the observer is able to see at one and the same time is called the ophthalmoscopic field. The question of its size can be best answered by applying the law of reciprocity. Every point in the patient's fundus sends luminous rays into the observer's pupil, every point of the observer's pupil receives these rays if they are luminous; in short, the ophthalmoscopic field is coincident with that diffusion image of the observer's pupil which is made upon the fundus of the patient's eye. To construct the image of the pupil, *Pp* (*Fig. 44*), upon the fundus of the patient's eye, draw lines from *P* and *p* of *Ob* through the nodal point *K* to the retina of *Pa*. Then *p' P'* is the image of *Pp*, in case *Pa* is adjusted for *Pp*, which is obviously not always so. Consequently every point of *Pp* may

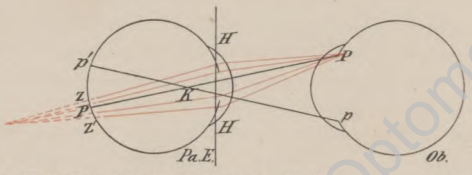

FIG. 44.—THE OPHTHALMOSCOPIC FIELD OF VISION. UPRIGHT IMAGE.

produce on the patient's fundus a diffusion circle instead of an exact image. The red lines represent the diffusion circle *z z'* of the point *P*, assuming the patient to be emmetropic and free from accommodation. If this is taken for granted, it is a simple matter to determine the four conditions which influence the size of the ophthalmoscopic field.

(*a*) *The size of the observer's pupil* must be considered, since the greater *Pp* is, the greater will be the image *p' P'* on the fundus of the patient's eye. As a matter of fact, the size of the observer's pupil becomes of no consequence by reason of the small hole in the ophthalmoscope that is always placed before the observer's eye. This hole in the mirror, therefore, plays the part of the observer's pupil in *Fig. 44*.

(*b*) *The distance of observer from patient* is of great significance;

Digitized by the Illinois College of Optometry

because, as the patient is approached, the hole in the mirror is brought closer and allows a larger image to be thrown on the patient's fundus. The practical rule, then, in the examination of the upright image takes no account of the size of the observer's pupil, but emphasizes the importance of approaching as close as possible to the patient.

(*c*) *The size of the patient's pupil* is also of great significance. It must be as dilated as possible, by closing the other eye, shutting off unnecessary light (dark room), excluding light from the most sensitive part of the fundus (macula lutea), or, if necessary, by the use of a mydriatic. That the ophthalmoscopic field is enlarged and the examination facilitated by a dilated pupil is seen in *Fig. 44*. A narrow pupil in the patient cuts off some of the rays and diminishes the size of the diffusion circle, $z\,z'$.

(*d*) *The position of the point for which the patient's eye is accommodated* has the most direct influence upon the size of the diffusion image of *Pp*, and therefore upon the size of the field. Obviously the diffusion increases equally as the point of accommodation in the patient's eye is withdrawn (toward the right in the figure); if this reaches infinity, that is, if the patient is emmetropic, the field is greater than that of any myopia; in hyperopia it is the greatest, the point of accommodation being beyond infinity. Hence we may conclude that *in the examination of the upright image the ophthalmoscopic field increases with increasing hyperopia and decreases with increasing myopia.*

In this study of the size of the ophthalmoscopic field it is always taken for granted that the entire fundus of the patient's eye emits light. This is not always so. In practice we find, often enough, that only a small part of the field is illuminated, or consequently luminous and visible. The character of the mirror, the size and distance of the flame, are here the most important factors.

The increase of the field with corresponding decrease in magnification of the image can be demonstrated as follows: On the atropinized eye of a rabbit place a small glass cylinder whose base is covered with a sheet of mica; fill the space between cornea and mica with water. The cornea is thereby obliterated (optically) and the eye made strongly hyperopic; we see now a large area of the fundus scarcely magnified at all. Since the virtual image of the fundus lies relatively close behind the actual fundus, the most inexperienced observer can easily accommodate for this image. The experiment is a good introduction to the study of ophthalmoscopy.

The conditions are the same after cataract operations; but as the lens has only one-fourth the refractive power of the cornea, the hyperopia is not so great as it is when the cornea is obliterated.

Digitized by the Internet Archive in 2010 with funding from Illinois College of Optometry

(2) *Inverted Image.* In this, also, the ophthalmoscopic field is coincident with the (diffusion) image of the observer's pupil on the fundus of the patient's eye; but, on account of the interposition of the convex lens, it is much larger than in the examination of the upright image. If the lens is held properly the size of the patient's pupil has no influence, the size of the observer's pupil very little influence, so that it is unnecessary to study these factors further. But the size of the lens and its focal distance and the refractive condition of the patient's eye are of the greatest importance. This is easily perceived in *Fig. 45.*[1]

Here the pupil of the observer is assumed to be a point. A pencil of rays proceeding from it would, on account of the relatively great distance between *Ob* and the lens, *S S*, be united close behind *f*, the focus of *S S*. If now the lens is so held that its focal point falls just in front of the plane of the patient's pupil, the image of *p* will lie at or close behind this plane; and, consequently, *p' P'* will be

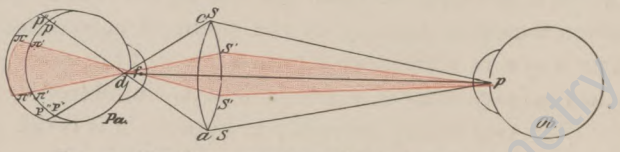

FIG. 45.—THE OPHTHALMOSCOPIC FIELD, INVERTED IMAGE.

the diffusion image of *p*, if the patient is hyperopic, or *p'' P''* if he is myopic.

Without going further, it is seen that the size of the patient's pupil is without significance if the point of intersection, *d*, lies near the pupillary plane, and that the ophthalmoscopic fields, *p' P'* and *p'' P''*, become somewhat larger when the observer's pupil is dilated. Every point of his pupil will then produce just such a field, *p' P'*, and the individual fields will only in part be coincident.

The influence of the size of *S S* is shown in the coloring in *Fig. 45*. If *S S* is made small by reducing it to *S' S'*, then only the areas, $\pi' \pi'$ or $\pi'' \pi''$, receive rays from *p* and are perceptible. The influence of the focal distance can be recognized by the fact that with a shorter focal distance the lens, *S S*, would have to be approached closer to the patient in order to throw the image of the observer's

[1] For the sake of clearness, it is assumed that the rays converging to the point, *d*, proceed further in a straight line. As a matter of exactness this is correct only when *d* coincides with the nodal point. But there is obviously no radical error in using this license in a text-book.

Digitized by the Internet Archive in 2010 with funding from Illinois College of Optometry

pupil on to or close to the patient's pupil; but the nearer $S\,S$ is to the patient, the greater is the angle at d, and therefore the greater is $p'\,P'$.

The influence of the refractive condition of the patient's eye can be seen in the fact that $\pi'\,\pi'$ is smaller than $\pi''\,\pi''$, and $p'\,P'$ is smaller than $p''\,P''$. The hyperopic eye ($p'\,\pi'\,\pi'\,P'$) admits of a smaller ophthalmoscopic field, *ceteris paribus*, the myopic eye ($p''\,\pi''\,\pi''\,P''$) a larger; the emmetropic eye a medium field—*the size of the ophthalmoscopic field increases with increasing myopia, diminishes with increasing hyperopia.*

In practising the examination of the inverted image the proper distance for the lens is found by observing the image of the patient's iris. If the convex lens is held too far from the patient, that is, if its focal point falls in front of his eye, the observer sees an inverted image of the iris; if it is held too near, he sees a virtual upright image; and if it is held just right, that is, so as to throw the focal point the smallest distance in front of the pupillary plane, he sees no iris image. It is best, therefore, to move the lens back and forth till the iris image disappears, when the largest field will be visible.

When it was said that if the lens were held properly the size of the patient's pupil had no significance, it had reference only to the theoretical ophthalmoscopic field, it being taken for granted that the entire fundus of the patient's eye emitted light. This assumption is practically not fulfilled. On the contrary, the ordinary concave mirror illuminates only a part of the ophthalmoscopic field and makes it perceptible. Practically, then, the size of the patient's pupil plays an important part in the examination of the inverted image. The beginner finds it hard or even impossible to see the fundus of the patient's eye if the pupil be small. The principal reason for this lies in the fact that, as the pupil contracts, the brightness of the illuminating field (in the fundus of the patient's eye) decreases, while the quantity of light reflected from the cornea remains unaltered. The corneal reflex, therefore, rather obscures the image of the fundus.

From what has been said, especially from the examples given, we see that the ophthalmoscopic magnification is decidedly larger in the examination of the upright image than in that of the inverted image; and further, that this magnification on the one hand, and the extent of the field on the other, stand somewhat in opposition to each other. A good working rule may be deduced from this—first, to examine the inverted image of the fundus to get the largest possible view of it and its condition, and then to proceed to the examination of the upright image in order to study the details with the highest possible magnification.

Digitized by the Internet Archive in 2010 with funding from Illinois College of Optometry

2. DESCRIPTION OF THE OPHTHALMOSCOPE.

Although Helmholtz's original ophthalmoscope is now used only for particular purposes, we should honor its discoverer by describing his instrument first (*Fig. 46*). It consists of a disk of three reflecting glass plates, *a*, which form the oblique end of a brass tube, *b*, and of an adjustment at the other end for putting in place a concave lens, *c*. The whole is held by a handle (not shown in the figure). The observer at *d* looks into the square end of the tube through the glass plates toward the patient's eye. The visual axis cuts the glass plates at an angle of 30°. In order that the luminous rays coming from the lamp may be reflected in this direction, they must have an incident angle of 60°, an arrangement possible only when the lamp is placed quite at one side. This inconvenience must be put up with for the sake of the advantage gained by the strongest possible illumination of the fundus with the weakest possible reflex of the cornea.

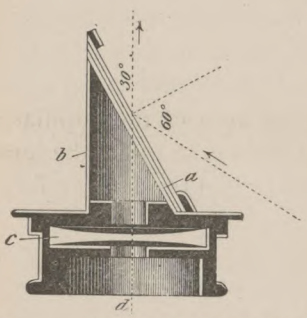

FIG. 46.—HELMHOLTZ'S OPHTHALMOSCOPE IN HORIZONTAL SECTION. The arrows indicate the path of the incident rays.

Helmholtz's ophthalmoscope gives, however, under the best of circumstances, but feeble illumination. For this reason Epkens used a glass disk with a coating on the back, a genuine mirror, in which a small hole was scratched for the observer to look through; but since there was still a reflex from the uncovered bit of glass, which, while it absorbed light, also confused the observer by throwing part of this reflex into his eye, the method was adopted of boring a hole through the glass itself. This hole formed a small canal through the thickness of the glass, and its walls had to be well blackened in order to avoid any confusing reflex from them. This could not be completely overcome unless the canal were made very short, which was possible if a polished plate was used instead of glass.

Even with these improvements the plane mirror is still of feeble illumination. For this reason Ruete, to whom we also owe "the examination of the inverted image," made use of the stronger concave mirror. This gives in front of its reflecting surface an in-

Digitized by the Internet Archive of Optometry

verted, reduced, actual image between mirror and patient; the plane mirror, on the contrary, gives an upright, virtual image behind the mirror, that is, an image at a greater distance from the patient. It is evident, then, that the concave mirror throws a greater quantity of light into the patient's pupil, although this does not imply that the retinal area illuminated by the concave mirror is brighter than can be obtained by the use of a plane mirror. The circumstances influencing this condition are, however, too numerous to be disposed of in a few words.

The concave mirror most used, on account of its handy shape and small price, is that of Liebreich (*Fig. 47*). Its focal distance is generally between *14* and *20 cm.* On the blackened frame sur-

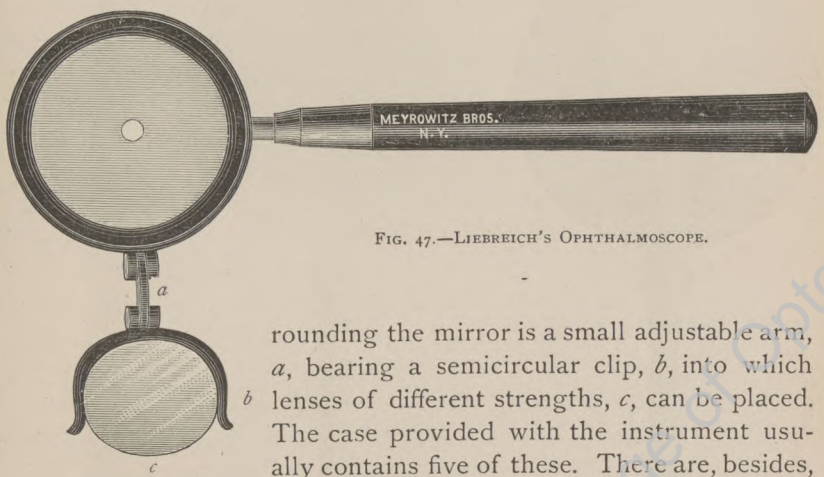

FIG. 47.—LIEBREICH'S OPHTHALMOSCOPE.

rounding the mirror is a small adjustable arm, *a*, bearing a semicircular clip, *b*, into which lenses of different strengths, *c*, can be placed. The case provided with the instrument usually contains five of these. There are, besides, two convex lenses of *13.0 D* and *20.0 D*, which can be used both for examination of the inverted image and for focal illumination.

As a rule, the weak plane mirror is to be preferred to the strong concave mirror. Jaeger devised an ophthalmoscope in which either a plane or a concave mirror could be introduced at will. Coccius obtained the same result by combining a plane mirror with a convex lens, the latter being replaceable by one of stronger or weaker focal distance as might be required, and according to choice, the effect of a concave mirror of great or small focus was produced. If the convex lens was removed there remained only the action of a plane mirror.

Digitized by Illinois College of Optometry

Zehender accomplished a similar result by combining a convex lens of about *10.0 D* with a convex mirror; in this ophthalmoscope changing the distance of lens from mirror produced the same effect as changing the lenses in Coccius' instrument.

An essential advance was marked by the introduction of the refraction ophthalmoscope. *Fig. 48* illustrates one of the best of its kind. The principle of it is the same as that of the simple



FIG. 48.—REFRACTION OPHTHALMOSCOPE.

Liebreich instrument. It has the added advantage that behind the sight-hole there can be introduced lenses of varying strength mounted in a rotating disk.

There are innumerable ophthalmoscopes. Many are but modifications of the above; some introduce other optical principles; others, such as the instrument to examine one's own eyes, or the binocular ophthalmoscope, serve a particular purpose. They need no description here.

Digitized by Illinois College of Optometry

3. USE OF THE OPHTHALMOSCOPE.

The ophthalmoscope serves four purposes—

(*A*) *To discover and to determine the location of opacities in the refractive media;*

(*B*) *To study the fundus;*

(*C*) *To determine the refraction condition;*

(*D*) *To demonstrate differences in level in the fundus.*

In using the ophthalmoscope the observer sits in a dark room about *40 cm.* in front of the patient. By the side of and somewhat behind the eye to be examined is the source of light, which may be an oil lamp or a gas flame; the flame should be large in any case. The source of light, the eyes of observer and patient, should all be in about the same horizontal plane; it is therefore of advantage to have lamp and stools for the physician and patient that can be raised and lowered. It is advisable for the physician to accustom himself, when making examinations of the upright image at least, to use his right eye for the patient's right eye, and his left for the patient's left eye, since this is the only way to get closest to the eye, and the discomfort of rubbing noses is thereby avoided. It must be acknowledged, however, that most ophthalmologists do examine the patient's left eye with their right. Another good plan is for the patient to turn his face toward his right while continuing to look straight ahead, since in this way his nose is brought to the side of the nose of the examiner.

The patient is now asked to stare vacantly at the physician's right ear if the patient's right eye is to be examined, at the left ear if the left eye is to be examined; by doing this his pupil remains dilated and there is no effort at accommodation if the stare is a vacant one. Then the physician places the ophthalmoscope before his eye, and moves it about somewhat till the bright beam of light strikes the patient's pupil, a proceeding that often enough miscarries with the inexperienced observer, who fails to illuminate even the body, let alone the eye of the patient. The pupil appears bright red, and, of course, contracts somewhat under the stimulus of the light. This contraction is insignificant, because, if the attitude above mentioned is maintained, the light does not strike the most sensitive area of the fundus, the macula lutea, but falls on a portion of the retina which is less apt to cause a reflex pupillary reaction.

Digitized by the College of Optometry

(A) TRANSILLUMINATION.

If a foreign body or an opacity is present in the pupillary area, it appears as a dark spot on a red ground. If this opacity is not very dense, a nebecula corneæ, for example, it appears as a mere shadow on a bright ground.

Any spot appearing black or dark by transillumination seems white, or lighter than its surroundings by focal illumination. The explanation is easy. Opaque spots are only partially or not at all transparent; luminous rays proceeding from the fundus and falling on the opacities (from behind) are returned to the fundus and are not seen by the observer. The reverse is true of focal illumination; rays reflected from opaque spots do not reach the retina of the patient, but are thrown into the eye of the observer.

In locating an opacity one fact must always be remembered, that spots on the cornea and lens are immovable, while anything in the

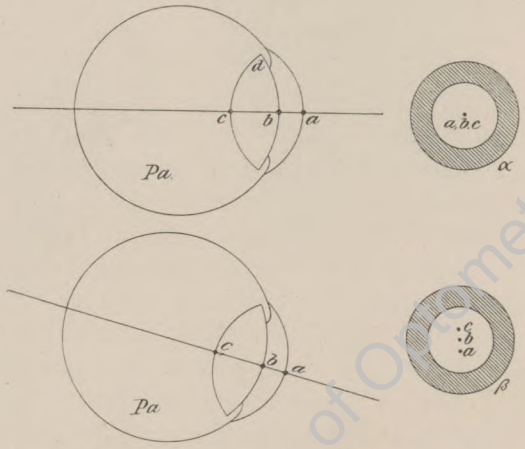

FIG. 49.—LOCALIZATION OF OPACITIES IN CORNEA AND LENS.

vitreous is generally movable. If the patient be asked to look with jerky movements upward and downward, to the right and left, these unsettled cloudinesses of the vitreous continue to float within the pupillary area after the eye has ceased to move, till they slowly sink out of sight by their own gravity. They may have the shape of threads, clouds, lumps, or misty films.

Opacities of the cornea have no movement independent of the eyeball. To distinguish them, in addition to focal illumination (*p. 98*) we use the phenomenon of parallactic displacement. Let the point *a*, *Fig. 49*, be an opacity of the cornea, the point *b* an opacity in an anterior layer of the lens about in the pupillary plane,

Digitized by Illinois College of Optometry

the point *c* an opacity on the posterior surface of the lens. Then the observer, looking in the direction of the optical axis into the patient's pupil, sees only one opacity, as is illustrated in *a*, *Fig. 49*. Now ask the patient to look downward; all the opacities now become visible, the corneal opacity lying below, the posterior lens opacity above, the opacity *b* in the middle. This last, apparently, has not changed its place; the posterior one seems to have risen. (As a matter of fact, they have all three descended somewhat.) An apparent movement in a direction opposite to the actual movement of the patient's eye is a proof that any opacity lies behind the pupillary plane; an apparent movement in the actual direction of the patient's eye indicates a position in front of the pupillary plane.

If the patient's eye remains still and the observer himself moves, the opposite is true; that is, opacities lying in front of the pupil seem to move in the opposite direction, opacities behind the pupil in the same direction. The extent of this apparent movement gives us a clue to determine the distance of the opacity either in front of or behind the pupillary plane.

The examination of corneal and lens opacities by transillumination can be completed by placing behind the sight-hole of the ophthalmoscope a convex lens which allows the observer to approach closer to the opacity, and which magnifies it at the same time. Hirschberg and Magnus have developed this method and devised special instruments for it; the strong lenses of the refraction ophthalmoscope can, however, be used for the same purpose.

Transillumination effects more than focal illumination in a case, for example, where an attempt is made to discover a small hole in the iris through which a splinter of iron may have passed into the eye. A luxation of the lens, or a movable lens, can best and easiest be recognized by transillumination.

(B) EXAMINATION OF THE FUNDUS OF THE EYE.

It is advisable for the beginner to commence with the examination of the upright image of an atropinized eye. A rabbit is a good subject for experiment, since it remains still if placed in a suitable receptacle, has hyperopic eyes, and does not complain of blindness or discomfort at long seances. Moreover, its fundus has a very characteristic structure, whose lines and colors are easily described and drawn. The first effort consists of obtaining a view of the optic nerve entrance (papilla nervi optici). The observer, in examining a rabbit's eye, looks from below upward and back-

Digitized by Illinois College of Optometry

ward; he knows he is in the right direction when he sees that the usual red appearance of the fundus has changed to a white shimmer. To be sure, the medullary fibers also return a white reflex, but much has been accomplished when even this is discovered. The best method is to begin at a distance of about *20 cm.*, and to throw the light from the mirror in various directions on to the pupil till a white reflex appears, then to approach as close as possible to the eye under examination. If this effect is lost by inexperience, begin over again in the same way, till the eye can be approached very closely without losing this white reflex from the pupil. The next is the hardest task—to find the proper focal adjustment for the location of the virtual image of the fundus. As the observer knows that the object he is examining lies just in front of his eye, he accommodates instinctively and thereby prevents the most accurate vision; he must therefore try to imagine that the object of his attention lies far off, or in case this does not suffice he must neutralize his accommodation by concave lenses. On account of this instinctive accommodation the beginner is often able to see the fundus the easier, the more hyperopic the patient is, that is, the nearer the virtual image of the fundus lies to the actual fundus. If all this is successful, let the student take pencil and paper and try to reproduce what he sees in a drawing, even if it be imperfect; this sharpens the attention decidedly and protects the student from many errors to which he might otherwise fall a victim.

If the first difficulties are overcome and the student can see the upright image, the papilla, the retinal vessels, and the medullary nerve fibers in the rabbit's eye, let him make the more difficult attempt to see the inverted image of the fundus (*Fig. 40, p. 107*). Let us suppose that this attempt is made on man; we must then try to see the optic disc, first, because this spot on the fundus is the brightest and the easiest to describe, second, because it is insensitive to light, its illumination neither blinding the eye nor causing contraction of the pupil. On *page 69* we saw that the papilla in man lies about *12°* to *15°*, reckoned from the nodal point, toward the nasal side of the fovea centralis. We must, therefore, after having induced the patient to gaze in a certain direction, look into the eye at that angle measured from the visual axis outward (toward the temporal side).

The observer is now at about *40 cm.* distance from the patient,

Digitized by Illinois College of Optometry

and he illuminates the pupil back and forth until it appears white, or at least a paler red. Then, holding the convex lens between his index finger and thumb, he introduces it into the path of the luminous rays, taking care that the left hand does not tremble in the air but is supported by the little and ring fingers resting on the patient's forehead. Generally the beginner sees nothing at the first attempt but reflexes—images of the mirror reflected from the convex lens or from the cornea, but by tilting the lens a little from the optic axis, the observer learns to obliterate from his visual field these disturbing images. It should not be forgotten, however, that if the lens is held too obliquely the fundus may be astigmatically distorted, and therefore the lens should be tilted only to the minimum extent necessary. If light has not been by this means diverted from the patient's pupil, the last and hardest step comes now—for the observer to accommodate for the image in the air. Since the beginner generally has the impression that the object he is looking at is in the eye, he accommodates for that distance; but the aerial image for which he should accommodate lies in front of the eye and in front of the convex lens, and, therefore, by accommodation for the actual location of the fundus he cannot obtain a perfect view of the image.

To learn how to conquer this difficulty, one can practise reading print held upside down and looked at through a convex lens. The convex lens gives an inverted image of the inverted print, that is, it gives an upright image between the lens and the reader, and the print is unreadable so long as the observer cannot bring about the adjustment necessary for the location of the aerial image between his eye and the lens. This adjustment can be more easily acquired by holding a needle at about the spot where he expects the image to be. If he cannot find this aerial image, let him try with a convex lens of *2 or 3 diopters*, such as is found in any refraction ophthalmoscope.

After the disc has been seen and an opinion formed concerning its normal or pathological condition, the student proceeds to examine the fundus in detail. The neighborhood of the nerve sheath and the spot most necessary to vision (the macula lutea) can be brought into view by moving the convex lens; the rays emitted from the fundus pass in that case through the periphery of the lens, which acts as a prism to deflect these rays toward the base, and consequently the observer does not see that portion of the fundus which lies exactly opposite the lens, but other areas lying somewhat to the side.

To view the fundus at a still greater distance from the disc, the patient changes the direction of his gaze, or the physician moves

Digitized by Illinois College of Optometry

his own head and looks at the fundus from above, from the right and from the left; but the upper half of the retina can be seen only when the patient looks upward.

Although the various pathological changes in individual diseases will be discussed later, this is the best place to introduce a short description of the normal fundus. On the red ground is seen the lighter papilla with the retinal vessels arising from it. As to the ground itself, its color changes from yellowish-red to reddish-brown according as the individual is light or dark haired. Boll, the discoverer of the visual purple, ascribes the red of the fundus to the presence of a retinal purple, but this view is not tenable. Visual purple is a quite different red (rose, blue-red, hence the name purple) and can be bleached out without materially changing the color of the fundus. Undoubtedly the red of the fundus is due to the blood of the choroid. The capillaries of the choroid are covered only by the transparent retina and the translucent but not transparent pigment-epithelium. The abundance of pigment in the epithelium has, consequently, the illumination being the same, the greatest influence on the color of the fundus. This abundance of pigment directly corresponds also to the pigmentation in other parts of the body; in the negro it is so great that the bloodredness of the choroid can scarcely be distinguished.

The *papilla nervi optici* is the most remarkable spot of the fundus, and is the area at which every ophthalmoscopic examination begins. The name would indicate that something protrudes above the surface of the fundus, but that is not the case. Anatomically the condition is as follows (*Fig. 50*): the choroid has a hole in it extending through the sclera; this aperture is crossed by a network of fibers from the scleral tissue. The optic nerve fibers have their normal medullary sheath as far as this network, the so-called lamina cribrosa (*Fig. 50*), but inside this network, that is, within the sclera, the medulla is lost. After the naked axis cylinders have passed through the opening in the choroid they bend nearly at right angles and spread out as the innermost retinal layer as far as the periphery of the fundus. There is, therefore, no reason for calling it a prominence (papilla).

The external border of the optic nerve sheath (*Fig. 51*) is a black circular line called the choroidal ring, because it bounds the opening in the choroid through which the optic nerve enters into the eyeball. Next the choroidal ring inward is the scleral ring (*Figs.*

Digitized by Illinois College of Optometry

ance according as it is viewed in the upright or in the inverted image. In the upright image it appears about the size of the disc, distinguishable from the surrounding fundus by being somewhat darker in color; in the middle of it is a sickle or fan-shaped or rounded point of light. In the inverted image (*Fig. 51*) the yellow spot in young persons appears to be bordered by a line describing an egg-shaped figure with its long axis horizontal.

These phenomena can be thus explained: The light thrown on the fundus is partly returned as diffused, that is, each point of the fundus returns luminous rays diverging in all directions; each point, therefore, is luminous. Some of these rays reach the observer's eye and enable him to see vessels, pigment spots, differences of level, etc. But on the inner surface of the retina there are regularly curved areas that act as concave or convex or cylindrical mirrors according to their curvature, and consequently rays proceeding from the ophthalmoscope are returned to form small reflected images—actual if in front of the retina, virtual if behind it. These images of the ophthalmoscope are seen by the observer only when a narrow cone of light from an image reaches his eye.

The fact that the yellow spot, round anatomically, appears egg-shaped to the observer is explained by Johnson to be a distortion caused by the mirror and convex lens.

There are other differences besides those given here, and the beginner is apt to call them pathological, although they are only modifications of a healthy fundus. One of the most common is the visibility of the choroidal vessels; they may be distinguished from the retinal vessels by their ribbon-like appearance, their arrangement in parallel groups, and their lack of branches. Again, the pigmentation may not be regular, so that the fundus loses its uniform appearance and seems parceled off into divisions. One sees dark spots with bright red streaks between; the streaks are choroidal vessels, the dark spots are the "intervascular spaces." Finally must be mentioned the reflexes along the vessels, giving to the retina a peculiar glittering appearance, but easily distinguishable from retinal opacities, which are constant and immovable, by the fact that the reflexes seem to be moved and displaced when the mirror is turned.

(C) ESTIMATION OF REFRACTIVE CONDITIONS.

Even when illuminating the refractive media (*p. 118 et seq.*), we may often determine whether the patient is hyperopic or myopic. In many cases retinal vessels are visible at quite an appreciable distance; if now we find an actual, inverted aerial image in front of the patient's eye, the condition must be myopia; if, on the other hand, the image is virtual, upright, and behind the patient's eye, the

Digitized by Illinois College of Optometry

condition must be hyperopia. It is easy to decide which of the two is the case. Let the observer move his own head toward his right; if he sees the vessels, and if they make an apparent movement toward the left, that is, in an opposite direction, they belong to an image of the fundus inverted and in front of the pupil, and the eye is myopic. If, however, the vessels appear to move with the observer's head, they belong to an image which is upright and behind the pupil, and the eye is hyperopic. In emmetropia or any trifling degree of myopia and hyperopia, the vessels of the patient's eye are not visible at the usual distance because the ophthalmoscopic field is too small (*p. 109*).

To understand the principles of these apparent movements it must be remembered that these images of the fundus are projected by the observer toward the pupil of the patient, whose eye therefore seems to be at rest while the images of the fundus seem to move. That the movement appears to go with the observer's head when the image is upright, against it when the image is inverted, we can understand when we turn to the explanations of the apparent displacement of corneal opacities in front of the pupillary plane, and of lens opacities behind the pupillary plane (*p. 118*). The point *a* (*Fig. 49*) corresponds to the inverted image, the point *c* to the upright image.

Obviously, it does not suffice to have determined whether the patient's far point lies close in front of his eye (strong myopia) or close behind it (strong hyperopia), or at some distance from his eye (moderate myopia, moderate hyperopia, or emmetropia); our task is rather to measure the refractive condition. This can be carried out in three ways, namely :—

(α) by the upright image (the direct method);

(β) by the inverted image (the indirect method);

(γ) by skiascopy (the shadow test).

(α) *The estimation of the refraction by the upright image* is carried out by means of the refraction ophthalmoscope (*Fig. 48*). The emmetropic observer first tries to see the papilla without any lens at all; if he is not successful he introduces successively behind the sight hole of the mirror by revolving the disk a series of concave or convex lenses until he finds the lens with which he can see the patient's fundus most clearly. This lens measures the amount of refractive error present, assuming that neither the observer nor the patient makes an effort at accommodation, and taking care that the distance of the lens from the patient's eye is negligibly small—a condition admissible only in errors of low degree. In errors of high degree a distance of the neutralizing lens from the patient's eye of five or more centimeters is of considerable importance,

Digitized by Illinois College of Optometry

since without taking this distance into consideration myopia might be found too great and hyperopia too small.

Let us take an example. In *Fig. 52*, *Pa* is the patient's eye, and has a myopia of *10.0 D;* therefore luminous rays emitted from the fundus of *Pa* will produce an inverted, enlarged image, *a' b'*, at $\frac{1}{10}$ *m.* = *10 cm.* in front of the principal plane. Let the eye, *Ob*, be *5 cm.* from *Pa;* supposing this observer's eye to be emmetropic and free from accommodation, it will see distinctly the fundus of *Pa* when using a concave lens which makes parallel the rays converging to *b'*, in other words, a lens whose (negative) focus is equal to the distance between *L L* and *a' b'*. If this concave lens is at *1 cm.* in front of the principal plane of *Ob*, that is, *4 cm.* in front of the principal plane of *Pa*, then the focal distance of the lens would have to be *6 cm.* and its refractive power $\frac{100 \text{ cm.}}{6 \text{ cm.}}$ = *16.66*— Diopters; the neutralizing lens is therefore *6.66*— *D* stronger than the myopia of *Pa*.

A corresponding example shows that an emmetropic observer free from accommodation sees distinctly the fundus of an eye of *10.0 D* hyperopia at a distance of *5 cm.* with a convex lens of *7.1 D* placed *1 cm.* in front of the principal plane of *Ob*, that is, *4 cm.* in front of the principal plane of *Pa*. The error is consequently *2.9* Diopters.

Such palpable errors ought not to be made. If they cannot be avoided they can at

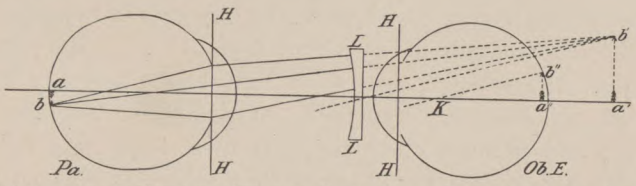

FIG. 52.—EFFECT OF THE DISTANCE BETWEEN PATIENT AND OBSERVER, IN THE ESTIMATION OF REFRACTION BY THE UPRIGHT IMAGE.

least be modified if the neutralizing lens is placed close to the patient's eye, rather than close to the observer's own. Supposing in the above example of myopia of *10.0 D* the neutralizing lens is placed *1 cm.* in front of the principal plane of *Pa*, the lens should then have a focal distance of *9 cm.*, a refractive power of *11.11*— Diopters, in order to give to the emmetropic observer *Ob* a distinct view of the fundus of *Pa*. The error in this case is only *1.11*—Diopters. Since one must thus sacrifice the very advantages peculiar to the refraction ophthalmoscope, it is best, therefore, in cases of high degree of ametropia, to use another method, the shadow test, which, even at the worst, makes an error of only about *1.0* Diopter.

If the observer himself has any refractive error, he must either correct it with a suitable lens during the examination, or make allowance for this error when estimating the patient's condition. In any case he must take the refractive condition of his own eye into account.

Suppose the observer is hyperopic *3.0 D* and finds that —*2.0 D* gives him the best view of the patient's fundus (the lens being at a negligible distance from the patient's eye). The patient must then have a myopia of (—*2.0 D*) + (—*3.0 D*), that is, of *5.0 D;* for in this case luminous rays emerging from the patient's cornea are not made parallel, but are only weakened enough in their convergence to intersect each other at the

(negative) far point of the hyperopic observer, that is, $\frac{1}{3}$ *m.*, *33.3 cm.* behind the principal plane of *Ob*. It would require a concave lens strong enough to overcome this convergence, than is, the lens already found plus a second lens of —*3.0 D*, before the rays could be made parallel; this lens is therefore the real measure of the myopia.

Or suppose the observer with myopia of *3.0 D* sees the fundus of the patient's eye with —*2.0 D*; then the patient has obviously *3.0 D* —*2.0 D* = *1.0 D* of hyperopia; for a myopic observer of *3.0 D*, with lenses of —*2.0 D* is changed to a myope of *1.0 D*. He now sees (without accommodation) everything lying at *1 m.* in front of him. The virtual image of the fundus must therefore have lain *1 m.* in front of the observer (the distance between the two being neglected) or *1 m.* behind the patient. An eye with negative far point of *1 m.* is hyperopic to the extent of *1.0 D*.

A general rule may be thus expressed: If the patient's refractive condition is of a character opposite to that of the ametropic observer, the latter's refractive error expressed in diopters is added to that lens which neutralizes the error found. If the patient's refractive condition is of the same character as that of the ametropic observer, the latter's refractive error expressed in diopters is subtracted from that lens which neutralizes the error found. Suppose the observer is hyperopic, and that, without correcting his own ametropia, he finds the patient to be myopic; the myopia thus found must be increased by the amount of the observer's hyperopia. Or, suppose the observer is hyperopic, and without correcting his own hyperopia finds the patient also hyperopic; the observer then subtracts his own hyperopia from that of the patient. And so forth.

If there is astigmatism, the proper correction for both principal meridians cannot be made at the same time with spherical lenses. The retinal vessels parallel to one principal meridian are sharp, those perpendicular to it are hazy. The astigmatism might now be measured by selecting the lens correcting the error in one principal meridian, and then the lens correcting the error in the other principal meridian: the difference between these lenses would be the measure of the astigmatism present. The lens with which one sees distinctly horizontal retinal vessels measures the defect of the perpendicular meridian. But, unfortunately, retinal vessels are not always so obliging as to run exactly parallel to the principal meridians; therefore we may try to neutralize the astigmatism by means of cylindrical lenses. If we succeed and the proper correction is obtained, the retinal vessels of both principal meridians must obviously be seen with the same distinctness.

This method is warmly recommended by Parent. Ophthalmoscopes provided with cylindrical lenses are, however, very expensive, and the decision as to which is the neutralizing lens cannot always be depended on. Besides, it is most important to remember

Digitized by Google

that the distance of the lens from the principal plane of the patient's eye will be a source of still greater error than that found in the measurement by means of spherical lenses. In any case we possess in the shadow-test a method which is much cheaper and more easily applied than that just mentioned.

It is advisable to combine the examination of the upright with that of the inverted image (Schweigger's method). Any astigmatism, even if it cannot be measured, can be detected thereby with great speed and confidence if it is not too small. The method is as follows: If the optic nerve sheath of the patient's eye is anatomically round, it appears, if the eye is astigmatic, to be an ellipse—an ellipse placed perpendicularly if the perpendicular meridian has the stronger curvature, and an ellipse placed horizontally if, as is seldom the case, the horizontal meridian has the stronger curvature.[1]

If now we use a convex lens [2] to examine an astigmatic eye in the inverted image, the diameter of the image of the disc must appear shorter in its perpendicular principal meridian, because the refraction in this meridian is greater (*p. 109*). The disc consequently appears to be a horizontal ellipse in the inverted image. The conclusion is unavoidable that there must be astigmatism if the shape of the disc is different in the upright image from that in the inverted. Any small departure in the shape of the disc from the circular form in only one method of examination does not warrant the diagnosis of astigmatism, because the disc anatomically is as often egg-shaped as round.

(β) *Estimation of the refraction by the inverted image* (indirect method). This method, developed and particularly recommended by Schmidt-Rimpler, depends upon the following fact: An image, *Fl'* (of the flame, *Fl*), reflected from a concave mirror, *Sp* (*Fig. 53*), will be imaged distinctly on the fundus of an eye only when the location of the image, *Fl'*, and the fundus of the patient's eye are conjugate foci; in other words, when

[1] If this is not at once clear, let the student read the section on "Magnification of the Upright Image" (*p. 107 et seq.*). If even this fails to make it clear and intelligible, the student may make use of an experiment to convince himself of the practical correctness of the statement, at least. For this purpose, let him take from the case of test lenses a convex spherical and a convex cylindrical lens of about $+6.0\ D$ and $+4.0\ D_c$ respectively. He then puts the two together, one over the other, and looks through this meridian-asymmetric system at the optic nerve sheath in *Fig. 51*. He will then notice that the optic nerve sheath, actually round, now appears elliptical, the long axis of the ellipse being perpendicular to the axis of the cylinder; in other words, the long axis of the ellipse lies in the same plane as the meridian of strongest curvature in the meridian-asymmetric system.

[2] The lens must be placed so close to the eye that the anterior principal plane lies within the focal length of the lens.

Digitized by the College of Optometry

the far point of *Pa*, made artificially myopic by a convex lens, *S S*, coincides with *Fl'*. If now the refractive power of *S S* and its distance from the principal plane of *Pa* are kept permanently the same, then the spot where *Fl'* should be thrown in order to produce in *Pa* a distinct *Fl''* depends only upon the refractive condition of *Pa*. If we know the location of *Fl'*, we can determine by its distance from *S S* the refractive condition of *Pa*.

To simplify this determination, Schmidt-Rimpler uses a convex lens of *10.0 D* placed *10 cm.* in front of the principal plane of *Pa*. If the patient is emmetropic, *Fl'* must lie at the focus of the lens, *10 cm.* in front of it, in order to produce a clear image in *Pa*. If *Pa* is myopic, *Fl'* must lie within the focal distance of the lens; and if *Pa* is hyperopic, *Fl'* must lie beyond this focal distance; every centimeter toward the lens indicating *1.0 D* of myopia in *Pa*, and every centimeter from the lens indicating *1.0 D* of hyperopia in *Pa*.

In the practical application of this method the observer must

(1) Estimate at what distance his mirror must be placed in order to reproduce a clear image, *Fl''*, on the fundus of *Pa*, and

(2) Measure where the image, *Fl'*, lies at the instant that *Fl''* is most distinct.

The first problem can be solved only by an observer whose eye is corrected for the

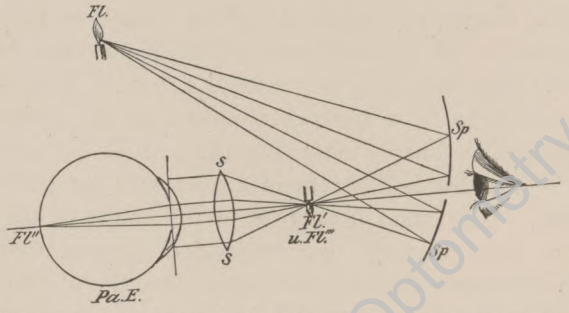

FIG. 53.—SCHMIDT-RIMPLER'S METHOD FOR MEASURING REFRACTION.

location of *Fl'*. The image, *Fl''*, has itself become an object, and therefore reproduces an enlarged, inverted image, *Fl'''*, exactly upon *Fl'*, and—neglecting the intensity of the illumination—coincides with it point for point. Although the observer cannot see *Fl'* because the luminous rays proceed from him, he is able to see the coincident image, *Fl'''*, in case he is dioptrically corrected for the location of it.

The second problem, to find out where *Fl'* (or rather *Fl'''*) lies, is solved in two steps: (1) by measuring the distance of the mirror, *Sp*, from the lens, *S S*, at the instant that *Fl'''* is seen distinctly; and (2) while the distance of the flame, *Fl*, remains unchanged, by throwing the image, *Fl'*, on a screen and then measuring how far the screen must be removed from the mirror in order to make *Fl'* perfectly distinct. The difference between these two distances is the desired distance of *Fl'* and *Fl'''* from *S S*, and gives at once the refractive condition sought.

As is seen, this method is extremely ingenious, but not so very simple. According to Schmidt-Rimpler's experience, it may be learned by any one who can use the ophthalmoscope and who possesses good accommodative power, and it gives as good results as does the examination of the upright image, that is, to within *1.0 D* of error. He advises a small and handy instrument (refractometer), with which the fixation of *S S* at *10 cm.* in front of the principal plane of the patient's eye, as well as the measurement of the dis-

Digitized by the Internet Archive in 2010 with funding from College of Optometry

tance of the mirror from *S S*, is easily determined; also, instead of the ordinary gas flame, he advises the use of some other luminous object whose image admits of the recognition of the smallest errors of accommodation.

(γ) *Estimation of the refraction by the Shadow test. Skiascopy.*

When an observer, *Ob* (*Fig. 54, A, B, C*), sits opposite a patient, *Pa*, and looks at the pupil, *P p*, of *Pa* with proper correction, there is formed on the observer's retina a reduced and inverted image, *P' p'*. All luminous rays proceeding from the fundus of *Pa* through the pupil, *p P*, either do not reach the eye of *Ob* at all, or they strike the

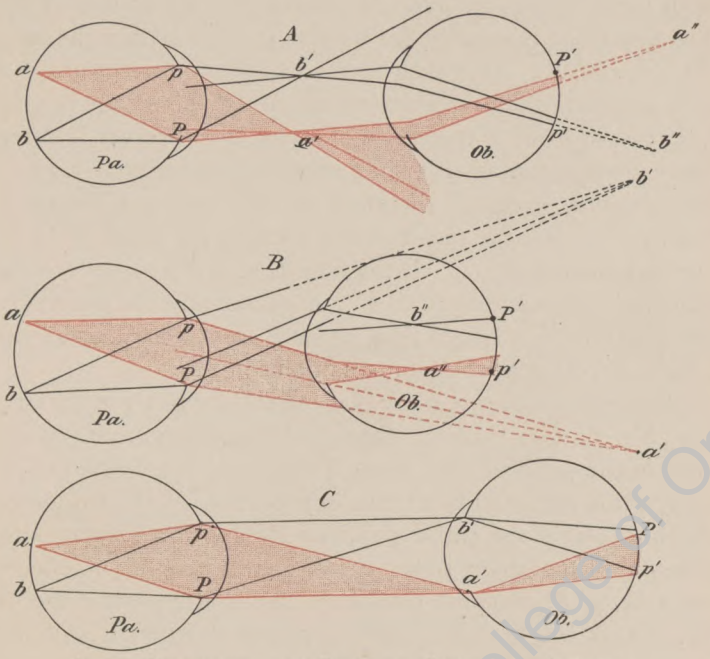

FIG. 54.—ESTIMATION OF THE REFRACTIVE CONDITION BY SKIASCOPY.

fundus of *Ob* between *P'* and *p'*. For example, all rays from the point, *p*, irrespective of whether they come from one point or from several points of the fundus of *Pa*, must unite at *p'* of *Ob*, assuming, of course, that they are intercepted by the pupil of *Ob*. Let there be a luminous point, *a*, on the fundus (*Fig. 54, A*) of *Pa*, and let *Pa* be myopic; then at the far point of *Pa* and on the connecting line between *a* and the nodal point there will be an aerial image, *a'*. The rays diverging from *a'* will in part reach the pupil of *Ob* beyond this *a'*, and in passing through the refractive media will be so united

Digitized by Illinois College of Optometry

that the image, a'', would result if the rays were not intercepted by the fundus of *Ob*. On the upper part of $P'p'$ there is a bright diffusion circle, while the lower part of $P'p'$ remains unilluminated. Now, since our retinal images are projected into the outer world as inverted, *Ob* must therefore see the pupil of *Pa* bright below and dark above. If the luminous point, *a*, in *Pa* descends, say to *b*, its aerial image must ascend to b', and there results a bright spot below in $P'p'$ of *Ob*; consequently the observer sees in the pupil of *Pa* a bright area passing from below upward ↑, when the luminous point in the fundus of *Pa* passes from above downward ↓.

The condition is exactly the reverse if *Ob* is within the far point of *Pa* (*Fig. 54, B*). It is seen that *a* would produce its image at a', but on account of the refractive media of *Ob* this image is really at a'', that is, in front of the retina, because the observer is corrected for rays diverging from pP while receiving convergent rays. The object point, *a*, produces therefore in this case a diffusion circle below at $P'p'$, and the result is that *Ob* sees the pupil of *Pa* bright above and shaded below. If the object, *a*, in *Pa* passes downward, say to *b*, a'' passes upward to b''; consequently the observer sees in the pupil of *Pa* a bright area passing from above downward in the same direction as the luminous point in *Pa*.

And, thirdly, let the pupillary plane of *Ob* lie exactly at the far point of *Pa* (*Fig. 54, C*); then the object point, *a*, produces its image, a', exactly in the pupil of *Ob*. Since the ray, pa', is refracted to p' and the ray *Pa* is refracted to P', the entire area, $p'P'$, is illuminated, and consequently the entire pupil of *Pa* appears luminous to *Ob*. Movement of the object point, *a*, to *b* in this case has no effect; the entire area, $p'P'$, remains luminous, and consequently the entire pupil, Pp, is bright. Not until *a* passes downward still further than *b* does the image, b', lie on the iris of *Ob*, in which condition no luminous ray whatever can reach $p'P'$, and at one stroke the whole pupil, Pp, becomes dark.

If we apply what has been said for one object point, *a*, of *Pa* to the whole field of light, we obtain the following rule for the shadow test: If an observer looks at the pupil of a patient from a greater distance than that of the patient's far point, and if the luminous area in the fundus of the patient's eye passes downward, the observer sees in the patient's pupil a luminous area passing upward, that is, in the opposite direction to that actually taken by the luminous area. If, however, the observer is within the patient's far

Digitized by Illinois College of Optometry

point, then he will see in the patient's pupil a luminous area passing in the same direction as the actual movement of the luminous area in the fundus. Finally, if the pupillary plane of the observer's eye lies at the patient's far point, then the observer sees no movement at all, but a sudden illumination of the patient's entire pupil followed by an equally sudden shadow.

In this we have, then, a method of finding the far point of any eye (free from accommodation) by approaching or withdrawing our own eye to or from the patient's eye, until the movement of the light and shadow in the same direction with, or in the opposite direction to, the movement of the luminous field ceases, and is replaced by an instantaneous change from total light to total darkness.

In order to apply this method generally in all refractive conditions, we must, *first*, be able to establish a common far point at about *30 to 40 cm.* This is made possible by means of the lenses of the oculist's test case. Hyperopia we change into myopia, strong myopia we change into moderate myopia, by concave glasses. We must, *second*, be able to obtain a play of light in definite directions upon the fundus of the patient's eye. This is made possible by means of a lamp and a *plane* mirror. The plane mirror gives a virtual, upright image of a flame lying behind the observer; this upright image becomes an inverted image in the patient's eye. Consequently a downward movement of the mirror image effects an upward movement of the luminous area in *Pa* (*Fig. 54*). If the mirror is turned upward, the virtual image behind the mirror moves downward, while the illuminated area in *Pa* moves upward, a movement in the same direction with the movement of the mirror.

If a concave instead of a plane mirror is used the conditions are reversed; that is, if the mirror is rotated upward, the luminous area on the patient's retina moves downward.

In putting the shadow test into practice the physician sits opposite the patient at about *50 cm.* distance, and asks him to look toward a remote object on the nasal side of the eye to be tested. Then with the plane mirror light is reflected into the eye, and a few movements are given to the mirror to decide whether it is within or without the far point. This is literally the work of a flash! If the pupil is partly dark and partly bright, it is a proof that the pupillary plane of the observer does not lie at the far point of the patient. A movement of the visual area in the same direction as the mirror indicates that the far point is behind the observer; if

Digitized by the Illinois College of Optometry

against the direction of the mirror, the far point lies in front of the observer. In the last case the observer approaches closer, rotating the mirror occasionally, until the light and shadow do not seem to pass across the pupil at all, but complete illumination gives place to total shadow. At this instant, by means of a tape-line already at hand, the distance of patient from observer is measured: a tape divided into centimeters (*100 cm.* = *1 m.*) will show in diopters the amount of myopia present.

If the light and shadow move in the same direction as the movement of the mirror, indicating a far point behind the observer's eye, an effort must be made to reach this far point by receding from the patient, or in case this is impracticable, by placing convex lenses before the patient's eye until the far point is brought nearer. The strength of the lens to be chosen can be approximately estimated by the appearance of the light and shaded parts of the pupil. If there is weak myopia, emmetropia, or weak hyperopia, the pupil shows a flat, circle-like area of light, which changes rapidly with slight movements of the mirror—a lens of $+3.0\ D$ may be tried. If, on the contrary, a high degree of hyperopia is present, the area of light is of smaller diameter and moves slowly with moderate rotation of the mirror—for this try a lens of $+5.0$ to $+7.0\ D$. Whatever convex lens has been used to bring the far point to the convenient distance of *30* to *50 cm.*, it must obviously be deducted in the final estimation. Suppose a lens of $+5.0\ D$ has displaced far point to *42 cm.*; then we have a myopia of $\frac{100}{42} = 2.5\ D$ (approximately), or allowing for the convex lens, we have $(+5.0) + (-2.5) = 2.5$ hyperopia.

The shadow test performs the best service in measuring astigmatism, since in applying it one's attention is often instinctively called to the presence of that condition. Suppose the far point is in front of the observer; he now approaches the patient with slight movements of the mirror upward and downward until he can no longer recognize the direction of the movement on the pupil. He now rotates the mirror toward the right and left; if the horizontal meridian does not have the same refractive condition as the perpendicular, there are still noticeable distinct movements in the shadow—movements in the same direction with the mirror if the far point of the horizontal meridian lies behind the observer, that is, if the horizontal is less myopic than the perpendicular meridian. The movement is against the mirror if the far point of the horizontal meridian

Digitized by Illinois College of Optometry

lies in front of the observer, that is, if the horizontal is more myopic than the perpendicular meridian.

If the principal meridians of an astigmatic eye are not perpendicular and horizontal (they usually are so), we shall notice, when the mirror is rotated around its perpendicular or horizontal axis, an obliquity of the light and shadow in the patient's pupil, making the determination of the principal meridians an easy matter, since the direction of these movements will become parallel to those of the mirror when the latter is rotated in the planes of the principal meridians.

Since the shadow test gives us the far point of the meridian of greatest curvature and the far point of the meridian of least curvature, we see that it shows not only the degree of astigmatism, but also its character; skiascopy, therefore, does better service than keratoscopy. The latter is undoubtedly more accurate, but it measures only one condition, the meridian-asymmetry of the cornea, while skiascopy ascertains the complete error in the eye, whether due to corneal astigmatism, to lens astigmatism, or to a disproportion in the length of the eyeball.

The errors in the shadow test are probably as great as in any other objective method for estimating the refractive conditions.

For an easy application of the shadow test, various ophthalmologists have devised various instruments. In order to make a rapid change of the lenses in front of the patient, some use a wheel in whose edge a series of lenses is placed. Others, in measuring the distance between patient and physician, attach a tape measure to the lenses placed in front of the former. There is nothing in all this essentially necessary, since a plane mirror, a case of test lenses, and a tape measure suffice to carry out the shadow test with all desirable accuracy.

(D) DEMONSTRATION OF DIFFERENCES OF LEVEL IN THE FUNDUS.

The optic nerve sheath does not always lie at the surface of the fundus. A depression in the middle has already been mentioned as the physiological excavation (*p. 124*). But the whole sheath may lie at a greater depth, a condition that is always pathological and of great diagnostic import. The presence of an excavation can be demonstrated in two ways:—

(*1*) *By the phenomenon of the parallax.* For this purpose, look at the inverted image of the fundus and move the convex lens in its own plane upward and downward, to the right and to the left. If an excavation of the papilla is present, we see, when the lens is

moved, an apparent movement of the papilla's edge against the ground of the disc, the edge seeming to be displaced over the ground.

This is illustrated in *Fig. 55*. Let *Pa* be an emmetropic eye with an excavated disc. Then from the point *b* (imaginary in this case), lying in the retinal surface, a pencil of rays (not shown in the figure) will emerge from the cornea parallel; rays from the point *a*, on the contrary, will emerge convergent. The image of *a*, therefore, lies at *r*. If the observer puts a convex lens, *S S*, in front of the eye, the image of *a* is produced at a shorter distance—say at *a'*, and the image of *b*, which otherwise lies at infinity, is now at *b'*. For both images, or rather for their pencils of rays, *b a' r* is the ray of direction. This is changed at once if the lens, *S S*, is displaced—say into the position marked in red. The eye and the lens are now decentered. In each pencil of rays there is a new ray of direction, and these two new rays of direction are not coincident. In the first pencil, whose rays emerge from the cornea parallel to the axis, *d b''*, is the ray of direction; in the second pencil, whose rays emerge from the cornea convergent, the ray passing through the nodal point of the red lens is the ray of direction. Consequently the point *b'* moves to *b''*, the point *a'* to *a''*. An observer who is toward the right, at the pro-

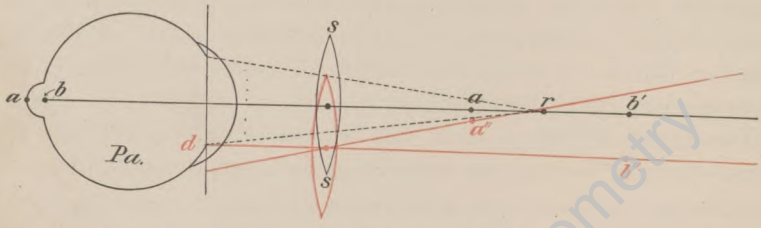

FIG. 55.—DEMONSTRATION OF DIFFERENCES IN LEVEL BY APPARENT DISPLACEMENT OF IMAGES.

longation of *a' r b'*, will see, when the lens is displaced from the position marked in black into the position marked in red, both images also displaced,—*a''*, which is closer to the lens, moving the smaller distance, and *b''*, which is farther from the lens, moving the greater distance. From this we get the impression that *b''* has been pushed in front of *a''*.

This apparent displacement of points lying at different levels depends, therefore, upon the fact that the eye and the lens become decentered, and that the divergence of the two rays of direction increases; the stronger this divergence, the greater the displacement. The degree of divergence is only another expression for the refractive condition of the eye with reference to these two object points, *a* and *b*, in other words, an expression of their differences in level.

(2) *By estimating the refractive conditions of two points lying at different elevations.* This is done by the examination of the upright image. Suppose it has been estimated that the fundus (*Fig. 55*) can be seen by an emmetropic observer (using no accommodation) without a neutralizing lens, and that the point, *a*, is clearly seen only by neutralizing myopia in the patient of —*10.0 D*; there

Digitized by Illinois College of Optometry

is then between *b* and *a* a difference of refraction of *10.0 D*, which by calculation means a difference in depth of *3.47 mm.*

Ordinarily, however, the amount of this difference is not calculated, and we are content to demonstrate the fact that it is present.

IV. MEASUREMENT OF TENSION.

The eye may be termed a sphere with a threefold envelope—the sclera, choroid, and retina—containing within it the lens, the aqueous, and the vitreous. The vitreous is a half-fluid jelly of such a nature as to permit us to consider the eye as a sphere filled with fluid, and, therefore, to speak of the fluid tension of the eye. Under normal circumstances this rises and falls only within moderate limits, but a decided increase or decrease in tension is always pathological, and n the diagnosis of certain diseases is of great significance.

To measure this internal tension in the eye we use either simple pressure with the fingers or a special instrument, the ophthalmotonometer. Pressure with the fingers is conducted as follows: The physician, being in front of the patient, asks him to look downward, and pushes the index and middle fingers between the roof of the orbit and the eyeball until the finger points form something like a wedge, which presses the eyeball downward and holds it fast. The finger points are thus beyond the tarsus and are separated from the globe by the soft parts only. Then the physician plays the finger points as if he were testing for fluctuation in an abscess; the impression of the elasticity thus obtained is compared with the memory of the resistance in normal eyes, or in case only one of the patient's eyes is affected, this is compared with the other. The immediate comparison of one eye with another is desirable, because healthy eyeballs often show quite noticeable differences. For example, the eyes of the young are on the average softer than those of the old. The result of this test is expressed as follows: *Normal Tension* = *Tn*; Noticeable increased Tension = *Tn* +*1*; Decided Tension = *Tn* +*2*; Stone hardness = *Tn* +*3*. Reduced Tension is correspondingly designated as *Tn* —*1*, *Tn* —*2*, and *Tn* —*3*.

It is evident that these signs are just as inexact as the method of measurement itself, and that various observers are by no means always unanimous in deciding whether a certain eyeball may have a normal or an increased tension.

Digitized by the Internet Archive in 2010 with funding from Illinois College of Optometry

There has, therefore, been no lack of experimenting to devise some suitable instrument (**ophthalmotonometer**) by means of which the eye's tension may be estimated independently of any subjective sensation. A whole row of tonometers have been thought out, but no one of them has become a fixture in practice, since they all have given untrustworthy results, the underlying principle being that the power with which an impress of a certain depth could be made on the eyeball would correspond to the tension of the eye. This is a false principle. Undoubtedly, the power necessary to make an impress of a certain depth must be greater the higher the tension of the eye, but we ought by no means to conclude that the tension of the eyeball and the power making a certain impress on it are proportional to each other or in any way equal. Tension on the one hand, and opposing power on the other, are of such a complicated relationship as to defy mathematical expression, let alone an attempt to make use of it as a working basis.

A. Fick has recently been successful in devising an instrument free from theoretical errors, which yields quite trustworthy results. It is illustrated in *Fig. 56*. The tension is taken from the capsule of the eye. Equilibrium can exist only when the strain on any isolated area of the capsule is such that its resultant directed inward neutralizes the internal tension. With equal internal tension the strain on the capsule increases with the radius of curvature of the sphere, because as the sphere becomes flattened there is a decrease in the force directed inward. If the radius of curvature in any part of the capsule were infinitely great, that is, if this part were flat, then no component of the strain would be directed inward, but the whole strain would act tangentially. If, therefore, I press flat any part of the capsule, the internal pressure exerted against this flat part is held in equilibrium solely by the external pressure, and that part of the capsule and the strain upon it do not enter into the calculation. We must try, therefore, to flatten out some part of the capsule whose elasticity is known, by means of some force also known. Then the internal pressure equals in hydrostatic measure the external force, and from the size of the flattened area the internal pressure can be estimated.

The instrument constructed on this principle is illustrated in *Fig. 56*. It is quite simple. A small, flat disk, the tonometer plate, *Pl*, is connected with the spring, *F F*, which is fastened to the standard,

Digitized by the College of Optometry

R R. If this plate is pressed against any resisting body, the spring is bent, and its upper end, provided with a pointer, moves along the scale, *T*, on which every division indicates a pressure on the plate of one gram. The plate is just large enough to carry *1 gram* of mercury *2 mm.* thick. If we press on a scleral area the size of the plate with a force of *10 grams*, that is, with a force carrying the pointer through *10* scale divisions, we know that in the interior of the eye there is a fluid pressure of *20 mm.* of mercury.

FIG. 56.—A. FICK'S TONOMETER.

For this instrument two assumptions are made :—

(1) That no unusual power is needed to press flat an area of the sclera—the atmospheric pressure upon the inner and outer surfaces of the sclera being the same.

(2) That the cubic contents of the eye is not appreciably reduced by the pressure of this plate upon the scleral area.

Both assumptions are admissible, as many trials by R. A. Fick have proved. These were conducted by means of a calf's or a pig's eye emptied of its natural contents and filled with water, and

Digitized by Illinois College of Optometry

then connected with a pressure flask and the manometer, thus obtaining an immediate comparison between the actual pressure and that found by the tonometer. These have all taught us that the results obtained by the tonometer are accurate within very narrow limits. The instrument has proved equally as trustworthy in man. My experience has been that all the results are trustworthy if—

(1) There is no swelling of the conjunctiva, and if—

(2) Two observers on opposite sides of the plate notice that it is accurately adjusted on the sclera.

This last point contains the whole difficulty. If too strong a pressure is applied, a small wall of conjunctiva is elevated at the edge of the plate; if too weak a pressure is applied, a slight crack is seen between sclera and plate; but one observer alone cannot control with his eye at one instant the entire circumference of the plate.

Measurements by A. Fick's tonometer have determined that a normal eye has a tension of *20 mm.* of mercury. I have found in glaucoma simplex a tension of *24* to *34 mm.*, in glaucoma absolutum a tension of *50* to *60 mm.*

Maklakoff has also devised a tonometer on theoretical grounds. It does not, as A. Fick's instrument, give the internal tension of the eye in absolute terms, and is therefore of far less practical applicability than the instrument of A. Fick.

Digitized by Illinois College of Optometry

PART SECOND.

THE DISEASES OF THE EYE.

INTRODUCTION.

The variety of the anatomical structures composing the eye and its surroundings shows very clearly how one may divide the diseases of the eye according to an anatomical scheme. This division cannot, to be sure, be carried out completely, for on the one hand there are diseases which depend not upon changes in the individual anatomical structure, but upon changes of the eye as a whole—errors of refraction, for example, glaucoma, panophthalmitis; on the other hand, there are diseases of the eye for which we are not prepared to give anatomical explanations, as in certain forms of "weaksightedness." Therefore, diseases suitable for anatomical classification must be put into the first group, and the others into the second.

The order of arrangement in the first group should depend upon the system of examination followed by the surgeon.

In a certain sense every examination ought to begin with a short history. The age, calling, earlier diseases, and present symptoms of the patient should be noted. In many, indeed in most cases, they are a valuable signboard for a closer examination, and in their proper place will be referred to again.

The examination begins with a *view of the patient.* After glancing at his face roughly to see whether he looks ill or well, whether there is any eczema on the nose or ears or angles of the mouth, and after the glands of the neck have been felt, the physician turns to the—

(1) *Lids*, and studies the condition of the skin, of the margins, and of the fissure.

(2) *Puncta lacrimalia* and the neighborhood of the *tear sac.*

Not till then does the hand touch the patient; but now the lids are everted (*page 183*) and we examine the

(3) *Conjunctiva* and

(4) *Cornea.* To examine the cornea thoroughly simple observa-

Digitized by Illinois College of Optometry

tion does not suffice; we must make use of focal illumination and the magnifying glass. The same method helps us in examining also the

(5) *Anterior chamber, Iris,* and *Lens.* Finally there follows the

(6) *Ophthalmoscopic examination* of the interior of the eye.

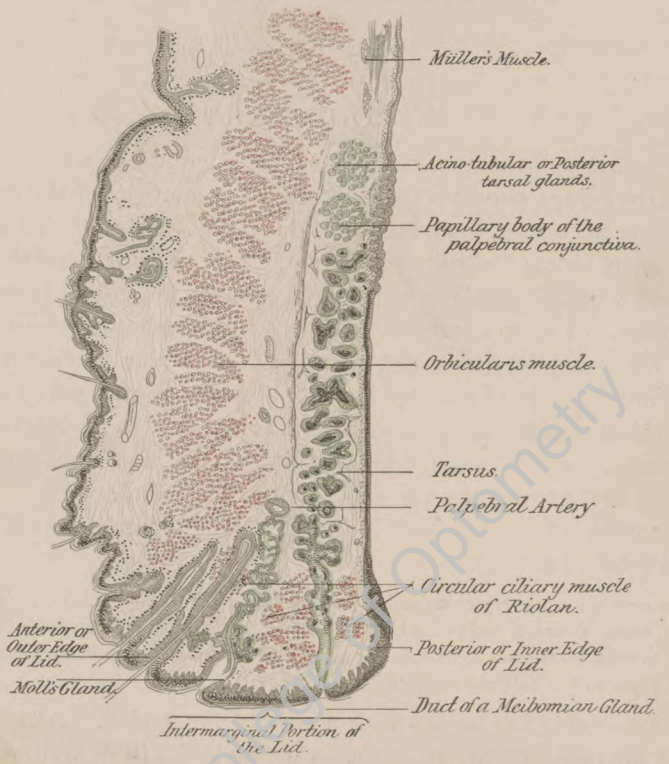

FIG. 57.—SECTION THROUGH THE UPPER LID. (*After Waldeyer and L. Schroeter.*)

A rigid adherence to this procedure will save the beginner many a blunder. How often has it happened that a sore eye is treated with all manner of washes as a catarrh until the patient goes to some other physician, who pulls from the lid the irritating lashes overlooked by the first one, whose attention had been attracted by the redness of the eye itself.

Digitized by Illinois College of Optometry

I. DISEASES OF THE LIDS.

Anatomical Introduction. *Fig. 57.* The eyelid is developed in the embryo from a fold in the skin. During development the inner surface of the lid loses the histological construction of the outer skin and becomes mucous membrane, the *conjunctiva palpebræ*. A plate of thickened connective tissue, the cartilage of the lid, *tarsus*, gives to the lid a certain degree of stiffness. Between this cartilage and the outer skin lies the closing muscle of the eye, *musculus orbicularis palpebrarum*. Between this muscle and the external skin lies a relaxed, elastic connective tissue, poor in fat. Since the skin of the lid is very tender and thin, it is easy for extravasations of blood, effusions of blood and of water (edema), and such like to take place.

The external surface of the lid ends with the rounded-off anterior lid edge; the internal surface of mucous membrane ends with the abrupt posterior lid edge. Between these two lid edges lies the intermarginal space, which is *2 to 3 mm.* broad, becoming smaller toward the angles, especially toward the outer one. Along the posterior lid edge one can often with the naked eye and always with the magnifying glass see a row of about *20* fine points, the exit ducts of the *Meibomian glands*, whose secretion serves to lubricate the lid. The anterior lid edge carries the lashes, *cilia*, the upper lid having *100 to 150*, the lower lid half as many. In the hair bulbs there are little fat glands, some large and some small, the *Mollian glands*, whose exit ducts are at the side of the hair shafts on the intermarginal space. The edges of the upper and lower lids unite at an angle, in the *canthus externus* (*Fig. 64*) and again at the *canthus internus*, which has the shape of a horseshoe, embracing a small mass of metamorphosed skin, the *caruncula lacrimalis*.

The lids in winking act as a moist cloth to wash away all dust, mucus, and tears from the outer to the inner angle into the tear sac, from which everything fluid is conducted through the nasal duct into the nose, leaving everything solid at the inner canthus to be removed as opportunity offers by the fingers or by washing. The lids protect the eye from dryness and from accidental touch by involuntary closure; the lashes of the upper lid form a rake to catch any dust falling from the air.

1. DISEASES OF THE SKIN OF THE LID.

All diseases described in any text-book of skin diseases are occasionally found on the skin of the lid, but I will limit this description to those few having especial interest to the ophthalmic surgeon. We may discuss them, therefore, according to their order in the different layers of the skin.

(*a*) **Herpes Zoster Ophthalmicus.**—This disease is an acute febrile one, and begins as such with general systemic disturbance, prostration, headache, and loss of appetite, followed by chill and a fever. Certain nerves, particularly the nervus supraorbitalis, n. supratrochlearis and infratrochlearis, are painful, the pain growing so intense as to radiate over the entire side of the head. Less often is the territory of the nervus infraorbitalis (second branch of the trigeminus) involved. These introductory pains last some time in one case, a few hours in another, or may even extend over months

Digitized by Illinois College of Optometry

in a third. In the end the skin disease discovers itself in the form of red spots that are confined closely to the territory of the diseased nerve. One or two days later small, watery blisters appear upon these red spots; this fluid becomes richer in cells and more like pus. Finally the blisters dry up, leaving a crust behind, under which, in many cases, a superficial layer of the true skin melts away, so that when these crusts are thrown off, healing takes place with the formation of a scar. The healing of the eruption is by no means the end of the disease, for nerve pains, hyperesthesia, or anesthesia may remain for a long time afterward.

The essential location of the disease is in the nerve itself and that part of the Gasserian ganglion belonging to it; in a few autopsies these have been found in a condition of pronounced inflammation. The cause of the disease is not well known. It is recognized by the eruption along the course of the nerve, it being a particularly diagnostic point that the eruption does not pass the middle line of the forehead and nose. The prognosis is good, assuming that the nerve twigs supplying the cornea are not affected. If they are, the result may be ulcers and scars of the cornea. **Treatment** should be confined to suppressing the pain by morphin, and by powdering the diseased skin area with a mixture of zinc oxid and starch (*Zinc. oxid. 5.0, Amyli 20.0*), in order to hasten the drying up of the blisters. If crusts have formed, they can be softened by borated vaselin or any other mild salve.

(*b*) **Eczema.**—This is a protean disease. It begins as a shot-like, a vesicular, or a pustular eruption. This dries in scales or crusts. Beneath the scale lies the reddened skin, either moist or dry, its tissue being more or less infiltrated, and sometimes superficially eroded or necrosed. The most prominent subjective symptom is itching.

Eczema is seen on the lids in all its manifestations, being as a rule only the continuation of an eczema on the face or about the nose and ears; or it may be the result of some disease of the conjunctiva and cornea which has caused an abundant secretion of tears. Tears have in themselves irritating properties, as may be seen in any case of eyes "red wept." To be sure, the skin is rather more resistant than the mucous membrane of the eyes and nose, but the skin of the lid is much thinner than the skin of the rest of the body, and it is particularly delicate in blond, scrofulous children. When such children rub away with their little hands

Digitized by Illinois College of Optometry

the tears welling up from the eyes, the combination of the softening effect of the moisture with the mechanical effect of the rubbing will easily produce an eczema. Of special interest to the surgeon is that eczema, relatively seldom, I am sure, produced by a wet bandage saturated with antiseptic fluid (sublimate eczema).

The **treatment** consists in protecting the skin and oiling the lids with vaselin or some simple salve. If there are scales they can be gently removed after softening them with warm oil. Moist spots can be protected with a paste of salicylate of zinc (*Zinc. oxyd. 10.0, acid. salicyl. 0.1, Vaselin 10.0*), or with a salve of white precipitate ointment (*Hydrarg. precipitat. alb. 1.0, Vaselin 10.0*). If there is a superficial erosion beneath the scales, painting with a two per cent. solution of nitrate of silver is of value.

(*c*) **Abscess.**—If in addition to the four known signs of inflammation (calor, tumor, rubor, dolor) we find fluctuation as a fifth, there is an abscess. On the lids the signs of an abscess appear in certain diseases quite distinct from each other, but which may be treated by one method. The differentiation into furuncle and abscess is doubtless pathologic, but is only of academic interest to the physician as well as to the patient.

(*a*) FURUNCLE.—The disease begins with a pricking pain, the painful spot being hard to the touch, owing to inflammatory infiltration. The skin is red with a full capillary injection. All this vascular hyperemia and infiltration produces a swelling. The center of the diseased area dies, and is thrown off with a slough of some part of the surrounding surface of the skin, which is replaced by a connective-tissue scar.

Necrosis of a bit of tissue is therefore diagnostic for furuncle. When necrosis attacks a hair sheath with its adjacent sebaceous glands (the cutis itself), we speak of follicular furuncle; if necrosis begins beneath the skin, we speak of cellular furuncle; if the necrosis includes a large section of the skin, we call the disease anthrax or carbuncle. This is always severe and may lead by sepsis of the whole body to death itself. Particularly in the severest form of furuncular anthrax it is usually possible to demonstrate the cause as an infection with an animal poison. An anthrax carbuncle produced by inoculation with anthrax bacilli gives a type of the condition. Inoculation is generally brought about by the dirty hands of the patient himself; an actual wound of the skin is scarcely necessary, since the hair sheaths are, as C. Hueter states, mouths in the skin through which any infection may be carried. Here and there inoculation may be brought about by the bite of insects that have settled on diseased cattle or any other infectious object. It may be added, too, that many tropical insects carry in themselves such a strong (chemical) poison that their bite or sting can produce a furunculous inflammation. In our country the greatest evil of this kind is the sting of bees or wasps, which can lead, however, to no more than a severe inflammatory swelling.

The majority of furuncles are at the edge of the lid, and will be spoken of later under hordeolum, though there are, less often, however, genuine furuncles on the skin itself.

(*β*) PHLEGMON, PSEUDO-ERYSIPELAS.—Lid abscess in its narrower sense is most usually seen in children, and generally appears on the upper lid. The lid is hot, red, and painful. A spot, at first hard, but later softer, assumes after a few days a yellow color, and finally points with escape of pus. The diagnosis from furuncle lies on the one hand in the absence of necrosis, and on the other in the more diffuse character of the diseased process, and in the more apparent evidence of fluctuation. It is scarcely possible to draw a distinction between cellular furuncle and abscess. A lid abscess results generally from injury, especially a bruise; but how the infecting germs obtain entrance beneath the skin cannot always be demonstrated.

Prognosis of furuncle and abscess depends upon the nature and amount of infection. As we cannot estimate this circumstance, we must judge by the appearance and size of the area involved.

Treatment consists in making an incision as early as possible and with antiseptic precautions, a removal of diseased tissue, and an antiseptic bandage.

(*d*) **Hemorrhage, Hemophthalmos externus.**—A hemorrhage into the lid depends—

(*1*) Upon an injury to the lid itself or to the adjacent tissue.

(*2*) Upon injury to remote parts, and

(*3*) Upon a general dyscrasia, scorbutus, for example, where there is no actual rupture of any vessel, the blood corpuscles merely escaping through the uninjured but abnormally relaxed vessel wall.

If a blood-vessel in a lid is ruptured a large quantity of blood may be poured out on account of the yielding nature of the tissue. The lid appears bluish-red or black, and the swelling is so great that the patient practically loses the use of his eye. Laurence says that in the ordinary fist fight of Englishmen the seconds are accustomed to make occasional incisions into the puffy lids of the fighters and to squeeze out the blood, so that the fight may proceed.

The *first* kind of hemorrhage can be caused

(*a*) By a dull instrument.

(*b*) By minor surgical operations or by leech bites in the vicinity of the lids, or

(*c*) By rupture of a blood-vessel by severe coughing, sneezing, or vomiting.

Digitized by the Southern College of Optometry

The *second* kind can be caused by fracture of the skull. For example, a fracture of the roof of the orbit, or of the base of the skull, may lead to a hemorrhage into the cellular tissue of the orbit. This blood becomes visible in the conjunctiva of the eyeball and on the inner surface of the lid, and shows itself on the outer surface only when it has passed through the tarso-orbital fascia—the tissue connecting the lid with the circumference of the orbit.

The *third*, hemorrhage by diapedesis, has no real interest for the ophthalmic surgeon.

If a patient is seen with a "black eye" which he cannot open on account of the swelling, it is of first importance to determine whether or not the eyeball is injured. If it is not, then treatment is scarcely necessary; the blood will disappear of itself in two or three weeks after having assumed various shades of color. If the patient insists on treatment, lead water compresses and a pressure bandage may be prescribed.

FIG. 58.—DESMARRES' LID ELEVATOR.

(*e*) **Edema.**—The lids are the favorite seat for any fluid deposits, and they may become so abundant that the patient finds it impossible to open his eyes, and he is much distressed thereby. The most significant sign is the persistence of a small dimple when the swelling is gently pressed by the point of the finger. These collections of lymph in the skin and the tissue beneath it are only in part of an inflammatory nature. When they are so they must be considered as indicating a local disease. For example, a lid edema is a regular accompaniment of a furuncle or abscess, and disappears very quickly when exit is given to the pus. Again, lid edema is a very grave sign when there is an inflammation of the conjunctiva or bulb or of the cellular tissue of the orbit. Since it is generally painful and sometimes mechanically impossible to open the lids when an inflammatory edema is present, the significance of such an edema is often incorrectly interpreted. It is a good rule to follow, therefore, first to feel of the lid itself—a hard and particularly sensitive spot indicating furuncle or abscess; then to open the lids, if necessary, by means of a Desmarres' lid elevator (*Fig. 58*).

In case the edema can be traced to some disease of the lid, the

Digitized by Illinois College of Optometry

conjunctiva will be only slightly or not at all inflamed, the eyeball normal and easily moved. If, on the other hand, the edema is of graver significance, the conjunctiva is found inflamed and swollen, the deep vessels of the bulb are injected, the bulb itself prominent and scarcely movable. (The significance of this sign will be discussed later.)

Non-inflammatory edema is also as a rule a sign of disease, though the disease may not always be so easy to find. In some cases the edema must be called the disease itself. If a patient is seen with edema of the lids for which no local cause can be found, search must be made for some disease of the heart, kidneys, or liver. The general dropsy of kidney disease shows itself with particular preference on the lids; a light edema, after scarlet fever, for instance, being a hint for the physician to think of scarlet fever nephritis. Again, a lid edema may be a sign of trichinosis, appearing toward the end of the first week of the disease.

It is scarcely necessary to treat a lid edema locally after some cause has been discovered, but in cases where the edema must be called idiopathic we may use a pressure bandage and massage or, at the worst, an excision of small strips of skin.

A swelling of the under lid and cheek, little if at all painful, may appear after sounding the lacrimal passage and washing out the tear sac—an indication that one must go to work the next time with a little more care. If pain is complained of, hot applications should be used, but otherwise treatment is superfluous.

(*f*) **Emphysema.**—Puffiness of the lids may also be caused by air, the presence of which beneath the skin may be recognized by a peculiar crackling when pressed by the finger and by the absence of lasting depression afterward. The majority of these cases (by no means common) are produced artificially. It sometimes happens that a false passage is made when probing the nasal duct; if the patient blows his nose soon afterward he may force air through the small opening into the subcutaneous tissue. But the physician is not guilty of all cases of emphysema of the lids. Some result from a fracture which opens a communication between the air spaces of the nose or of a neighboring sinus, and the orbit.

Treatment of emphysema need be only palliative; in any case the patient must be warned against blowing his nose too strongly.

Chromidrosis.—This disease is not common and is found nearly always in women and girls. It is characterized by the appearance of blue blotches on the skin of the under lid. The color cannot be

Digitized by Illinois College of Optometry

wiped off while it is dry, but with oil or glycerin it may be removed; after a few moments it reappears, however. The cause is obscure. In many cases it has been demonstrated that the patient herself has smeared the coloring matter on the skin. In others a pathological change in the glandular secretion has been assumed.

2. DISEASES OF THE LID EDGE.

(*a*) **Seborrhea** (*Blepharitis simplex, Blepharadinitis*).—The patient complains of itching and burning—which is increased by smoke, dust, heat, continued reading, or night work—and that the eyes tire easily. The edges of the lids are somewhat reddened and thickened. Close to the lashes the skin is covered with a yellowish matter or with crusts and scales. In the first case the *seborrhea* is called moist, *fluida;* in the second, dry, *sicca.* If this moist or dry material is removed the skin is found covered with epidermis of only the thinnest structure, the exposed spots being red and shiny. The disease depends upon an abnormally abundant secretion of the sebaceous glands, four of which find exit at each hair-bulb. The lashes may even disappear, a condition especially distressing to women on cosmetic grounds. The disease is said to accompany general disturbances of the sexual organs, and Michel adds syphilis also.

Treatment consists in a radical removal of the fat or scales and crusts by washing with soap and warm water, a proceeding much simplified by softening them with a mild salve beforehand. When the lid is thus cleansed, an astringent salve should be used (*Zinc. oxyd. 1.0, Vaselin 10.0*); Horner recommends sulfuretted mercury (*Hydrarg. sulf. bas. 0.1, Vaselin 6.0*).

A patient will often complain that the eyes are sensitive, that they feel red and swollen, although there may be no fatty accumulation or crusts visible. This condition must be designated hyperemia of the lid edge, a diagnosis to be used sparingly and only with a mental reservation; for, as a rule, there is behind it some refractive error, hyperopia or astigmatism, or some conjunctival inflammation with an incipient blepharitis ciliaris.

(*b*) **Eczema** (*Blepharitis ciliaris seu simplex, Blepharitis ulcerosa, Blepharitis hypertrophica*).—The protean character of eczema, the abundance of hairs and glands at the edge of the lids, the greater or less extent of the disease, all cause various pathological pictures to be grouped together under the name of eczema.

Let us study first the picture of a simple *blepharitis ciliaris.* On several parts of the lid edge the lashes are found matted together into a pointed mass embedded in a yellow crust. If this crust is

Digitized by Illinois College of Optometry

raised by means of a ciliary forceps, *Fig. 59*, preferably from the edge upward, a thin yellow pus will ooze out. If the whole mass with some of the hairs be completely removed, a red, moist area will be seen, indicating that the epidermis has been lost. If the lids in such a case are neglected or badly treated, or if the condition is progressive, the disease extends to the entire edge, or perhaps all four edges are involved. The whole lid becomes red and swollen. The crusts from which the hairs protrude in a mass are thick and often colored brown with dried blood, while beneath them are seen yellow pus points partly covered by epidermis. If pus and crusts are removed, moist, bleeding, flat, or sunken areas are exposed along the edge of the lid—a condition called *blepharitis ulcerosa*, or *eczema pustulosum*, which, after continued treatment, may result in the condition known as *blepharitis hypertrophica*, corresponding to the final stage of the disease, *eczema squamosum*. The edge of the lid is now found red and thickened, covered by scales and crusts, while here and there can be discovered a crust, a spot either moist or dry, but showing a young and delicate epidermis, the picture, therefore, of a *seborrhea*.

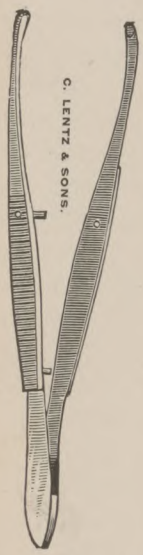

FIG. 59.—CILIARY FORCEPS, WITH TWO SMALL FLAT SURFACES FOR SEIZING THE HAIRS.

Blepharitis ulcerosa leaves in its trail various sequelæ, the commonest being an irregularity in the number and position of the lashes. Many of the hairs are entirely destroyed by suppuration of their bulbs, while others are so displaced into a false direction by the scar that they scratch the cornea, and these may escape the physician's notice, since they are smaller and lighter in color than normal hairs. This condition is called *trichiasis* (*p. 153*). The intermarginal space may be completely lost, so that the conjunctiva is drawn up to the skin by the contraction of the scar. The lids then always remain red—ectropium conjunctivæ. If the changes due to the scar are very pronounced, the result may be an entropium of the upper lid and an ectropium of the under one.

Children in particular, and especially blond ones, are attacked by an eczema of the lids. Seborrhea of the lid edge manifests a tendency to blepharitis in the same sense as do all diseases of the

Digitized by Illinois College of Optometry

conjunctiva and cornea associated with an abundant secretion of mucus and tears. The last-mentioned condition may be accounted as one cause of blepharitis, since the mucus and pus of the conjunctival sac always contain a choice collection of bacteria, so that the macerating and inoculating effects of a conjunctival secretion go hand in hand. It is easy to understand that dirty children are very open to attacks of blepharitis. Lice of one kind or another may also cause it. Whether the ordinary blepharitis is due to a bacillus of its own is not as yet capable of demonstration.

Widmark, in each of twenty-five cases, has detected the staphylococcus pyogenes. This is obviously no proof that these bacteria are the actual cause of the disease, and it is still less a proof that other bacteria may not produce the clinical picture of a blepharitis.

The prognosis of simple and of hypertrophic blepharitis is favorable ; that of the ulcerous form doubtful or even unfavorable. In any case the disease, even with proper treatment, will last for weeks, the ulcerous form for months.

Treatment consists in removing all scales, crusts, and pus, in encouraging a growth of new epithelium over the ulcers, in protecting the places already healed from further irritation, tears, dirt, etc., and finally in removing such results and conditions as thickening of the lids, trichiasis, and so forth. The first object can be most gently accomplished by means of a bit of cotton saturated in warm water or in a sublimate solution (*1 : 5000*) ; whatever is adherent should be patiently pulled off by means of forceps. With the same instrument the little pus points should be opened, and the cilia glued down by the pus will often come away at the same time. Many surgeons consider it necessary to pull out every hair having a diseased root, but I have rather followed Horner in avoiding a routine epilation.

For the second object, we have numerous applications at our disposal. I apply as a rule *Pagenstecher's "yellow ointment,"* using at the same time massage to the lids if there are no ulcers. If ulcers are present, however, I paint the moist areas or little pits with a two per cent. solution of nitrate of silver every alternate day. A thin scab then forms over them which is too adherent on the following or intermediate day to be removed without injury; on this day, therefore, I use only massage with the yellow ointment.[1]

[1] Yellow ointment is prescribed as follows :—

Hydrarg. oxydati flavi via humida parati, ... 1.0
Vaselin, ... 10.0

In spite of the amount of mercury it contains, the salve is very well borne. It is

For the third object, the treatment of any disease of the conjunctiva or cornea is of the greatest importance; during which treatment any healed places should be covered with a protecting layer of fat (yellow ointment). The treatment of the sequelæ will be discussed later; it suffices to mention here that massage is of good service in overcoming any thickening of the lids. In any case they may be painted with the tincture of iodin, although caution must be observed lest a drop or so escaping into the conjunctival sac cause a painful smarting. The rather common relapses of blepharitis can be best guarded against by continued massage to the lids with yellow ointment.

Ulcer.—The abundance of glands at the edge of the lid, the thinness of the epithelium, and the habit man has of rubbing the lids with the fingers whenever the eye itches, not to mention the dreadful custom in some parts of the world (Russia and the South of France) of licking foreign bodies from the conjunctival sac of a sufferer, all these can be accountable for the fact that occasionally ulcers are found at the edge of the lid which appear as a rule only on other parts of the body. Among these the hard *chancre* must be mentioned, its appearance being the same as it is elsewhere. The diagnosis demands the evidence of an opportunity for infection as well as the cartilaginous hardness of the edge of the ulcer, the swelling of the lymph glands in front of the ear, at the angle of the jaw, on the neck, with signs of syphilis on other parts of the body, and in doubtful cases the success of a specific treatment.

Vaccination pustules are sometimes found at the edge of the lid. They may be developed in the intermarginal space from small, superficial pus vesicles having a diphtheritic appearance and accompanied by a severe swelling of the inner and outer portion of the lid (chemosis and edema). In three of seven cases reported by Schirmer, the cornea was attacked. It may be mentioned incidentally that the cow-pox pustule with its central indentation is sometimes seen on the skin of the lids, being, of course, much less frequent than those formed by small-pox in the intermarginal space, where the virus seems to attack a delicate epithelium even if the surface has not been injured. In spite of its threatening appearance, this generally runs a favorable course, healing taking place without an appreciable scar. *Treatment* should be rather negative, iodoform and a bandage sufficing in all cases. Cancer is referred to on *p. 165*.

(*c*) **Hordeolum** (*Stye, Acne*).—This disease attacks young people principally. It begins with a pricking pain at the edge of the lid, accompanied soon after by a swelling of the whole lid, which, in case the upper lid is the one attacked, may prevent the eye from being opened. If the swollen and reddened lid is stroked with the finger a hard spot will soon be discovered which makes the patient wince when it is touched. This place should now be observed with greater care by raising the lid from the eyeball, when a yellow

affected by light so that it changes from yellow to black. It is best, therefore, to keep it in some non-transparent vessel with a good, well-fitting cover.

Digitized by Harvard College Library

pus point will be seen lying either at the anterior or posterior margin. As soon as this little point is opened and the pus released, all the signs disappear and the disease is over, assuming that the same process has not begun anew at some other place.

A pronounced swelling of the lid may mislead the physician into making a diagnosis, say, of an incipient blenorrhea. The evidence of a hard spot on the edge of the lid and the condition of the conjunctiva of the globe are contra-indications, however. The conjunctiva may, of course, be occasionally swollen with a simple stye, but in this case it appears rather pale and transparent instead of red and raw, while the fluid secreted by it is watery and light colored.

This disease, like acne of the skin in general, depends upon inflammation and suppuration of a hair-bulb and the adjacent sebaceous gland; or if it has its seat on the posterior lid margin, it depends upon suppuration of a Meibomian gland—a rather unusual occurrence. It is perfectly justifiable to consider the disease as originating in an infection from without, although this has not yet been proven; but the fact that styes occasionally appear after massage of the eyes, is an indication that bacteria may, by mere mechanical rubbing, be driven into the open ducts of a gland. The tendency of many otherwise healthy people to have styes may be explained by assuming that in them the ducts of the glands are very patent, or that the character and quantity of the secretion from the glands are particularly favorable for the cultivation of bacteria.

Treatment, especially when no pus can be seen, should begin with dry heat[1], which not only lessens the pain but will sometimes even abort the disease. If pus is seen it must be let out. To prevent a recurrence, cleanliness and disinfectants should be advised. For my own patients I prescribe a morning and evening bath to the eyes with lukewarm sublimate solution (*1 : 5000*). In addition a sulfur salve (*Lactis sulfuris 1.0, Vaselin 10.0*) should be rubbed on the edges.

(*d*) **Trichiasis.**[2]—This name is applied to an unnatural position

[1] Dry pocket handkerchiefs heated in an oven or by holding against a clean kettle filled with boiling water will serve the purpose.

[2] In many text books trichiasis and distichiasis are treated of together. But the normal lashes of the upper lid are not arranged in rows and series; they are rather planted by threes and fours in the anterior lid edge. It happens, therefore, that that bit of skin carrying the lashes appears so divided that a double row of lashes may be spoken of. This subdivision has, however, nothing pathological in it.

Digitized by Illinois College of Optometry

of the lashes, in which they are directed inward toward the eyeball. The patient complains that something is scratching his eye, that "something is in the eye," that he has caught cold; or he may make the correct diagnosis of "wild hairs." Inversion of the lashes causes an irritation: close inspection may unmask a simple conjunctivitis, or a corneal ulcer, or even a pannus. Inverted lashes may be easily overlooked, since they are, as a rule, thinner and lighter colored than their healthy neighbors. According to Michel, the best method for discovering these hairs is the following: cover the eyeball with a thin sheet of fluid to the level of the inner edge of the lid; in the normal condition a regular reflex is caught from the surface of the fluid, but if any hair out of line dips into it, the regularity is destroyed. Corroborative evidence is furnished by a magnifying glass with oblique illumination. Even the thinnest hair ought, in this way, to be detected.

An inversion of one or more lashes is usually the result of an earlier inflammation of the lids, although trichiasis may be present with no history of preexisting disease, particularly among people who, according to Michel, are at work in an atmosphere laden with dust.

Treatment consists in pulling out the inverted hairs with ciliary forceps. In many cases this alone is enough, but in others a new hair grows in the same false direction and demands a repeated resort to epilation, a proceeding unpleasant both for patient and for physician. An effort should be made, therefore, to prevent this new growth by destroying the hair bulb. The best method, but a painful one, is the continuous electric current, using at the kathod a needle which is driven into the bulb, while at the anod is a disk resting on the temple. The current should be applied about half a minute. As every hair bulb must necessarily be destroyed by itself, this method is obviously applicable only when the trichiasis is reasonably limited. If, as is not seldom the case, the trichiasis is associated with a dislocation of the whole lid—entropium—resort must be had to the methods explained on *p. 162*.

3. DISEASES OF THE TARSUS.

Chalazion.—The patient visits the physician rather on account of the displacement caused by the chalazion than because of the slight irritation proceeding from it. A chalazion is a roundish tumor of the size and shape of half a pea, the convex side being

Digitized by Illinois College of Optometry

toward the skin, the flat side toward the conjunctiva. The skin covering it is movable and normal in appearance; the conjunctiva, on the other hand, is reddened and often, indeed, spongy, looking as if a piece of red velvet were stuck to the inner surface of the chalazion. If the tumor is taken between the fingers it will be noticed that it is tough, insensitive, and movable only with the cartilage; we have then obviously a tumor arising from the tarsus itself. It is not uncommon for a patient to have several of these small tumors, even on one lid. The disease is a chronic one and may, if untreated, continue for years in an unchanged condition.

The anatomical examination of chalazion does not, in all cases, give the same result, wherefore many authors, along with Michel, distinguish between atheroma and chalazion—a differentiation that is of little importance to the physician. Horner thus describes the structure of a chalazion: the outer shell of the tumor is composed of a dense whitish layer derived from the tarsus; the inner surface of this capsule being supplied with a layer of granulation tissue, which embraces a space filled with a fluid mass of pus cells and cholesterin. In other cases this hollow space is lacking, and the tumor consists entirely of granulation tissue.

Opinion is still divided as to the essential character and cause of chalazion. Tangl is responsible for the most modern view, that the condition is one of local tuberculosis. The benignity of the disease, however, seems to contradict this. Deutschmann, after examining several tumors, is strongly of the opinion that chalazion is not of tubercular origin. The question would seem to be still open to dispute.

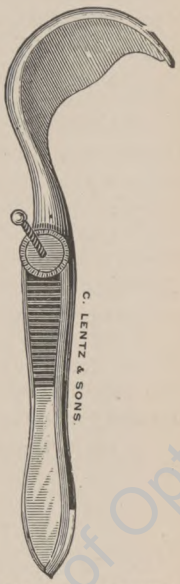

FIG. 60.—ENTROPIUM FORCEPS FOR THE UPPER RIGHT LID. The disk is placed beneath the lid, and the arm is screwed down upon it, the skin being embraced between the two.

Treatment consists in excising and curetting the tumor. The pain of the operation can be overcome by cocain (*cocain. muriatici 0.25, aquæ dest. steril. 5.0*, a drop in the conjunctival sac every minute for five minutes), especially if it is performed on the conjunctival side. When the conjunctiva is incised, curetting ought to be the only procedure, and excision with scarification should be avoided, as entropium may result. The tumor is reduced in size by this method, but is not completely extirpated, and several weeks are

Digitized by the Los Angeles College of Optometry

required before it entirely disappears. If the operation is performed from the skin side, the tumor can be at once completely removed. In this method it is well to use special forceps (*Fig. 60*) to avoid hemorrhage. An incision is made in the skin parallel to the edge of the lid down to the capsule of the chalazion, from which a good-sized piece is taken; then the hole is curetted with a sharp spoon and the wound in the skin is sewed up, although this last is scarcely necessary.

Lithiasis Palpebralis (*Chalazion Terreum*).—In old persons there are sometimes found little yellow points about the size of a pinhead on the inner surface of the lids; these may or may not be the cause of slight irritation in the eyes. The contents of these little points consist of carbonate of lime and cholesterin. They are situated in the exit ducts or the expanded lobes of the Meibomian gland. The only treatment is to clean them out.

Tarsitis.—An acute idiopathic inflammation of this cartilage is extremely rare. Michel states that a subacute or chronic tarsitis is more frequent, occurring in children between seven and ten years of age, as the result of scruphula or syphilis, and always on the upper lid. This droops somewhat, cannot be easily elevated, and is very sensitive. as may be noticed when the attempt is made to turn it over. The cartilage is thickened, harder than normal, and its sharp outline is lost. The skin is normal but the conjunctiva is reddened. *Treatment* consists locally in wearing constantly emplastrum hydrargyri spread on linen, with general medication to overcome the dyscrasia underlying it.

My experience is that the following disease is not unusual: The upper lid is reddened, thickened, and droops. If it is everted, there are seen one or more spots, somewhat less than the size of a pea, shining through the reddened conjunctiva. An incision releases pus, and if this area is curetted, a prompt cure is the result.

In the section, "Diseases of the Conjunctiva," the method of everting the lids is explained.

4. MALPOSITIONS OF THE LIDS AND LID EDGES.

(*a*) Narrowed Fissure.

The normal palpebral fissure is in adults *26* to *28 mm.* long and about *1 cm.* wide (high), but in any one case the measurement may be above or below this average, and the fissures of the two eyes may not be of the same dimension. If the fissure is narrower than the average, the laity speak of "small eyes;" if wider, of "beautiful large eyes;" and if, by any diseased condition, the fissure becomes narrowed, the laity speak of "the eyes growing small."

An actual narrowing of the fissure is distinguished as *ankyloblepharon*, or *blepharophimosis*. A phimosis indicates that a perpendicular fold of the skin covers the external angle. If this is drawn away from the eye toward the temple, the lid edges appear normal and the fissure is of the normal size. This condition results from a contraction of the skin of the lid after a long-continued conjunctival catarrh. This is especially so when the flabbiness of the skin in old age favors such a formation from the skin of the temple.

Digitized by the New College of Optometry

Ankyloblepharon denotes an actual growing together at the external angle of the lids. The condition is occasionally congenital, but is often the result of a burn, or of some ulcerative disturbance at the outer angle.

A fissure may seem to be too narrow when the upper lid droops, the so-called **ptosis.** There may be various causes for this condition: chalazion, abscess, edema, hemorrhage, and inflammation of all kinds may weigh down the upper lid so that even a strong effort of the will is not sufficient to raise it. The same is true in *ptosis adiposa*, a condition in which a relaxed fold in the skin becomes filled with a yellow, fatty tissue, and therefore causes the lid to droop, and may possibly press the lashes against the eyeball. Ptosis may result, moreover, from an injury to the levator palpebræ, and from a paralysis of the sympathetic nerve, or of the oculomotor. The oculomotor nerve supplies the levator palpebræ superioris and the sympathetic supplies the so-called Mueller's muscle (*Fig. 57, p. 142*). It is easy to distinguish which of these two muscles is the inactive one, since in a complete or partial paralysis of the striated levator palpebræ the patient, even with the greatest effort, cannot possibly open the eye to its normal width, but if the unstriated Mueller's muscle is affected, the ptosis is apparent only during involuntary movements, since by a decided effort of the will the healthy levator, acting alone, is able to open the fissure completely. Ptosis, again, is sometimes congenital (acquired perhaps during labor).

One cause for a seemingly too narrow fissure is a cramp or a contraction of the muscle that closes the eye—the orbicularis palpebræ. There are clonic and tonic spasms. A clonic spasm is often nothing but a repeated and unnatural involuntary winking—*nictitatio:* but during the intermissions the muscle is not completely relaxed, and therefore the fissure appears narrow at all times. In other cases contractions in individual fibers of the muscle produce a like condition, though obviously this narrowing of the fissure is not a symmetrical one. Such clonic spasms, so-called "fibrillary contractions," appear in many persons after the use of eserin. In other cases they indicate exhaustion from excesses, such as continued drinking and other weakening influences. Finally, an unnaturally frequent winking may often be found in school children. Here the indication is of some disease of the conjunctiva, doubtless connected with error of refraction.

Digitized by the College of Optometry

A tonic spasm, especially if it attacks both eyes, as it usually does, is much more serious than a clonic spasm. The patient is blind as long as the spasm lasts, and is often embarrassed if not endangered thereby. A tonic spasm of the orbicularis—*blepharospasmus*—is generally of reflex origin from irritation to a conjunctival or corneal nerve, by a foreign body or an inverted eyelash, a phlyctenule or an ulcer. In the minority of cases a cause for the spasm cannot be found on the eye itself; the whole extent of the trigeminus must then be explored, as experience has taught that a hollow tooth, or a scar pinching a terminal nerve, or even an ulcer on the mucous membrane of the mouth, is capable of producing such a reflex spasm. If nothing objective can be found, "pressure points" must be looked for, that is, areas where moderate pressure by the finger on a branch of the trigeminus produces a temporary

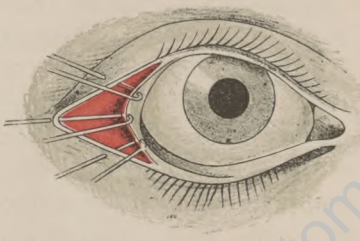

FIG. 61.—AMMON'S CANTHOPLASTY.

cessation of the spasm. In many cases pressure on the facial nerve at its exit from the styloid foramen is said to stop the spasm, since this nerve supplies the orbicularis palpebrarum. A spasm may also be of central origin.

Treatment *of ankyloblepharon* consists of an operation called *canthoplasty*. The adhesions are separated by a horizontal incision, leaving a wound with a *V*-shaped surface (*Fig. 61*). Suitable sutures, as shown in *Fig. 61*, provide for proper union and prevent readhesion in the old form.

Blepharophimosis can be corrected by cutting away a perpendicular fold of skin from the temple near the external canthus; after stitching the edges of the wound together, the redundant tissue will disappear.

Treatment *of ptosis* will depend somewhat upon the efforts of the patient, since he can, by means of the temporal muscle, draw up

Digitized by the Internet Archive for Optometry

the skin of the forehead and the lid connected to it; of course, the wrinkles of the forehead are perceptibly increased in size. Another device of the patient is to throw his head back. The physician directs his treatment to the cause of the ptosis. If there is any inflammation of the lids or of the eye, the ptosis itself needs no treatment, but if it is a sign of an oculomotor paralysis or of an incipient tabes dorsalis, treatment must attack the disease at the bottom. The ptosis itself may be treated ut aliquid fiat by the galvanic current, by strychnin injections, or by various local applications. If the lid droops so that vision is interfered with, a small spring appliance of gold wire may be used, which presses gently into a fold of the skin with only strength enough to elevate the lid, but not enough to prevent its closing. This lid elevator is the device of Dr. Adolf Meyer, of Wuerzburg, who successfully overcame his own ptosis by its aid.

Operative interference may be called for. One of the many operations consists in cutting away a horizontal fold of skin. In ptosis adiposa this is generally successful, but the fat presenting in the wound must be removed at the same time. Another operation consists in catching up a horizontal fold of skin by permanent silver sutures. A third proposes to excise a portion of the orbicularis muscle with the hope of weakening it, at the same time shortening the lid perpendicularly, without the loss of any skin. A fourth device is to excise part of the tarsus and to advance the tendon of the levator palpebræ superioris. It is obvious that this last operation can be successful only when the levator is not completely paralyzed. A fifth operation, theoretically the most practicable, consists in suturing the tarsus to the temporal muscle so that the function of elevating the lid is thrown upon it.

Treatment *of spasm* must likewise attack the cause. When one cannot be discovered, the spasm is called "idiopathic," and we must comfort the patient with long-continued galvanic treatment, using a weak current with the positive pole on any discoverable pressure point, and the negative pole to the back of the neck. The application should be made every day or every second day, two or three minutes at a time.

(*b*) **Widened Fissure.**—The opposite to ankyloblepharon may be caused by any cleavage in the external canthus. In many cases after an injury, union is not perfect, especially if the wound was not exactly horizontal but extended rather downward and outward,

Digitized by the Illinois College of Optometry

severing the orbicularis fibers—a disaster that may occur at any part of the muscle. The resulting disfigurement is quite distressing. Epiphora is occasionally an unpleasant accompaniment.

A much commoner cause of an enlargement of the fissure is the protrusion of the eyeball from its socket, a condition called *exophthalmos*, or "pop-eye" (see the chapter on "Diseases of the Orbit"). In a mild degree this is noticeable after strabismus operations, such as advancement or retirement of a rectus externus or internus, or in myopia due to a long axis of the eyeball. A higher degree of exophthalmos is one of the regular signs of Basedow's disease (*exophthalmic goiter*). A most pronounced type follows corneal staphyloma, or tumors behind the eyeball. In such cases the lids cannot close completely over the eyeball even by a supreme effort, a condition called *lagophthalmos*. As will be explained in the chapter on diseases of the cornea, there is the greatest danger to the

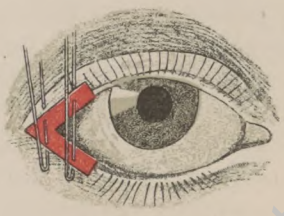

FIG. 62.—TARSORRAPHY.

eye from this condition. Lagophthalmos may arise from still another cause, a paralysis of the facial nerve that supplies the orbicularis palpebrarum muscle—a circumstance that prevents a closing of the lids even when all else is relatively normal.

Treatment of narrowed fissure consists in an operation called *tarsorraphy*. The edges of both upper and lower lids are denuded of their lashes at the outer canthus, and the raw surfaces are then sutured together. The extent to which this must be done depends upon the degree of the contraction. The direction of the incisions (a long one parallel to the edge of each lid, and a short one perpendicular to it, the two long incisions meeting at an acute angle) is illustrated in *Fig. 62*. These incisions do not pass through the entire thickness of the lids but penetrate the skin only, and must be completed by the incision of Flarer (separation of the lid into an anterior and a posterior plate, see *p. 162*). In lagophthalmos

Digitized by Illinois College of Optometry

the tarsorraphy does not entirely correct the trouble; it is advisable, therefore, either to resort to suturing the edges of the lids through their whole extent, or to the use of a bandage that assures thorough closure of the fissure.

(*c*) **Entropium** is the name given to an inversion of the edge of the entire lid or any part of it. In the upper lid the outer third is more often involved, in the under lid either the outer two-thirds or the whole lid. There is usually associated with it a trichiasis, that is, a displacement of the cilia at the edge of the lid. The unavoidable result is an irritation to the eye, giving rise to pain, lacrimation, and spasm. If the cornea is annoyed by these irritating hairs for a long time, there will result small or large ulcers or the so-called keratitis pannosa, characterized by haziness and the formation of new blood-vessels.

There are several causes for entropium. A spasm of the orbicularis is one, and some persons can produce a voluntary entropium by this means. In others this spasmodic contraction and the resulting entropium takes place involuntarily, if the conjunctiva or cornea be painfully irritated. Every spasmodic closure of the eyes does not, however, produce entropium, so we must suppose that some particular circumstance favors it; and we do, in fact, find such a condition in a narrowed fissure, a relaxed skin, or flabby tarsus, or an absorption of the natural fatty cushion in the orbit. The aged are regularly victims to some of these conditions, and, therefore, we often see entropium in old persons whose eyes have been bandaged, since a bandage obviously encourages inversion of the lids by pressure upon them. Entropium from this cause is called spastic, and attacks with preference the lower lid. A second and very common cause of entropium is a cicatricial contraction of the conjunctiva with a distortion of the tarsus, usually the result of trachoma, the conjunctiva and tarsus of the upper lid suffering most, a condition called cicatricial entropium.

The diagnosis is easy, but a simple trichiasis should not be mistaken for it. In trichiasis the edge of the lid is normal, but the cilia are displaced. In pure entropium the reverse is the case. Of course, the cilia may be displaced on an entropianized lid, just as we may find inverted lashes on an ectropianized lid.

Treatment of spasmodic entropium often requires only some slight modification in the bandage; or one end of a strip of plaster may be fastened close below the lashes, and, after they have been

Digitized by Illinois College of Optometry

drawn into place, the other end should be attached to the cheek. If these simple means do not suffice, an operation must be performed. Gaillard's suture seems to be most in use and is made in the following way: Raise the skin with a bit of the muscle beneath into a horizontal fold parallel to the under lid, and pierce the base of this fold perpendicularly from below upward, so that the point of the needle makes its exit *3* to *4 mm.* below the edge of the lid; now reverse the needle, and about *2 mm.* from the point of exit enter the needle again and carry it downward through a fold of the skin, tying a knot over a roll of cotton. Two or three of such sutures may be made along the lid. After two days the threads are to be taken out. The scars corresponding to the paths of the thread are said to make the immediate effect of the suture a permanent one.

I have seen so many failures after Gaillard's suture for entropium that I have abandoned the method. Instead of it I prefer the classical excision of a horizontal fold of skin parallel to the edge of the lid, with a suture of the wound. I have never known failure from this.

If, however, the desire is only temporarily to prevent a bandage from causing entropium, I have always been satisfied with the following suture: I enter the needle about *1 cm.* inward from the external canthus, and push it, as may seem best, *2*, *3*, or even *4 cm.* beneath the skin outward, or outward and downward. After bringing it out I tie the ends of the threads. The skin thus caught up is formed into a sort of tumor, the lid being actively stretched and drawn away from the eye. Of course, the thread gradually cuts into the skin and its efficacy is consequently lost, but as soon as the bandage is unnecessary, the thread should be removed.

A successful **treatment** *of cicatricial entropium* demands a more radical interference. As the edge of the lid, in this case, will not yield to moderate traction, it must first be made movable. This can be done by *Flarer's incision*, which is made a few millimeters deep at the intermarginal part, and splits the lid into an anterior and a posterior layer,—the anterior carrying all the lashes with their hair bulbs and glands, and the posterior consisting of tarsus and conjunctiva, while the length of the incision is proportionate to the length of the entropianized part of the lid. The excision of a fold in the skin parallel to the edge of the lid is made after this. The edge of the lid is thus made movable. If the wound parallel to the edge of the lid is now closed by perpendicular sutures, this movable edge will yield to traction on it, and there will remain a narrow wound beneath the edge of the lid (if the upper lid has been operated on). This linear wound surface was formerly left to itself,

Digitized by the College of Optometry

but recently it has been covered by means of epidermis transplantation; that is, small bits of skin taken from the upper arm and so excised that only the tops of the papillæ are cut off. Others use as a covering that portion of the skin of the lid which has just been removed, but in this case it is not completely severed, being released only enough to be able to shove it beneath the bridge made by the lower incision. The operation, after it is ended, seems to leave a clumsy result, but at the end it is generally quite successful. Thier prefers to sever the flap before using it as a cover: the wound is first carefully sutured and then the flap is transplanted to the intermarginal part and pressed into this wound by sutures passing around it from the anterior to the posterior edge. By these methods the tissue carrying the lashes is placed in a new position—a process called "Transplantation of the ciliary floor."

(*d*) **Ectropium.**—The slightest degree of ectropium is termed *eversion*, by which is meant a moderate elevation of the edge of the lid from the eyeball. In the highest degree of ectropium, not only is the edge of the lid but also the entire lid turned outward. Ectropium most commonly attacks the under lids, either limited to the inner or outer canthus, or extended through the entire length of the lid.

The results of moderate ectropium are by no means so severe as those of entropium. The most important is epiphora, which shows itself if the inner angle of the lid is only slightly everted, but enough to bring the inferior punctum lacrimalium out of the tear-sea. Epiphora by itself is only harmful through the eczema it induces in the skin. If the eversion is so complete that the conjunctiva is unprotected, hypertrophy results and the conjunctiva looks like raw flesh—a condition called *ectropium sarcomatosum*. On account of this, as well as of the infiltration of tissue arising from the eczema, the lid becomes heavier and less able to assume the normal position. In this condition, old persons may run about from year to year without the courage to undergo an operation or even to ask the advice of a physician. Such a "blear-eyed" person looks bad, but he does not look badly!

Just as spasm of the orbicularis leads to entropium, so is a paralysis of that muscle a frequent cause of ectropium. This paralysis need not be complete; a mere muscular weakness suffices, a condition seen in advanced life, particularly if the skin hangs down in flabby folds, and when the patient adds to a beginning eversion

by continually trying to wipe off the lid. Such an ectropium is called paralytic or senile, and usually begins at the nasal angle.

Another cause, the tension of a scar, leads to *cicatricial entropium*. As a rule, this results from some earlier disease which has destroyed the symmetry of a part of the lid. Caries of the orbit in children is the commonest cause of adhesion between skin and bone. The upper as well as the lower lid may suffer from this ectropium, the favorite seat of such a scar being the edge of the orbit, either above or below and at the outer angle. Burns, lupus, syphilis, small-pox, etc., are less common causes.

The prognosis is always grave, especially if the eversion is so considerable that the eyeball is never quite covered (lagophthalmos). Such a condition threatens the cornea and vision as well.

Treatment.—In the simplest cases (eversio simplex) this consists in slitting up the lacrimal canal, sounding the nasal duct (*p. 176 et seq.*), and cautioning the patient not to wipe the eye, as he usually does, from above and inward toward the temples, but to rub it in the opposite direction. Epiphora, with its attendant evils, is corrected, and the malposition itself is overcome by this orthopedic massage.

If this simple means is not sufficient, resort must be had to Snellen's suture, which is preferred by the patient who objects to an operation but has no fear of a simple thread. For this purpose take several silk threads, each thread being armed at each end with a needle; enter the two needles of the thread on the conjunctival side of the lid from above downward; bring them out onto the skin at about the level of the edge of the orbit and knot the ends over a roll of cotton. It should not be forgotten that the lashes may be in a position of trichiasis in spite of the existing ectropium, and that, if the lid is replaced to the normal, they may be brought against the eyeball. The direction of the hairs, therefore, must always be of the first importance.

In severe cases of paralytic ectropium there are numerous operations all designed to raise the under lid or to stretch it out horizontally. The first aim is met by *tarsorraphy* (*p. 160*). If this is not successful it may be combined with the excision of a triangular piece of skin close to the outer canthus (*Fig. 63*). If *a* is united to *a'* and *b* to *b'*, the result is plainly to raise the lower lid and to put it on the stretch.

I have always had a satisfactory outcome from an operation originally planned for the extirpation of a tumor of the lid (see *p. 166*).

Digitized by Illinois College of Optometry

In cicatricial ectropium the first step is to sever the adhesion between lid and bone, and then to bring about reposition by any of the methods mentioned above, and to cover any remaining scar by a flap from some adjacent part.

Coloboma.—This name is given to an unusual and congenital defect, the evidence of which lies in a perpendicular fissure in the edge of the lid. It involves the whole thickness of the lid in the shape of a wedge with its base at the edge of the lid. At the apex of the wedge a small bridge of skin sometimes connects the two sides, while beneath this bridge the fissure penetrates muscle, tarsus, and conjunctiva. The defect is usually found in the upper lid, either at the middle or toward the inner canthus. There are generally other anomalies connected with it, such as harelip and fissure of the palate.

A similar fissure may be caused by wounds (*p. 159*), and this is also called coloboma. To prevent this, the edges of any wound should be carefully approximated. In case there is still a fissure after union, freshen the edges and suture again.

Epicanthus.—In persons with flat noses and relaxed tissue, such as babies, Mongolians, or syphilitics with saddle noses, a perpendicular fold of skin from the nose may cover the inner canthus; the free edge of the fold being slightly curved, the concave side toward the temple. As the condition appears nearly without exception on both sides, the nose looks very broad and ugly. This is called epicanthus. When congenital, treatment is seldom necessary, for the growth disappears of itself as the nose grows larger with increasing years. In syphilitics an excision of a perpendicular fold of skin at the bridge of the nose will obliterate the deformity. The operation is called rhinorraphy.

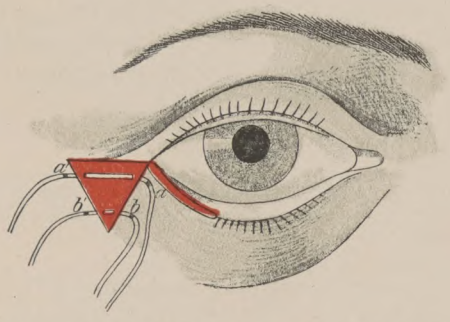

FIG. 63.—OPERATION FOR ECTROPIUM. (*After Dieffenbach.*)

5. NEW GROWTHS.

The literature will show that every variety of tumor is to be found on the lid, but only the most important will receive mention here.

Cancer.—This is undoubtedly the most important new growth on the lid which the surgeon has to treat. It appears only in adult life, from forty years and upward. As a rule it arises from the edge

Digitized by Illinois College of Optometry

and probably from a sebaceous gland. It occurs most commonly upon the inner half of the lower lid.

Michel distinguishes a flat, a deep, and a papillomatous form of cancer. A characteristic of all forms is a small, hard, knotty tumor at the edge of the lid, which ulcerates in the center while it spreads at its margin by the addition of new nodules. The *flat* kind is distinguished by a shallow, indolent ulcer, cicatrizing easily; the *deep* kind has a crater-like ulcer of rapid growth, dark red in color, with hard edges, inducing an inflammatory reaction of the whole lid; the *papillomatous* kind has spongy hypertrophied tissue that bleeds easily, giving to the surface a lumpy or flap-like appearance. The surgeon, however, is interested more in the diagnosis of cancer itself than in any fine differentiation concerning it. A hard chancre affords the most chance for a mistake, but a syphilitic sore arises from contact, probably acknowledged by the patient. It grows rapidly; the lymph glands near the ear, at the angle of the jaw, and on the neck are early involved; and finally edema is more apparent. In cancer we have more advanced age, slower development, and a later involvement of the lymph glands.

Tuberculosis must also be thought of. I have just operated on a tumor supposed to be cancerous, but a histological examination made by Dr. Hanau showed tubercle in the form of lupus.

Treatment of cancer consists in excision. So long as the tumor is small, the following method will afford a permanent cure: Let an assistant seize the edge of the lid with a forceps on each side of the tumor, to stretch the part to be operated upon and to prevent bleeding; then the surgeon cuts between the forceps in healthy tissue with scissors, embracing the whole thickness of the lid and making a wedge with its base to the edge of the lid. The V-shaped wound thus formed is united by conjunctival sutures first, and by skin sutures afterward. If the cancer has attacked the conjunctiva, the operation must be more extensive, even to removal of the eyeball in certain cases.

Verrucæ (*Warts*).—These are usually discovered by accident, when the patient is seeking advice for some other ailment, never having noticed these small tumors. As a rule the wart lies at the outer angle and has a broad base. The surgeon must remember that such a tumor in an old person may eventually develop into cancer, or it may end in a horn, *cornu cutaneum*, as is occasionally seen in both old and young. They should be removed by scissors curved on the flat, or by cautery if the patient fears the knife, though the cautery is actually more painful in the end.

Transparent cysts of the edge of the lid are quite benign; they result from occlu-

Digitized by the Internet Archive in 2010 with funding from University of Illinois Urbana-Champaign

sion of an exit duct of a sweat gland. Its contents is a clear fluid, and may be let out by an incision.

Angiomata (*Vascular Tumors*).—These are of two kinds—*telangiectatic* and *cavernous*. The first variety characterizes the congenital red blotches vulgarly called birth marks, which are composed of dilated blood-vessels shining through the epidermis. They may disappear spontaneously in later life, although they sometimes increase in size, after lying quiescent for years. The cavernous angioma is distinguished from the other by the fact that it protrudes above the surface and is thus a real tumor; it distorts the upper lid or impairs its usefulness by preventing its proper elevation (ptosis). The cavernous angioma has still other characteristics; it is bluish-red in color, and pressure upon it will for the moment obliterate the whole tumor. If the patient desires the removal of an angioma, it may be accomplished by excision or by the cautery; but if the growth seems too large for a safe operation it should be made to atrophy by introducing platinum wires and then raising them slowly to a red heat by means of the electric current.

Xanthelasma (*Xanthoma*).—There are two kinds—*xanthoma planum* and *xanthoma tuberosum*. The first appears nearly always as an egg-shaped or irregular blotch on the fold of the upper lid, above the inner tarsal ligaments; it is dirty yellow in color, and varies in diameter from *1* to *4 mm*. After a time new blotches appear near the original one, and the disease may pass to the lower lid or may attack the other eye, so that in the course of years both eyes may be surrounded by a group of yellowish spots. The disease is said to be an hypertrophy of connective-tissue cells in the cutis, with subsequent fatty degeneration of these cells. Xanthoma tuberosum is made up of small, light-yellow nodules, lying generally on the skin of the nose. They result from occlusion and hyperplasia of sebaceous glands. If removal is desired they may be excised. Stern has recently stated that cauterization with *10* per cent. sublimate collodion will completely bleach these yellow spots without destruction of tissue.

II. DISEASES OF THE LACRIMAL APPARATUS.

Anatomical and Physiological Introduction.—Tears contain, according to Arlt, *0.52* per cent. albumin and *1.257* per cent. sodium chlorid. This large amount of sodium chlorid in proportion to that in other fluids of the human body gives to tears their salty taste, and is accountable for the irritation they cause to the mucous membrane of the eye and of the nose. The amount of tears secreted is, under ordinary circumstances, very small; but it can be remarkably increased at any moment by irritation to the conjunctiva, cornea, optic nerve, to the nose, and finally by mental excitement. Tears are secreted by the glandulæ lacrimalis. Each eye has two glands, an upper and a lower. The upper lies in a pit in the roof of the orbit, the fossa glandulæ lacrimalis; the lower and smaller one is separated from the upper by a slight fascia; it lies directly against the conjunctiva, and in many individuals can be seen through it if the upper lid is everted with the eye directed strongly downward. The ducts of both glands have exit in the outer and upper fold of the conjunctival sac, from which the tears flow between the lids and the eye toward the nose into the lacrimal sac, a space bounded outwardly by the plica semilunaris, inwardly by the edge of the inner canthus, above and below by the caruncles. (Goldzicher and Jendrassik have recently declared that the secretory nerve of the lacrimal gland is not the lacrimal branch of the first division of the trigeminus, but belongs to the facial nerve. In a complete facial paralysis, therefore, of central origin, the secretion of tears on the affected side would cease, and in mental excitement there would be "one-sided weeping.")

Digitized by the Internet Archive in 2010 with funding from Illinois College of Optometry

To get an idea of the course of the tears, place a cover glass on a slide and put a drop of water on one side of the glass; the water will then, by "capillary attraction," be drawn between the two glasses. If now a bit of blotting paper be held on the opposite side of the cover glass the water will be sucked up by it. The two glasses represent lids and eye, the blotting paper the lacrimal apparatus.

This lacrimal apparatus (*Fig. 64*) begins with the two puncta lacrimalia, superius et inferius; the passage enters perpendicular to the lids for a millimeter, then turns nearly at right angles and proceeds in the direction of the lid as the canaliculus toward the nose. The canaliculi, either together or separately, open into the outer wall of the tear sac, saccus lacrimalis, a space lined with mucous membrane, lying behind the inner palpebral tendon in the fossa lacrimalis, and having an upper blind end, the fundus, somewhat above the tendon. This inner palpebral tendon is seen as a yellowish cord in the skin, when the external angle is dragged toward the temple. The passage now proceeds perpendicularly downward from the sac, as the ductus naso-lacrimalis, finally opening into the inferior meatus of the nose. This naso-lacrimal duct is contracted in two places, the beginning

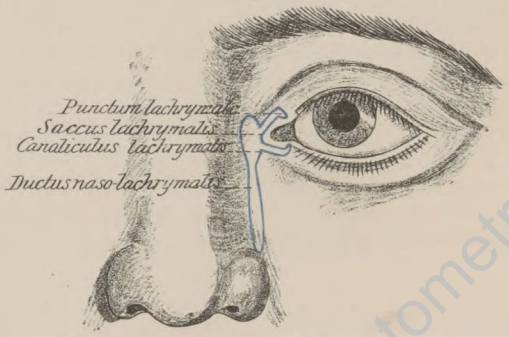

FIG. 64.—SCHEME OF THE LACRIMAL PASSAGE.
The lower punctum and the upper canaliculus are not indicated by name.

and the end. It is lined with mucous membrane similar to that of the nose, and, particularly at its lower half, is embedded in a venous flexus.

The naso-lacrimal duct is not exactly perpendicular nor exactly straight. Its deviation from the straight line—called the S curve—is of no practical importance. The deviation from the perpendicular must be borne in mind, for, according to the shape of the skull, the passage curves more or less backward; while if the nose is narrow it curves somewhat inward. Strictures occur most frequently at the upper and lower orifices. The tears collected at the inner canthus flow through this passage into the nose. The forces at work are capillary attraction, gravity, and the movements of the lids. That these movements directly assist in emptying tears into the nose can be easily understood when we remember that by winking rapidly we prevent an overflow of tears when they are secreted too freely, and the nose "runs" when we cry. Henke has analyzed the effect of a wink. He compares this to a suction-pressure pump, but other investigators do not uphold him in every respect. The accepted idea is, that in winking the tear sac is expanded by the traction of the muscles and the tears sucked into it, but that the contraction of the sac is only passive, due to the elastic action of tense tissues.

Digitized by the Ohio College of Optometry

1. DISEASES OF THE LACRIMAL GLANDS.

(*a*) **Abscess** of the lacrimal gland is an extremely rare disease, and the diagnosis of such may always be questioned. The *diagnosis* depends upon the signs of abscess at the upper and outer angle of the orbit, but this does not exclude the probability that the gland itself may be healthy and the abscess a process going on in the adjacent orbital tissue (see Diseases of the Orbit). The fact that the incision into such an abscess often reaches denuded bone rather corroborates this latter supposition.

(*b*) **Inflammation** of the lacrimal gland is also very rare, but has been actually observed.

The diagnosis depends, not so much upon the presence of swelling in the neighborhood of the gland, as upon the fact that the swollen gland can be seen and felt. The lid, especially when the inflammation is severe, must of course be red and swollen, and difficult to elevate. In cases reported by v. Graefe, Heymann, and v. Wecker, the eye itself was inflamed on account of excessive secretion of tears. In a case reported by Horner, no cause could be discovered unless we call "catching cold" a cause. This case is likewise remarkable in that the disease appeared on both sides and that the lobular structure—generally not appreciable—was plainly evident to the fingers.

Treatment consists of inunctions of mercury and iodid of potassium salve; healing may result in the course of months.

(*c*) **New Growths.**—Most new growths in the gland are adenoids, that is, tumors that develop from the epithelial cells of the gland; they have few blood-vessels and are of a distinctly defined nodular nature. As these nodules grow slowly from the center and have no tendency to extend beyond the gland, they may be classed with the benign tumors. But a *chloroma* sometimes attacks the gland, and is a very malignant tumor. It has a greenish color, but its histological structure is not definitely known. Sarcomata and carcinomata have been observed. The first sign of tumor in the lacrimal gland is a slowly increasing exophthalmus that prevents the eye from moving upward and outward. If the patient tries to look in this direction (on the affected side) he gets cross-eyed and sees double. Careful examination will now show to the fingers a hard, lumpy tumor, which may perhaps be seen under the conjunctiva in the fornix, if the lid is everted. If the tumor increases the eye is pushed downward, inward, and forward. Squint results

Digitized by the Internet Archive in 2010 with funding from Illinois College of Optometry

from all movements. The exophthalmus finally becomes so pronounced that the lids can no longer be closed and lagophthalmus is constant.

Treatment must be a radical excision, shelling out the tumor from its bed. In the case of adenoids, at least, a permanent cure may be expected.

(*d*) **Dacryops.**—The name is intended to indicate that condition produced when a duct of the gland is occluded. A space behind it becomes filled with tears. The result is a bluish, transparent cyst, in the upper, outer fold of the conjunctival sac. As the tumor grows the patient complains of a feeling of pressure with a watering of the eyes.

Treatment seeks to open a passage for the escape of tears. A thread piercing the cyst from without and allowed to remain until it cuts its way through, will accomplish this end.

(*e*) **Fistula of the Lacrimal Gland.**—A small opening may show itself near the gland on the skin, from which a watery fluid (tears) escapes. This fistula may be the result of an injury or an operation. Healing may be induced by connecting the fistula with the conjunctival sac, after which the opening on the skin usually heals of itself. The operation is made by a thread, armed with a needle at each end. One needle is introduced into the fistula and passed to the conjunctiva; the second needle is introduced in the same way at the side of the first, after which the two ends are tied over the conjunctiva. The suture thus embraces the portion of tissue lying between the fistulous opening and the conjunctiva. If this tissue is destroyed by the pressure of the suture, the desired connection will be established.

2. DISEASES OF THE LACRIMAL PASSAGE.

All diseases of the lacrimal passage have one sign in common—weeping or epiphora. This is often the only symptom; at least the only symptom that affects the patient disagreeably. It is, therefore, the first, and in some cases the only, requisite of treatment to effect a proper discharge of the tears into the nose,—a task in which even the cleverest may fail.

Although weeping is found with all diseases of the lacrimal passages, it is by no means true that epiphora proves the presence of some obstacle in these passages; for weeping may be only a reflex symptom, since the tears may be so abundantly secreted when certain endings of the trigeminus are irritated that even a normal duct is unable to take care

Digitized by Harvard College Library

of the flood and to carry it all into the nose. We have examples enough of this in the ordinary cases of weeping eyes due to inflammations of the conjunctiva, cornea, or iris. Many people weep on coming into fresh air, but this is no indication that there is any disease of the eye or any hindrance to the passage of tears. We must suppose that in their case there is a pronounced irritability of the trigeminus, for if the irritation from wind and weather be strong enough any eye will weep. A superabundant secretion of tears is, at times, a forerunner of Basedow's disease.

(*a*) **Puncta Lacrimalia.**—Any malposition of the puncta or of the lower punctum alone will cause the tears to overflow. This can be easily accomplished by dragging down the lower lid; when this is done the punctum no longer rests upon the eyeball or upon the plica semilunaris, and therefore does not dip into the tear sea. The tears in running over soften the epithelium of the lid; this leads to eczema of the lid and of the skin; the lid grows thicker and heavier and a simple eversion of the lid is turned into a pronounced ectropium. We have thus every reason to endeavor to nullify the effect of malpositions of a punctum. The best method is the one introduced by Bowman of slitting open the canaliculus. This is done by a canaliculus knife (*Fig. 65*), as follows: Draw the lower lid downward and outward (or the upper lid upward and outward); introduce the point of the knife into the punctum perpendicular to the edge of the lid and bring the handle around till the blade is parallel to this edge; now push it forward till the point meets resistance at the lacrimal bone. After making sure that the blade is in the correct position toward the eyeball, revolve the knife as a lever, upward and inward for the lower lid (downward and inward for the upper lid), keeping the point firmly against the bone. The wound is to be opened the next day with a sound. This must be repeatedly done if the lower canaliculus has been slit, since it has a marked tendency to close up. The canaliculus has been changed by this procedure into an open gutter, and, as far as the disposition of tears is concerned, it is a matter of indifference whether they flow through a closed passage or an open one. If this gutter opens properly toward the globe, the tears will still be carried away through it, even if the lower lid is slightly everted.

FIG. 65.—CANALICULUS KNIFE.

It is quite evident that if the punctum is stopped up the tears

will not flow through it. Such a stoppage may be due to a cicatrix of the lacrimal papilla or of some adjacent tissue. In reality, it is oftener assumed than found. I myself, at least, have most always been able, by using a good lens, to find an opening when the naked eye could see neither papilla nor punctum. Treatment here, too, is the above operation, especially as the obliteration of the punctum (of the lower lid) is usually associated with some ectropium. To enter the puncture and to dilate the canaliculus a fine conical sound is used. This can be done, of course, only when obliteration is not as complete as it is after a burn or severe suppuration. In such a case we guess where the punctum ought to be, and after slicing off part of the lid at this place, try to find some entrance on the surface of the wound.

(*b*) **Canaliculus.**—If the obstacle to the flow of tears is in the canaliculus, there is a stenosis, which may be due to some foreign body from the conjunctival sac, such as an eyelash, the wing of an insect, a wheat bristle, etc. As this accident almost always attacks the lower canaliculus, it shows the importance of this passage for the flow of tears. If a foreign body still protrudes from the punctum, it scratches the eyeball at every movement of the lids, and produces a conjunctivitis or keratitis; thus there is epiphora from two causes. Such an inflammation is cured by removing the foreign body. The trouble is more complicated if the occlusion is caused by the formation of stone (*dacryolith*) in the canaliculus. There are often several stones, varying in size from a millet seed to half a pea. We must always bear this in mind when there is a tumor in the neighborhood of the canaliculus, with epiphora and some pain, but no involvement of the tear sac. Pressure on this tumor will drive a drop of mucus or pus from the punctum. The microscope shows such stones to be composed principally of carbonate of lime and leptothrix threads. *Polypi*, though very rare, may produce the same phenomena. They may grow so luxuriantly as to protrude from the punctum.

Treatment of stone and polypus consists in an operation to remove them, for which purpose slitting the canaliculus is indispensable to success.

(*c*) **Tear Sac** (*Catarrh of the Lacrimal Sac, Dacryocystoblennorrhœa, Dacryocystitis, Lacrimal Fistula, and Hydrops of the Tear Sac*). —These five diseases may be described together, since they are essentially but various stages of one and the same process.

Digitized by the College of Optometry

The mucous membrane of the tear sac is subject to catarrh the same as any other mucous membrane. Considering the connections between the conjunctiva and the nose, and considering what free access all fluids of the conjunctiva have to the lacrimal sac, it is a matter of wonder that the latter compared with the former is so seldom attacked by catarrh. It is probable that the thick layer of pavement epithelium in the lacrimal canals (Merkel) offers some protecting obstacle to an advance of a catarrh from the conjunctiva into the lacrimal sac; at least we know that this epithelium on the cornea offers much more resistance to infection than does the thinner epithelium of the conjunctiva. Again, infection of the tear sac by fluids from the conjunctiva is to a certain extent prevented by the rapidity with which these fluids pass into the nose. Experience has taught that nothing so exposes the tear sac to disease as a stoppage to the flow of tears below the sac. Finally, the comparatively rare ascent of catarrh from the nose into the lacrimal sac may be explained by the narrowness of the duct at its nasal opening, since any slight catarrhal swelling of the adjacent mucous membrane must indeed produce a complete occlusion there. It must be remarked in passing that the great majority of all so-called strictures and stenoses of the lacrimal passages is due solely to swelling of the mucous membrane or of isolated patches of it.

In *catarrh of the lacrimal sac* the mucous membrane is red and swollen; its secretion, normally clear and sparse, is now cloudy and abundant. This cloudiness is due to cast-off epithelium and to migrated pus cells. Since a congestion of the mucous membrane leads in all cases to a still further narrowing of an already narrow entrance into the passage, the fluid collected in the sac is prevented from escaping; the sac is therefore stretched, and a small tumor shows itself. The trouble this condition causes the patient is trivial, and for many hours of the day may pass unnoticed, but when he goes into the open air or into a smoky or dusty room the tears begin to run. If the swelling of the sac reaches a higher stage, there is a complaint of pain, or at least discomfort, at the inner canthus. The congestion may, and undoubtedly often enough does, disappear without medical interference. This is, however, not always the result. Stagnant fluid in the tear sac is a splendid nutrient for bacteria, that are always present on the mucous membrane of the nose and often on that of the eye.

When bacteria develop in the tear sac, its contents assumes another character; it becomes pus—a condition called *blennorrhea of the lacrimal sac, or dacryocystoblennorrhea.* The patient has still little to complain of beyond weeping, red eyes, some matter on the lids in the morning when he wakes, or scabs at the inner angle. That is all! Perhaps for years he has had this trouble, and comes at last to the physician on account of some slight and insignificant injury to the cornea. He has now the sorrowful task of telling the patient that the sword of Damocles

Digitized by Illinois College of Optometry

has been threatening him, that it has now fallen, and that this blennorrhea may in a few days destroy his eye. The contents of a suppurating tear sac is extremely infectious; only a small wound is needed, the slightest injury to the corneal epithelium, to light up one of the most dangerous of eye diseases, ulcus serpens. Many a suppurating keratitis, after cataract operation, has originated from a blennorrhea of the tear sac that the surgeon had overlooked.

The toxic nature of this pus may with very small encouragement be the cause of another disease, abscess of the lacrimal sac, *dacryocystitis*. Some small area in the mucous wall may ulcerate; bacteria may penetrate into the tissue beneath, and an abscess may result, which, like any other abscess, shows itself with heat, redness, swelling, pain, and constitutional disturbance. Abscesses from other causes at the inner canthus below the tendon are extremely rare, and we may, therefore, boldly assume that any abscess at this place originates in the tear sac, especially if the patient acknowledges that he has suffered from a blennorrhea of the sac, or if pressure (which is very painful) on the tumor near the sac expresses any pus from a corresponding punctum. Additional symptoms are redness of the skin and conjunctivitis. If the abscess is left to itself, it will sooner or later open below and external to the tendon of the orbicularis. After the pus finds exit, pain and fever rapidly disappear. The exciting disease, the blennorrhea, may heal, and the contracted tear sac may cicatrize and atrophy. This favorable result is not the rule, however; on the contrary, a new pathological condition, *fistula sacci lacrimalis*, is by far the more frequent outcome. The name suggests an ulcer on the skin at the inner canthus; it looks like a small knob of spongy granulations; the skin near by is dark red; a fine opening about the diameter of a hair is visible, from which exudes a drop of matter that is sucked in and out by every movement of the lids. The fistula is in direct connection with the lacrimal passage, generally with the sac itself. It may remain a lifetime, and is really a protection against the renewal of a dacryocystitis, for it has been observed that after the fistula has healed a dacryocystitis may suddenly be lit up, obviously because there is no longer a natural passage for the tears into the nose; and an occlusion of the fistula means, again, a stasis with all its dire consequences.

Many a patient has a suppurating tear sac for years without infecting the conjunctiva or cornea. Gradually, too, the contents

Digitized by the College of Optometry

of the sac ceases to be pus and becomes watery and thin. The mucous membrane is no longer thick, velvety, and red, but is thin, pale, and slate colored. As it shrinks, the mucous membrane loses its resistive power, and fluid collecting within the sac stretches it more and more to the size of a pea, or even of a cherry. As it is certain to be stretched in the direction of least resistance, toward the skin, the result is a tumor visible externally, with well-defined outline, because there is now no inflammatory infiltrate in the adjacent skin. This condition is called *Hydrops sacci lacrimalis.* It may appear and disappear, or remain permanently, although at times the mucous membrane of the lacrimal duct may so retract as to open a passage for the tears into the nose. It seems that if the sac is once stretched beyond a certain limit, the lids lose their effectiveness as a pump, and that the filled or even over-filled sac can be emptied only by pressure of the finger, even if the passage to the nose is still patent.

From the symptoms and signs given it ought to be easy to recognize these five diseased conditions. Dacryocystitis and fistula need only to be seen to be diagnosticated. A simple catarrh, a blennorrhea, or a hydrops are discovered by the trick of emptying the sac with pressure of the finger, but to be successful one must keep the puncta lacrimalia constantly in view. The best way is to stretch the lids with one hand, at the same time ectropionizing them somewhat, while a finger of the other hand is firmly pressed upon the inner tendon or the orbicularis. In catarrh, a watery, flocculent fluid gushes out, in blennorrhea there is more or less pus, but in hydrops there may be nothing, as all the fluid may escape into the nose. From a normal lacrimal sac nothing can be expressed, that is, nothing upon the conjunctiva.

Treatment of catarrh and of blennorrhea must be begun by a radical examination of the nasal mucous membrane, as not only may catarrh arise from this source, but there is always danger of a tuberculous infection of the lacrimal passage. I cannot here discuss the treatment of the nasal mucous membrane; that of the tear sac must first attempt to secure a free passage into the nose, and second to restore the mucous membrane to its normal condition. If the first succeeds, the second will generally be accomplished of itself, because, as has been mentioned, a catarrh or a blennorrhea is due to occlusion of the lacrimal passage into the nose. The occluded canal is opened by means of Bowman's cylindrical sound

Digitized by Illinois College of Optometry

(*Fig. 67*) or of Weber's cone-shaped sound (*Fig. 66*). Now slit the upper canaliculus, since this is the shorter, has less tendency to close again, and is easier to sound than is the lower one. The proceeding is moderately painful, but this may be diminished by a few drops of a *5* per cent. solution of cocain on the conjunctiva. The next day the lips of the wound are to be opened by a sound and at the same time an attempt should be made to pass it carefully



FIG. 66.—WEBER'S SOUND.

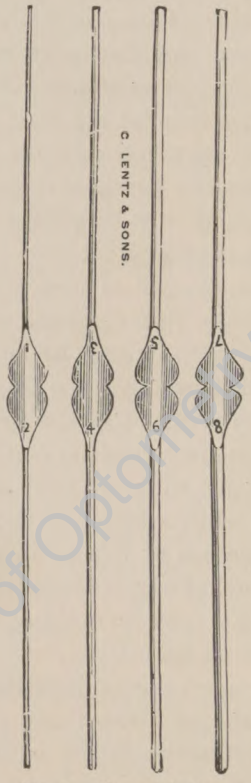

FIG. 67.—BOWMAN'S SOUND.

further on. In doing this, the upper lid must be firmly drawn outward and upward; the point of the sound is passed along the back of the incision in the canaliculus to the nose until it is felt to strike against a bony resistance; the sound is then rotated till it points in a downward direction, which will be given it by holding the point against the lacrimal bone. An effort should now be made to pass the sound into the nasal duct, pushing it along the

Digitized by Illinois College of Optometry

inner, bony wall of the sac. If the sound is in the proper position, that is, if it lies in the sagittal suture, between the nasal bone and the tear sac, the effort will be successful with only moderate force. Once in the duct, the greatest difficulty is overcome, even if a few narrow places demand a stronger pressure to pass them. The amount of pressure necessary can be judged only by experience.

The following rules must be observed: Bone-like resistance indicates a false passage, as the resistance offered by a fold of swollen mucous membrane always yields in some degree. If no advance can be made, the sound should not be pushed to the right or left, but must be withdrawn a few millimeters and again pushed forward. If this is not successful, try another sound; thicker ones often pass where thin ones have been caught, for the smoothed-out folds in the membrane that offer an obstacle to thin sounds may be no hindrance to thicker ones. If they all fail, wait a few days before making the next attempt. By that time the mucous membrane may have shrunken so materially as to simplify the passage of a sound. The first introduction of a sound is extremely painful, the pain radiating to the teeth; some patients even faint. Repeated applications of cocain to the conjunctiva may lessen the pain considerably. Hemorrhage is not uncommon. It indicates the necessity for great care, small-sized sounds, and longer intervals between each effort.

The more experience I have the less eager I am to begin the use of the sound. I have given up entirely the larger sounds. It has often been my misfortune to see an open lacrimal passage gradually grow narrow and narrower, pari passu with the treatment by the sound, and finally to become quite impervious, presumably on account of a periostitis due to this sounding of the lacrimal duct.

If the sound is successfully passed, it should remain two to twenty minutes according to the difficulty found in passing it. If it went in easily and if the duct was narrow at only certain places, say at the beginning and end, the sound can remain twenty minutes. But if the whole canal was narrow and tight, the sound should be taken out at once, otherwise it will in a few minutes be so tightly grasped by the stricture that considerable strength will be needed to remove it, and even then hemorrhage may be caused. As a rule, weeks or months will be consumed before the patient can be discharged. Probing must be continued at intervals of four to eight days until the higher number, 3 (Bowman), can be easily introduced at any time. I do not even then dismiss my patients, but advise them to return every fourteen days for the sound, and finally every month; relapses may be thus avoided.

The slow results of the use of the sound induced Stilling to try "*Stricturotomy*," that is, cutting open the stricture by means of a small knife especially constructed for entering the nasal duct through the lacrimal sac. Thomas has recently recommended the operation warmly. *Fig. 68* shows the knife used by him. It can obviously be used only in the cases in which the blunt point of the knife will first pass the stricture.

Digitized by Illinois College of Optometry

Stilling omitted further local treatment; Thomas, on the other hand, held it necessary to have the patient carry a lead sound of about *1.5 mm.* diameter for some time after the operation. It must be confessed that this method has cured cases pronounced incurable by the ordinary use of sounds.

The fact that a sound if long retained is held fast, due obviously to the swelling of the mucous membrane, suggested to me to try a method that might be called "graduated sounding." At first a thin sound is introduced well anointed with cocain salve, and is then moved back and forth in the nasal duct till it passes with noticeable ease. It is now drawn out and a thicker one introduced, moved back and forth till it also meets no resistance. I have had the good luck in the very first sitting to be able thus to introduce with no difficulty at all the thickest sound I ever use.

FIG. 68.—KNIFE FOR CUTTING A STRICTURE OF THE NASAL DUCT.

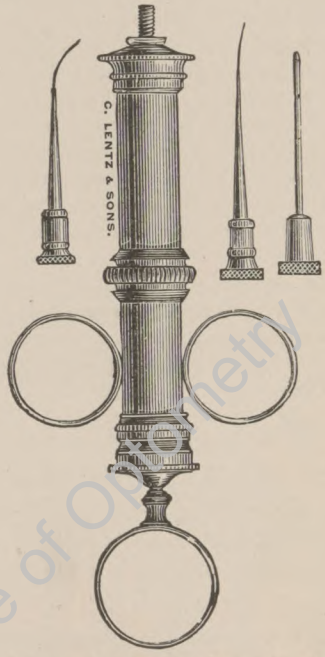

FIG. 69.—SYRINGE FOR INJECTING THE LACRIMAL PASSAGES.

For direct effect upon the mucous membrane we use various solutions injected into the tear sac by a suitable syringe (*Fig. 69*). If the passage is pervious, most of the fluid runs into the nose, and from there either out of the nostrils, or, if the patient throws his head back, into the throat.

The solutions most generally applied are *0.6 per cent. sulfate of zinc, 1 per cent. acetate of lead, 2 to 5 per cent. nitrate of silver, 1 to 2 per cent. tannic acid, 0.02 per cent. corrosive sublimate,* and, finally, *iodoform emulsion.* I have seen the best results from nitrate of

Digitized by Illinois College of Optometry

silver. There are cases enough, however, where suppuration will not dry up in spite of all possible fluid applications.

Under these circumstances I have felt justified in daring to use a solution of *10 per cent. chlorid of zinc*. The result was unexpectedly favorable. In many cases a single injection was sufficient to stop completely, and finally to dry up, all suppuration. Of course, such a fearful means of cautery can be attempted only under certain precautions. The best plan is the following: first inject several drops of a five per cent. cocain solution into the tear sac to reduce the pain as much as possible, when the whole conjunctiva and cornea is covered with a thick protective layer of vaselin. Now the surgeon can inject several drops of the 10 per cent. chlorid of zinc into one punctum or canaliculus, while an assistant injects into the other punctum a four per cent. solution of carbonate of soda. The chlorid of zinc, as it flows back, unites with the carbonate of soda to form chlorid of soda and carbonate of zinc, two indifferent and unirritating solutions. The reaction to the chlorid of zinc solution is very intense; it is best, therefore, to tell the patient that his face will puff up somewhat, but that this puffiness, with any pain accompanying it, will disappear after a few hours if he use hot compresses. I happened quite accidentally upon this plan, which has already been tried by other surgeons. While sitting one day with a few colleagues, we began to confess our ophthalmic sins. One of us said that he had once picked up the wrong bottle, and had in consequence injected the ten per cent. chlorid of zinc instead of 0.02 per cent. sublimate solution into the tear sac. The whole face had swollen up dreadfully, but the suppuration had stopped then and there.

It is evident that suppuration will not cease if the passage for the tears into the nose cannot be kept open. Therefore, if the patient is to be freed from the danger constantly threatening when there is pus in the neighborhood of the noble organ of vision, nothing remains but to extirpate or to destroy the lacrimal sac. To cut out the tear sac uninjured is an operation more often begun than carried out according to program. Arlt, that past master of operative ophthalmology, gave up the method after several attempts. If the operation is decided upon, it is best in every case to have ready knife, scissors, forceps, chisel, with other appliances and a sharp spoon to scrape away bits of mucous membrane or other impeding tissue, in case of severe hemorrhage, thus transforming the operation into a curetting one instead of a literal extirpation.

The obliteration of the tear sac is a classical method, and was done by the actual cautery or by various chemicals. It is to-day effected as follows: after anesthetizing the patient, the lids are drawn firmly outward and the point of a knife is entered just below the prominence of the tendon of the orbicularis, pushed on into the tear sac, and then withdrawn in a downward direction, cutting through with one stroke the anterior wall of the sac, the subcutaneous tissue, and the skin; the incision is then widened upward through the tendon to include the fundus of the sac. The wound

Digitized by Illinois College of Optometry

is now held open by two forceps or sharp hooks, and after stopping hemorrhage, so as to get a good view of the mucous membrane, it is thoroughly cauterized by the galvano-cautery.

It may be mentioned that v. Wecker rejected this destruction of the tear sac and replaced it by his method of making a large opening for the tear sac into the conjunctival sac, combined with extirpation of the lacrimal gland. What good does all this do, if in spite of it the mucous membrane of the tear sac continues to suppurate?

Treatment *of abscess, fistula, and hydrops* of the lacrimal sac needs further mention. Abscess must be opened as early and as thoroughly as possible. This may occasionally be effected by slitting the canaliculus, but usually an incision through the skin and anterior wall of the sac cannot be avoided. After the abscess heals there still remains the hard task of curing the blenorrhea.

To cure a fistula we must first try to restore the normal passage. If this is done, the fistula will, as a rule, heal of itself, or may be encouraged to do so by applications of nitrate of silver or tincture of iodin.

In hydrops we have the choice between incision through the anterior wall of the sac or its obliteration—assuming that the patient spares us the trouble of choosing by insisting that he is quite content with his present condition and refusing any operative interference.

(*d*) **Nasal Duct.**—It has already been said that disease of the nasal duct is one of the most prominent sources of infection in the lacrimal sac. The commonest cause of disease in the nasal duct is a catarrh of the nasal mucous membrane, which, when congested, affects the entrance of the duct and causes a stenosis. The introduction of the sound, used in the interest of the tear sac, overcomes the stenosis and therefore heals the catarrh. If it seems best to treat the mucous membrane especially, a good device for that purpose is the hollow, perforated sound of v. Wecker, through which fluids may be injected upon any area of the passage.

In rare cases the whole passage is absolutely impassable, and successful local treatment seems, therefore, out of the question. As causes of such an occlusion may be mentioned foreign bodies, so-called dacryoliths, new growths of the adjacent tissue,—especially those of the nasal cavities,—and affections of the canal due to injuries, lupus, syphilis, and tuberculosis (caries) of the bones.

Assuming that the dacryostenosis is not altogether subordinate to the general disease, operative measures may be suggested, depend-

Digitized by Illinois College of Optometry

ent on the presence or absence of pus in the lacrimal sac. If there is pus, the old barbarous method of forcing a new passage through the lacrimal bone into the nose need not be thought of, but the surgeon can content himself with the treatment by ten per cent. chlorid of zinc, or with obliteration of the sac.

III. DISEASES OF THE CONJUNCTIVA.

Anatomical and General Remarks.—If the lids are shut, the conjunctiva forms a closed sac (*Fig. 70*) whose walls are pressed against each other by the protrusion of the eyeball from behind (the anterior layers of the cornea, the epithelium, and Bowman's membrane being considered a part of the conjunctiva, the *conjunctiva corneæ*). That part of

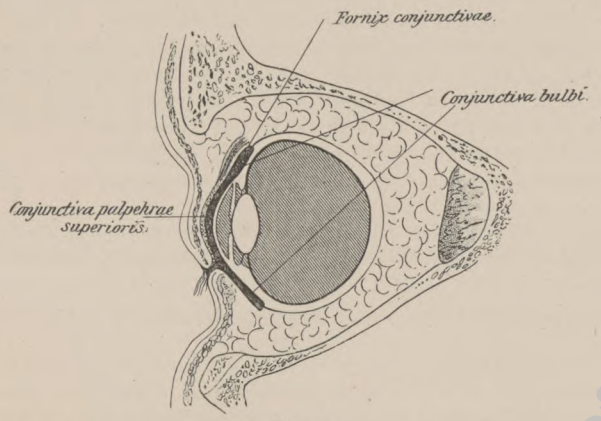

FIG. 70.
Conjunctival sac (in heavy black) is in reality only a capillary fissure, but here it is exaggerated for the sake of clearness. (*After Merkel.*)

the conjunctiva covering the back of the lid is called *conjunctiva palpebrarum;* that covering the anterior segment of the globe is called *conjunctiva scleræ*, or *bulbi;* that part forming the fold between the two is called *fornix conjunctivæ*. The histological structure is quite different in these three divisions, but they all have in common an epithelium, a substantia propria, and a subconjunctival connective tissue.

The *conjunctiva palpebrarum* (compare *Fig. 57, p. 142*) forms in the vicinity of the palpebral fissure a smooth covering for the tarsus; further back, at that edge of the tarsus away from the fissure, the conjunctiva becomes thick, pitted, uneven. If looked at with a lens, it is seen to be covered with fine papillæ, a fact that suggested the idea of a papillary body (*Fig. 57*). The epithelium is composed of cylindrical cells on the surface, with a layer of round cells beneath them. The tunica propria consists of a thick connective tissue of few elastic fibers in which numerous lymph bodies are sprinkled; on account of these latter it has been called "adenoid." These lymph nodules are particularly abundant in the "papillary body." The tarsus (*Fig. 57*) in the conjunctiva of the lid takes the place of the subconjunctival connective tissue.

Digitized by the Internet Archive in 2010 with funding from Illinois College of Optometry

At the fornix the conjunctiva leaves the lids abruptly, but passes much more gradually onto the globe. There are here three or four layers of epithelial cells. The tunica propria cannot be separated from the subconjunctival tissue, but both of these layers, by having a more mesh-like structure and an abundance of elastic fibers, are different from the corresponding layers of the palpebral conjunctiva. Lymph nodules are found in clusters at the fornix, the so-called "leukocyte follicles," cell masses enclosed in an undoubted connective-tissue capsule. Many histologists declare that these lymph follicles are in man always pathological. We shall learn that in certain diseases of the conjunctiva they have an important part to play.

On the conjunctiva bulbi the epithelium becomes richer in cells as we approach the cornea, and possesses peculiar goblet cells (individual mucous glands).[1] The tunica propria and the subconjunctival tissue are like that of the fornix in construction, and are loosely connected by a few fibers with the sclera and the tendons of the eye muscles; this connection is especially intimate along the "scleral border," that is, at the circle of union between sclera and cornea. The epithelium passes without interruption into that of the cornea, while the connective tissue becomes Bowman's membrane (*Fig. 4, p. 27*). Particular notice must be given to the blood-vessels of the conjunctiva. On the lid they are thin, and run parallel to each other from the fornix to the lid's edge; the conjunctiva of the globe and of the fornix have, on the other hand, a network of stronger vessels that spread in all directions like the branches of a tree. As a result of the structure of the tunica propria in various places, it will be noticed that the conjunctiva of the lid cannot be moved, while on the globe it is easily displaceable.

The anatomical subdivision of the conjunctiva into three parts gives us a certain natural subdivision for pathological study. That is to say—

(1) *The diffuse inflammations attack particularly the conjunctiva of the lid.*

(2) *The diseases characterized by the growth of follicles and granulations attack the fornix;* and

(3) *The localized* (focus) *diseases, as phlyctenules, pterygia, xerosis, attack the conjunctiva of the globe.*

If the conjunctiva is inflamed the eye looks red, but every red eye does not have an inflamed conjunctiva. As it is transparent, one can see through the conjunctiva the deeper congested blood-vessels. There are three ways of distinguishing deep from superficial injection:—

(1) Vessels lying in the conjunctiva are easily movable upon the sclera beneath it.

(2) Individual vessels are bright red; and

(3) They can be traced along their entire course.

In a deeper injection single vessels cannot be seen, and there is only a diffused and bluish-red color, which passes from delicate rose to a light purple, according to the depth of the injection. The sclera when injected appears violet.

To recognize diseases of the conjunctiva, it is necessary to examine it throughout its entire extent. Sometimes this is easy, sometimes hard, occasionally impossible, according to the stiffness of the lids, the amount of pain present, and the good or bad intention of the patient. The conjunctiva of the lower lid, of the fornix, and of the lower half of the eyeball is visible if the surgeon places his finger at the edge of the lid, presses it firmly downward, and asks the patient to look upward. A patient with any painful affection and dread of light does this instinctively. The task is more difficult in the case of the upper lid. The patient is asked to look toward the ground, because the upper lid is thus

[1] Many observers maintain that this is a mucous degeneration of the epithelium and is pathological.

Digitized by Illinois College of Optometry

best flattened out. Then the surgeon grasps a few lashes between the left index finger and thumb, and pulls firmly downward and outward so as to draw the lid away from the eyeball; at the same time he presses with the thumb of the right hand against the upper edge of the tarsus and pushes it firmly downward, while the left hand pulls the lid upward, the right thumb nail supplying the fixed point about which the lid is revolved. It is easier for the beginner if he uses in place of the right thumb a stiff sound or a glass rod, placed horizontal at the upper edge of the tarsus; it may be withdrawn as soon as the lid is turned over. The patient does not always obey the order to look downward; sometimes the lashes cannot be grasped because they are too short or too scanty. In such cases draw up the skin on the lid with the index finger of the left hand, so as to show the posterior edge of the lid, then push the left thumb beneath it, and press it firmly upward, while the right hand does its part as above described. To get a view of the fornix, the ectropionized lid must be lifted from the globe by a sound or a spatula, or it can be turned over a second time if the patient will continue to look downward with all his might.

I. DIFFUSE INFLAMMATIONS.

(*a*) **Hyperemia acuta.**—In the strict sense of the word, hyperemia, that is, a fulness and congestion of the blood-vessels of the conjunctiva, is not a disease but a symptom, introducing a series of different diseases; but it is often the only symptom and to this extent it is the disease itself. This is the case, for example, when a foreign body remains in the conjunctival sac; it then produces a feeling of something in the eye, with pain, fear of light, vascular injection, weeping, and even spasms of the lids, which may continue after it has been removed. It happens, therefore, that a patient sometimes presents himself with a pure hyperemia. The conjunctiva looks bright red and shiny and is somewhat swollen by transuded serum. It is oftener the case that the cause of the hyperemia is still there, whether this be the first expression of a beginning conjunctival inflammation, or a foreign body, or a wild hair (*p. 153*) still scratching the eye. It is therefore essential, when a patient with red eyes is seen, always to examine the lashes and to scrutinize the entire conjunctiva for foreign bodies.

Treatment of a pure hyperemia—beyond removal of the cause, a foreign body or a displaced eyelash—is unimportant; the redness with all other signs of irritation disappears in a few hours.

(*b*) **Hyperemia chronica** (*Catarrhus siccus, Dry Catarrh*).—The patient complains of all sorts of uncomfortable sensations in the eye, prickling, itching, foreign body, heavy upper lids, and frequent winking. The distress increases toward evening and after use, and bears no relation to the pathological change in the conjunctiva itself. Moderate alterations in the tissue may produce severe dis-

Digitized by Illinois College of Optometry

comfort in case the lids cling to the eyeball; gross alterations are borne surprisingly well if the lids can be opened wide and are relaxed. This is true of all other diseases of the conjunctiva. In cases of dry catarrh, there is, as a rule, very little to see by merely looking at the patient, but if we examine the conjunctiva on the lids and at the fornix we notice that they are redder and rougher than normal. The inner surface of a normal lid, when inverted, is yellow and has numerous fine but plainly marked vessels running from the fornix to the edge of the lid, while a catarrhal condition is evidenced by a uniform redness, and along the upper edge of the tarsus, particularly at the sides, it seems covered with small nodules of raw flesh. These nodules appear to the naked eye like the normal conjunctiva looked at through a magnifying glass. This redness and roughness or uneven congestion is most strongly developed in the papillary body, and diminishes rapidly from the fornix toward the free edge of the lid. There is no pathological secretion.

The causes of dry catarrh are manifold. The most common is irritation by dust and similar foreign substances, and for that reason millers, stone masons, innkeepers, school children, and prisoners are most exposed to the disease. Lithiasis palpebrarum (*p. 156*) may be added to this group.

A second group of causes is found in the different conditions that hinder regular flow of tears (*p. 170 et seq.*). If the eye is constantly bathed in tears, it encourages all harmful influences, and but affirms the proverb of a classical teacher of ophthalmology that "tears are the eyes' worst enemy."

Finally, there is always the possibility that a dry catarrh is but a disease inseparable from certain occupations. For example, firemen and puddlers who must work in a fierce light, or students who for hours at a time read and write by artificial light, expose themselves to the dangers of a conjunctival (or retinal) hyperemia. To be sure, the eyes most endangered by such occupations are those already burdened with some pathological condition, such as hyperopia, astigmatism, or insufficiency of the internal recti muscles.

Treatment, in all cases due to the latter cause, must begin with the prescription of the proper glasses. In diseases of the lacrimal passages the methods mentioned on *p. 170 et seq.* must be resorted to. If the irritation is due to strong light or to dust, protective

Digitized by Illinois College of Optometry

smoke glasses can be advised. If the catarrh continues in spite of the removal of the cause, or if the cause cannot be removed, as will probably be the case when it is one of the first group, astringent applications and the eye douches are of service. I usually commence by flooding the conjunctival sac twice daily with zinc washes (*Zinc Sulph. 0.2, Aquæ dist. 30.0*). In case this does not accomplish the purpose, I apply every second day to the inner surface of the lids a two per cent. solution of silver nitrate. A drop of tincture of opium once a day or every second day has been recommended.[1] Besides these applications, which all irritate for the moment, we can use the eye douche (*Fig. 71*), which is immediately soothing. A rather powerful stream of lukewarm and later cold water is allowed to flow from three to five minutes against the closed lids, twice a day.

FIG. 71.—EYE DOUCHE.

(*c*) **Conjunctivitis catarrhalis simplex** (*Simple Catarrh*).—This begins with hyperemia, redness, and an irregular congestion of the mucous membrane, to which a profuse discharge is soon added. This discharge consists at first of a watery, slightly cloudy, sticky fluid, in which a few mucous particles float. It becomes gradually richer in cells, cloudier, and more abundantly supplied with fibrinous matter that changes to pus at the height of the disease. Since such a fluid does not easily flow through the lacrimal passages, the mucus and pus collect at the inner canthus and on the lids, and the lashes are matted together in masses. As there are more tears than normal, the lids and edges are kept constantly moist, this sufficing in scrofulous children or those with tender skin to produce a blepharitis (*p. 149*) or an eczema (*p. 144*) of the lid.

The tears dry up during sleep, and the secretion collected along the lids dries also into hard crusts that stick the lids firmly together. The hyperemia of the conjunctival vessels is extreme and general. Even the intermarginal portion of the lids and the conjunctiva bulbi

[1] I have given up touching very swollen lids with blue stone (Cuprum sulfuricum), as it seemed to me that the conjunctiva became smoother but not thinner nor paler. Some surgeons recommend acetate of lead 0.2 per cent. to 0.3 per cent., others, aluminate of copper 0.2 per cent. to 0.3 per cent., or borate of soda 0.25 per cent. to 0.5 per cent., or compresses of sublimate solution 0.05 to water 200.0.

Digitized by Illinois College of Optometry

below the fissure are congested, this being particularly the case at the caruncles and adjacent parts. At the fornix and on the lids this hyperemia is most pronounced. Even when the lids are everted and the conjunctiva thereby put on the stretch, the tarsus is invisible, for the conjunctiva is so filled with blood and saturated with exudate that it is no longer transparent. The cornea remains healthy as a rule, and only in old persons do we see a loss of epithelium and corneal ulcers resulting from it.

If the disease is left to itself it subsides within one to three weeks. The secretion lessens, and hyperemia and congestion of the conjunctiva disappear in some portions, particularly in those near the fornix. The conjunctiva here appears red, velvety, and rough, as if strewn with "papillæ." This is the condition of chronic conjunctival catarrh. It may go on to complete recovery or continue unchanged for years. The complaint made by patients with acute conjunctivitis begins as a rule with the statement that they must have sand in the eyes. This depends probably on the roughness of the mucous membrane, which scratches the cornea or the opposed mucous membrane of the globe at every movement of the eyes. The mucous particles and fibers, too, play the real part of foreign bodies. As the disease progresses this feeling of "sand" subsides, but the eyes still itch and burn so that the patient keeps constantly rubbing them. Another complaint is that the lids are heavy and tired. All symptoms are worse toward evening. Any strain on the eyes, particularly in bad light or impure air, exaggerates the symptoms. On awakening in the morning, even if the lids are not stuck together, there is always some difficulty in opening them. This is almost always symptomatic of chronic catarrh. Apart from photophobia and other discomforts the patient is distressed by optical disturbances, which arise from the deposit of mucus and pus on the surface of the cornea, and can for the time being be wiped away by frequent winking; these disturbances are hazy vision, polyopia, appearances of rays of light and colored rings and flames.

Catarrhal conjunctivitis is the commonest disease of the eye. No wonder that special importance is laid upon the question as to its cause. Its frequency among millers, stonemasons, and other workers in a dust-laden atmosphere shows that irritation by minute foreign bodies is one of them. Another source of catarrh is found in the contagious diseases, for conjunctivitis is one of the most fre-

Digitized by Harvard College Library

quent accompaniments of measles, scarlet fever, and such eruptive disorders. A bond of union may be suspected between such different causes, especially if we consider further that dirty children are most prone to an attack; that this attack nearly always affects both eyes; that a cold often, and a dacryocystoblennorrhea always, leads to a conjunctivitis; and, finally, that the disease is to a certain extent spread directly by its secretions and may appear as an epidemic. This bond of union is undoubtedly infection. On every conjunctiva there are bacteria,—some innocent, some pathogenetic, and the secretion of a diseased conjunctiva is naturally more crowded with them. The particular causes of the disease can therefore be conveyed by a bit of mucus, a dirty hand, or dust from the air, but what these bacteria are, or what kind of pathogenetic germs are necessary, is at present the subject of bacteriological investigation. For the moment the tendency is to assume that the germs produce a substance, a ptomain or toxin, the smallest quantity of which irritates intensely. This view is supported by the fact that a severe catarrh may result from the irritation of some gas, such as sulfurous acid in the atmosphere; or from the irritation of some chemical, such as corrosive sublimate in watery solution. Large-sized foreign bodies, if remaining for a long time in the conjunctival sac, may produce catarrh. Any mechanical abuse of this delicate membrane seems sufficient to irritate it.

Treatment must be directed first to the suppression of demonstrable causes—the removal of foreign bodies, extraction of wild hairs, and the cure of any affection of the lacrimal sac. The discharges and the scales must be immediately removed by washing with lukewarm water or a sublimate solution *1 : 5000*. This is simplified if the lids are anointed every evening with vaselin, pure, or sublimated *0.003 : 10*. To spare the eyes, to avoid fierce light, smoke, or dust, must be insisted on, though it is often of no avail. Direct medication aims to reduce and to dry up secretion and to encourage the swelling to go down. For this purpose the most commonly used applications are sulfate of zinc and nitrate of silver as applied in the treatment of dry catarrh. The frequency of the nitrate of silver applications depends upon the amount of discharge; if there is very much, once every twenty-four hours is none too often; if by this means the secretion noticeably diminishes, every second day will suffice, and on the intervening day a zinc solution, morning and night, may be used. Immediately after

Digitized by Internet Archive in 2010 http://www.archive.org/details/textbookofophtha00fuch

applying the nitrate of silver any remaining fluid is to be washed away by a simple chlorid of sodium solution; if the caustic effect of the silver is very irritating, cold compresses should be used for half an hour. As a rule, these means will be successful in obtaining a rapid improvement and a cure within one to two weeks.

Many ophthalmologists apply cold compresses at the commencement of a conjunctivitis. I cannot recommend it; especially as patients often resort to this domestic remedy themselves, and though the symptoms are for the moment less distressing, the condition as a whole has been made worse. If nitrate of silver and zinc are not effective, we must try other astringents, as tannin 1.0 to 30.0 or plumbum aceticum 0.2 to 30.0. It is always advisable to examine the eye again to see whether some continued cause of irritation has not been overlooked, such as a foreign body, misplaced hairs, a tear sac inflammation, improper use of the eyes, or perhaps a small corneal ulcer.

Any sequelæ of catarrh, as inflammation of the lid edge or eczema, should be treated according to the rules already given (*pp. 144 et 149*). Small fissures in the external canthus give particular trouble. Sæmisch's view is that these heal with such difficulty because the lashes of the upper lid are always injuring the scarcely restored skin in that place. Cutting off the neighboring hairs is very effective. My opinion is that these little fissures do not owe their origin to the lashes but to the hand of the physician, or to the refusal of the patient to open his lids.

(*d*) **Blennorrhea** (*Conjunctivitis blennorrhoica, sive purulenta*).—The essential characteristics of blennorrhea are redness and swelling of the entire conjunctiva, excessive formation of pus, and involvement of lids, skin, and even lymph glands behind the ear.

The secretion is at first thin, but slightly cloudy, and is of a citron-yellow color, due to blood pigment. In proportion as the secretion becomes richer in cells is it thicker and cloudier and of a more pronounced yellow; it wells up over the lid edges and lies on the lids, partly as a fluid, partly as dry crusts. The inner surface of the lids is often covered with a thin and transparent layer of coagulated secretion; these pseudo-membranes are very apt to be formed on exposure of the mucous membrane to the air. If the disease has passed its height, the secretion is less in amount and becomes more mucus-like in character. For this reason the stages have been called those of dacryorrhea, pyorrhea, and blennorrhea.

At its commencement the disease looks like a simple conjunctivitis, but in a few days the hyperemia and swelling increase enormously; the conjunctiva is red, smooth, and shiny, not only on the lid and at the fornix but also on the eyeball. The swelling of the conjunctiva on the eyeball reaches such a degree that a dark red mass crowds between the lids, *chemosis conjunctivæ*. Indeed, the inflammation involves the lid edge and the skin; the upper lid, hot,

Digitized by Illinois College of Optometry

red, edematous, with its wrinkles obliterated, hangs down above the lower, too heavy for the levator to raise it, too thick to pass into its place beneath the roof of the orbit; the ptosis is now complete. When the storm has raged its worst, the swelling of the lids and conjunctiva decreases, and at the fornix and the adjacent conjunctiva on the lid there can be seen those uneven places already mentioned, the so-called papillæ. *Fig. 72* gives an idea of the anatomical changes in the conjunctiva of the lid: A large papilla is seen; at the base of it are cross sections of blood-vessels (*a a*), and just beneath the epithelium is a network of finer ones (*b b*); the whole papilla is strewn with round lymph or pus cells, particularly abundant near the vessels. The upper layer of epithelium consists of

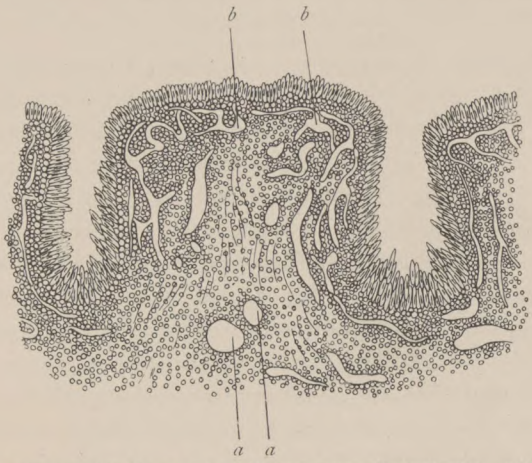

FIG. 72.—HYPERTROPHIED PAPILLÆ OF A BLENNORRHEIC CONJUNCTIVA. (*After Sæmisch*)

cylindrical cells that appear remarkably long in the pits between the papillæ.

The disease, if left entirely to itself, can run its course to complete recovery in two or three weeks. The skin and the conjunctiva of the globe are the first to recover their normal character; the conjunctiva of the lids the last. As a rule, however, recovery halts half way; the swollen papillæ do not shrink together, the production of pus and mucous does not completely cease, and acute blennorrhea passes into the chronic stage. This may last for months or years, and at any moment the inflammation may blaze up into an acute form again. The change from acute to chronic blennorrhea is not always the worst that may threaten the patient.

Digitized by Illinois College of Optometry

This disease, much more than a simple conjunctivitis, has the tendency to cause corneal ulceration, and may thereby destroy the eye (panophthalmitis ending in phthisis bulbi), or may at least do great damage (leucoma or corneal scars). The reason for this danger to the cornea is easy to see. The intense swelling of the conjunctiva near the cornea squeezes the blood-vessels that carry nourishment to it; the swollen and stretched upper lid irritates the cornea mechanically, the ceaseless flood of pus macerates the protective epithelium, and finally, if the smallest crevice appears in the epithelium, the nature of the pus is such that a direful infection results through the wound.

I have just been observing two cases in which panophthalmitis developed after years had passed. In one case the eye had been completely quiescent after a blennorrhea and suppuration in the cornea, in the second the inflammation had been lighted up at intervals.

The symptoms of the patient are about the same as those of a simple conjunctivitis. It should be mentioned that the severe pain at the commencement generally diminishes as soon as "pyorrhea" begins.

FIG. 73.—GONOCOCCI IN THE EPITHELIAL CELLS. (*According to Bumm.*)

The cause of the disease is better known than is that of any other conjunctivitis. We are sure that a well-defined germ, the gonococcus of Neiser (*Fig. 73*), is the cause of all malignant cases and is present in many of a milder type.

The source of the infection can usually be detected without difficulty. Many children are infected during or after birth by the coccus-bearing mucus of the maternal passages, *Blennorrhea neonatorum.* In other cases patients infect themselves by carelessly wiping the pus of a clap into their eyes with their hands, the right eye being most often affected—*Conjunctivitis gonorrhoica.* This kind of affection is found only in men and female children.

Conjunctivitis gonorrhoica has two characteristics to distinguish it from blennorrhea; first, the swelling of the upper lid to a board-like hardness, and second, swelling of the lymph glands in front of the ear. Conjunctivitis gonorrhoica is rare in proportion to the frequency of clap. This is due less to caution and cleanliness on the part of the clap sufferers than to the circumstance that gonorrheal pus loses its infectiousness by being so thinned with fluids and by being long in a dry state.

Every blennorrhea is not caused by the gonococcus. There

Digitized by Union College of Ophthalmology

are other germs, presumably, that can produce similar changes in the conjunctiva. At any rate, many blennorrheas, especially those of the new-born, have been observed without the gonococcus, but these cases are essentially distinguished from those caused by the gonococcus by a later onset, at the fifth to the twelfth day after birth (the malignant cases begin on the second or third day), by a milder course, and particularly by a shorter period of life and by the immunity of the cornea.

Again, mechanical and chemical accidents to the conjunctiva can start up a condition of blennorrhea.

Sæmisch mentions that an "artificial eye" may at times cause considerable irritation to the conjunctiva, and in case it is not taken out at once, it may even produce a blennorrhea. I myself once had this experience: I was called to see a peasant, whom I found with the perfect picture of a fresh blennorrhea, and wild from pain. After questioning him I found that he had a mild conjunctival catarrh, and at the advice of a friend had bathed it with a mixture of salt and French brandy! Undoubtedly this friend had observed that physicians "stimulated" inflamed eyes, and he had imitated the process according to his light.

Treatment should be, above all, to avoid the disease. *By proper precautions every case of blennorrhea neonatorum can be prevented.* To Credé belongs the immortal honor of having found an effective agent against it. His method consisted in carefully cleaning the eyes in the bath and then in dropping a few drops of a two per cent. solution of nitrate of silver "exactly on the cornea" of any child born of a mother with a gonorrhea. The drops spread over the conjunctiva, scale off the superficial epithelium, and thereby destroy all gonococci that have not so far penetrated beneath the surface.

Since this disinfection is always painful (perhaps to a tender mother more than to the child), and causes a conjunctival hyperemia, it has been proposed to replace Credé's method by washing with sterilized water, chlorin water, solution of potassium permanganate, or even with corrosive sublimate 1 : 5000. Ahlfeld would not disinfect the conjunctiva at all, but would replace that by radical disinfection of the lying-in woman. This may be possible in a well-conducted obstetrical hospital, but in ordinary practice it is out of the question. Preference must be given without condition to the simple and sure method of Credé, although the drops need not fall "exactly on the cornea," so long as they reach the conjunctival sac in some way.

Prophylactic measures must be taken for the other eye, in case the patient comes to the physician with only one eye attacked. In adults (conjunctivitis gonorrhoica) it is best to wash and disinfect the sound eye externally and then to wash out the conjunctival sac with sublimate solution *1 : 5000*, and immediately afterward to isolate it with a bandage of sublimate cotton. In infants such a

Digitized by the Internet Archive of Ophthalmology

bandage is impracticable; we must be content to instruct the mother or nurse, and to have the child lie so that the pus welling from the diseased eye may not overflow into the healthy one.

Fraenkel has had good results with no bad luck in applying daily a drop of two per cent. nitrate of silver to the healthy eye.

If the disease is once started the best method to pursue is the following: the attendants must get a large bottle of sublimate solution *1 : 5000*, a package of absorbent cotton, and be directed to open the lids every hour of the day and night, to wipe off the pus with moist sublimate cotton, then to dry the eye and to put in the fissure and on the lids some vaselin, either sublimated (*0.003 : 10.0*) or borated (*1 : 10.0*). This prevents, to a certain extent at least, the pernicious action of the pus on the epithelium of the cornea and on the tender epidermis of the lids. The physician must paint the conjunctiva of the lids and fornix *once a day with two per cent. solution of silver.* In the second stage, if the conjunctiva is thick and velvety, stronger solutions, say five per cent. of nitrate of silver, are indicated. In the third stage the two per cent. solution can be returned to, but the application need be made only every second day, in the interval zinc solution being used.

Results from such treatment are good. As a rule, decided improvement is already noticeable after the first or second application, but several weeks are necessary to effect a complete cure.

The cornea must be watched continuously, and any attack on it should be treated according to the principles given on *p. 234*. Corneal involvement is no contra-indication to the nitrate of silver treatment. In blennorrhea of the new-born the disease, as a rule, runs its course without attacking the cornea; in conjunctivitis gonorrhoica of adults, on the other hand, the cornea is very often destroyed, or at least endangered.

Many surgeons apply constant ice poultices during the first stage of the disease (dacryorrhea). I consider this superfluous, if not harmful. It must also be mentioned that formerly it was quite general to resort to cauterization with the nitrate of silver pencil, or with the lapis mitigatus (*Argent. nit. 1.0, Kali 2*). I could never induce myself to use it, nor can I ever see wherein lies the advantage of the pencil over fluid applications. Local blood-letting has been used; that is, scarifications by shallow, longitudinal incisions in the conjunctiva of the fornix. Bloodletting is indicated where a peculiar dark-red color of the mucous membrane suggests a slow and impeded blood current. If the lids are strongly everted, a profuse hemorrhage may take place spontaneously. It may sometimes be necessary to split the external canthus down to the

Digitized by Illinois College of Optometry

orbicularis muscle, and to keep the wound open for some time, in order to relax the upper lid and thus to lessen the serious pressure of this lid on the cornea. At the same time the hemorrhage caused by this procedure acts favorably in reducing the congestion of the conjunctiva.

(*e*) **Conjunctivitis crouposa** (*C. membranacea, Croupous Inflammation*).—The picture of this disease is in many respects even to-day a confusing one. One author declares that it is very infrequent, another says that it is common; one calls it mild, another severe; one affirms it to be infectious, another not. At any rate, we may conclude from this that the disease appears in many forms and is of variable frequency in different neighborhoods. It is characterized as a more or less pronounced inflammation of the conjunctiva of the lid and fornix, with the formation of a yellowish membrane which can be rather easily lifted from the mucous surface. Such a description may under certain circumstances be given to blennorrhea also, and it may occasionally happen that the same case will be called by one surgeon conjunctivitis crouposa, and by another blennorrhea pseudo-membranosa. Nevertheless, it is quite possible, and therefore of practical importance, to distinguish these two forms of disease, because treatment of the croupous inflammation of the conjunctiva is quite different from that of the suppurative form.

At the beginning the lids are swollen and red, but soft and only moderately sensitive. The upper lid, heavy and immovable, hangs over the under one. Between the lids there wells up in more or less profusion a quantity of watery secretion mixed with a little mucus. If the lids are everted, one finds in severe cases the whole conjunctiva of the lids and fornix covered with a yellowish, untransparent membrane; in the worst cases the conjunctiva of the globe is also affected, being congested and covered with the same membrane; but in the mildest cases the croupous membrane consists of only small white islands lying near the edge of the lid and leaving the fornix and the entire conjunctiva bulbi free. If the covering is detached there is a slight hemorrhage from the mucous membrane, leaving it rough and pimply, dark-red, and rather swollen. This covering is formed anew on the next day. After a period of from two to six days the membranes are cast off of themselves and are not renewed, while at the same time the secretion becomes ordinary pus, the conjunctivitis crouposa having entered upon the blennorrheal stage, from which it may pass to a complete cure. In many cases the course is different. The membrane, whether torn or cast off, is repeatedly formed anew. Manz reports a case in which membrane was still forming after half a year. In about *40* per cent. of cases there is a mild or severe corneal infection. The majority of cases, however, heal quickly and completely.

Pathological anatomy of these croupous membranes shows them to consist of fibrin fibers filled with pus and epithelium cells. Distinct layers are demonstrable in them; their structures being, therefore, the same as that of the membrane in laryngeal croup. The thickness of the membrane may vary from *0.1* to *1.5 mm*. (Knapp).

In considering the origin of the disease we must notice the circumstance that it usually appears on children with eczematous skin eruptions on the head, and with other signs of scrofula. If one remembers, moreover, that according to Lotz half the children are attacked in only one eye, and that the eye which remains unattacked, in spite of neglected precautions, belongs to that side of the head which is also free from eruption, the conclusion cannot be avoided that the skin eczema is the cause of the disease. The why of the case may find some solution in the great epidemic that raged during 1882 to 1884 in many centers of ophthalmic activity: At v. Wecker's suggestion many surgeons tried to cure a corneal pannus by painting the conjunctiva with a watery extract of jequirity seeds. This always produced a regular croupous conjunctivitis and often the desired subsidence of the pannus. But since the effect of jequirity is to a certain extent purely

Digitized by the Internet Archive in 2010 with funding from University of California Berkeley Optometry

chemical, the idea suggested itself that the secretion from an eczematous skin surface was the cause of an analogous effect on a susceptible conjunctiva. This by no means excludes the possibility of germs producing the same effect. Many cases have been described in which conjunctival croup appeared simultaneously with laryngeal or tracheal croup, presumably from the same cause.

Treatment, tested in Schiess' clinic, and recommended by Lotz, begins with an attack on the skin eczema, the principal dependence being placed on applications of white precipitate ointment (*Hydrarg. præcip. alb. 1.0, Vaselin 20.0*) to the skin. The eyes are washed several times daily with a carbolic or sublimate or boric acid solution, and the membrane carefully removed if possible. The chief local treatment consists of nearly continuous compresses of lukewarm lead water to the eyes.[1] Applications of nitrate of silver are unconditionally forbidden and may not be applied until the croupous condition has passed. With this treatment a cure will be obtained in from ten to thirty days. Any corneal disease showing itself is to be treated according to the principle given on *p. 226*. Special protective measures need not be taken for an unaffected eye, although, of course, an infection with secretion must be carefully avoided, for every conjunctival secretion contains germs of various kinds. Even if in one case they were only harmless parasites, it must not be taken for granted that in another case they would not produce disease.

(*f*) **Conjunctivitis diphtheritica.**—The production of coagulating secretion on the surface of the conjunctiva is characteristic of croup, but in diphtheria there is an inflammatory condition in which a firm exudate lies within the tissue of the mucous membrane itself. The croupous membrane may therefore, in the severest cases, carry the epithelium with it, but when the diphtheritic membrane is cast off the mucous membrane itself is destroyed also. A croupous mucous membrane heals with restoration of its former structure; a diphtheritic mucous membrane always heals with the formation of scar tissue.

Conjunctivitis diphtheritica always produces a grave disturbance of the general system, with fever and its consequences. The local picture is that of blennorrhea at its height. To avoid repetition I shall give here only the differential diagnosis: In diphtheria the upper lid is bluish-red and so swollen that it feels hard and unyielding. To the touch it is hot and exquisitively sensitive, so exquisitely sensitive that even the hands of a v. Graefe or a Horner were unable to evert the lids so as to see the inner surface without making the patient shriek with the frightful pain; chloroform had to be used in order to make a proper examination. In the worst cases a complete eversion of the upper lid is impossible. If the upper lid is raised an abundant, thin, discolored fluid, full of yellowish flakes,

[1] Warm compresses of three per cent. boric acid solution have been equally efficacious in my hands, and are free from the danger of lead deposits.

Digitized by Illinois College of Optometry

escapes. The conjunctiva of the lid appears grayish-white, smooth, and porklike. Blood-vessels are absent or only partly visible; the conjunctiva of the globe is chemotic and spotted with small hemorrhages, in the worst cases looking like a piece of raw ham. If the conjunctiva is cut no blood escapes, since the vessels are strangled. This condition needs two to five days for its complete development, and then remains for some time, even as long as eight days, unchanged. The second stage of the disease now begins. The conjunctiva becomes spongy, relaxed, and full of blood; the exudate poured into the mucous membrane is partly absorbed and partly thrown off with the necrotic tissue. The secretion becomes purulent, the eye looks "blennorrheic," but the condition is quite different. In blennorrhea the red papillæ are part of the swollen mucous membrane, while in diphtheria they are wound granulations. Moreover, the sequelæ are quite different; in the one case restoration of normal tissue, in diphtheria formation of a cicatrix tissue, resulting in a condition called *xerosis parenchymatosa* (*p. 202*). This atrophy can lead to symblepharon (*p. 217*) and to malpositions of the lids, and may thereby endanger the visual power of the eye. At the height of the disease one would scarcely think of these curæ posteriores, since the integrity of the eye is threatened by the infinitely greater danger of infection of the cornea. Of the ravages of the disease we may form some idea from the fact that of *40* cases in children treated by A. v. Græfe from the beginning, nine eyes were totally destroyed and three seriously injured; in adults it was even worse: of eight eyes, three were destroyed, two escaped with severe, and the remaining three with mild impairment of the cornea.

The disease of the cornea begins as a rule with a yellowish infiltration of the center. As the epithelium is cast off the infiltrate changes to an ulcer that increases the more rapidly in breadth and depth the earlier the cornea was attacked.

Diphtheria results from infection. There is no doubt that infection with the gonococcus of Neisser and with the diphtheria bacillus of Klebs-Lœffler can produce a conjunctival diphtheria. Whether the same is true of other germs is not known. It is worthy of mention, however, that badly treated wounds, such as the pits of blepharitis ulcerosa, occasionally show a diphtheritic covering that spreads in isolated patches over the conjunctiva; but these foci of diphtheria are a relatively benign disease—a fact that may suggest an origin from some other germ. A purely chemical

Digitized by Illinois College of Optometry

action may produce an anatomical picture of diphtheria; we see this in the injuries resulting from unslacked lime, from acids, alkalies, jequirity, and burns with molten metal.

Treatment must be directed largely to the protection of the healthy eye (*p. 191*), if such there be, both on account of the infectiousness and of the malignity of the disease. If the disease is once started, treatment seems to be futile.

Ice compresses, once so warmly praised by v. Graefe and others, seem of late years to have met with a cool reception, and by Berlin, Burkhardt, and others have been altogether rejected, because the conjunctiva is already anemic and is endangered in proportion to this impoverishment of protective blood supply. Perhaps modern ideas are better conformed with if the active attacks with ice, blood-lettings, and such are omitted, and if reliance is placed only on frequent cleansing of the eye with a mild antiseptic and the use of lukewarm boric acid compresses. The incision through the outer canthus, canthoplasty, cannot always be avoided; it reduces the pressure of the upper lid on the already poorly nourished cornea. If the membrane begins to be cast off there is no doubt of the efficacy of hot compresses and mild astringents. As Horner says, caustics are to be omitted, since they would only encourage cicatricial contraction. At the most, when pus is freely produced or when the isolated granulations are unusually profuse, silver nitrate is indicated.

Walfring advises massage of the inner surface of the lid with yellow precipitate ointment. Is this possible, considering the frightful pain of severe diphtheria? Fieuzal has seen good effect from lemon juice, Mayweg from iodoform powder, Tweedy from quinin solution, Vossius from salicylic glycerin solution, and Hotz from carbolic-iodin-alcohol solution. The more hopeless the results of treatment, the greater the number of remedies exploited.

2. INFLAMMATIONS WITH FORMATION OF FOLLICLES.

(*a*) **Conjunctivitis follicularis** (*Follicular Catarrh*).—It is still a disputed point whether lymph follicles (*p. 182*) are normally present in a healthy conjunctiva, but this much is certain, that in a healthy conjunctiva no lymph follicles can be seen with the naked eye. In the disease under discussion, on the contrary, the naked eye can see them on the mucous membrane as pale red, more or less translucent, roundish protuberances. They lie in the fornix of the lower lid (*Fig. 74*), row on row; the upper lid is free, although at the inner and outer angles small clusters may be found.

Digitized by Illinois College of Optometry

Follicular catarrh may be acute or chronic. The acute form begins as a simple conjunctivitis, that is, with a secretion at first of a watery but finally of a muco-purulent character. During the first week of the disease suspicion may be soonest awakened by the circumstance that the fornix in particular seems reddened and swollen: the follicles are already there, though not yet visible. They cannot be seen till the congestion of the conjunctiva recedes, when they glisten faintly through the overlying membrane. If the hyperemia and swelling of the conjunctiva recede still more, the follicles rise above the surface and complete the pathological picture. A noteworthy sign deserves mention, namely, that the lower lid is somewhat crowded away from the eyeball by these follicles, in such a way that between the lid and the ball a pit is formed, which is filled up with tears. Michel declares that besides this, in the majority of cases the lymph glands in front of the ear are swollen.

Follicular catarrh may develop without acute symptoms, warranting us in speaking of a chronic form of the disease. Its duration is very variable, lasting sometimes four to eight weeks, sometimes months and years. Healing takes place by absorption of the contents of the follicles and disappearance of the nodules.

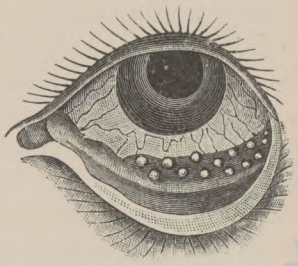

FIG. 74.—NODULES ON THE LOWER FORNIX IN FOLLICULAR CATARRH. (*After Sichel.*)

The obstinacy of follicular catarrh suggests the conclusion that it is a much more severe disease than simple conjunctivitis. A further evidence of this lies in the fact that follicular catarrh is more prone to relapses, and to attack the cornea during its course. This latter shows itself at first with "pericorneal injection," the precursor of shallow ulcers at the corneal margin. Since these ulcers are in the immediate neighborhood of blood-vessels (*Fig. 80, p. 221*), every circumstance favors a speedy vascularization and recovery. A farther difference from simple catarrh lies in the facts that the follicular form is more infectious than the simple, both eyes being nearly always attacked, and that epidemics are not infrequent; schools, barracks, asylums, prisons, in short, all buildings where persons are penned together, provide a romping ground for such epidemics. Suspicion has been directed against some germ as the cause of the disease, and investigators have

Digitized by Illinois College of Optometry

attempted to demonstrate a micrococcus which by many is considered identical with the trachomacoccus (*p. 203*).

Follicular catarrh is said to be produced by chemical action, especially by atropin, as well as by infection. It is a fact that the continued use of atropin will light up a follicular conjunctivitis, but another fact is that atropin solutions, as formerly used without the addition of some sublimate, become full of germs after awhile, so that together with the atropin all manner of germs were dropped into the conjunctival sac. Many investigators, like Raehlmann and Michel, discard the term "atropin conjunctivitis," while others insist that sterile solutions and even dry atropin are capable of producing follicular catarrh. Nevertheless, "atropin follicles" have grown less since dry atropin was placed on the conjunctivitis. I cannot say that I have ever seen an undoubted case of it.

As compared with that of simple catarrh, the prognosis is unfavorable on account of its prolonged course and tendency to relapse, but as compared with that of trachoma, about to be described, it is favorable, for the follicles disappear, no scar remains, the tarsus is unaffected, and the cornea is not seriously attacked—conditions that all prevail, unfortunately, in trachoma.

Treatment should begin with measures to protect the healthy eyes of the patient's associates. If there is an epidemic in the house, the sick should be isolated, taken care of in well-ventilated rooms, and encouraged to pass as much time as possible outdoors where the air is free from dust. Without this "fresh-air cure" too much cannot be expected of local treatment. As far as this is concerned, it is a rule that the follicles themselves do not need direct treatment. The hyperemia and swelling at the fornix can be attacked with shallow incisions, the pathological secretions by the remedies mentioned under the treatment of simple catarrh. The secretion itself must be washed away with sublimate solution and made harmless. If in spite of this treatment the absorption of the follicles is delayed, the fornix may be touched every second or third day with "blue stone" (a pencil of sulfate of copper polished smooth with a wet cloth). The smarting that follows and lasts for about half an hour can be soothed and shortened by cold compresses. The subsequent short but pronounced hyperemia that follows encourages the absorption of the contents of the follicles. If this does not achieve its purpose, the follicles may be squeezed out with ciliary forceps (*Fig. 59, p. 150*) after cocainizing the conjunctiva, of course.

If corneal ulcers appear, atropin and a bandage are indicated, while zinc, nitrate of silver, copper, or other astringents are to be avoided.

Digitized by Illinois College of Optometry

In spite of its frequency and in spite of numerous and painstaking investigations, the nature of trachoma is not as yet so clear as that of blennorrhea. There is not even unanimity concerning its infectiousness. The fact that trachoma is epidemic in barracks, schools, and among sailors is claimed by some as a proof of its infectiousness, but by others as a proof of its myasmatic nature. The regular involvement of both eyes is by some called an illustration of its infectiousness; the rare but well-authenticated cases of one-sided trachoma are used as illustration against it. In spite of all this we can say with Sæmisch, H. Cohn, and others, that the trachomatous secretion is infectious, not through the air, like measles and small-pox, but by direct contagion. This infection happens, as a rule, after the common use of handkerchiefs, wash-bowls, and towels, or by the contact implied when the well and the sick sleep together.

As we view the matter to-day, we are inclined to assume that some specific germ is the cause of trachoma. Investigation directed to discover this trachoma germ has given results that are not quite harmonious. This may be said, too, of the germ of follicular conjunctivitis. The question is not yet solved whether trachoma and follicular catarrh are different diseases. Many investigators assume that the same germ may produce at one time a mild disease called follicular catarrh, and at another a severe disease called trichoma. Indeed, many imagine that chronic blennorrhea is a third leaf on the same tree, and that the gonococcus of Neisser is the ultimate cause of them all. This view finds support from the observed fact that contagion of a healthy conjunctiva from pus of a chronic blennorrheal conjunctivitis will in certain cases produce a trachoma and not a blennorrhea. The demonstration is not a perfect one, since the secretion of a chronic blennorrhea is undoubtedly the home of many kinds of germs. The view finds no support from the fact that individuals differ in the resistance to trachoma, and that trachoma is limited to well-defined regions, which is not at all the case with blennorrhea and gonorrhea. The view that trachoma and follicular catarrh are the same is moreover, actually denied. Foerster and H. Cohn consider it only a question of time when the individuality of each disease will be recognized by all surgeons. There remains only one fact more to be mentioned: that another germ altogether, which no one has as yet called the real trachoma bacterium (that is, the tubercle bacillus), is able to produce a typical clinical picture of trachoma in its second stage (*p. 206*).

As a rule, young persons in the second or third decade of life are more inclined to trachoma. The poor are oftener attacked than those in comfortable circumstances, a fact easily explained by the greater care and cleanliness of the latter. Poorly nourished persons, those suffering from scrofula and tuberculosis, are said to supply a relatively large number of cases of severe trachoma. Negroes are said to be nearly immune. Trachoma is a disease of low lands, flat coast districts, and river valleys. Elevated regions are free from it. Here in Zürich, trachoma is rare; in the Baden Oberland it is infrequent, but near the mouth of the Main it is seen oftener, and from there downward in the Rhine Valley it increases till it reaches its greatest luxuriance at the mouth of that river. Two hundred meters above sea level trachoma loses its contagiousness to a certain extent, although many elevated districts become infected by the numerous immigration of trachoma cases. If a trachoma patient travels to a dry altitude his disease runs a comparatively rapid and favorable course.

The prognosis is unfavorable. To be sure, a cure may take place, but after such a long delay, and after such an abundant proliferation of granules, that all the conjunctival tissue capable of producing them has been destroyed and replaced by cicatricial tissue.

Digitized by Illinois College of Optometry

The resulting condition, the xerosis of the conjunctiva, is of itself the source of many disturbances.

Normal conjunctiva is moist and smooth, for the reasons that the gentle irritation of conjunctiva on cornea is reflexly a cause of the secretion of tears, and that the conjunctival glands themselves secrete a small amount of mucus. Xerosis cuts off both supplies of moisture by closing the ducts of the lacrimal gland with a scar, and by destroying the glandular cells lying in the bed of the conjunctiva.

The dryness of the conjunctiva is very disagreeable to the patient, and leads to a certain distress in all movements of lids and eyes. It induces, moreover, a change (a dryness) in the corneal epithelium, which is of direct influence on the visual power. Entropium and trichiasis are also immediate results of cicatricial contraction, and modify vision materially. The consequence is that the disease attacks the cornea directly, and in the great majority of all cases enfeebles the vision by incurable corneal opacities. In some cases the prognosis depends on the greater or less abundance of granulations formed, and on the treatment.

Treatment, taken altogether, is encouraging, and would have even more successful results if it were not impossible for many patients to continue it as long as may be necessary. Treatment should begin by telling the patient of the infectiousness of the disease and of the usual sources of infection, as towels, handkerchiefs, etc.; the proper advice (often ignored) as to cleanliness of rooms and clothing should be given. If the patient is scrofulous or tuberculous, his habits of life should be made as favorable as possible. It is a good plan to send patients to a high altitude, although this is often impossible, since the poor are usually the victims of trachoma and the ones who apply for treatment. For local treatment there are numberless applications. I shall discuss here only those best approved,—copper, surgical treatment, and, the latest method, massage with sublimate solution.

The *copper* pencil is suitable for both first and second stages. It is applied by everting the upper lid and rubbing the polished pencil gently into the fornix first, and on the back of the lid afterward. Ripe granules are broken and their contents thereby squeezed out. The effect of this is, as a rule, quite favorable, both to the granules and papillæ, as well as to the pannus. Small corneal ulcers oppose no obstacle to it, and heal quickly after the copper application. If the discharge is a very abundant pus, however, nitrate of silver in two per cent. or five per cent. solution can be used. This cautery

Digitized by Illinois College of Optometry

with blue stone (the copper sulphate pencil) may be daily repeated. Many patients who cannot visit the physician every day, learn to make the application themselves. As a rule, its effect passes off in the course of time and improvement ceases, and some new remedy must be then tried.

In case the surface of the mucous membrane hypertrophies, which would obviate the fear of conjunctival contractions, *excision* of the redundant folds of the fornix may be practised—strips of conjunctiva *10* to *15 mm.* long and *2* to *3 mm.* broad being removed without fear; many surgeons cut out pieces *3 cm.* long and *0.6 cm.* broad, including sections of the tarsus! The wound should be carefully sutured. A noticeable improvement generally follows this excision. For pannus we have another surgical expedient; assuming that pannus depends on a purely mechanical cause, the scratching of the granules on the cornea, it has been proposed to counteract this by splitting the external canthus. Pannus is by no means, however, traceable in every case to mechanical irritation, although undeniable influence on the disappearance of pannus must be ascribed to the effect of thus relaxing the tension of the upper lid.

The latest method is that of Keining. It consists in a firm *massage* to the exposed conjunctiva of the upper lid with a wad of cotton soaked in *1 : 2000 sublimate solution.* To reach the fornix the everted lid must be still further turned over, while the patient looks downward as much as possible. The dryer and harder the granules and hypertrophies of the conjunctiva are, the firmer should the rubbing be; while the more hyperemic and softer the conjunctiva, the more gently must it be handled. The results of this method are most encouraging, according to v. Hippel. The granules recede without leaving scars; pannus, small ulcers, and infiltrates are quick to heal, and the time required for treatment is much shorter than by the other methods. Relapses or sequelæ are not prevented by it, but they heal very quickly when the method is again used.

I prefer massage with iodoform powder to that with sublimate solution. The powder does not leave behind the ugly gray coating that may on the following day demand a postponement of the treatment. Iodoform massage is also less painful to the patient.

Distorted positions of the lids and lashes must be treated according to the principles on *p. 163*. Corneal opacities, depending on pannus, if they are still capable of absorption, are to be treated by

massage. The discomforts of an atrophied conjunctiva (xerosis) are lessened by the use of milk as an application.

(*c*) **Conjunctivitis tuberculosa.**—The resemblance of this disease to trachoma is so great that the differences should be specially mentioned. In tuberculosis there are follicles, papillary hypertrophies, ulcers, and pannus; but while cicatrization and healing does result in trachoma, in tuberculosis, on the other hand, the ulceration and the hypertrophy continue unlimitedly and end finally in complete destruction of the surface of the eyeball. Tuberculosis is therefore a still more dangerous enemy than trachoma, and it is of importance in choosing the treatment to differentiate it clearly from trachoma. This is not easily done, and has been made possible only within a recent period. The diagnosis depends upon the following facts: Trachoma attacks both eyes as a rule; tuberculosis, on the other hand, is almost always confined to one eye, and if, as in a case of my own, it does appear in both eyes, the stage of the disease is so different in each eye that this very difference simplifies the recognition of the picture. The swelling of the lymph glands in front of and beneath the ear and on the neck as far as the chin, is very noticeable in tuberculosis, and sometimes there may even be suppuration from them; but in trachoma, especially in mild cases, these lymph glands play a very modest rôle. The ulcers in tuberculosis are decidedly greater than in trachoma. Finally, it indicates tuberculosis if there are hypertrophies in the lacrimal sac and in the nose.

The conditions mentioned here arouse the suspicion of tuberculosis; the proof of it is supplied only by the histological and bacteriological demonstration of tubercle bacilli in the secretions of the tissues.

The disease results from inoculation of the tubercle bacillus on the conjunctiva. In one case the patient himself provides this inoculation by rubbing his eyes with fingers that are soiled with some tubercular poison, like the sputum. In another case the disease may spread from the nose through the tear sac on to the conjunctiva. In a third case a foreign body may be the carrier of the disease. Fuchs has observed that the favorite seat of a foreign body beneath the upper lid (about *2 mm.* from the posterior margin) is often the initial spot to be infected with tuberculosis.

The prognosis is very unfavorable. Left to itself, the disease leads to destruction of the eyeball. Not only does the whole cornea grow opaque with pannus, but the sclera itself becomes saturated with tubercle and granulations until, finally, the eyeball atrophies and the condition of phthisis bulbi is produced. If an early and appropriate treatment is begun, a cure may be effected in some cases and an improvement in others.

Treatment, like that of tuberculosis in other parts of the body, is both general and local. The general treatment consists in life in the pure, open air, care of the skin, and abundant nourishment. The local treatment must effect the destruction of all tissue involved. The boldness of surgical interference must, however, be modified by the fear of producing too great a scar, with its consequent disasters. According to Haab's experience, the best plan is to remove all comb-like excrescences and growths with knife and scissors, to curette ulcers with a sharp spoon, and to destroy small punctate and nodular foci with the actual cautery. All this, as a rule, cannot be done at one time, but must be extended through several operations.

3. CIRCUMSCRIBED DISEASES.

(*a*) **Conjunctivitis catarrhalis estiva** (*Hypertrophia epithelialis estiva*, *Phlyctena pallida*).—This disease forms a bridge, so to say, to that group of diseases having their principal seat on the conjunctiva of the eyeball. The changes produced by *spring catarrh*

Digitized by the Internet Archive in 2010 with funding from University of Toronto

lie chiefly at the "limbus," that is, at the spot where the conjunctiva passes over into the cornea, but in the majority of cases there is at the same time a similar involvement of the conjunctiva of the upper lid. The disease attacks both eyes, preferably of country children from five to fourteen years old. It appears in the spring with the beginning of warm weather, continues with slight changes about the same through the summer, subsides gradually in the fall, and appears again in full activity the next spring. To this peculiarity is due the name of "Spring catarrh." The patient complains of a pricking pain, photophobia, and a moderate "weeping" or secretion of tears, with light, stringy mucus. On examination, the surgeon first notices, as a rule, a sleepy look, that is, a very slight droop of the upper lid. In the fissure a few large blood-vessels are visible, which course from the canthus toward the cornea, to sink into the grayish and swollen limbus. The limbus injection appears in various characters; at one time a jelly-like band surrounding the cornea, at another a chain of dots, red in the fissure but pale above and below; or this limbus injection may be limited to the fissure, forming two triangles with bases on the cornea and apexes pointing toward the inner and outer canthus. If the lids are everted a second sign of the catarrh will be noticed, the soft and pale appearance of the whole conjunctiva; it looks, says Horner, as if it were covered with a thin film of milk. The third diagnostic sign is a hypertrophic growth of the conjunctiva of the upper lid. At one time there are only a few flat, pale protuberances sitting on a thin trunk, like mushrooms, or again there are so many of them that they crowd against each other, being separated only by delicate furrows. These hypertrophies have often led to confusion between spring catarrh and trachoma, but the lack of follicles and the freedom of the cornea from involvement should prevent such a confusion.

The essence of the disease is a pronounced thickening of the epithelium and a round cell infiltration of the tunica propria conjunctivæ; a new growth of connective tissue is found later. The thickening of the epithelium is the reason for the peculiar soft, white discoloration of the mucous membrane.

The prognosis is favorable, even though the disease may last for years; Horner mentions a man twenty-five years old, "who has had this 'Easter present' since his thirteenth year." But after the disease has exhausted its strength, nothing remains behind except a feeble discoloration of the mucous membrane, some furrows on the inner surface of the lid, and in a few cases an opacity of the edge of the cornea.

Treatment is practically futile. Astringents and stimulants are poorly borne; excision or cautery of the hypertrophies are well borne, but the result from them is seldom a lasting one. The best plan is to use a mild eye-water (*Zinc sulfat. or Plumb. acet., 0.1 to 30.0*), and to insist on suitable habits for the patient, such as avoidance of smoke, dust, or hot and drafty rooms. Protective glasses must be prescribed.

(*b*) **Conjunctivitis phlyctenulosa** (*Eczematosa, Scrophulosa lymphatica, Eczema of the Conjunctiva*).—This disease is characterized by the eruption of temporary vesicles and pustules (phlyctenules). These phlyctenules are always on the conjunctiva bulbi, but may be of different sizes and of varying distances from the cornea. Two types of eczema are therefore described. One is called by Horner the *solitary* form; it begins so quietly at times that the patient does not notice it, and has his attention called only to the redness of his eye. In other cases the development of the pustules or of one pustule begins with a pricking pain, photophobia,

Digitized by Illinois College of Optometry

and lacrimation. The vesicles form flattened prominences of from *1* to *4 mm.* in diameter; their color is grayish-red and noticeably paler than the deep red surroundings. The light red conjunctival vessels can be distinguished from the bluish episcleral vessels shimmering below them. The reddened mucous membrane is only moderately congested and passes gradually into healthy tissue. The vesicle consists of a collection of round cells beneath unaffected epithelium. This epithelium is, as a rule, cast off after a few days, and the vesicle becomes an ulcer which rapidly flattens out, while epithelium is developed above it from its edges. As the epithelial covering is reproduced the inflammation declines by degrees from the edges toward the center, so that after a week or so only a reddened point can be seen at the spot of the healing phlyctenule. Single (solitary) phlyctenules grow, as a rule, in the path of the fissure, a few millimeters from the margin of the cornea, being seldom found within the cornea itself. The disease is serious only when phlyctenules are too near the cornea. When present on the conjunctiva they heal without a trace, but when on the cornea there is usually some opacity left behind.

The second form is called the miliary or *multiple*. It develops usually with signs of decided irritation, severe pain, photophobia, and even spasm of the lid. The lid is swollen and red; the injection of the eye is severe and extensive; the limbus conjunctivæ is swollen and strewn with minute phlyctenules that look like grains of sand. If the lid is everted its conjunctiva is swollen, velvety, and red. There is an abundant muco-purulent discharge, which is lacking in nearly every case of the solitary form. The course of the miliary form is extremely rapid. The disease soon reaches its height, remains unchanged for a few days, and then as rapidly disappears, either with or without ulcers.

This eczema of the conjunctiva usually attacks children from four to fourteen years old, although it may occasionally be seen in adults. Scrofulous children are particularly victims, that is, children who suffer from eczema of the upper lip or nose, of the skin near the eyes or behind the ears, and of the scalp; and also those who have swollen glands behind and below the jaw, and who suffer from catarrhs of other mucous membranes, particularly that of the nose. The miliary form attacks also children who have just recovered from measles or scarlet fever. Eczema of the conjunctiva attacks one or both eyes; or it may change, healing in one eye

Digitized by Illinois College of Optometry

while it breaks out afresh in the other. The disease has a decided tendency to relapse, so that it may last for years, although each attack runs its course in about fourteen days. It is not contagious, for admitting that inoculation of the secretion in a healthy eye produces inflammation, this is not an eczema unless the healthy eye happens to belong to an eczematous person. The facts just mentioned support the assumption that the disposition to conjunctival eczema lies in an unhealthy nature of the whole body (scrofulosis), on account of which only a comparatively slight irritation is necessary to excite this conjunctivitis. That external irritation plays its part is proved by the fact that the area of the fissure is preferably the portion attacked; but whatever may be the nature of this irritation cannot as yet be stated.

Burckhardt has cultivated various kinds of cocci from phlyctenules, staphylococcus pyogenes aureus, albus, and flavus.

He considers these cocci to be the cause of the conjunctival (and corneal) eczema, because he has succeeded in producing a typical corneal eczema by inoculating rabbits with them. Bach has confirmed these statements as far as the staphylococcus pyogenes aureus is concerned, and has produced phlyctenules by inoculation in human beings as well.

Since staphylococci are found with extraordinary frequency on the healthy conjunctiva and lids, there would be no lack of opportunity for infection. It is still necessary to explain how the infection, or the loss of epithelium necessary for it, can take place. This explanation is difficult to give, particularly for a case of corneal phlyctenule (*p. 231*) or groups of them, the cornea being protected from minute injury not only by its many layers of epithelium, but also by a rich nerve supply and the accompanying sensitiveness. Again, we often see severe injury to the corneal epithelium without the least sign of a phlyctenule. In short, even if the staphylococcus be guilty of arousing a conjunctival or corneal eczema, there will still be one missing link in the chain of a complete demonstrable explanation.

The prognosis is favorable so long as the eruption is confined to the conjunctiva. This is by no means always the case. On the contrary, the disease has a decided tendency to break out on the cornea, or to pass to the cornea from the conjunctiva (*p. 231*).

In both cases a corneal scar may remain, this being obviously worse for vision in proportion to its size and its closeness to the center of the cornea. In making a prognosis, the great tendency to relapse must be considered, but the prognosis may still be favorable, because treatment shows good results, as a rule.

Treatment must be general and local. Unfortunately, general treatment is hard to carry out, owing to the poverty, ignorance, or prejudice of the parents. Baths, that is, general cleanliness of the

Digitized by the Internet Archive of Ophthalmology

child, should be ordered, and life in the open air (not in a dark room!), or at least in well-ventilated rooms, with open windows at night, and, finally, good food—like meat, eggs, milk, butter, or cod-liver oil. All this will not cure a case, but it will encourage healing and help to prevent relapses.

Local treatment should be stimulating. Its effects are noticed quite rapidly. The most-used remedies are calomel and yellow mercurial ointment. The calomel must be absolutely dry and powdery, and should be dusted with a camel's-hair brush onto the conjunctiva once a day, while the under-lid is drawn down. The lids form little strings of this dust which lie for hours in the upper fornix. When the calomel (Hg_2Cl_2) is brought into contact with the sodium chlorid of the tears, it is changed into the bichlorid ($HgCl_2$), to whose disinfectant power the favorable effect is ascribed. *Calomel must never be used when the patient is taking iodid of potassium*, for if it is so used there will be a formation of iodid of mercury, which is irritating to the mucous membrane. Indeed, even if no iodid of potassium has been given at all, calomel may occasionally slightly irritate the mucous membrane. The second stimulating application, oxid of mercury, is called Pagenstecher's salve, and should be used once a day in connection with massage. I prefer this method to the calomel treatment, because children very soon learn to get rid of calomel by rubbing the eyes with their hands and by the accompanying flood of tears.

These remedies should be used every second day for weeks after the eczema has disappeared, to prevent relapses. As a rule, however, the parents do not bring the children after the eye appears cured or looks white; only when a relapse occurs do they come back, and then it must be all gone over again. If the eye is irritated, as may often happen in the miliary form, atropin should be used, and daily massage with iodoform salve (*1 : 10*), Pagenstecher's salve being applied when the inflammation is past. If the adjacent mucous membrane is swollen, and if a secretion is present, a zinc wash (*2 : 300*) may be applied. Here and there cases occur where the conjunctival congestion is so great and the discharge so profuse that applications of nitrate of silver (*2 : 100*) are unavoidable. I then massage one day with "yellow ointment," and on the next—always in the forenoon—use the nitrate of silver, while in the afternoon of each day I apply the zinc.

Stimulants are inadmissible if corneal ulcers are present (*see p. 233*).

Digitized by the Boerhaave Museum of the History of Medicine

(*c*) **Pinguecula.**—On those triangular areas of the bulb that are seen adjacent to the cornea beneath the fissure, there are often found in old persons small, yellow, irregular elevations. Such a growth is called pinguecula because the yellow color deludes one into supposing it to be a fat tumor. Histological examination has shown that it is only thickened epithelium and thickened connective tissue, poorly supplied with blood-vessels. This lack of vessels is particularly noticeable when the eye is hyperemic, because the colorless spot is then sharply defined from its reddened surroundings. Pinguecula is oftener to the inner than to the outer side of the cornea. Its origin is obscure. We can suppose that some part is played by mistreatment, to which this portion of the conjunctiva is quite exposed. Mechanical action of the lids may also be mentioned, by which the redundant conjunctiva in the palpebral fissure is made to bunch up into little folds. There is seldom any pain from pinguecula, and the discomfort is hardly enough to necessitate the physician's interference. Pinguecula has a certain significance as being an indirect course of pterygium.

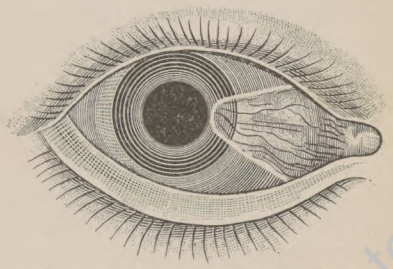

FIG. 77.—PTERYGIUM. (*After Sichel.*)
The "Head" reaches nearly to the pupillary area.

(*d*) **Pterygium.**—This name is used to denote a triangular-shaped conjunctival fold, lying with its apex on the cornea and its base toward the equator of the eyeball (*Fig. 77*). The name arises from the fact that the blood-vessels of a pterygium bear a certain resemblance to the delicate vessels in an insect's wing. Three parts are distinguished—head, neck, and body. The head is the point of the pterygium turned toward the cornea; the neck is the part which lies at the border between cornea and sclera, while the remainder is termed the body. Although pterygium is adherent by its under surface to what lies beneath, it is possible to push a sound below the edges of the neck, since they overhang somewhat. Pterygium always grows beneath the palpebral fissure and to the inner side of the cornea. At times pterygia grow on both sides of the same eye, one from the inner and one from the outer side. It is said that pterygium never grows on the outside of the cornea

Digitized by the College of Optometry

alone.[1] The appearance is different according to its age. A new pterygium is thin and pale, only the head being thick and somewhat raised above the surface of the cornea. As it continues to grow the pterygium becomes thick and red, so that it looks like a mass of flesh (pterygium carnosum). In the course of years the tissue atrophies, and the pterygium looks pale, thin, and tendinous.

Histological examination teaches that pterygium consists of nearly unchanged conjunctiva supplied with numerous thin-walled blood-vessels. On the cornea it takes the place of epithelium and of Bowman's membrane.

Pterygium gives trouble only in case its development is excessive, since in growing it drags toward the cornea not only the conjunctiva of the eyeball, but also the plica semilunaris and even the caruncle, and consequently irritates the conjunctiva mechanically. If this dragging is very great it may even act as an obstacle to certain movements of the eye, and therefore cause squint and diplopia in certain directions of vision. (See *paralytic squint.*)

The origin of pterygium has been until now explained as follows: Some ulcer has developed at the edge of the cornea, and if the conjunctiva was relaxed and yielding, as is often the case in elderly persons, the healing of the ulcer produces a fold of the mucous membrane where it was dragged on. In other cases a pinguecula may have been the exciting cause, by growing over onto the cornea and forming a crevice, in which small foreign bodies, dust, mucus, or bacteria might lodge without being washed away by the movements of the lids. All conditions would then be favorable to the development of a corneal ulcer, the healing of which would lead to adhesions between both suppurating edges, that of the cornea and that of the conjunctiva. As long as this crevice remains there is always danger of a new ulcer, and consequently the head of the pterygium grows toward the center of the cornea, and drags the neck and body after it like the tail of a comet. Stationary pterygia therefore follow an injury or an ulcer, while creeping pterygia follow a pinguecula.

The explanation of pterygium just given has been tested by E. Fuchs in an exhaustive manner, and found to be untenable. According to him, pterygia resulting from corneal ulcers are false pterygia, and should be sharply distinguished from the true ones. The ulcer at the head of a real pterygium is purely imaginary, he declares. The true pterygium always results from a pinguecula, for the latter has an unfavorable influence on the nourishment of the adjacent cornea, a localized corneal inflammation is the result, and the pinguecula is thereby encouraged to grow over onto the cornea.

The prognosis depends altogether upon whether or not an advance of the pterygium toward the corneal center is to be expected. This cannot be determined by inspection alone. It may

[1] I cannot confirm this statement. I have just treated a patient who had a distinct pterygium on the outer side of the cornea and nothing on the inner side.

Digitized by Harvard College Library

be assumed, however, that a bulbous head protruding above the corneal surface, or an ulcer at the edge of this head, or small corneal opacities just in front of the head, all indicate a progressing pterygium, while a flat, stringy head indicates a cessation of the growth. If there is any doubt, it is best to use the strabometer (*Fig. 31, p. 90*) from time to time to measure the distance of the head from the edge of the cornea.

Treatment is not necessary for a stationary pterygium. Any hyperemia can be treated with zinc solution, or, as Zehender advises, with calomel powder. The progressive pterygium should be removed by incision and subsequent approximation of the conjunctival edges. The neck of the pterygium is seized with fixation forceps (*Fig. 78*), held perpendicular to the eyeball; this makes it possible to loosen the head from the cornea with a lance-shaped knife (*Fig. 79*) introduced on the flat. When this is accomplished, two converging incisions into the body are made with scissors, and the part thus prepared is dissected away from the tissue beneath it by short cuts with the scissors. The lozenge-shaped wound is now partly closed by a conjunctival suture, which must be *3* to *5 mm.* distant from the sclero-corneal margin, so as to prevent the epithelial covering of the corneal wound from being part of the process of repair in the conjunctiva.

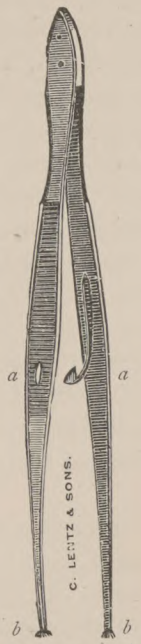

FIG. 78.—FIXATION FORCEPS WITH CATCH AT *a* AND TEETH AT *b*.

FIG. 79.—LANCE-SHAPED KNIFE.

(*e*) **Xerosis epithelialis.**—The conjunctiva lying exposed beneath the palpebral fissure appears dry, lusterless, spotted, and uneven, as if a white foam had dried upon it. It has a fatty structure, as is shown by the fact that fluids, the tears, for example, flow over it without wetting it. If this diseased conjunctiva is scraped and the crumby substance thus obtained examined microscopically, it is found to consist of fatty degenerated epithelial scales, covered with numberless bacilli, "xerosis bacilli." This change in the conjunctival epithelium may involve the cornea as well and produce similar deposits on

it, which may lead to the development of a corneal scar. The patient visits the physician for other complaints that have only an indirect connection with xerosis. Night blindness (hemeralopia) is the first of these. The common ground for the development of hemeralopia and xerosis is a state of impoverished nutrition.

Treatment must be directed to such improvement of nutrition as each case may demand. Locally, warm compresses and a bandage have been recommended, but the usual involvement of both eyes makes this latter inapplicable. Besides this, considering the bacilli present, even though they are only harmless parasites, some disinfectant like sublimate vaselin (*0.003 : 10.0*) or iodoform vaselin (*1 : 10*) is made appropriate.

4. INJURIES AND THEIR CONSEQUENCES.

(*a*) **Foreign bodies** in the conjunctival sac are of very frequent occurrence. Lashes, gnats, seeds, grains of sand, bits of coal, splinters of wood or straw or iron, wings of insects, fragments of glass, and other debris may find their way into the eye. Whether or not the foreign body works itself out, depends upon its size and shape, whether round, sharp, uneven, or pointed. There is always a sensation of a foreign body, with pain and lacrimation due to reflex irritation of the lacrimal gland. In many cases the tears wash the particle into the tear sac, whence it is easily disposed of. In other cases the eye itself is not capable of getting rid of the little stranger. It is driven hither and thither by the movements of the eye and lids till it finally finds secure lodgment somewhere. The favorite locations for foreign bodies are :—

(1) The inner surface of the upper lid, *2* to *3 mm.* from the posterior margins.

(2) The shallow border between cornea and sclera.

(3) The upper fornix.

Anything remaining in the first location must scratch the cornea at every movement of the eye and therefore cause great distress. To remove it the lid should be everted and the foreign body dislodged by the finger, or if it is too firmly embedded, by a needle or a chisel spud (*Fig. 90, p. 250*).

Foreign bodies are often removed by the laity. Locomotive engineers are said to have a trick of shoving the lower lid beneath the upper, thus wiping away any foreign body. Another practice of the laity is the use of a so-called "crab's eye," which is a small lens-shaped limestone, convex on one side and flat on the other, with a dimple on the flat side. These stones are found in the crab's stomach. They are placed in the conjunctival sac so that minute foreign bodies, like coal-dust or grains of sand, are caught in the dimple. It sometimes happens that neither the foreign body nor the messenger sent after it comes out again.

Foreign bodies lodging in the second location may remain with no special symptoms. An inflammatory focus is produced around

Digitized by Illinois College of Optometry

them so that they may at times be mistaken for phlyctenules. The third location is chosen by larger guests, like wisps of straw or crab's eyes. They may remain there for months without causing noticeable trouble, or without the patient's being aware of their presence. The conjunctiva itself, however, does not act so indifferently; it hypertrophies and forms a wall of bleeding granulations about the foreign body. In that case the foreign body is not easily removed by curette or sound but must be seized with forceps and dragged out. The granulations do not, by any means, disappear spontaneously, but should be cut off as soon as the foreign body is removed.

(*b*) **Wounds.**—Wounds of the conjunctiva take place often without injury to the sclera, as when boys playing "Indian" shoot themselves. External hemorrhage is slight, but if it is beneath the mucous membrane it seems to the relatives very dangerous. Small wounds need only an antiseptic wash (sublimate solution *1 : 5000*) and closure bandage. A larger wound may require a conjunctival suture. Clean wounds are intentionally made by the surgeon in strabismus operations, and from these granulations occasionally grow. As the wound closes, its edges constrict the base of the little tumor, which then assumes a mushroom-like shape. If left to itself, this is gradually killed by the contraction of the scar. The surgeon need not wait for this: he can cut off the base with scissors.

(*c*) **Hemorrhage** beneath the conjunctiva is often the result of injuries from blows; it has, of itself, no significance, and disappears spontaneously in the course of two weeks or so. The question must always be asked, however, whether the eye has been otherwise injured by the blow, and can be answered by testing the visual acuity and examining the eye with ophthalmoscope and focal illumination. A small conjunctival vessel may rupture without external evidence, *apoplexia subconjunctivalis*, or in severe fits of coughing, or in whooping cough, or after great mental excitement. That one can get "bloody eyes" from anger is a correct observation on the part of the laity.

In old people these spontaneous hemorrhages have a graver significance, since they indicate a disease of the vessels (atheroma) which may cause a cerebral hemorrhage at any time. One should not forget to look for sugar in the urine when any such hemorrhage occurs.

Digitized by Illinois College of Optometry

(*d*) **Burns** are apt to attack the cornea and even the sclera, but to a certain extent the cornea is protected by its strong epithelium and the sclera by the conjunctiva above it. For this reason burns not unusually attack only the ocular conjunctiva. They may result from explosions of powder and dynamite, from the spattering of molten lead, iron, tar, sealing wax, from boiling water, from a gas flame or a burning cigar or matches. Effects quite similar to these genuine cauteries are produced by contact with concentrated acids,[1] or by potash or lime in either the unslaked or slaked form. This most commonly gets into the eye as mortar, and then has a bad effect, not only chemically, but also mechanically on account of the sand it contains. In all accidents of this kind there is very decided pain, and where the conjunctiva is touched a scab is formed. The conjunctiva looks yellowish or grayish-white, and its sensitiveness is reduced, the degree of this anesthesia being an indication of the depth of the burn. The unaffected tissue is quite red and swollen. Healing results by throwing off the scab. If the burn was so superficial as to destroy only the epithelium, the normal condition is quickly restored; but if the scar penetrated into or through the tunica propria, the result is a cicatrix that may lead to adhesion between lid and eye (symblepharon) in case the loss of tissue extends to the fornix or involves conjunctival surfaces opposed to each other.

Very slight and superficial burns are not easy to recognize. As a rule, only a reddened spot on the conjunctiva is seen, although this is not diagnostic; but if a drop of fluorescin solution (*p. 222*) is placed on the conjunctival surface, an area denuded of epithelium will be colored yellowish-green.

Treatment begins by a thorough cleansing of the eye, since the patient is usually seen too late for the effective use of neutralizing acids or alkalies. Water should not be used if bits of lime are in the eye, for water dissolves the lime and spreads it over the conjunctiva, producing a new source of irritation. Forceps and a piece of cotton soaked in oil is the best method to use in these cases. The eye's surroundings should then be carefully washed with sublimate solution *1 : 1000*, the conjunctiva with *1 : 5000*, and a bandage applied. To diminish the severe pain a few drops of a *5* per cent. cocain solution may be dropped into the eye and an atropin-cocain salve (*Atrop. sulf. 0.1; Cocain muriat. 0.2; Vaselin 10.0*)

[1] Burns from acids are caused sometimes with criminal intent.

Digitized by Illinois College of Optometry

rubbed into it before the bandage is applied. The scab may be encouraged to come off by warm compresses.

(*e*) **Symblepharon.**—We distinguish an anterior and a posterior symblepharon. The former indicates an adhesion of the lid to the eyeball, forming a bridge between the two, but not extending to the fornix. The latter refers to an adhesion reaching to the fornix or beginning at it. These adhesions more or less restrict the eye's movements, or they may so anchor the lid to the eye in front of the pupil as to render vision impossible. Every means must be tried, therefore, to prevent such an adhesion. This can generally be done if the two opposed burned areas do not extend to the fornix; it is only necessary during healing to separate the wound surfaces daily by some mechanical means and to prevent their subsequent sticking together by applications of borated or iodoformed vaselin (*1 : 10*). If the burn extends to the fornix nothing can be expected from such means.

If an anterior symblepharon already established is to be treated, it is best to cut the adhesions and try to change the conditions so that wound surface does not come into contact with wound surface but with mucous membrane. In many cases this can be done by carrying an incision through the conjunctiva to the right and left of the wound, and by transferring the loosened mucous membrane by a few sutures so as to bring it over one wound surface. The eye has now two wound surfaces, but the lid only one, and this not in apposition to the others; adhesion is therefore impossible. In a small anterior symblepharon a simple incision through the adhesion with subsequent prevention of further union is sufficient. If the symblepharon is posterior, the conjunctival sac can be repaired and a freedom of movement secured, after breaking up adhesions, only by transplantation of new skin or mucous membrane. The healing of this new tissue taken from the patient or some other person, thanks to antisepsis, will usually give no trouble; but the success of transplantation may be nullified by subsequent contraction. It will be a matter of further experience before it is decided which tissue is best suited for transplantation, whether cutis (which becomes changed to mucous membrane), or mucous membrane taken from the mouth or the vagina, or the digestive tract of the rabbit, or the skin of the frog.

Digitized by the Internet Archive in 2010

5. TUMORS.

Lipoma (*Fatty Tumor*) is congenital. It remains quiescent for some time, but may later on begin to grow. It is soft, has a rough, lumpy surface and a yellow color. Strictly speaking it is not a tumor of the conjunctiva but of the underlying connective tissue, over which the conjunctiva passes unchanged. A lipoma is usually found on the upper and outer quadrant.

Polypi are pale-red, pedunculated little tumors of *0.5* to *1 cm.* diameter, usually on the plica semilunaris or the lacrimal caruncle. They bleed easily.

Cysts are thin-walled sacs, somewhat transparent, filled with a watery fluid, and having the form and size of half a pea or bean. They are usually near the corneal margin, generally congenital, but may develop as the result of an injury. A cyst springs from a dilated lymph vessel. In rare cases conjunctival cysts spring from the bladder of the cysticercus cellulosæ (*q. v.*). Since they are not in, but rather below the conjunctiva, this form of cyst appears less thin-walled and transparent than others, especially as the conjunctiva may become inflamed by irritation from the parasite. In spite of this the neck and head of the worm may glisten as a whitish spot within the cyst.

Dermoid tumor is yellowish, and has the size and shape of a split pea, lying at the corneal margin in the lower and outer quadrant. It can with equal right be called a tumor of the cornea. Dermoid tumor is congenital, and may remain indefinitely without increase in size. If it begins to grow it is not a pure dermoid, but a mixed form of dermoid and lipoma. Histologically it is found that a dermoid consists of a thick layer of stratified epidermis cells beneath which are connective tissue, fat cells, smooth muscular fibers, glands, and hairs, all being tissues of the external skin. Its origin is explained by supposing a piece of lid to have become at one time adherent to the eyeball, but later to have been constricted at its lid attachment with subsequent growth upon the eye; hairs found in a dermoid would therefore be dislodged lashes. It may be said that these hairs are the surest signs of dermoid.

Sarcoma is usually found at the limbus of the conjunctiva, and seldom any other place, although Horner mentions a case discovered on the inner surface of the upper lid. The tumor is pedunculated, vascular, and inclined to bleed; it is of a warty surface and grayish brown to black in color (Melanosarcoma). This latter is

Digitized by the Internet Archive in 2010 with funding from Illinois College of Optometry

one of the most malignant of all tumors, but the sarcomata lying superficially are, according to Schweigger's experience, relatively benignant—a fact to be considered when the question arises whether or not the globe must be sacrificed.

The conjunctiva bulbi may have congenital pigment spots which do not noticeably alter in years, and must, therefore, be considered as nevus pigmentosus. Nevertheless, one must always consider the possibility that such a nevus may begin to grow, and in the end to become a melanosarcoma.

Carcinoma is usually found at the sclero-corneal margin. Its growth is so slow and painless that it may be overlooked in diagnosis. In time an excrescence develops, whose pedicle passes gradually into the conjunctiva—a condition not found in a phlyctenule or an inflammatory focus. With a lens this warty character of the surface may be recognized.

Treatment.—Lipoma is to be shelled out; polypus to be removed by excising the pedicle down to healthy tissue, for if the pedicle remains it will grow again. A cyst is to be opened and the walls touched with nitrate of silver.

Sarcomata and carcinomata, being malignant tumors, are to be radically excised down to what appears to be healthy tissue, and the wound must be cauterized with the hot iron. If the disease has involved the sclera, enucleation is unavoidable.

6. EXTREMELY RARE DISEASES.

(*a*) **Pemphigus** (*Formation of Vesicles*).—It has been occasionally observed that a vesicular eruption at the mouth, on the face, or on the extremities has been accompanied by a similar eruption of vesicles (bullæ) on the conjunctiva. These vesicles are about the size of a pea and filled with a cloudy fluid. When they open they leave a shallow ulcer, which heals with a cicatricial contraction of the affected conjunctiva. Since the process repeats itself on the mucous membrane the same as on the surface of the body, there may be in the course of years a considerable distortion of the conjunctival sac, or in some cases an adhesion between lids and eyeball (*p. 213*), or a xerosis conjunctivæ (*p. 217*). A similar condition may develop very gradually without pemphigus vesicles. In Graefe's clinic five such cases were observed and reported as "essential contraction of the conjunctiva."

Treatment can accomplish little. The internal use of arsenic seems powerless. Schmidt-Rimpler, in one case reported by him, found local applications of boric acid compresses and the styptic use of tannin and nitrate of silver solution of some service.

Amyloid occurs in young persons who may be quite healthy in other respects. The patient's attention is first called to it by a droop of one or both upper lids. As the disease involves a greater area of the conjunctiva, new symptoms appear, such as lack of strength in the eye, repeated redness, and disturbances produced by subconjunctival hemorrhages and by the protrusion of the diseased conjunctiva into the palpebral fissure. The eye becomes useless at last, because the patient is no longer able to open the swollen and distorted lids.

Digitized by the Illinois College of Optometry

If the physician everts the lids he sees a picture greatly resembling that of the second stage of trachoma (*p. 201*). In both cases the conjunctiva is hypertrophied in depth and on the surface, particularly at the upper fornix; but in amyloid this hypertrophy is greater and extends over the entire conjunctiva, including that of the bulb. Further differences are to be found in the character and color of the surface. In amyloid the surface is smooth, the protruding folds of the fornix being the only irregularities. In trachoma, on the other hand, the surface is roughened, in places at least, by the underlying follicles. Amyloid is pale yellow, waxy, and transparent, trachoma a dirty reddish-yellow. In amyloid, even of ten years' standing, the cornea is unaffected; in trachoma the cornea is almost always attacked. The cause is unknown, and even the sages have not decided what the histological structure of the changed conjunctiva really is. So much is certain, however, that a piece of tissue cut from a conjunctiva with amyloid degeneration yields on pressure a jelly-like substance which stains violet with iodin and sulfurous acid, thus giving the distinct color reaction for amylum or amyloid. The detection of this color reaction on an excised bit of tissue should never be neglected in the differential diagnosis between amyloid and trachoma. *Treatment* consists in excision of the most prominent folds with expression and curetting of the amyloid substance. If healing does not result, a decided improvement is at least obtained. Cures have, however, been reported.

Hyaline degeneration is a condition scarcely to be distinguished clinically from the above. The difference consists chiefly in absence of the amyloid reaction. Many authors consider hyaline degeneration a distinct disease; others, as Raehlmann, merely a forerunner of amyloid.

DISEASES OF THE CORNEA.

Preliminary Remarks.—The contents of the eyeball is enclosed in a threefold envelope. The tunica externa is the outer coat: its smaller anterior segment, *the cornea*, is as transparent as glass, its larger and posterior segment, *the sclera*, is like porcelain and untransparent. Both segments have a thickness of *1 mm.* or more, and are of decided density, so that they are a protective mantle for the delicate inner membranes. The cornea is the segment of a sphere of *7.5* to *8 mm.* radius, the sclera is the segment of a sphere of *12 mm.* radius. The cornea is fitted into the sclera like a watch crystal into its case. It consists of five layers (*Fig. 4, p. 27*). The middle layer is by far the thickest, being about 95 per cent. of the whole; it is called the *substantia propria corneæ* and cornea scleræ. It consists of extraordinarily fine connective-tissue fibrils. These fibers are matted together into bundles, which are placed in layers over each other; between these lamellæ are a series of inter-communicating spaces called lacunæ; these lacunæ with their canals form the lymph system of the cornea. Since the cornea must be transparent, it is obvious that blood cannot circulate in these lymph spaces, because the nutrient fluid formed there must also be quite transparent. This fluid consists of a clear lymph with a moderate number of ameboid cells, white blood corpuscles. Besides movable contents there are found in the corneal lacunæ immovable cells called the fixed corneal corpuscles. The anterior structureless membrane is called the lamina elastica anterior or Reichert's or *Bowman's membrane* (*Fig. 82, p. 224*). Morphologically this belongs to the substantia propria. Above Bowman's membrane lies the corneal epithelium disposed in eight or nine layers of cells (*Fig. 86, p. 241*). The innermost layers consist of cylindrical cells arranged with the long axis perpendicular to the cornea;

Digitized by Illinois College of Optometry

the three or four superficial layers are pavement cells with their long axes parallel to the surface of the cornea; the middle layers are cuboidal. The corneal epithelium forms the *conjunctiva corneæ*. The posterior surface of the substantia propria is covered by the glass-like and structureless lamina elastica posterior or *Descemet's membrane* (*Fig. 82*). In spite of its thickness of only *0.006 mm.*, this membrane is very strong. Its posterior surface is covered with a single deposit of flat endothelial cells, the fifth and last layer of the cornea. The fourth and fifth layers together are called *choroidea corneæ* because they belong morphologically to the middle tunic of the eye.

Although the cornea has not and cannot have blood-vessels of its own, it is by no means cut off from the nutrition supplied by the blood current. At the corneal margin superficially there lies a network of blood-vessels (*Fig. 80*), ready at any moment to push on into the cornea new-formed vessels. There are also vessels at the scleral margin deeper down, from which this vascularization may proceed.

Since the cornea is in immediate contact with the outer world and thereby exposed to all manner of injury, it possesses a special protective mechanism. This consists of an extraordinarily rich supply of nerves, and obviously if the transparency of the eye is to be maintained these nerves must be of the non-medullated variety. The branches of the nerves extend to the uppermost layer of the corneal epithelium. If the cornea is irritated by dust or wind, if it is too dry, or if in any way it resents interference, then

FIG. 80.—VASCULAR NETWORK AT THE CORNEAL MARGIN. (*After Waldeyer.*)
Red, arteries. Blue, veins.

through these nervous fibrils an impulse is sent for the lids to close and protect it and for the tears to wash it clean.

The *sclera* is similar but less regular in structure; a lamina elastica anterior with its epithelium is unnecessary, since the surface of the sclera is not exposed, but is protected partly by the conjunctiva, partly by Tenon's capsule. Decemet's membrane with epithelium is unnecessary because the inner surface of the sclera does not line the space filled with fluid; both inner and outer surfaces, therefore, are covered only with a large-celled endothelium, in order to facilitate the movement against Tenon's capsule on the one side and the middle tunic on the other.

I. INFLAMMATIONS OF THE CORNEA.

1. *General Considerations.*—Inflammations of the cornea form not only the majority of corneal diseases, but a goodly proportion of all eye diseases as well. They demand particular attention, because they very often leave behind opacities of the cornea and the incurable disturbances of vision connected with them. What determines

Digitized by Illinois College of Optometry

a corneal inflammation? The four usual signs of inflammation—heat, swelling, redness, and pain—are not here at all! Since the cornea is non-vascular, in a recent inflammation there can be no redness. Since it is unelastic, there can be no swelling. Pain, to be sure, is present, but it is by no means exceptional to see an inflammation in the deeper layers of the cornea run its course with no pain whatever. Heat depends upon blood congestion, and can, therefore, play no part in a non-vascular tissue. Hence it is plain that we must search for another sign which will be present in all corneal inflammations: this sign is cloudiness.[1] The cause of this cloudiness or opacity is to be found in a collection of leukocytes that have passed into the cornea from the adjacent blood-vessels, or have sprung upon the fixed corneal cells by karyokinesis.

Opacity causes an impairment of vision, often the only complaint of the patient, although in most cases he complains of pain, photophobia, and lacrimation. The pain is easily distinguished from that of conjunctivitis by the fact that it is not limited to the diseased area, but radiates to the forehead and upper jaw, the so-called ciliary pain, because the nerves of the cornea arise from the nervi ciliares. Objective examination shows swelling and redness of the lids and congestion of the conjunctival vessels; a quite important sign is the injection of the deep sub-conjunctival vessels that arise from the ciliary arteries (*see p. 182*), "pericorneal injection" or "ciliary injection;" in the cornea itself there may be any kind of opacity, and the iris may be congested or inflamed.

2. INFLAMMATIONS WITH THE FORMATION OF ULCER.

(*a*) **Ulcus Corneæ** (*Corneal Ulcer*).—If there are signs of corneal inflammation and if a loss of substance can be found, we can speak of an ulcer. Demonstration of this loss of substance can, in doubtful cases, be simplified by the use of fluorescin, introduced by Straub. A drop of a solution (*Fluorescin 0.1; Natr. carb. 0.2; aq. dest. sterilis. 5.0*) is placed in the conjunctival sac and at once washed off with warm sterilized water or sublimate solution *1 : 5000*. Any spot on the cornea which has lost its epithelium will be colored a vivid green.[2] In a crying and struggling child the glance of a

[1] There are corneal opacities of a non-inflammatory nature; these will be discussed later.

[2] Diseased epithelium will also be colored green, as, for example, the epithelium covering an eczematous pustule; but such a spot is only dull green, while a spot actually denuded of its epithelium appears to be saturated with a vivid green.

Digitized by Illinois College of Optometry

moment will show what the condition is better than the most careful examination without fluorescin. If an ulcer is proved to be present, this is by no means all that must be done; we must determine whether the ulcer is beginning, or spreading, or healing; we must further find out whether the ulcer arose (*1*) from external infection, (*2*) from extension of some conjunctival disease to the cornea, (*3*) from some nervous disease, or (*4*) from some systemic disturbance. It will then be possible to give to the ulcer its own personality, which completes the description of the disease. Although it is often easy to recognize what stage the ulcer has reached, it is quite as often difficult or even impossible to decide what was its origin. We must, therefore, be content with the name corneal ulcer, and reserve the right to complete the designation at any succeeding examination.

Ulcers originate in two ways. Either a wound causes a loss of

FIG. 81.—BEGINNING CORNEAL ULCER. (*After Sæmisch.*)
The upper layers of epithelium are partly lacking. At Bowman's membrane a layer of pus-cells is seen. In the substantia propria are numerous small groups of pus-cells.

epithelium, so that the door is opened for the entrance of bacteria, which effect a suppurative infiltration of the neighboring tissue; or this infiltration is the earlier process which leads to a later destruction of the superficial corneal layer with its epithelium and the subsequent ulcer (*Fig. 81*). In the first stage the ulcer has the following appearance: the base, where tissue has been lost, looks grayish or yellowish, uneven and rough; the edge is irregular, jagged, and torn (*Fig. 82*); the neighborhood of the ulcer is usually clouded, but in a few cases it may be clear and unaffected. As long as the ulcer progresses, new areas of the cornea melt into it; the loss of tissue becomes greater; pain, lacrimation, photophobia, and dimness of vision become more pronounced, or are at least unimproved. At last the turning-point comes and healing begins. The base of the ulcer is a little less clouded, for the detritus covering it is disappearing; the ulcer looks clear and smooth, for epithelial cells are spreading across it from edge to edge (*Fig. 83*).

Digitized by the Illinois College of Optometry

For the same reason the edge of the ulcer is rounded off, and is less sharp than before the adjacent cloudiness clears up, or is at least restricted to the immediate neighborhood of the ulcer. Finally, new-formed blood-vessels are seen (*Fig. 83*) either because they have developed up to the ulcer, or because the marginal vas-

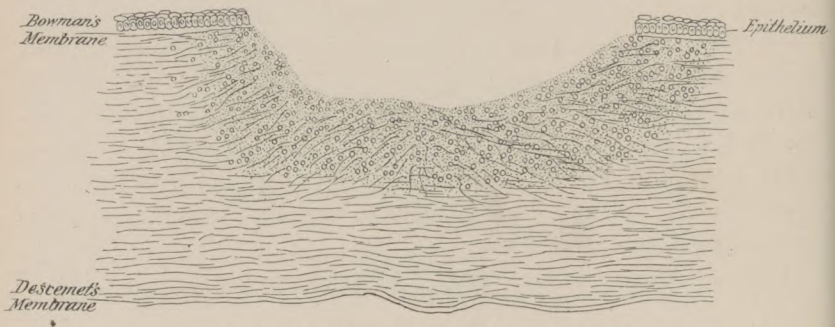

FIG. 82.—PROGRESSING ULCER. (*After Sæmisch.*)
The neighborhood of the ulcer is infiltrated with pus-cells.

cular network was so close to the ulcer that new vessels could easily branch out from it. At the same time a decided improvement in the patient's symptoms sets in. As soon as the base of the ulcer is again able to reflect light, we may assume that it is covered with epithelium and that the essential requirement of healing has been complied with. To be sure, the lost tissue is not yet

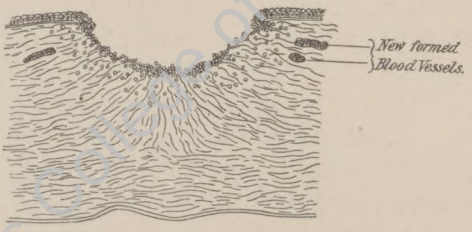

FIG. 83.—HEALING ULCER. (*After Sæmisch.*)
The infiltration has disappeared. The base of the ulcer is covered with young epithelial cells.

completely replaced; this occurs gradually by the formation of new connective tissue below the epithelial covering, and sometimes in elderly persons is never completed. Until the tissue is fully restored there remains a corneal "facet." The new-formed connective tissue resembles corneal tissue, but is not so completely transparent.

Digitized by Illinois College of Optometry

As the facet grows shallower the cloudiness becomes more opaque. The younger the patient the sooner can one expect a gradual clearing up of this scar.

The favorable course here described is the usual one in cases properly treated; but we must learn to recognize the exceptions that turn out very unfavorably. If the ulcer has eaten through the entire thickness of the substantia propria the internal pressure of the eye rests alone on Descemet's membrane. This becomes so stretched that it bulges into the ulcer, filling it completely. Since the base of the ulcer now lies on this surface, is transparent, and reflects light, the inexperienced observer may be misled into believing that such a corneal hernia, *keratocele*, is an unexpectedly rapid healing. The experienced observer, however, will be attracted by the undiminished irritation in the eye to its actual condition, which he can then corroborate by means of lens and focal illumination. If the ulcer advances further the result is a *perforation;* the aqueous flows away between the lids, the iris is either stretched across the aperture or is dragged completely through it—*prolapsus iridis.* The effect of the perforation is favorable to the ulcer; the reduction of the eye's tension encourages the circulation in the cornea, and the round cells attracted hither can now succeed in effecting the demarcation and destruction of all unhealthy tissue, and a cleansing of the ulcer. Healing results by the prolapsed iris' changing into granulation tissue and uniting to the adjacent corneal scar. The iris remains permanently adherent to the white corneal scar, a condition called *leucoma adherens.* If the perforation is very small the iris may again retract, leaving the patient with only a simple corneal scar. If the ulcer was exactly at the center of the cornea, the anterior lens surface, instead of the iris, falls into the opening when perforation occurs. The result is an opacity of the lens capsule at the anterior pole—anterior central capsular cataract. A perforation at the center of the cornea may result in another evil, for if the iris does not reach to the point of perforation, but is yet near enough to act as a wedge and thereby to prevent the lens from closing the aperture, the perforation remains open, and the result is a corneal fistula through which the aqueous continuously trickles. The eyeball is thus softened and ill nourished, and finally atrophies, unless nature or art effects a speedy closure of the fistula.

Digitized by Illinois College of Optometry

There must be mentioned, finally, the worst cases of corneal ulcer, in which a large part of the cornea, or all of it, within a remarkably short time is eaten away by the pus, and where the iris prolapses to a great extent or totally, and even the lens or part of the vitreous may be let out. Such a case may lead to an atrophy of the eyeball—*phthisis bulbi.* In other cases a cure may be effected if the prolapsed iris becomes covered with cicatricial tissue. A cicatrix with adherent iris will often bulge forward on account of the internal pressure of the eye, forming a berry-like tumor, which will be discussed under *staphyloma corneæ* (*p. 257*).

The prognosis depends upon the location, size, and nature of the ulcer, as well as upon the resistance which the corneal tissue is capable of opposing. In general, only this much can be said: that a yellow color of the base and edge of the ulcer indicates pus infiltration and further destruction of tissue, but that areas of the cornea provided with blood-vessels, "vascularized," are protected from destruction; the mere proximity of vessels assures some protection; therefore the corneal zone bordering on the marginal network of blood-vessels remains undestroyed, even if the entire cornea suppurates. It may be given as a good rule that advanced age and a poorly nourished condition of the patient tend to make the prognosis bad, because both circumstances reduce the cornea's power of resistance and reaction. The prognosis is also essentially modified by treatment.

Treatment attempts to accomplish three objects:—

(1) The eye, like any other diseased organ, is to be made to rest, and is to be protected from new injury.

(2) The ulcer is to be disinfected.

(3) The nutrition of the corneal tissue and the natural healing dependent upon it is to be as much as possible encouraged.

To accomplish the *first* object, atropin, the pressure bandage, and rest are at our disposal. Atropin subdues the pain and overcomes the inflammation. We can often see how the ciliary injection noticeably subsides within half an hour after atropin has been dropped into the eye. Atropin is also indicated on account of the iris. Every active inflammation affects the adjacent parts in sympathy, and therefore iris hyperemia or even an iris inflammation is a not unusual result in corneal ulcer. Atropin stops the play of the pupil and prevents the formation of posterior synechia.

Digitized by Illinois College of Optometry

Atropin should not be applied if corneal perforation threatens, or if perforation is already present. In such a case one must apply the exactly opposite remedy (*Eserin sulf. 0.025; Aq. salicylat. 5.0;* [1] *one drop twice a day*).

Eserin effects a powerful contraction of the pupil, increasing, of course, the irritation of the iris but reducing the internal tension of the eye, and therefore reducing the pressure against the cornea. Moreover, it must be remembered that in a tense and distended iris the danger of a prolapse is much less, and consequently we are warranted in hoping that in spite of a perforation we may effect a cure without anterior synechia, that is, adhesion between iris and cornea.

The pressure bandage prevents movements of the lid, and protects the eye from light. Rest in bed is indispensable in severer cases, and acts favorably by keeping the whole body quiet, and particularly by lessening the demands upon the healthy eye.

For the *second* object, disinfection, we have a number of remedies at hand. In the mildest cases, it is enough to wash the lids thoroughly with sublimate solution, and to douche the conjunctival sac with sublimate *1 : 5000*. The ulcer may be dusted with finely powdered iodoform.[2] A bandage will prevent secondary inflammation from dirty fingers, dust, etc., and it is best to use for this purpose antiseptic material, such as cotton prepared with sublimate solution (*1 : 1000*); or if eczema results we take iodoform gauze. If the ulcer progresses in spite of this treatment, stronger means of disinfection should be used. The strongest, and at present most popular, is the galvano-cautery, with which every part of the cornea that seems to be in danger is cauterized. Since many ulcers progress only from their edges, in these cases it is not necessary to cauterize the whole ulcer but only the advancing portion. The result of the cautery is a brilliant one in case every infected area is actually destroyed, and, when only this infected portion is destroyed, the scar is no greater than it would have been without such a radical procedure.

I seldom use the cautery, if I find that a milder method does quite as good service. By this, I mean the scraping of the ulcer with a sharp spoon or a chisel. If the ulcer is colored green with fluorescin before the operation, the green color serves as a guide to limit the curetting. After fluorescin, cocain is applied, and after the operation everything is washed away with sublimate solution, and an antiseptic bandage is put on.

---

[1] Eserin sulfate, dissolved in distilled water, soon becomes red. If salicylic acid is added to the water the solution remains colorless.

[2] Stilling proposed to use the diffusible anilin dyes as disinfectants, and he introduced methyl violet into practice under the name of "Pyoktanin," pus destroyer. Pyoktanin has been tried by many surgeons in different eye diseases, particularly in corneal ulcers. It is as yet undecided what effect it has, but it is probably not so favorable as Stilling at first hoped.

Digitized by Illinois College of Optometry

In the *third* group of remedies moist heat plays an important part. It may be assumed that its effect is to arouse a reactive inflammation and to encourage the sloughing of the already necrotic tissue; moreover, it encourages the development of protecting blood-vessels, and at the same time lessens the pain. It is therefore used in all cases where the pain is great, and where the disease pursues the subacute course. It is particularly useful in non-irritating ulcers and infiltrations, where this reactive inflammation is ordinarily lacking. Moist heat can be applied as a warm compress of chamomile tea, or three per cent. boric acid solution, or as an ordinary moist warm compress. If the last is applied it may be prevented from drying by covering the bandage with a layer of oil silk.

Puncture of the base of the ulcer has the same effect as moist heat. When the aqueous escapes, the cornea has less pressure upon it; the circulation of fluids in the lymphatics is encouraged, and the ulcer is better drained. The experience that perforated ulcers heal quickly of themselves first suggested the resort to this measure. In the worst cases it is not sufficient to puncture the base of the ulcer with a needle, it must rather be incised with a Graefe's cataract knife (*Fig. 126*) from healthy tissue to healthy tissue, and the wound must be opened for several days following with an aseptic probe. In short, the ulcer must be treated as an ordinary abscess. This is called *Sœmisch's operation.*

This is an operation I seldom resort to; although I have just had a case in which the ulcer, in spite of radical curetting, made such rapid progress and became so large, that I could not even think of cauterizing every part of the area involved.

If the iris prolapses we may try to drag it out of the wound by eserin. If this is not successful, we must await the healing of the ulcer, and then attempt to abscise the prolapse (*p. 258*) or to burn it off with the cautery.

A corneal fistula is treated in the same way with eserin and pressure bandage. If this method is unavailing we must try to destroy the epithelial covering of the fistula by means of the cautery.

When the base of the ulcer reflects light, and ciliary injection and the other signs of irritation have disappeared, the treatment with stimulants should be begun. Daily massage with yellow mercurial ointment encourages the absorption of the round cells in the neighborhood of the former ulcer and the obliteration of the new-formed blood-vessels. Both results are apparent—to the physician by

Digitized by Internet Archive

clearing up of the opacity, and to the patient by improvement in visual acuity (if the opacity lay near the center of the cornea).

(*a*) Ulcus serpens, Hypopyon Keratitis, usually attacks poor people in advanced age. The disease most commonly results from an injury to the eye,—for example, when a twig has scratched that part of the cornea exposed within the palpebral fissure, etc., or when some splinter of wood or any kernel of grain flies into the eye and makes a small wound. Even the scratch from an eyelash may be enough to cause it. Such little injuries of themselves would, as a rule, have no serious consequences, but if germs have entered the little wound, although it may have closed a short time after it was made, the result is a corneal ulcer having a remarkable inclination to spread superficially and profoundly—*ulcus serpens.* Germs may be introduced by the object causing the injury; this is particularly common in the case of injuries made while working with farming tools. In perhaps one-third of the cases they get into the wound from the pus of a blennorrheic tear-sac (*p. 172*). In still other cases, germs may enter from the discharges of an inflamed conjunctiva, of a lid, or from the nose or mouth. Infection from the nose or mouth may be accomplished by dirty handkerchiefs and fingers, since many people have a habit of using saliva to wash out the eye when it itches. Finally, it must be remembered that any corneal ulcer may be changed to an ulcus serpens by secondary infection.

Undoubtedly there are many kinds of germs able to produce an ulcus serpens. Investigations made up till now have shown the presence of one or more of the following: staphylococcus pyogenes albus and aureus, gonococcus, streptococcus, anthrax, typhoid or diphtheria bacilli, and aspergillus glaucus, leptothrix buccalis.

Symptoms of the patient—lacrimation, photophobia, and ciliary pains—are extraordinarily various and bear no relation to the severity of the disease. The objective phenomena of irritation, "pericorneal injection," are quite as various. The visual disturbance, on the other hand, is always noticeable, since the ulcer lies within the territory of the palpebral fissure, and, indeed, in or close to the center of the cornea.

The edge of the ulcer forms a yellowish-white curved line, or a group of smaller curves clustered together; a radiating bundle of delicate gray spokes passes from them into the still transparent corneal tissue. The ends of the spokes are connected by delicate

Digitized by Illinois College of Optometry

bundles running nearly parallel to the edge of the ulcer. At the posterior wall of the ulcer there is found, in cases where the inflammation is severe, a grayish cloud that extends even into the anterior chamber. The aqueous is therefore rendered opaque by pus cells. If this collection of pus cells reaches a certain degree, the settling of the cells will produce on the floor of the anterior chamber a yellowish-looking mass, which is bordered above by a horizontal line and below by the edge of the cornea, and is therefore in the shape of an arc; this is called *hypopyon*.[1] According to Sæmisch, hypopyon occurs in 70 per cent. of serpiginous ulcers.

The iris also is involved in the inflammation and becomes adherent to the anterior surface of the lens—*synechia posterior*.[2] Even irido-cyclitis and suppuration of the entire eye may be produced, but this danger usually threatens in those cases where the first developments of the disease occurred in the deeper layers of the cornea. A loss of substance then—an ulcer—is not at first present, the disease beginning as a corneal *abscess*, as a round, yellowish disk in the center of the cornea moderately swollen at the edge. The surface of this lesion is flat and somewhat depressed. Until the abscess breaks and forms an ulcer, it, of course, increases in size, both in surface and depth, which gives to this particular form its dangerous character. It may be produced in an intact cornea by germs that have migrated into the cornea from the blood current. This may happen, although not often, after severe infectious diseases, as typhoid fever, scarlet fever, and particularly after smallpox. It is oftener the case that germs are admitted through a minute wound of the epithelium, which has already healed when the abscess begins to show itself.

The prognosis is unfavorable. In the best of circumstances the disease may heal with an opaque corneal scar, often with anterior and posterior synechiæ. The **treatment** of this form of corneal ulcer occasionally necessitates Sæmisch's operation at the base of the ulcer.

(β) Ulcus Rodens.—In spite of the similarity of the names, ulcus rodens has little in common with ulcus serpens. Ulcus serpens is an acute disease leading to suppurative destruction of the cornea, to hypopion, and even to irido-cyclitis; ulcus rodens, on the other hand, is a chronic disease, which in the course of months, with occasional inter-

[1] Since hypopyon is a nearly constant occurrence in ulcus serpens, Roser named the disease hypopyon keratitis.

[2] Adhesion of the iris with the cornea is called *synechia anterior*.

Digitized by Illinois College of Optometry

missions, scales off the most superficial layers of the cornea without perforating the cornea itself, or even without penetrating into its deeper layers. Ulcus rodens begins at the margin of the cornea, and passes step by step, with decided irritation, pain, photophobia, lacrimation, and ciliary injection, across the middle of the cornea and ends at the opposite margin. The base of the ulcer is seldom deeper than the surface of the cornea. It is rather opaque and abundantly supplied with vessels springing from the marginal network. The edge of the ulcer is whitish, abrupt, and somewhat undermined; minute white points in the neighboring but still healthy cornea are outposts and signs of a further advance of the disease. Nothing is yet known of any causative germ. As *treatment*, the obliteration of the advancing edge of the ulcer with the cautery may be advised; the application of nitrate of silver has done good service; atropin and a bandage are always to be used.

(*b*) Ulcerative Corneal Inflammation Arising from the Conjunctiva.

(*a*) KERATITIS ECZEMATOSA (*Lymphatica, Scrofulosa, Phlyctenulosa*) attacks children, chiefly those who suffer from eczema of the skin, of the lids, and particularly of the conjunctiva; to avoid a repetition the student is referred to *p. 207*. Keratitis eczematosa does, however, occur in adults and in healthy children with intact conjunctiva. The disease is extraordinarily various, since in one case there are small eczema vesicles (phlyctenules, *Fig. 84*); in another, large eczema pustules, since ulcers may spring up from this eczema, producing on the same cornea lesions of different size and character next to each other; and since, finally, an eczematous ulcer may lose its own peculiarities by any infection added to it. The study will be essentially simplified if we differentiate with Horner—

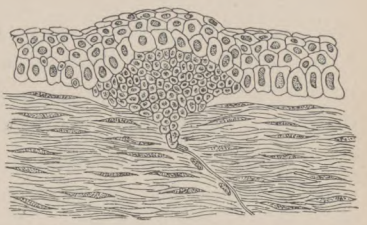

FIG. 84.—PHLYCTENULAR KERATITIS. (*After Iwanoff.*)
This consists of a collection of pus cells between the epithelium and the substantia propria. The band passing obliquely to it is a corneal nerve.

(1) Eczema passing from the conjunctiva.

(2) Eczema originating in the cornea.

(1) A single phlyctenule lies at the limbus of the conjunctiva but extending a bit onto the cornea. At this spot there will be an opacity of the cornea, which disappears if the progress is favorable; if it is unfavorable it changes to a funnel-like ulcer or is inclined to sink, step by step, and to cause a perforation with all its consequences. Or, the marginal phlyctenule may form the first stage of a bundle of vessels of a corneal inflammation—*keratitis fascicularis*.

Digitized by Illinois College of Optometry

While this phlyctenule is healing on the conjunctiva it is advancing on the middle of the cornea and drags the sheaf of new-formed vessels behind it. The appearance of such a vascular condition is unusually characteristic, and is easily distinguished from the ordinary vascular ulcer arising at the edge of the cornea—first, by the parallelism of the vessels; second, by the opacity of the vascular area of the cornea; and third, by the sharp contrast of the opaque cornea with the healthy cornea marked by two parallel lines. The apex of the bundle of vessels is a yellowish crescent with its concavity turned toward the vessels; this is a small ulcer with an infiltrated base and a raised edge. The vessels may disappear, but the opacity never does; it remains during life.

The picture becomes somewhat different if a larger number of conjunctival phlyctenules attack the cornea; the mildest involvement of the cornea is called phlyctenular marginal pannus—*keratitis superficialis vasculosa.* It is characterized by a slight opacity and vascularization of a corneal area bordering directly on a conjunctival limbus having these phlyctenules. It is to a certain extent only an inflammatory product which has involved the cornea. A severer form is the eczematous circular ulcer; this is characterized by small infiltrations, each corresponding to conjunctival phlyctenules springing up along the corneal margin, changed into ulcers and soon after run together. Circular ulcers under some circumstances may threaten even the center of the cornea, since a suppurative infiltration and necrosis may involve a part of the cornea extending to its very center.

(2) Idiopathic eczema of the cornea is somewhat simpler in its manifestations. Horner distinguishes three forms, the differences consisting in a greater or less depth and extent of the commencing infiltrate, from which smaller or larger ulcers develop, which in the worst cases may lead to hypopion and iritis. The infiltrate is seen as a somewhat raised grayish point about the size of a pinhead, sometimes on a clear cornea, at other times on a cornea moderately opaque.

Every infiltrate need not change to an ulcer. Even the large ones, yellow in color and of considerable depth, may be dissolved under proper treatment without producing an ulcer; in spite of which, however, there is left, as a rule, an incurable opacity. This keratitis eczematosa resulting from an infiltrate is really a very serious disease, needing from four to six weeks for its cure; but the final result is better than might be expected from the threatening appearance it has in its full development.

Digitized by University College of Optometry

Treatment consists of atropin, douches of sublimate solution *1 : 5000*, bandage, and warm compresses when proper. Good nutrition is particularly important in this form.

All forms of eczema of the cornea produce in the majority of cases, besides the ordinary symptoms of irritation, an extraordinary degree of photophobia, which may increase to an actual spasm of the lid (*p. 157*). The epithelium of the cornea is remarkably rich in nerves, and for that reason superficial corneal inflammations occasion severe reflex symptoms. The use of the eyes demands movements of the lids, and movements of the lids irritate the surface of the cornea already diseased; it is no wonder, then, that children instinctively creep into the darkest corner of the room, burying their faces in cushions, or by squeezing their fists into their eyes seek to prevent the physician from getting a look at them.

The prognosis is doubtful. If left to itself the disease that at the beginning was merely superficial or sub-epithelial, is cured only after months of distress, leaving behind it numerous opacities of greater or less density, which disturb the visual acuity the whole life long. If the treatment is a proper one, the prognosis is, on the other hand, essentially better. The general treatment has been discussed on *p. 209*. The local treatment differs with the stage of the disease. If the case is a recent one of corneal phlyctenule or simple infiltrate a soothing treatment is in place. In such a case I use inunctions of atropinized vaselin (*0.1 : 10.0*) and a bandage. If an ulcer has already formed, the treatment for corneal ulcer is the proper one,—that is, douches, atropin, iodoform, bandage, and, if the improvement is not rapid, curetting, which removes granulations occupying a rather deep space undermining the edge of the ulcer. This space is particularly developed at the apex of the vascular tissue. If the severest symptoms of irritation have passed, or if the ulcer has begun to heal, it should be treated by stimulants, calomel powder, or yellow ointment. This is also applicable to eczematous pannus.

If there is a doubt whether it is an open ulcer or a new infiltrate, the fluorescin test should be applied; if the diseased area is colored green it is not yet the proper time for a stimulating treatment. An exception to this is offered in the case of suppuration from the conjunctiva, which, if present, may be treated with two per cent. nitrate of silver solution, even if a recent ulcer is present; after this, atropinized vaselin and a bandage should be applied.

Digitized by Illinois College of Optometry

Photophobia of children has been traditionally overcome by a few seconds' dousing of the face in cold water. It is easy to see that children for the moment forget their fear of light in their fear of choking to death, and that they therefore open their tightly closed lids at the dread of it; but such a result does not last long and is certainly purchased at the expense of mental agony to the child. It is just as easy to obtain the effect with milder means, cold water, for example, or in any case by a cold douche; moreover, the sensitiveness of the cornea can be reduced by atropin, or even better by cocain, both of which may be applied in the form of ointments (*Atropin sulf. 0.1; Vaselin 10.0;* or *Cocain mur. 0.2; Vaselin 10.0*); the mere covering of the cornea with a layer of vaselin has a good effect in moderating irritation. In case the eczema has already changed to an ulcer a bandage is unconditionally demanded. As soon as the cornea begins to improve, the photophobia, as a rule, diminishes.

(β) Catarrhal Ulcer is a disease of elderly people suffering from chronic conjunctivitis. It looks something like a furrow running parallel to the edge of the cornea, appearing most usually above, that is, in that part of the cornea covered by the lid. Often there are several ulcers along the edge of the cornea, one after the other. The first stage of catarrhal ulcer is usually an infiltrate or a group of pinhead-like infiltrates, which gradually coalesce into an ulcerous furrow. The prognosis is favorable. The **treatment** is that, in general, of corneal ulcer; if the secretion from the conjunctiva is very abundant this must be at the outset overcome by application of two per cent. nitrate of silver solution.

(γ) Corneal Ulcer in Trachoma.—Ulcers are not regular occurrences in trachoma; they are not dangerous to the eye if they are at the edge or within the area of a corneal pannus, since the vascularized cornea is to a certain extent protected against necrosis. If, on the other hand, in acute trachoma (*p. 199*) there is a loss of corneal epithelium, the result may be a dangerous ulcer produced by infection from the conjunctival secretion so rich in bacteria. Ulcers of a pannused cornea need no particular treatment; they heal of themselves if the conjunctiva is treated properly. Ulcers in acute trachoma should be treated according to the same principles as in blennorrhea.

(δ) Corneal Ulcer in Blennorrhea.—This ulcer begins with a small, scarcely perceptible loss of epithelium at the apex of the cornea. Twenty-four hours afterward there is a round or elliptical infiltrate present, which is decidedly greater than was the loss of epithelium. The infiltrated portion melts rapidly away. The depth of the ulcer is easily underestimated, since its base only, not the edges and surroundings, are clouded. Horner's is the best method of recognizing this funnel-like extension—very oblique (tangential) inspection, of course with the aid of focal illumination. A cure may be effected by the reproduction of the epithelium to replace what was already lost; this new form of tissue, in the course of

Digitized by Illinois College of Optometry

years, becomes more and more like true corneal tissue, and more and more nearly transparent. A cure may again result by the development of blood-vessels, which are spread to the ulcer from the lower edge of the cornea. Or, finally, a keratocele is produced, followed by a perforation, before healing is accomplished.

Another form begins like a catarrhal ulcer but does not seem to have any inclination to heal; it rather creeps along the edge of the cornea, so that a circular ulcer is produced, which, as Sæmisch says, to a certain extent undermines the cornea and destroys it.

Treatment consists in the speediest cure of the conjunctiva (*p. 191*). The ulcer itself is to be protected as far as possible from infection with the conjunctival secretion, by means of inunctions of borated, sublimated, or iodoformized vaselin. The bandage is inadmissible, since it would retard the removal of the pus that ought to be removed as rapidly as possible. If perforation threatens, eserin should be used. Even after perforation eserin acts favorably, and often drags the prolapsed iris back into the anterior chamber, or at least away from the surface of the cornea.

(ε) CORNEAL ULCER IN DIPHTHERIA begins with a delicate cloudiness, the corneal area appearing as if it had been just breathed on; then follows loss of epithelium, infiltration of pus, and necrosis. According to Horner the color of a diphtheritic ulcer is yellow or even a yellowish-brown, darker, therefore, than a blennorrheic ulcer; another distinction lies in the rapid course of the diphtheritic process, twenty-four hours being often sufficient to cover the progress from loss of the epithelium to perforation. If the diphtheritic ulcer begins with the conjunctival disease, say on the first or second day, the eye is surely lost, for the cornea must have been accidentally supplied with blood-vessels from some ulcerous disease—an eczema, for example. If the ulcer, on the other hand, does not develop until the end of the first week, we may hope to retain at least a part of the cornea. Ulcers arising later are, of course, still less dangerous. The treatment is that of a blennorrheic ulcer.

(ϑ) KERATITIS PUNCTATA SUPERFICIALIS (Fuchs).—During an acute conjunctival catarrh in young persons there may develop a number of small, gray, elevated points in the superficial areas of the cornea. These points are in groups and rows, or are spread over the entire cornea. The disease is more often bilateral than unilateral; the irritation produced by them soon disappears but the dots remain for months. I have seen two cases that fitted to Fuchs' description, except that in them the disease of the conjunctiva was deeper and more rebellious. The appearance of these gray dots in the cornea was but an act in the drama of an extremely rebellious conjunctival catarrh, defying the usual treatment.

(*c*) Inflammation Resulting from Disease of the Nerves.

(*α*) HERPES ZOSTER OPHTHALMICUS CORNEÆ.—Herpes describes a group of small vesicles filled with a watery fluid. Herpes of the skin, as a phenomenon of a disease of the first branch of the trigeminus, has been mentioned on *p. 143*. This herpes zoster ophthal-

Digitized by the Columbia College of Ophthalmology

micus at times passes onto the cornea. The vesicles are very transient, and are usually broken before the physician catches sight of the patient, the physician finding only a group of small corneal ulcers. However, the disease is easily recognized by the herpes, or the fresh scars of it on the forehead, and by the patient's description of the pain which accompanied it. This disease has, besides, two particular diagnostic signs: anesthesia of the cornea and softness of the eyeball.

The sensation of the cornea may be proved by touching it with a cone of paper. Normally, the lightest touch will excite an immediate closure of the lids. If the sensation is reduced, however, the lid does not even wink. Anesthesia may be of itself the cause of a disease—*keratitis neuroparalytica* (*p. 238*).

In a dissertation by J. Wanglar, he reports six cases of herpes zoster in which the vesicle and ulcers did not appear, the only local condition being small opacities lying just below the epithelium. Within the area of these opacities the cornea was anesthetic.

(β) Herpes Febrilis (Horner).—Vesicles of *0.5* to *1.0 mm.* in diameter develop on one cornea with profuse lacrimation; generally a group of these forms a connecting line somewhat fork-shaped. These vesicles exist for an extremely short time; they break so soon that when a physician makes an examination he sees only the result of the vesicles, irregularly bordered ulcers (*Fig. 85*) having a great similarity to the superficial injuries (epithelial scabs). The naked eye can scarcely detect any opacity of the cornea, but with a lens a delicate gray cloudiness near the ulcer may be seen. The ulcer itself is the only anesthetic portion; the remaining cornea being sensitive. Healing takes place without the growth of blood-vessels, although it takes much longer than in equally extensive loss of substance from other causes. If the ulcer becomes infected it loses its characteristic appearance, and may assume all the peculiarities of an ulcus serpens. The latest investigations of Haab have shown that a new crop of herpes vesicles may spring up, which coalesce with the old ulcers and appear to be a continuance of them. The peculiarly branched form of a herpetic ulcer has attracted to itself several distinct descriptions, with such names as keratitis dendritica, kératite ulcéreuse en sillons étoilés, keratitis ramiformis.

Fig. 85.—Herpetic Ulcer. (*After Hagnauer.*)

Digitized by Illinois College of Optometry

It should not be forgotten that the discoverers of these forms of keratitis have energetically opposed the reproach that they have described cases of herpes as distinct diseases; for example, Emmert distinguishes *keratitis dendritica* from herpes in the following way: "Keratitis dendritica is not preceded by a general febrile condition; the conjunctiva of the upper lid is more swollen than it is in herpes. In exceptional cases keratitis dendritica begins as a sub-epithelial, grayish opacity, forming a tree-like figure; the epithelium about it is puffed up and of a grayish color; after this epithelium has been thrown off the grayish furrow is seen beneath it, which forms a tree-like ulcer."

I have just had under treatment a girl whose eye became inflamed after an acute fever of two days. I was thus able to show the case to a pupil as a typical herpes *in statu nascendi*, that is, in the vascular stage. The next day I showed the case to a young physician from Berne, who exclaimed with great pleasure: "That is a case of keratitis dendritica!" To be sure, the vesicles had disappeared, although ulcers were by no means present, but only two delicate, superficial, tree-like opacities, which branched out from two dense, round, marginal infiltrations toward the center of the cornea. Thanks to the early treatment, there was no formation of ulcer at all. I am compelled to conclude, therefore, that keratitis dentritica is only a form of herpes corneæ.

Herpes corneæ febrilis is, like herpes of the lips and of the nose, a symptom of a febrile disease, particularly of inflammation of the lungs and of grippe; but a collection of 150 cases made by Haab has shown that in about half the number a general febrile condition could not be demonstrated. If we consider that herpes belongs to the rare diseases, that febrile disturbances are, on the other hand, of daily occurrence, that herpes is often extraordinarily painful and almost always confined to one side, and that this herpes corneæ has the greatest resemblance to the demonstrably neurotic herpes zoster, it is admissible, for the present at least, to group it among the neurotic inflammations.

The course is a slow one, lasting for weeks, or often months; only the mildest cases and those treated from the very beginning will heal without a scar. The scar of herpes is so characteristic that the diagnosis of herpes may be often made long after the disease has been cured. The surface of the scar remains for months uneven, a particularly noticeable sign when the shallowness of a herpetic ulcer is considered. The edge of the scar is very irregular, as if a fork of lightning had passed across the cornea. Since the scar tissue forms only a very thin layer, the scar itself appears of a delicate gray, and can be well seen only with focal illumination; it is generally free from blood-vessels. Since herpetic ulcers show no inclination to extend, the treatment may be confined to the gentlest measures, with atropin, disinfection, and the bandage.

By scraping with a sharp spoon I have in two or three days cured ulcers which have defied milder measures for weeks at a time. I therefore resort to this little operation

Digitized by Illinois College of Optometry

with much greater freedom. For after-treatment massage with yellow ointment is to be recommended. This should not be begun too early, however, particularly if the cornea is still uneven.

Keratitis Filamentosa (Fädchen-Keratitis).—After injuries to the cornea, after herpes and similar ulcers, there may, at times, be seen little threads hanging from the area which has been denuded of epithelium. They consist of metamorphosed epithelial cells twisted together into a thread. Occasionally such threads may be seen on an otherwise healthy cornea, suggesting the diagnosis of a special disease.

(γ) KERATITIS NEUROPARALITICA.—If the nervus trigeminus of a rabbit be severed within the cranial cavity, either in front of or at the Gasserian ganglion, the animal utters a cry, the pupil of the affected eye contracts, and the cornea and conjunctiva become anesthetic. On the following day the center of the cornea is cloudy, the cloudiness increases, the grayish-white color turns to yellow, and the cornea dies in a suppurative condition. This process is called keratitis neuroparalitica. What is the explanation of it? An immense number of theories gives us about as many contradictory answers. One view is that on account of the anesthesia of the cornea small injuries may happen to it, which are changed into creeping ulcers by the entrance of germs. This explanation is correct but by no means complete, since injuries to the cornea in a rabbit whose nerve has not been cut do not show the least inclination to change into ulcers. Others answer by saying that the cause of the disease is a drying up of the cornea, since section of the trigeminus deprives the lacrimal gland of its functions and prevents closure of the lid. This explanation, also, is insufficient, since it is well known that a healthy rabbit does not secrete tears unless he be particularly stimulated, nor does he wink very much. A third and more probable explanation is given by Gaule, who observed that section of the trigeminus produced on the epithelium, the endothelium, and the fixed corneal cells changes that could be demonstrated by the microscope (cellular subdivision on the one hand, cellular death on the other). These changes are by no means a keratitis neuroparalitica, nor do they necessarily produce it, but the power of resistance in the cornea is so much reduced that external influences such as dryness, injuries, and germs may easily accomplish the destruction of the cornea. How the section of the nerve or ganglion produces these demonstrable changes in the corneal cells has itself not yet been explained.

Keratitis neuroparalitica, such as is artificially produced on an animal, may happen to man, although less typical and less pure. Pathological changes in the cranial cavity, hemorrhages, new growths, syphilitic gummata, and the like, are not as sharply defined as a firm puncture or section by the hand of a skilled operator. Cases of trigeminus paralysis in man are, therefore, not so complete, and are, moreover, associated with paralysis of other nerves, the oculomotor, the abducens, the facialis, for example; the preceding description of keratitis in a rabbit is consequently applicable to that in man, but its course in man is much more chronic. Moreover, it is a peculiar fact that in man the portion of the cornea covered by the upper lid will often remain uninjured.

Prognosis and treatment must depend upon the causative disease

Digitized by the Internet Archive

within the cranium. Of course, care must be taken that the cornea is protected from dryness, from injury, and from infection.

(δ) KERATITIS BULLOSA.—Vesicles of *4* to *5 mm.* diameter spring up on the cornea in the center or the lower half, less often on the upper half, accompanied by considerable pricking pain. They are moderately filled with fluid, hang downward like a bag, and are moved hither and thither by the edge of the lid. The wall of the vesicle usually consists of nothing but corneal epithelium. After a few days the vesicle breaks, its contents is discharged, and the remnants of the wall are worn off by the lids. As soon as the vesicle breaks, the symptoms of irritation subside. In a few days the epithelium is reproduced, and the moderate opacity of the cornea, apparent at the site of the vesicle, gradually clears. This would end the matter if the process were not repeated, after a greater or lesser interval of quiet; but the disease may extend over months in this way.

The nature of the disease is not known; the best presumption is that some disease of the corneal nerves is at the bottom of it. Its recurrent appearance and the fact that in many cases there is decided pain in the territory of the supraorbital nerve, accompanied by a moderate swelling on the forehead, would support this view.

Keratitis bullosa may attack healthy eyes or eyes that have been previously irritated by some scratch. It is most commonly observed in glaucoma absolutum, in glaucoma secundarium, that is, on corneæ that are seriously diseased. **Treatment** consists in opening or in excising the vesicle, atropin and cocain if the pain and photophobia are severe, and protection from germs by antiseptic bandage; yellow ointment may be used after all inflammatory symptoms have disappeared.

(*d*) Ulcers from General Diseases.

(*a*) KERATITIS E LAGOPHTHALMO.—Many people do not completely protect the eye by the lids during sleep. The cornea is perhaps not injured by this, because the eye of the sleeping person turns upward and the cornea lies beneath the upper lid in any case; but if, under certain circumstances (*p. 160*) the protection to the eye is so insufficient that a bit of the cornea remains uncovered during sleep, the corneal epithelium on this area becomes too dry and perishes, and the result is a keratitis e lagophthalmo. It is evident that this will result the easier if the cornea is at the same time insensitive (*p. 238*), or if the integrity of the corneal tissue has suffered very deeply by some great exhaustion of the whole body. The first condition, due to lack of sensation in the cornea, may result from any disease of the brain causing paralysis of the facial or trigeminal nerves. The second condition, due to some profound nutritive disturbance, may result in persons who have lain in a comatose condition for a long time—for example, in typhoid fever, uremic coma, or in the prolonged agony of carcinoma. This corneal ulcer is distinguished by its location at the lower edge of the cornea, by its sharply divided upper edge parallel to the margin of the upper lid, and, finally, by the fact that a dry scale is first pro-

Digitized by Illinois College of Optometry

duced, the ulcer not being visible until this scale is thrown off. Of course, there must be a positive proof that the ulcerated portion of the cornea has been actually exposed to desiccation. **Treatment** must be directed to protection of the cornea by the lids, either by means of a bandage, or, if this does not suffice, by an operation (*p. 152*); general principles, of course, apply.

(*β*) KERATOMALACIA INFANTUM, XEROSIS MARANTICA.—The disease appears usually, although not always, as we might expect from the name, in children during the first year of life. The patient is always severely ill, either from scarlet fever or syphilis, or from some profuse diarrhea which has brought him to the edge of the grave. The affection of the cornea begins with cloudiness and looseness of the epithelium below the palpebral fissure. The conjunctiva is at the same time in that condition described on *p. 213* as xerosis epithelialis. The disease extends rapidly within the cornea, which becomes necrotic without the inflammatory reaction that ought to accompany such destruction. As the profound prostration of the patient often prevents the eyelids from being completely closed, it is evident that the danger to the cornea is so much the more increased.

The prognosis is bad. Many such patients succumb to their disease. If recovery should take place, the corneal ulcer heals with several disturbing scars. **Treatment** must be directed to the preservation of the patient's strength first of all, then to disinfection, protection, and to encouragement of nutrition in the cornea. For the last purpose warm compresses are very serviceable.

Corneal Necrosis after Glaucoma.—When glaucoma (*q. v.*) has run its complete course, the affected eye is so radically changed and its nutritive condition is so impoverished that the cornea may suppurate and die. How much the anesthesia of the cornea may be considered, along with the impaired nutrition, as a cause of this necrosis cannot at present be decided.

3. INFLAMMATIONS WITHOUT THE FORMATION OF ULCER.

(*a*) **Pannus** is a new growth of connective tissue between the epithelium and Bowman's membrane, provided more or less abundantly with blood-vessels. If pannus begins superficially, it is not always restricted to this layer of the cornea (*Fig. 86*), but if the disease continues long enough it may affect the cornea proper, very clearly demonstrable, as Sæmisch says, by the fact that the vessels lying within the different layers may be seen crossing above or below each other.

Raehlmann thinks the condition is somewhat different. He found that pannus began beneath, not on, Bowman's membrane, and that the disease spread from here toward the surface and toward the depth. For example, collections of cells develop beneath Bowman's membrane; these are genuine follicles provided with an envelope; they raise Bowman's membrane and the epithelium, and then break out in small ulcers. These ulcers, however, play no part clinically; they need no particular treatment, and do not prohibit us from considering pannus among the "inflammations without ulcer."

Digitized by Illinois College of Optometry

Raehlmann found, further, that a pronounced pannus was developed with special layers, and that these layers consisted in part of sclerosed (cicatricial) connective tissue and in part of round cells; he considered that the layers stood for a gradual development of new tissue—the deposits of round cells indicating the new layers, the connective tissue, the old. The cornea becomes noticeably thickened by these numerous layers, reaching twice the normal thickness. In spite of this, however, it has no greater resistance, but on the contrary may be weakened by it, and on this account may easily yield to the internal tension of the eye, a condition known as ectasia (*p. 261*). The thickness of the pannus tissue decreases from the edge of the cornea toward its center; pannus at the edge of the cornea may extend even to Descemet's membrane; but at the center of the cornea only the anterior layers immediately below Bowman's membrane are infiltrated. The diminution in thickness from the edge toward the center of the cornea is so sudden that the pannused surface may be accurately marked off from the healthy tissue.

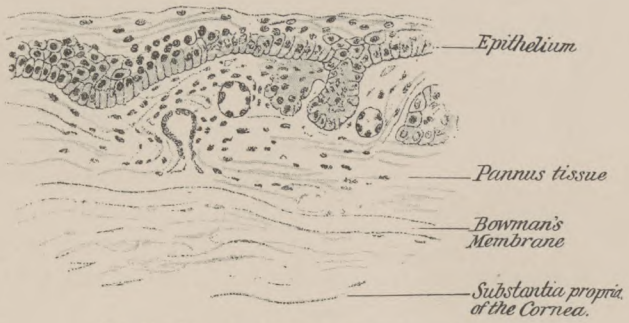

FIG. 86.—PANNUS. (*After Pagenstecher and Genth.*)
There are four blood-vessels to be seen in the section.

The vessels in pannus are offshoots from the marginal network, but occasionally come from the larger vessels arising far back from the conjunctiva. For this reason it is possible to follow a blood-vessel past the sclero-corneal margin into the conjunctiva.

Clinically, pannus appears as an inflammation of the cornea, in which large areas are clouded and penetrated by superficial vascularization. Therefore the surface of the cornea is not smooth but rough, uneven, filled with ridges which seem to be formed from the surface of the cornea by the thicker vessels. If this vascular formation is so luxurious that the red of the blood-vessels predominates over the gray of the pannused tissue, the condition is called *pannus crassus* or *carnosus*. If the mesh in the vascular network is coarse, the condition is *pannus tenuis*. There are two kinds of pannus, *pannus trachomatosus* and *pannus eczematosus*. The first has been described on *p. 201*; it is distinguished by the fact that it attacks the upper half of the cornea in an eye already suffering from a trachomatous inflammation of the conjunctiva (*Fig. 87*).

Digitized by Illinois College of Optometry

Pannus eczematosus has been described on *p. 232* under the name of phlyctenular marginal pannus or keratitis superficialis vasculosa. It may be supplementarily remarked that at the border between the transparent and pannused cornea new groups of grayish dots, small infiltrates or phlyctenules, may appear. The result of this is that the vascular network extends into the hitherto transparent cornea, and in doing so changes the marginal pannus into an eczematous pannus, or under certain conditions may spread over the entire cornea.

Pannus traumaticus may be described as still a third variety. It occurs after long-standing irritation of the cornea by inverted lashes (trichiasis) and lids (entropium); ulcers are not always formed, but only a superficial cloudiness—pannus, due to the blood-vessels. Of course, both conditions, pannus and ulcers, may occur together, especially if not only trichiasis but also eczema and trachoma have led up to it. In traumatic pannus the sharp outline between healthy and unhealthy tissue, and the rough, raw surface, with the thickening of the cornea, are all lacking.

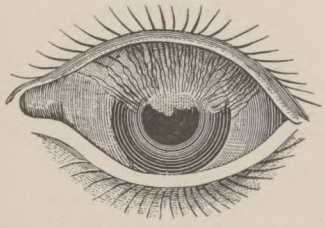

FIG. 87.—PANNUS TRACHOMATOSUS. (*After Sichel.*)

Treatment of traumatic pannus consists obviously in curing the trichiasis. The absorption of the pannused tissue can be encouraged by massage with yellow ointment; the same method is applicable in eczematous pannus. Trachomatous pannus heals without special treatment if the trachoma of the conjunctiva can be cured. In many cases, to be sure, the pannus outlasts the conjunctival disease; under such circumstances the various stimulating applications, such as yellow ointment, tincture of opium, and sulfate of copper, and, as a last resort, circumcision, must be tried. This last name indicates the operative excision of a strip of conjunctiva about *2 mm.* wide, parallel to the edge of the cornea; the vessels running to the cornea are in this way exposed or cut through, and as the wound cicatrizes they become obliterated. Another method deserves mention, namely, the production of a conjunctival blennorrhea by touching the conjunctiva with an extract of jequirity seeds (paternoster beads). It was quite accidentally observed that an old pannus healed in a remarkable manner after the cornea had been excessively inflamed

Digitized by Illinois College of Optometry

by any foreign substance. Even this method may fail, however, if the opacity depends not upon a fresh pannus but upon cicatricial connective tissue.

(*b*) **Keratitis Parenchymatosa** (*Keratitis interstitialis diffusa*).—The center of the substantia propria of the cornea becomes opaque after a moderate irritation and pericorneal injection; these opacities increase slowly but surely, so that after several weeks the entire cornea is saturated with them. Spoke-like opacities may occasionally be seen; all opacities are not of the same density, so that by superficial observation many parts of the cornea may appear quite unaffected. Nevertheless, when the disease is at its height, focal illumination will reveal more or less delicate opacities, even in such apparently unaffected areas. Without a lens the cornea appears diffusely opaque. In other cases,—this is the rule according to Horner,—the disease begins not at the center of the cornea, but at the margin, and advances step by step from all sides toward the center. Since the affected portions of the cornea are thicker than the healthy ones, the transition is often very abrupt. The epithelium is changed at the same time. At first it appears dull, later stippled, but never shows loss of substance. Ulceration is never a characteristic of this disease.

The disease is not restricted to the cornea alone; deeper portions of the eye, the iris especially, may be affected sympathetically, the production of posterior synechiæ being evidence of this. In fact, any series of cases may show a cyclitis or a choroiditis, with all their destructive consequences to the normal condition of the globe and the nutrition of the lens and vitreous. The involvement of the deeper tissues of the eye is often not recognizable until the clearing up of the cornea which has meanwhile resulted allows the deeper parts to be inspected.

Opacities of the cornea due to migration of round cells begin after several months to clear up from the margin by means of newformed corneal vessels. The number of these vessels varies, so much so, in fact, that one is inclined to call each case a particular disease. It must be remembered, however, that few cases run their course entirely without vascular formation, and that the recession of the opacities results quicker and more completely the more abundant this vascularization. These vessels are distinguished from the superficial vessels of pannus in three ways:—

(1) They do not, like pannus vessels, spring from the marginal

Digitized by Illinois College of Optometry

network of the conjunctiva, but from a network lying deep within the sclera, so that they can be followed only to the sclero-corneal margin; the pannus vessels, on the contrary, are easily traceable beyond the scleral margin into the conjunctiva.

(2) They are not, like superficial pannus vessels, covered by epithelium alone, but by the opaque cornea. They are, therefore, less red and less visible than pannus vessels, and are best seen by illumination from behind (*p. 100*).

(3) They are thin and run in parallel groups, while pannus vessels, at least those in eczematous and traumatic pannus, are of different sizes and spread out like branches of a tree.

It does occasionally happen that in keratitis parenchymatosa superficial vessels spring from the conjunctival network.

The condition of irritation is just as dissimilar as is the formation of blood-vessels. As a rule there is neither photophobia nor pain, in spite of pronounced injection about the cornea. This inflammatory redness about the cornea is, however, as much to be desired as the development of blood-vessels within the cornea, since it indicates the more rapid progress of the disease; although even in such cases the disease may be expected to last several months, and unfavorable cases may last for years, with alternate improvement and relapse.

Keratitis parenchymatosa is evidence of general infection. In proof of this we have the fact that in at least 80 per cent. of cases, according to Horner, both eyes are attacked, although not necessarily simultaneously. Besides this, Hutchinson has shown that inherited syphilis is undoubtedly the cause of the condition and is demonstrable in about two-thirds of all cases. It is therefore best to search for other signs of inherited syphilis. Among them may be mentioned "Hutchinson's teeth"—a condition characterized by an irregularity of the upper incisors, the edges of which are changed from a horizontal straight line into an upcurved arch. Other signs are a permanent thickening of the periosteum, particularly on the shin, painless joint affection, glandular swellings and cicatrices, scars and malformations of the palate, and rapidly developing deafness. Since inherited syphilis lies at the bottom of the disease, it is found particularly in young persons between the fifth and twentieth year; but it is not quite clear why female children should be attacked nearly twice as commonly as male children.

Digitized by Illinois College of Optometry

The diagnosis is easy in the fully developed condition; the affection in both eyes, the profuse opacity of the entire cornea, which is salmon-gray if the vascularization is abundant, or grayish if it is moderate, the lack of ulceration, all produce a noticeable pathological picture. On the other hand, the diagnosis is hard if the disease is found in any of its first stages, for so long as there is only a marginal opacity with congestion of the neighboring vascular network, there is danger of confusing the condition with keratitis eczematosa; the progress of the disease must be our guide.

Keratitis parenchymatosa was at one time considered of scrofulous origin. This old view has recently received more attention, inasmuch as many authors think that a certain proportion of the cases result from scrofula or modified tuberculosis. Acquired syphilis is said to be able to produce keratitis parenchymatosa.

The prognosis is unfavorable, and the patient must be told that his trouble will last for months or years, that the second eye will most probably be attacked, and that a restoration of the visual acuity unimpaired is scarcely to be hoped for, especially if the patient is not very young. There is almost always left some corneal opacity, in which one can see several fine blood-vessels with a magnifying glass, and from the presence of these unusually fine vessels one can detect the evidence of a keratitis parenchymatosa years or even decades afterward. Fortunately, complete loss of vision is seldom to be feared.

Treatment has little influence upon the course of the disease; if syphilis, either inherited or acquired, can be proven, an impressive course of mercurial inunction should be tried, unless anemia or general exhaustion make the method dangerous. In such a case mercurial treatment must be abandoned, and the physician should resort at once to iodid of potassium, iodid of iron, cod-liver oil, baths, and fresh air. Local treatment must be restricted to atropin, warm compresses, and protective glasses. Atropin overcomes the iritis and breaks up the posterior synechiæ, moist heat encourages vascularization and thereby shortens the disease. The tentative use of massage with yellow ointment to hasten the absorption of the infiltration should not be resorted to until the disease has passed the climax and the clearing up has begun. If massage is well borne, more energetic means may be tried, and the yellow ointment displaced after several weeks by other stimulants, such as calomel powder or equal parts of turpentine and olive oil.

Digitized by the College of Optometry

(*c*) **Keratitis parenchymatosa circumscripta** is a rare inflammation of the cornea that has many signs in common with keratitis parenchymatosa. It begins as a grayish opacity at the center of the cornea, rather in the middle layers. The opacity extends to the epithelium and to the posterior surface of the cornea. The marginal portions of the cornea remain free. After several weeks or even months have passed, the opacity begins to clear, but this process is seldom completed, and there is apt to be left an incurable corneal deposit exactly in front of the pupil. The irritation is slight, and may be so completely absent that at the first inspection no inflammation is seen, and one thinks to have found a large leukoma on the cornea. Vascularization does not take place, or if it does, it is very much less than in keratitis parenchymatosa. In severe cases the cloudy cornea is insensitive; if sensation returns, however, it is an indication of a speedy improvement. The disease is unilateral, and usually attacks elderly persons, men twice as often as women. The opacity is said to depend not on round-cell infiltrations, but on cloudiness and disintegration of the fixed corneal cells and on swelling and relaxation of the fibers. Little is known of the cause of the disease. Egger thinks that a weak physical condition with impairment of the general nutrition must be an important factor.

The prognosis, considering the length of the disease, the fact that incurable opacities are almost always left, and that the iris shows a tendency to be sympathetically affected, must be considered unfavorable. **Treatment** should seek to improve the general condition by a proper regimen; locally, the persistent use of moist applications may stimulate vascularization, and atropin should be applied in order to assure the preservation of the iris; when the irritation has completely subsided, massage with yellow ointment should be begun. Caution must be observed in resorting to operative interference, as iridectomy, for example; the eye seems to resent this, as I can confirm from unfortunate experience in the matter, and the opacity progresses rapidly into the hitherto peripheral portion of the cornea lying in front of the artificial pupil. This new cloudiness will probably clear up in a few weeks, but the patient does not relish the experience.

(*d*) **Keratitis Scleroticans.**—This disease is characterized by an involvement of the cornea in an inflammation of the sclera. The corneal opacity is of a somewhat triangular shape, its base lying toward the portion of the cornea already inflamed, its apex extending more or less into the cornea. The disease is usually chronic, with very little or no irritation, with very little or no vascularization, and without ulceration. So long as the clouded area does not extend its apex into the region of the pupil, the disease may go on without comment. The opacity recedes, also with equal slowness, but a complete clearance takes place only at the central edge of the clouded area. The marginal portions remain opaque, retaining an appearance as if the sclera had in this place grown into the cornea itself.

The prognosis is favorable if, as is usually the case, the disease is restricted to the edge of the cornea. It may last for months or years. **Treatment** should be directed to the cure of the inflammation of the sclera (*p. 262*); atropin and moist heat have been advised, but stimulants and operations should be avoided.

(*e*) **Keratitis Punctata Profunda.**—Just as the iris is sympathetically affected in severe corneal inflammation, so may an inflammation of the iris leave its mark upon the cornea. This is quite a usual result in iritis serosa (*p. 277*); indeed, "keratitis punctata profunda" itself is often the only sign of such an iritis. The changes on the cornea consist in minute points sometimes infre-

Digitized by Illinois College of Optometry

quent, sometimes innumerable, upon the posterior surface of the cornea—the so-called deposits upon Descemet's membrane. These dots may be large or small; the larger ones seen by the magnifying glass look like yellowish fat droplets. At times the deposit is arranged in the form of a triangle (*Fig. 88*). If these deposits remain very long they are apt to produce a disturbance of the nutrition and a subsequent opacity in the hindermost layers of the cornea which does not always disappear, even though the iritis serosa has been meanwhile cured and the deposit itself absorbed.

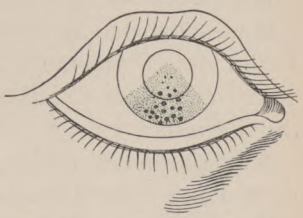

FIG. 88.—DEPOSITS UPON THE POSTERIOR LAYER OF THE CORNEA. (*After Nettleship.*)

The deposit upon "Descemet's Membrane" has such a characteristic appearance that we are at once justified in ascribing the seat of an opacity to the posterior surface of the cornea. This, of course, does not release the physician from the duty of determining by exact optical methods in what particular layers of the cornea the opacity actually lies. This can be done by means of focal illumination, the magnifying glass, and experience. If there is the least doubt, the phenomenon of the parallax must be used, that is, the apparent movement of the opacity against the surface of the cornea as a result of movement of the physician's head. It is understood that the surface of the cornea must be well recognizable, as it often is, by the way, by the minute air vesicles or collections of epithelium, fat, and mucus, all of which are rendered visible when the magnifying glass is used. If the surface of the cornea should happen to be clean it may be easily identified by dusting on it a few grains of calomel or iodoform, or by smearing it with a bit of yellow ointment. In rare cases similar droplets to those deposited on Descemet's membrane may be seen strewn on the anterior surface of the lens.

II. INJURIES.

The cornea is very often injured, partly because it is so exposed, partly because it is so tense that it cannot yield to any blow. That portion lying within the palpebral fissure is, of course, the area most often involved.

1. WOUNDS.

These are produced in innumerable ways, by scratches, for example, which little children make with their finger-nails on the eyes of their mothers or nurses. Similar wounds may be made by twigs, which may strike the eye of an unobservant traveler in the woods. Larger wounds may be made by the end of a vigorously wielded whipcord or by the blow of a cane or of the fist, especially if an

Digitized by Illinois College of Optometry

eye-glass is broken and the fragments shattered against the eyeball. The signs of a corneal wound are the following: The patient appears with an eye flooded with tears and afraid of light; he complains of great pain, or of the feeling that his eye has been scratched, or that there is a foreign body in it. The eye seems reddened, there is ciliary injection. Looking at the surface of the cornea (*p. 96*), a loss of substance is seen, but the ground is clear and unclouded. If the loss of substance is so small that it cannot be seen with the naked eye, focal illumination and the magnifying glass (*p. 98*) or the fluorescin test (*p. 222*) must be used.

The prognosis depends upon the location and depth of the wound and upon the nature of any accidental infection. A simple uninfected loss of epithelium will heal without a trace within twenty-four hours, and is therefore of no moment, even though it lies within the pupillary area. But the wound extending into the substantia propria of the cornea leaves a scar, and is therefore of great moment, although it may not lie in any portion of the cornea used for optical purposes. Still more serious are wounds of the entire thickness of the cornea; these are called perforating wounds. Immediately after a perforation of the cornea the aqueous escapes and the anterior chamber is obliterated. When the edges of the wound are bathed in the aqueous they become clouded and swollen; this cloudiness, either diffuse or striated, may extend more or less into the adjacent tissue. Usually the central layers of the cornea are quickly united, the anterior chamber is reproduced, the iris returns to its natural position, the epithelium grows from without into the wound, and under the protection of this new-formed cover the cleft is filled up again. If the wound is large, however, the escape of the aqueous is so sudden that the iris prolapses. The results of such an accident are discussed on *p. 257*.

It very often happens that bacteria enter the wound, either carried by the object producing the injury, or absorbed from the conjunctiva or the edge of the lid; or the wound may be subsequently infected by dirty fingers or pocket handkerchiefs, or by dirty water that has been used to bathe the eye. The evidence of such infection is a cloudiness of its edges and their surroundings. We have now all the manifestations of an ulcer, a *keratitis traumatica*. The appearance and course of this traumatic ulcer cannot be accurately given, since they depend so much upon the nature as well as upon the number of the germs that have found entrance.

Digitized by Illinois College of Optometry

If, for example, the injured person is suffering from an inflammation of the tear sac, the result will be "ulcus serpens;" if he has an old and indolent conjunctivitis, the result would be an ulcer that we may call catarrhal (*p. 234*) for lack of a better name.

Treatment of a fresh, uninfected, and smaller wound is met by a simple antiseptic bandage. If the wound is larger and if there is much irritation, atropin may be used in addition. If the iris has prolapsed the effort should be made to replace it by means of a small spatula, and to retain it in place by eserin, a bandage, and rest. If this is not successful the prolapsed portion must be seized with an iris forceps (*Fig. 89*), drawn out, and excised with one stroke of the scissors—in short, an iridectomy (*p. 280*) is completed.

FIG. 89.—IRIS FORCEPS.

2. FOREIGN BODIES (CORPORA ALIENA).

By far the most frequent injury to the cornea is made by a foreign body. Among the foreign bodies bits of metal, and among these bits of metal little iron chips are the commonest. Every foreign body produces the well-known signs of a corneal inflammation, its degree depending altogether upon the character of the foreign body. If the foreign body is covered with bacteria, as is usually the case, the result is an ulcus serpens. If it is free from bacteria, as is the case in bits of molten metal, the effect is only a mechanical, or a thermal, or a chemical one. The use of the actual cautery has often enough proven that the thermal effect is no more than that of an immediate and simple burn, and small aseptic cautery wounds heal with unusual promptitude. The chemical effect of a bit of iron is characterized by a small, encircling, brownish ring, indicating that the directly adjacent tissue of the cornea has been discolored by the oxid of iron (rust). Even the inflammation produced by bits of iron or copper may be largely ascribed to their chemical effect. If such an action must be excluded, in the case of bits of glass, for example, the mechanical effect is, nevertheless, sufficient to produce an irritation, since the weight and movements of the lids will press the foreign body into the cornea, so well supplied with nerves.

Digitized by Illinois College of Optometry

It is not always easy to find a foreign body, especially if the patient is not sure that it is in the cornea. It often happens, therefore, that the foreign body is overlooked. This may be easily avoided by a rigid adherence to the systematic examination recommended on *p. 141*, from the surface to the interior of the eye. The experienced physician will probably suspect the presence of a foreign body, even though the patient makes no mention of it, by the peculiar, delicate rose-red injection in the cornea. Dark foreign bodies are best seen against the comparatively light background of the iris. If a foreign body is not seen by simple inspection, focal illumination (*p. 98*), transillumination (*p. 118*), and the fluorescin test, must each in turn be used. When fluorescin is applied, the presence of the foreign body will be betrayed by the greenish area which surrounds it.

FIG. 90.—SPUD FOR REMOVING FOREIGN BODIES.

If the foreign body is not removed, it never altogether heals in situ. There is almost always about it a cell-infiltration which destroys the tissue immediately adjacent, so that the foreign body is loosened and may be washed away by the tears. This process, of course, takes place slowly, with all the phenomena of inflammation, and thus every opportunity for infection is offered.

Treatment demands immediate removal of the foreign body; this is accomplished by means of a small curette, chisel, or spud (*Fig. 90*). The cornea should be made insensitive by an aseptic cocain solution. The patient is then told to look steadily at some point. The left hand of the surgeon raises the upper lid and presses gently upon the eyeball in order to keep it steady. In removing foreign bodies the use of the lens and of focal illumination is most emphatically to be recommended. By this means the very minutest particle can be removed without any appreciable injury to the cornea itself. The lens should be held between the index finger and thumb of the left hand, while the middle and ring fingers raise the lid and press upon the eyeball. The illumination must be supplied by an assistant; if there is no assistant at call, a very good device may be made by fitting a convex lens to a lamp so that the light is properly thrown upon the field of operation. If the foreign body lies very deep in the cornea, it may be crowded into the anterior chamber by unskilful manipulation. This is a

Digitized by Illinois College of Optometry

serious accident. The foreign body then falls into the iritic angle and can no longer be seen by the surgeon. It is best, therefore, if the foreign body is close to or within the anterior chamber to introduce a small keratome (*Fig. 79, p. 213*), such as is used for iridectomy, into the anterior chamber, pressing the flat of the blade against the posterior surface of the cornea, and then with the support thus offered to remove the foreign body. After its removal a corneal wound is left, and this must be treated according to the rules already given.

3. BURNS.

Steam, molten metal, explosions of powder and dynamite, and, in the broader sense of the word, irritating chemicals, usually strike the lids and conjunctiva as well as the cornea, the conjunctiva, perhaps, being even more seriously affected (*p. 216*). The involvement of the cornea is recognized by a diffuse opacity and insensitiveness.

The prognosis depends upon the extent and depth of the burn; if only the epithelium has been destroyed, complete restoration will be effected without any permanent opacity. If the substantia propria of the cornea is burned off the whole tissue will slough away, and the healing will result with formation of a cicatrix. The degree of anesthesia is a good criterion of the depth of the burn. **Treatment** has been mentioned on *p. 216*.

4. FRIGERATION.

Cases have been reported of ulcers of the center of the cornea resulting, in the opinion of the attending physician, from severe cold.

III. CORNEAL OPACITIES OF A NON-INFLAMMATORY NATURE.

1. **Arcus Senilis** (*Gerontoxon*).—In old, sometimes even in young persons, there is seen a circular opacity of the edge of the cornea, distinguishable from other peripheral opacities by the fact that the outermost portion remains transparent. Its appearance, therefore, is that of a grayish-white ring about *1.5* to *2 mm.* broad within the cornea, surrounded by a very small dark ring (the iris) bordering on the sclera. The epithelium above this opaque ring reflects light perfectly. Fuchs' opinion is that the opacity is due to a deposit of hyaline material which has settled from the nutrient lymph stream between the lamellæ of the cornea as an insoluble form of albumin. Owing to the peripheral position of the arcus senilis it seems to have no bad influence on vision.

I think that a similar degeneration occurs in the more central portions of the cornea,

Digitized by Illinois College of Optometry

for I have twice observed corneal opacities without any indication of irritation and without any preceding inflammation. These opacities were unlike the ribbon-like opacities (*p. 253*), since in the former the epithelium reflected light perfectly, the borders were indistinct, and they extended over a greater portion of the cornea. In the second of my cases this bilateral cloudiness was coincident with an arcus senilis of unusual breadth and density.

2. **Cocain Opacity.**—We may well say that cocain, introduced into ophthalmology by Koller, has become an indispensable blessing. But even this drug, however indispensable it may be, proves itself at times a treacherous friend, since it annihilates the result of many a cataract operation by the incurable diffuse opacity of the cornea which it causes. If the physician has not himself had this severe experience he must certainly have often enough seen the beginnings of a cocain opacity in the haziness which the surface of the cornea assumes. This haziness has, as Wuerdinger shows, two causes:—

(1) The "lymphatic anemia," and

(2) The desiccation of the uncovered cornea.

The expression, lymphatic anemia, certainly an improper one, is used by Wuerdinger to designate the fact that the cornea, especially the central area, is made thinner and deprived of its nutrient material by cocain. If such an eye cannot be closed, a rapid desiccation takes place. It proves, therefore, that the cornea in this condition is extraordinarily inclined to absorb medicinal fluids, such as sublimate solution, which have been poured over it, and consequently it becomes still more opaque. To avoid cocain opacities it is best to have the eye closed after each drop of solution, and not to hold the eye open longer than is necessary when the operation is going on. Milder degrees of cocain opacities disappear without a trace, and those which remain are usually caused by cocain and sublimate together. As Nellinger has shown, they result from the fact that the sublimate solution penetrates to the anterior chamber and remains there. The part played by cocain is of importance only in so far as it encourages the penetration of fluid to the anterior chamber by reducing the tension of the eye and lowering the resisting power of the protective endothelium.

3. **Keratitis Striata.** — Another corrective proceeding, the bandage, is equally liable to produce corneal opacities, particularly if it is applied too tightly. These show themselves as delicate light gray lines which cross the cornea in all directions, so that they have the appearance of a crack on the surface of ice. Probably

Digitized by Illinois College of Optometry

these striæ are due to the formation of wrinkles in the cornea. A striate keratitis is most often seen after a cataract operation, the striations being perpendicular to the incision and passing with more or less divergence toward the center of the cornea, sometimes extending quite to the opposite edge.

Knies was the first to explain striate keratitis after cataract operation as due to wrinkling of the cornea. Hess has recently tried to prove that these striæ are wrinkles of Descemet's membrane. They usually disappear after two or three weeks, but cases have been reported where they remain permanent.

4. **Pressure Opacity.**—If the eye of an animal is seized and firmly pressed between the finger and thumb, the cornea becomes white and untransparent. This opacity due to pressure may be observed in the eye of man if attempt is made to make an incision in the cornea with a dull knife; the cornea becomes opaque about the point of the knife. Such an opacity is not due to any anatomical change, since the transparency returns immediately when the pressure is removed. It depends, rather, as Fleischl says, upon the difference in tension of individual fibers; those that are the most stretched become doubly refractive, this change from weaker to stronger refracting fibers impairing the transparency.

It might be supposed that a corneal opacity resulting from increase of internal tension, such as we see in glaucoma, might be explained in the same way, but investigations by Fuchs have shown that this is not the case. The very fact that a glaucomatous corneal opacity disappears quickly, but not instantaneously, negatives the similarity. Moreover, there has been detected as cause of this glaucomatous opacity an anatomical change, which Fuchs calls "edema of all the layers of the cornea;" the substantia propria has a relaxed appearance instead of its normal homogeneous density, the nerve channels are dilated, and below the epithelium are found droplets of fluid. This dull appearance of a glaucomatous cornea is due to these droplets. It is most prominent at the center of the cornea.

5. **Ribbon-like opacities** attack that portion of the cornea exposed beneath the palpebral fissure. As a rule this opacity begins in two places—at the temporal and at the nasal side of the cornea. Both opacities growing toward each other become united at the center of the cornea, and then form a broad band *3* to *5 mm.* wide, which gives the name to the disease. The opacity is of an even, light-gray color, the dots and striæ in it being detectible only by a lens. The surface of the cornea is usually dull and mottled. The disease attacks both eyes as a rule, and is developed very slowly without any signs of inflammation; visual disturbance is the only complaint the patient makes. It is supposed that a calcareous degeneration of anterior layers of the cornea is the essential characteristic of the disease. It usually attacks elderly persons whose eyes are otherwise sound, or others whose eyes have already suffered from glaucoma or iridocyclitis.

Treatment can do little. If there has been glaucoma, an iridectomy may be of service. In healthy eyes the attempt has been made to curette the superficial opacification.

6. **Cicatricial Opacity.**—All corneal injuries and ulcers penetrating Bowman's membrane and affecting the substantia propria, as well as many a keratitis without ulceration, in healing leave behind an opacity which is called either a leukoma or macula or

Digitized by Internet Archive of Optometry

nubecula. **Leukoma** is an opacity that reflects nearly all the light impinging upon it, and therefore appears to the observer as a white blotch. **Macula** is a less dense opacity which transmits a large part of the impinging light, and does not, therefore, appear white, but rather bluish-gray, and is generally only visible when the eye is so turned that the black pupil forms a background for this area. **Nubecula** is a transparent, extremely delicate opacity, which transmits nearly all the impinging light, and can therefore be detected only by optical aid (*p. 98*). Every grade of transition from leukoma to nubecula is, of course, possible.

Scars containing lead deposits are particularly white in appearance. Formerly, when lead applications were used for all sorts of inflammatory conditions, they were much more common than now. Whenever a corneal ulcer healed a deposit of lead was left behind; therefore lead solutions must be unconditionally avoided wherever there is an ulcer.

The patient asks the physician's advice, either because of the disfigurement produced by a leukoma, or because of a visual disturbance from an opacity, or, finally, because of an ulcer which is still left at the scar. Naturally enough, the patient does not always know the reason of his poor vision; he may not complain at all of weak-sightedness, but of short-sightedness, because he instinctively brings the book closer to the eyes in order to see the print under the greatest possible visual angle. *It is a good plan before every ophthalmoscopic examination, and after every test where visual acuity is found to be defective, accurately to examine the cornea with focal illumination.*

The degree of visual disturbance depends upon the position and nature of the opacity. An opacity near the edge of the pupil may not of itself affect vision at all, although the transparent portions of the cornea usually lose their regular curvature after the cure of a large marginal ulcer, especially if there has been perforation with adhesion of the iris; the result is an irregular astigmatism that must decidedly affect the visual acuity. Opacities lying altogether or in part in front of the pupil cause disturbances of various degree. A sharply defined, completely untransparent leukoma covering only part of the pupil would have no effect upon visual acuity, since there is still room at the sides of this leukoma for a sufficient number of luminous rays to reach the retina under normal refractive conditions. Unfortunately, there is no such leukoma; no leukoma is sufficiently sharply outlined, none is completely un-

Digitized by University of Toronto

transparent, and those transparent portions of the cornea lying next to it are always irregularly astigmatic; nevertheless, a tolerable visual acuity may remain in spite of a central leukoma. Blotches on the cornea are disturbing factors, too, since different parts of these blotches may be self-luminous and may flood the entire retina with a diffuse shimmer of light. The physician can form a general idea of the amount of visual disturbance when he uses the ophthalmoscope, the more indistinct the fundus appears to him, the worse must the outer world appear to the patient.

Treatment.—How can such a patient be benefited? Wecker proposed tattooing for the disfigurement. This is done by rapidly pricking the white corneal scar with a bundle of needles, after which a stick of India ink is rubbed over the perforated corneal area. The cornea is now washed off to see whether the black puncture points are close enough together to turn the white scar completely black. If this has not been done, the pricking and the India ink should be repeated, and the whole process continued until the desired result is reached. It is to be understood that the cornea has been anesthetized by cocain and that the needles, India ink, and the fingers are absolutely aseptic. In successful cases tattooing is said to have had a good influence on vision, since the semitransparent leukoma was made quite impenetrable to light.

There are numerous means for overcoming the visual disturbance. It must, first of all, be determined whether any opacity present is really due to a cicatrix, or whether it depends upon the remnants of some inflammatory infiltrate; in the latter case the eye is seen to be somewhat irritated, a condition very apt to be detected after a prolonged examination. By the presence of ciliary injection it is seen, moreover, that the clouded area shows fine irregularities, that the opacity is not very sharply outlined, but is gradually lost in healthy tissue, and finally—this is the most trustworthy sign—that there are still some blood-vessels running to the cloudy area. When there is even a suspicion of an inflammatory infiltrate, the attempt should be made to clear it up by continued massage with yellow ointment. It may be noticed that in very young children genuine scar-tissue can be made noticeably brighter after months or years of treatment, so that the scar resembles true corneal tissue very closely. If this last stage has been reached, the attempt should be made to improve vision by concave glasses. This is sometimes successful, even if there is no myopia, because a concave lens de-

Digitized by the Internet Archive for Ophthalmology

mands an effort of accommodation, and consequently, as the pupil contracts, some of the diffuse light is shut off. We have, finally, various operative procedures, such as iridectomy and the substitution of transparent cornea in the place of tissue partially or entirely opaque—*keratoplasty*. An optical iridectomy promises success only when some portion of the cornea is transparent, behind which an artificial pupil may be made. It is not always easy to determine this exactly, since delicate opacities cannot be easily detected against the comparatively bright background of the iris, but occasionally a good conclusion is reached by dilating the natural pupil and applying proper diaphragms, which may show what improvement to the visual acuity may be expected from an artificial pupil. If there is any choice, an iridectomy should be made downward and inward, because the visual axis passes through the cornea somewhat downward and inward from its center (*p. 84*).

In case there is a choice—this does not happen often, however—I prefer to place the artificial pupil above, because the upper lid may make this artificial pupil larger or smaller, according to circumstances. An optical iridectomy almost always turns out larger and more peripheral than the surgeon intended. Schoeler has therefore proposed to perform iridotomy in place of iridectomy. The pupil thus made is like a slit, which gives a much better visual acuity, especially in near vision, than does iridectomy. Whether this latter will be displaced by Schoeler's method is still a question.

The insertion of transparent cornea is as yet an operation of the future. No method has hitherto been devised by which opaque cornea can be replaced by transparent tissue. The operation itself is an easy one, and union takes place without any difficulty, but the transplanted cornea is not able to retain its transparency under its new conditions; it becomes opaque, and the purpose of the operation is turned to naught. V. Hippel has achieved success in corneal transplantation by making a section of the cornea with a trephine only down to Descemet's membrane, and in this excised area a corresponding bit of a rabbit's cornea was made to heal; Kuhnt also has had success in one case. It is evident, however, that even if the method of v. Hippel should become common property, it would be only a subdivision of genuine keratoplasty, the aim of which should be to excise the cornea in its entire thickness, and to replace it by living animal tissue.

I have been trying for some years to attain this end by suturing embryonic corneæ into place.

Digitized by Illinois College of Optometry

IV. PROTRUSIONS OF THE CORNEA.

1. **Staphyloma Corneæ** is a corneal scar which, with the adherent iris, bulges outward. It may be partial or total, according to whether the cornea, in part or as a whole, is changed into a protruding scar or cicatrix.

The cause of this condition has been already mentioned on *pp.* *225* and *226*. It need only be explained here how it happens that a corneal scar does not contract, as do others, but, on the contrary, protrudes more and more, until it resembles a growing tumor. The adhesion of the iris to the cicatrizing cornea produces traction on the ciliary body, that vascular and nervous part of the inner tunic of the eye by which the aqueous humor is secreted. Irritation of the ciliary body—so it is assumed—increases secretion; the internal pressure of the eye is thereby raised. This heightened tension pushes the scar forward with greater force; the ciliary body is thereby still more dragged upon, with the consequence of shutting up the circulus vitiosus.

The protrusion may come to a standstill, or it may continue to increase until the staphyloma ruptures, when the aqueous escapes and the staphyloma collapses. This improvement is, however, of only short duration. The perforation closes again, the space between lens and iris (the posterior chamber) again fills up, and the staphyloma soon assumes its abnormal size. This process may be repeated again and again, until finally the perforation becomes the entering gateway for germs which destroy the eye by suppuration (panophthalmitis).

Increased tension resulting from long-continued mechanical irritation of the ciliary body is an assumption but not an undisputed fact. This increased tension, in many a staphyloma at least, may be explained in a different way. If the staphyloma is a total one, the anterior chamber is completely obliterated, and the filtration angle, that physiological discharge pipe of the aqueous humor, is closed. Increased tension would be due, therefore, not to an increase in secretion but to a hindrance to the escape of the aqueous.

The diagnosis of a staphyloma is easy; in the partial form a spherical protrusion occupies a portion, and, as a rule, the lower portion, of the transparent cornea. The color of this untransparent area differs according to the thickness or thinness of the scar-tissue, and consequently the adherent iris is seen through it with more or less distinctness. The color of the scar-tissue itself is white or a dull yellow, that of the pigment of the iris is black; consequently,

Digitized by Illinois College of Optometry

a staphyloma may be either white or yellow, bluish-white or bluish-black. There may be a bit of red mixed with the other color, since blood-vessels from the conjunctiva may be drawn into the scar-tissue. A total staphyloma (*Fig. 91*) has usually a spherical, but occasionally an irregular shape. As a rule, the external edge of the cornea is not destroyed by the suppurative process; it remains comparatively transparent, so that the iris can be seen through it. When the tension becomes raised, this border between cornea and sclera is gradually destroyed.

A patient with a staphyloma is a great sufferer. Disfigurement is by no means his worst misfortune. This is of less consequence to him than the impairment of the visual acuity. Even a partial staphyloma, which leaves the pupil to a certain extent free, is accompanied by most pronounced "irregular astigmatism," which on its own account impairs the visual acuity. In a total staphyloma vision is quite out of the question; the eye can distinguish only light from darkness. If the other eye is uninjured, many a patient might tolerate this unfortunate condition, but he has no peace; at every movement of the lid and of the eyes the protruding knob is irritated by the edges of the lids, while it may, on its part, prevent them from closing at all. This all results in a painful condition of inflammation, and if the lids cannot close, the unprotected staphyloma may shrivel up or ulcerate. The deeper parts of the eye then become involved (secondary glaucoma), which will lead to the acute pain of ciliary neuralgia and to atrophy of the optic nerve.

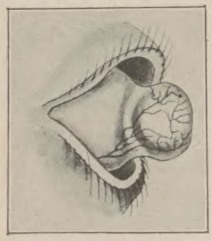

FIG. 91.—TOTAL STAPHYLOMA. (*After Sichel.*)

Treatment can be successful only when it is begun early enough, that is, at a time when the condition is that of a simple prolapsus of the iris. By abscission of this prolapse, by eserin, by rest, and a long-continued pressure bandage, it is sometimes possible to produce a flat and firm cicatrix, and in the end to keep the eye permanently at rest.

Abscission of a prolapsed iris cannot be well performed with a stroke of the scissors, since the prolapsed nodule is almost sure to escape from between their blades. The operation is much better performed with Graefe's Cataract Knife (*Fig. 126*) by piercing the base of the prolapsus at its center and cutting outward in the plane of the base. The two flaps thus exposed are then seized with toothed forceps and abscised completely with either knife or scissors.

Digitized by the University of Colorado Boulder Libraries

If this first stage is already passed, so that the iris has become incarcerated in the cicatrix, it is best to reduce the internal pressure by an iridectomy, and in this way to encourage the scar to flatten out. Of course, the iridectomy should be placed wherever an artificial pupil would seem to be most advantageous for vision. If the staphyloma increases in spite of the iridectomy and of long-continued bandaging, the staphyloma itself must be cut off. If the staphyloma is total, there will be left a rather large wound in which the lens is exposed, but since it is already opaque, it is best in any case to remove it at once. The gaping wound must be closed by two or three stitches, placing them either through the edges of the wound or through the conjunctiva after it has been freed from its adhesion to the eyeball, so that it can be drawn over the wound by these sutures. This operation does not attempt to restore any visual power, but only to form a suitable stump for a glass eye.

If keratoplasty is ever successful in the future, a new transparent cornea will, of course, be used in the place of the excised staphyloma.

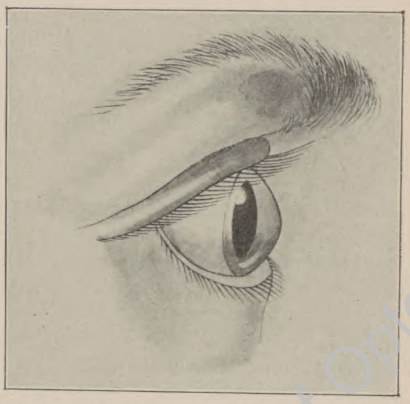

FIG. 92.—KERATOCONUS. (*After A. v. Graefe.*)

If the staphyloma is not to be treated until the eye is completely blind by heightened tension and optic nerve atrophy, enucleation must be considered, and the decision should not be long delayed if chronic inflammation of the staphylomatous eye threatens the remaining one with sympathetic inflammation.

2. **Keratoconus** (*Fig. 92*) is a protrusion of the cornea in the form of a blunt cone. The cornea is clear, the iris unaffected. The rounded point of the cone lies at about the middle of the cornea, and is only one-third as thick (*0.3 mm.*) as the normal corneal apex (*0.9 mm.*). The sides of the cone are somewhat thicker than the periphery of a normal cornea (*1.1 mm.*).

If the figure on a keratoscope (*p. 97*) is thrown upon the apex of a conical cornea, the image reflected from it is very small, but grows larger and larger as the reflection is made from the points lying further and further away from the apex toward the periphery.

Digitized by the Ohio College of Optometry

In this way v. Graefe was able to estimate in one case that the center of the cornea had the radius of curvature of a pea, while the edges of the cornea had the radius of curvature of a small potato. It is easy to see that such a cornea cannot throw distinct images upon the retina, consequently these patients have very poor vision: $V = \frac{1}{36}$, for example. Since objects lying toward the periphery are seen very indistinctly, the patient has great difficulty in finding his way in a strange place. The greatest complaint the patient has to make is that of multiple vision—*polyopia monocularis*—and irritation, which is probably due to the unavoidable dazzling.

To recognize a completely developed conical cornea it is only necessary to look at the patient from one side. The sugar-loaf appearance of the transparent protruding cornea (*Fig. 92*) explains the whole matter. At the beginning of the condition, however, a moderate protrusion may be easily overlooked, but a careful use of keratoscopy and of the ophthalmometer will prevent any error. In the last stage the diagnosis may be difficult, because the apex of the cone becomes cloudy at last and may simulate a healed ulcer.

The morphology of conical cornea is obscure. We know that it occurs in young persons between the fifteenth and twenty-fifth years without any evidence of inflammation, that its advance is extremely slow, although it may quite suddenly spring into activity, that the development may come to a standstill in any stage, and that perforation does not occur even in the most pronounced type. It is supposed that the cause is an undue thinness of the apex of the cornea. Whether the apex of the cornea was too thin from birth, and why the anterior chamber yields to the internal pressure only in later youth, are still unanswered questions. His tried to solve this problem. He scratched off the endothelium at the apex of a guinea-pig's cornea, and found that the posterior layers of the cornea grew cloudy, and that the corneal apex protruded at the same time. The cloudiness disappeared, but the protrusion remained. It is probable that in man some disease of the endothelium has undermined the resistive power of the apex of the cornea.

Treatment.—Vision may sometimes be improved by very strong concave lenses, because the greatest optical effect is produced at the apex of the cornea. The hyperbolic glasses devised by Raehlmann are of still greater service; rays which pass through the center of such a glass diverge rapidly, while those passing through the periphery diverge slowly, and they therefore neutralize the uneven convergence of the rays produced by the different sections of the cornea. The great disadvantage is that such a hyperbolic glass must be exactly centered with the hyperbolic cornea, but as soon as a patient turns his eye behind the glass the least trifle to one side, the neutralizing effect ceases, and his condition is worse than be-

Digitized by Illinois College of Optometry

fore. It would still seem, therefore, that the best results are reached by an operation, destroying the apex of the cone by the knife or the cautery, and leaving in its place a more resistive scar. It must be confessed that such a scar is untransparent, and that a high price has been paid for the flattening of the entire cornea thus obtained, and the operation must, therefore, be supplemented by an optical iridectomy.

I have proposed to treat conical cornea with a "contact glass," that is, with a glass ground so as to have the form of the normal anterior segment of the eye, this glass to be laid directly upon the affected eye, the space between glass and cornea being filled with some aseptic fluid of the same refractive index as that of the cornea. If this were done, the influence of the conical cornea upon the path of the luminous rays would be destroyed. Unfortunately, I have found no case exactly suited for the application of such a contact glass, but the improved visual acuity in proper cases of irregular corneal astigmatism has been surprising.

Keratoglobus is the name given to a second kind of protrusion of a transparent cornea. I have seen two cases of this unusual condition which resembled each other very much. In the first case I noted the following characteristics: Both corneæ and irides appeared decidedly enlarged; a measurement of the horizontal diameter of the cornea was easily made, since the cornea was sharply outlined from the sclera; in the right eye this was about *15 mm.*, in the left eye a trifle smaller. Both corneæ were absolutely clear. The anterior chamber in each eye was very deep, perhaps about *8* to *10 mm.* If the eye was looked at from the temporal side, it gave the impression of a glass hemisphere laid with its surface upon the iris and protruding nearly to the front of the cornea or to its apex, but at the periphery not approaching quite so closely. The iris was quite smooth and lay somewhat behind the plane of the sclero-corneal border; it trembled when the eye was moved. The eyes were hyperopic, visual acuity, fundus, and tension being normal; the patient denied any possibility of earlier disease (glaucoma). Both cases confirmed the view of Horner, W. v. Muralt, and L. Pflueger, that keratoglobus is an anomaly having nothing in common with infantile glaucoma (*q. v.*).

Keratektasia is the name given to a protrusion of an opaque, that is, cicatrized, cornea. It has this in common with keratoconus and keratoglobus that the iris remains unaffected; keratektasia is the result of a corneal ulcer which has not ended in perforation but rather in a thinning of the cornea; or it is the result of pannus and other "non-suppurative" corneal diseases.

Tumors arising in the cornea itself are extraordinarily infrequent. New growths which arise at the limbus conjunctivæ and attack the cornea afterward are comparatively common; they are discussed on *p. 218*.

Digitized by Illinois College of Optometry

DISEASES OF THE SCLERA.

1. INFLAMMATIONS.

Episcleritis.—Inflammations of the sclera are usually secondary to those of the cornea or ciliary body. They are of small importance compared to the principal disease. Idiopathic inflammation of the sclera is rare. It is a localized disease evidenced by a flattish nodule about the size of a lentil lying *3* to *4 mm.* from the edge of the cornea. Its color is yellowish-red at the center, bluish-red at and around the edge. Examined carefully with a good lens, the conjunctival cover of this nodule appears of a light red color. If the conjunctival blood-vessels are kept empty by gentle pressure by the finger, the bluish-red scleral vessels are seen more clearly. If now these latter vessels are kept empty by a somewhat stronger pressure, it is seen that the nodule is made up of minute vesicles of a yellowish color. This pressure causes moderate pain. The condition may last some weeks with only a few symptoms; the inflammatory redness then gradually fades away, the nodule flattens out and finally disappears, leaving a slate-gray discoloration. But the disease has by no means run its course; after a longer or shorter interval—weeks, months, or years—a new nodule is formed near the site of the earlier one, and this leaves in its turn another slate-gray blotch. So it goes on, until after years the entire strip of sclera between the edge of the cornea and the insertions of the tendons of the four recti muscles is occupied by blotches; hence the name *episcleritis migrans*. Occasionally the disease is not restricted to the sclera, but attacks the cornea also. The condition is then that of keratitis scleroticans, described on *p. 246*. In other cases the disease passes inward, attacks the ciliary body and the anterior part of the choroid, and is then called *sclero-choroiditis anterior* (*p. 290*). It is by no means certain, however, whether this last form arises originally in the sclera or in the choroid or ciliary body.

The diagnosis of episcleritis is easy if any adjacent slate-gray blotches aid in explaining the nodule present at the time. If this is not the case, it may be confused with a conjunctival phlyctenule. To avoid this, it must be remembered that a phlyctenule is a vesicle of the conjunctiva filled with cellular debris, and that therefore its center cannot be covered with the network of vessels which is seen over the episcleritic nodule. If a phlyctenule has changed to a

Digitized by University of Illinois at Chicago

shallow ulcer the diagnosis is very easy, since this cannot happen in episcleritis; the nodule is surrounded with a bluish-red area of inflammation, while in a phlyctenule the side turned toward the cornea is comparatively free from blood-vessels. In doubtful cases the further course of the disease will settle the question—a phlyctenule lasts but a short time, episcleritis a long time.

The nature of the disease is obscure; it is supposed that it results from some general dyscrasia, probably from gout, rheumatism, syphilis, or tuberculosis. In any case of episcleritis, therefore, these four diseases must always be searched for and the treatment directed accordingly.

The diagnosis is favorable, since the disease causes few symptoms and little injury to the eye, however long it may last; the disfigurement of the grayish blotches is of no significance.

Treatment must be general. If gout is detected, dietetic rules must be enforced. If the joints are swollen, salicylate of lithia or soda may be helpful. In syphilis and tuberculosis the well-known rules of treatment are to be applied. If no one of these four diseases can be detected, an impressive diaphoresis may at least be tried; in local treatment all stimulants must be avoided; only in a very chronic condition may a careful trial of massage with yellow ointment be made. In a fresh attack moist heat and a pressure bandage will accomplish as much as anything. The two may be happily combined by applying every night a moist and warm bandage beneath gutta percha paper. Atropin is indicated only when the choroid is involved (sclero-choroiditis anterior). If the presumption is warranted that the nodule is tubercular, the conjunctiva may be incised, the granular tissue curetted, and iodoform applied.

2. PROTRUSIONS.

Ectasia.—The shape of the eyeball may be changed in many ways, and the sclera must necessarily partake of the alteration, but the stretching of the sclera in infantile glaucoma and myopia, or its collapse in phthisis bulbi, are not really diseases of the sclera, since the rôle it plays in such changes is merely subordinate. Strictly speaking, the same is true of any ectasiæ of the sclera, since they are but consequences of some disease of the middle coat of the eye, the uvea. Nevertheless, they deserve mention here, since scleral changes, in certain stages of the disease, at least, are those most remarked by the observer.

Digitized by Illinois College of Optometry

Ectasia of a portion of the sclera is situated usually near the cornea, less often at the equator. The protruding sclera is thinned, the black uveal pigment is seen through it, and gives to the protrusion a bluish-gray or dark brown, or even a black color.[1] The thinness of the protruded sclera is characteristic of ectasia; it may be detected by the probe, since its wall yields to the pressure of the end of the probe, but springs back into its old place again as soon as the probe is removed. If the protrusion is due to any new growth, such as a melanosarcoma of the choroid, the pressure of the sound will reveal a firm, unyielding body beneath. Transillumination is another test which may be used for the same purpose; if light from the ophthalmoscope is reflected through the dilated pupil toward the ectasia, the thinned area of the sclera will be seen to become luminous. If the test is made impracticable by some corneal scar or by a contracted pupil, the area on the sclera opposite to the ectasia may be illuminated as intensely as possible by a convex lens; the thinned sclera will then transmit some of the light which has penetrated to the interior of the eye. Such tests must, of course, be performed in the dark room. The result is negative if the protrusion is due to a tumor.

FIG. 93.—ECTASIA CILIARIS. (*After Pagenstecher and Genth*.)

The entire ciliary region bulges forward, particularly at the outer (temporal) side. The ciliary body is therefore decidedly elongated. There have been retinal hemorrhages at the back of the eye.

An ectasia is named, according to its location, *intercalata*, *ciliaris* (*Fig. 93*), or *equatorialis*. The two latter terms explain themselves. Ectasia intercalata implies a protrusion in the region of the ligamentum pectinatum, that is, in the tissue intercalated [2]

[1] For this reason ectasiæ of the sclera are also called "staphylomata." The term staphyloma is, as Sæmisch long ago lamented, used in ophthalmology for many conditions that have no genuine relationship to each other. A "corneal staphyloma" is a protruded corneal cicatrix subsequent to perforation and prolapse of the iris; "anterior scleral staphyloma" is a protrusion of thinned sclera; "staphyloma posticum" is an aperture in the choroid, through which exposed sclera is visible with the ophthalmoscope. It is advisable, therefore, especially in protrusions of anterior portions of the sclera, to replace staphyloma by ectasia. This indicates at once that ectasia corneæ and ectasia sclerae are related conditions, and are both protrusions of a thinned but not perforated external coat of the eyeball.

[2] Schiess-Gemuseus, who first used the expression "intercalary staphyloma," implied by it a protrusion effected through the tissue, "intercalated" between the outer and inner coats of the eyeball. The term is now used in the sense given above.

Digitized by Google

between iris and ciliary body. Ectasia intercalata may be multiple, in which case there is a row of them encircling the cornea parallel to its edge, having somewhat the appearance of the colon in the intestines—ectasia intercalata annularis.

Treatment has less to do with the ectasia itself than with the causative disease of the choroid, or with the condition producing the increase in tension.

3. WOUNDS.

Wounds of the sclera, without involvement and prolapse of the iris, choroid, and vitreous, are scarcely possible. The scleral wound becomes therefore subordinate, in proportion to the accompanying injuries to the eyeball (see the section on "Injuries of the Eyeball"). If a recent wound of the sclera without injury to deeper parts should happen to present itself for treatment, the prognosis may be given as favorable, since the sclera shows little tendency to resent an injury or to become inflamed. Healing is usually prompt and complete.

Treatment is that of wounds in general: disinfection, closure of the wound, bandage. If the edges of the wound are well approximated, nothing more is necessary. If the wound gapes, a conjunctival or perhaps a scleral suture must be taken.

4. NEW GROWTHS.

Tumors of the sclera arise very rarely from that tissue itself; they are mostly tumors of the limbus of the conjunctiva (*p. 218*) or of the deeper tissue, which have involved the sclera later in their growth. Calcification of the sclera is not unusual in the eyes of old persons or in atrophic eyes.

DISEASES OF THE MIDDLE TUNIC OF THE EYE

(Tunica media, Tunica uvea).

1. ANATOMICAL INTRODUCTION.

The middle tunic of the eye is not a completely enveloping membrane. Anteriorly there is an aperture, the pupil, through which luminous rays enter, and posteriorly another opening for the optic nerve. This tunic is divided into three parts:—

(*1*) *The iris.*

(*2*) *The ciliary body*, and

(*3*) *The choroid.*

Iris.—With a good lens it may be seen that the anterior surface of the iris is by no means flat. Rather is it a "relief" of mountain, valley, ravine, and crevasse. The most prominent formation is a circular eminence about *1 mm.* from the pupil; this indicates

Digitized by Illinois College of Optometry

the *circulus arteriosus iridis minor*. The minute strand between the small circle and the pupil is called the pupillary portion, the entire remainder the ciliary portion. At the pupillary edge there is a brown or black band of pigment, which, when the pupil is contracted, lies in folds like the ruff of a shirt, but when the pupil is dilated almost entirely disappears; this band belongs to the most posterior, black-pigmented layer of the iris (*Fig. 94*) and is called "pars iridica retinæ," because it belongs morphologically to the retina. Outward from the small circle the iris passes in a double curve toward the ciliary edge. In the peripheral portion of the iris there are to be seen circular depressions concentric to the pupil; these are the folds into which the iris is drawn when the pupil becomes dilated. The iris appears to be somewhat smaller on the nasal than on the temporal side; in other words, the pupil is eccentric. Its size varies noticeably, owing to

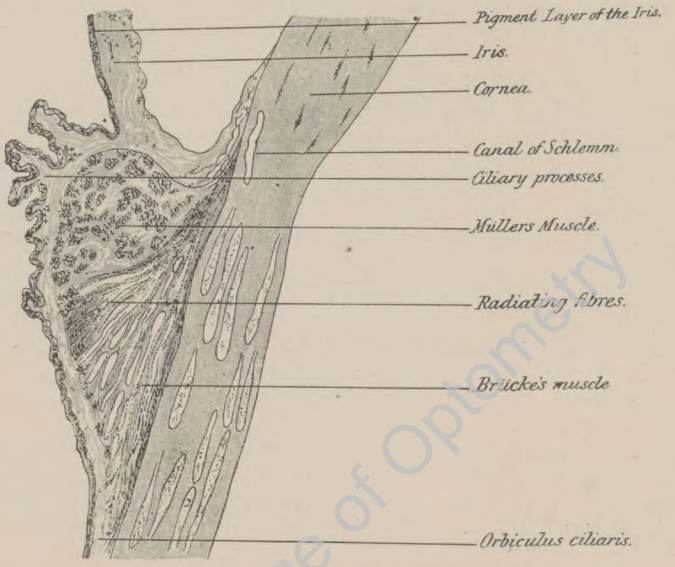

FIG. 94.—CILIARY BODY OF A HYPEROPIC EYE. (*After Iwanoff.*)

the action of two unstriated muscles, one being known as the *sphincter pupillæ* supplied by the oculomotor nerve, the other the *dilatator pupillæ*, supplied by the sympathetic.

The *sphincter* is a muscle about *1 mm.* broad and *0.1 to 0.25 mm.* thick (*Fig. 4, p. 27*). It lies close to the pupil and at the posterior surface of the iris. The *dilatator* is a single layer of unstriated muscular fibers arising from the sphincter to pass spoke-like to the ciliary edge; the fibers are close to the pigment-layer of the iris. The muscular nature of these fibers has been hitherto disputed—improperly, I think, for in the cadaver, where the sphincter is paralyzed, and where a purely elastic dilatator would be as active after as before death, the pupil is of only moderate width, about *4 mm.* in diameter; while in the living body we can, by paralyzing the sphincter with atropin and simultaneously stimulating the dilatator with cocain, produce a pupil having a diameter of *9 to 10 mm.*

Apart from the double layer of pigment (*Fig. 94*) at the back of the iris and sphincter there is no other stratified formation of the iris discoverable. It is somewhat schematic,

Digitized by the College of Optometry

therefore, to speak of a "vascular layer." The vessels are very numerous, radiate, and are provided with extraordinarily thick walls, obviously intended to prevent them from losing their lumen when stretched by the tension of the iris The iris is luxuriously supplied with nerves also, which arise from the same mixed ciliary nerves that give to the cornea its exquisite sensitiveness. But while the trigeminous fibers play the most important part, if not the only role, in the cornea, the iris depends upon fibers from trigeminus, ocolomotor, and sympathetic: this explains the presence of the ganglia in the iris and choroid, although these are of microscopic smallness. The stroma of the iris is a fibrillary connective tissue having anteriorly a loose envelope of endothelial cells. In the more anterior layers there are numerous star-shaped pigment-cells, the amount of which decides the color of the iris, or, as the laity say, "the color of the eye." Blue irides have no pigment cells, the blue color being but an interference phenomenon due to the pigment deposit at the back.

The **ciliary body** consists of the *ciliary processes* and *ciliary muscle*. Examined by the microscope, it is seen that the muscle is composed of unstriated muscle-fibers that run in three different directions (*Fig. 94*). The external group arises from the inner wall of the canal of Schlemm and passes backward in the direction of a principal meridian to be inserted in the choroid. This is called Bruecke's muscle, or the "tensor choroideæ." A second group arises in the same place, but passes rather toward the center of the eye, the so-called radial fibers. The third group has a circular course around the eye, and is called Mueller's muscle (seen in *Fig. 94* in transverse section).

The *ciliary processes* (*Fig. 94*) consist principally of blood-vessels, but there are a few connective-tissue fibers and pigment-cells. Their posterior surface is covered by a vitreous membrane of a double layer of epithelial cells, one of which, directly against the processes, is richly pigmented, and is a continuation of the pigment epithelium of the retina; the second and inner layer (inner referring to the direction within the eye) consists of cylindrical cells lacking pigment. Both layers are, on morphological grounds, called *pars ciliaris retinæ*.

The **choroid** is a membrane from *0.08 to 0.16 mm.* thick, composed chiefly of blood-vessels. In transverse section there is seen between the vessels a faint stroma of elastic fibers, with numerous star-shaped pigment-cells. These vessels are arranged in groups, the larger ones externally, next a layer medium-sized, and internally is the chorio-capillaris, a dense network of minute vessels, which is closer woven the nearer it approaches the area of acutest vision in the subjacent retina. The chorio-capillaris is, therefore, absent behind the ciliary processes—the so-called *orbiculus ciliaris*. The inner surface of the choroid is covered by a transparent membrane of extraordinary thinness. The outer surface is covered by loose, reduplicated tissue, composed of endothelial cells and called *lamina suprachorioidea*.

The **blood-vessels in the uveal tract** (*Fig. 95*).—In the human body an artery is usually accompanied by two veins, within which the blood from that artery flows back to the heart. The circulation in the eye is arranged in quite a different manner. We find here two distinct arterial territories, an anterior and a posterior, and the blood from them is carried off in a venous system lying between. The posterior arterial stream flows through the *arteriæ ciliares posticæ breves*, about 20 small arterioles penetrating the sclera near the posterior pole of the eyeball, to merge at once into the capillary network of the choroid. The anterior arterial stream flows through *two arteriæ ciliares posticæ longæ* and *seven arteriæ ciliares anticæ*. The two long posterior arteries penetrate the sclera at the posterior pole, and pass forward, without subdividing, to the nasal and temporal side of the eye, between sclera and choroid, where each sends a descending and an ascending branch to the ciliary body; the two ascending branches on the one side, and

the two descending branches on the other, meet to become united in the *circulos arteriosus iridis major*. The seven anterior ciliary arteries that arise from the muscular arteries of the orbit, and pierce the external coat of the eye near the sclero-corneal margin, pour their contents into the same arterial circle. From this circle arise numerous arteries supplying iris and ciliary body. When the blood has here become venous, it is collected into the small veins that pass backward – toward four to six points at the equator, where, united into one large vessel, they abruptly pierce the sclera posteriorly. Toward these same points at the equator pass the veins that have received the blood from the choroidal capillaries—that is, the posterior arterial stream. This venous current forms a kind of whirlpool, so that the four, five, or six collecting veins have been called the *venæ vorti-*

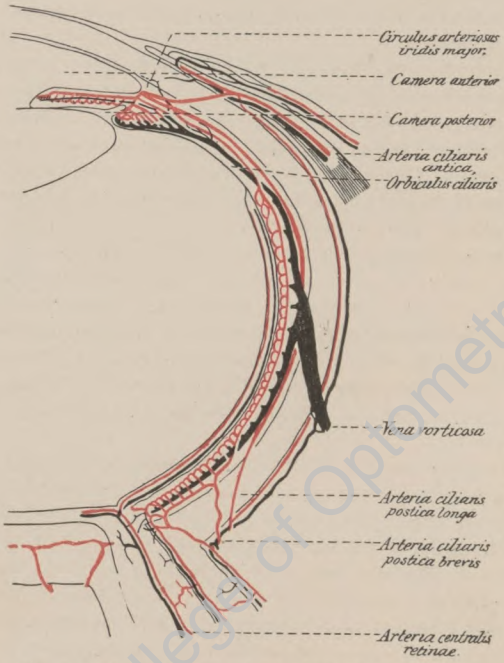

FIG. 95.—BLOOD-VESSELS OF THE EYE. (*After Leber.*)
Arteries, red; veins, black.

cosæ. However, that the principle of the circulation may not be contradicted, a small quantity of blood escapes from the eyeball through the *venæ ciliares anticæ et posticæ*, which take a course parallel to the arteries of the same name. The anterior veins are, in the living body, visible through the ocular conjunctiva, particularly after the disease to be described later on as chronic inflammatory glaucoma. The general principle of the circulation is still further preserved, in that the anterior and posterior arterial streams form an anastomosis through the minute vessels in the orbiculus ciliaris.

2. PHYSIOLOGICAL INTRODUCTION.

These three subdivisions of the uveal tract have different functions, as might be supposed from the difference in their structure; these functions being analogous, however,

Digitized by Illinois College of Optometry

as might be supposed from their common richness in pigment and blood-vessels. All optical instruments—the microscope, telescope, etc.,—are blackened inside so as to absorb any stray rays of light and to nullify their effect. The eye also is blackened by the pigment of the uvea. The richness in blood-vessels enables the uvea to secrete a thin, fluid lymph. The eye has not distinct lymph vessels, but there are lymph spaces, the fluid in which courses in two different directions. Within the eye the anterior and posterior chambers (*Fig. 95*) form one space, while the "canalis Cloqueti," or the "central canal of the vitreous," forms the second. Since the fluid contents of these lymph spaces has only a trace of albumin, and therefore cannot be a simple transudate from the uveal vessels, we must consider this fluid an evidence of lymph-secreting cells, and we assume that the pars ciliaris retinæ, particularly the unpigmented cells on the back of the ciliary body, plays the part of such a glandular structure. This much is certain, and can be demonstrated by injecting fluorescin into the circulation of a rabbit, that there is a current from the posterior chamber through the pupil into the anterior chamber. This current passes from the pupil toward the circumference of the anterior chamber (the filtration angle) and escapes through the network there into the canal of Schlemm and the anterior ciliary veins. It is possible that some fluid from the anterior chamber is sucked up by the sponge-like tissue of the iris, to be carried off through the ciliary body and the vorticose veins. The fluid in the central canal of the vitreous probably originates in the same way from the cylindrical cells of the ciliary body, and it flows backward, leaves the eye by the side of the optic nerve, and continues its course in the lymph fissures between the sheaths of the nerve.

The iris has a special, optical task—the regulation of the amount of light entering the eye. A luminous point will obviously send the more light to the retina—circumstances being otherwise the same—the larger the pupil is. Since, with a wide pupil, bright objects would produce retinal images whose intensity would be injurious to the retina, the nervous mechanism is so adjusted that *the pupil contracts when the quantity of impinging light is great, and dilates when this quantity is small.* If the contraction was excessive, the pupil dilates a bit immediately afterward, and it may thus fluctuate with alternate contraction and dilatation until its size is exactly proportionate to the amount of illumination.

Sharp retinal images will be formed only of such objects as send luminous rays to the cornea under a small angle of entrance. If the pupil is of medium width, this condition, for objects at infinity, is fulfilled by the iris, which shuts off peripheral rays striking the cornea under a large angle; but if the object lies within a few decimeters of the eye, some of the diverging rays strike a portion of the cornea not yet cut out by the iris, at a large angle of entrance. The result would be an indistinct retinal image, if it were not that the nervous mechanism is so arranged that *a contraction of the pupil takes place when a near object is looked at;* by this means all but the small central portion of the cornea is cut out, and through this area luminous rays pass nearly perpendicularly, in spite of the proximity of the object. Moreover, the contraction of the pupil is not accomplished directly by near fixation alone, but stands in intimate relation to accommodation and convergence. If the accommodation is made unnecessary by proper lenses, and the convergence equally so by prisms, the pupil does not contract, in spite of near fixation.

Contraction of the pupil by light, accommodation, and convergence occurs simultaneously in both eyes, even if one eye is excluded from vision by being covered. Inequality of the pupils—*anisokoria*—is, therefore, without exception, pathological. Besides light, accommodation, and convergence, other conditions have their influence on the width of the pupil. A congestion of blood in the iritic vessels causes contraction of the pupil, as, for example, the systolic wave, and the increase of blood pressure in expiration; while

Digitized by the Internet Archive of Optometry

strong irritation of some sensitive nerves and severe muscular exercise cause dilatation. Purely psychical forces have their effect, such as, for example, the contraction of the pupil—Haab's reflex—caused when attention is directed to some object at the side while the eye itself does not change its position.

Mydriatic and myotic drugs are of great importance in ophthalmology, since their effect may be produced by local application as well as by introduction into the circu a-tion. These remedies are used as solutions, salves, or in the dry form, for application to the conjunctiva. The drug is diffused through the cornea into the anterior chamber, and acts either directly on the muscles of the iris or on the nerve endings in them.

Mydriatics.—Those most used to dilate the pupil are: Sulfate of *atropin*, hydro-bromate of *homatropin*, and muriate of *cocain*. Atropin and homatropin paralyze the sphincter of the pupil and stimulate the dilatator at the same time. This last is taken for granted, because a dilated pupil subsequent to oculomotor paralysis can be still further dilated by atropin. Cocain affects the dilatator chiefly, stimulating it; this is assumed from the fact that a pupil dilated by cocain is still subject to contraction when influenced by light, accommodation, and convergence; the sphincter cannot possibly, therefore, be paralyzed as it is by atropin.

Mydriatics act on the muscle of accommodation (musculus ciliaris) besides affecting the size of the pupil. *Atropin* paralyzes it completely, and leaves the eye adjusted for its far point only; *homatropin* paralyzes it incompletely, while *cocain* but moderately de-presses its function. The effect of the strongest mydriatic, atropin, lasts the longest, about eight days; that of homatropin about a day, and that of cocain only a few hours. Of course, the amount of the drug used must be considered. Other effects of mydriatics have already been mentioned on *p. 226*, and still others will be discussed under "Glau-coma." It may be merely stated here that cocain stimulates the end fibers of the sympathetic, and produces thereby a contraction of the unstriated levator (*Fig. 57*) with the accompanying widening of the palpebral fissure.

Miotics.—*Eserin* sulfate or salicylate, and *pilocarpin* muriate are those most used. Both stimulate the sphincter pupillæ to a powerful tonic contraction, the result being to reduce the pupil to the size of a pinhead. It is, however, not rigid but mobile, although to a very limited degree. The ciliary muscle is stimulated to a spasmodic contraction, and the eye is therefore adjusted for the near point only. After very small doses of the drug, and after the spasmodic action has passed off, the ciliary muscle is strengthened, a condition that may be proved by the increased range of accommodation. The spasmodic muscular contractions make themselves felt in the eye as twitchings or "painful jerk-ings." In sensitive persons there are occasional fibrillary twitchings in the musculus or-bicularis palpebrarum, which are felt by the patient and seen through the skin. The effect of eserin on the iris may lead to a true iritis; the use of the milder pilocarpin is not accompanied by this danger. For the effect of myotics on the internal tension, see "Treatment of Glaucoma."

In addition to the mydriatics and myotics already mentioned there are other similarly acting drugs any of which may be at times used in place of the customary ones. *Mor-phin*, *muscarin*, and *nicotin* are myotics; *scopalamin*, *hyoscyamin* (the same as *duboisin*) and *gelsemin* are mydriatics. Dilatation of the pupil is caused by certain ptomains that develop in rotting meat and may reach the blood through the stomach.

The physician, when using a mydriatic or a myotic, should never for an instant forget that these drugs are powerful poisons; that fluid may escape through the lacrimal pas-sages to act on the nose and throat; that many persons are particularly sensitive to them; and that intoxication or poisoning has been the result, most commonly from atropin. The symptoms are tickling and dryness in the throat, vomiting, diarrhea, redness of the

Digitized by Google

face, quick and irregular pulse. Death itself has been caused by "eye-drops." All danger may be easily avoided, no matter how often the drug is applied, by directing the patient always to press the finger firmly against the lacrimal sac for ten minutes after dropping the medicine into his eye. If minute doses are used such precautions may be omitted.

A. DISEASES OF THE IRIS.

1. HYPEREMIA.

Hyperemia of the iris is not, strictly speaking, a disease, but merely a token of disease, which may accompany a large number of inflammations of the eye. It is necessary to describe it by itself, however, since to reach a correct prognosis a sharp distinction must be made between hyperemia and inflammation of the iris. Hyperemia is recognized by three objective signs:—

(*1*) *Narrowing of the pupil*—explainable, perhaps, mechanically by the increased volume of blood in the vessels of the iris. The pupil can be narrowed in this way, as may be easily demonstrated by injecting fluid into the vessels of the iris of an eye of a corpse.[1]

(*2*) *Discoloration*, recognized by the mixture of red with the predominant color of the individual iris; for example, a brown iris when hyperemic becomes reddish; a blue iris, greenish; a gray-blue iris, greenish-yellow.

(*3*) *Sluggish reaction to atropin*, the pupil becoming only moderately dilated by that drug, and this half mydriasis disappearing much more rapidly than under normal circumstances. In hyperemia there is, moreover, ciliary injection, photophobia, and lacrimation. Hyperemia of the iris accompanies all severe inflammations of the conjunctiva, such as acute trachoma, blennorrhea, diphtheria; all severe irritations to the cornea, such as that from a foreign body or ulcer; and all inflammations of the ciliary body and choroid.

2. INFLAMMATIONS.

If the hyperemia becomes so pronounced that an exudate is formed, there is a genuine inflammation—an iritis. Four kinds of iritis are distinguished, according to the nature and the location of this exudate.

---

[1] The mere removal of the fluid pressure upon the iris well suffices to contract the pupil. This may be done on the cadaver by allowing the aqueous to escape, while dilatation may be produced by injecting fluid into the anterior chamber. How these effects are produced is not quite clear, nor are authors in harmony on this point.

Digitized by Illinois College of Optometry

(*a*) An extremely scant, fibrinous exudate is deposited upon the anterior or posterior surface of the iris, the pigment layer at the edge of the pupil becoming thereby adherent in places to the capsule of the lens—synechia posterior. This form of iritis is called *simple* or *plastic iritis.*

(*b*) An inflammatory product, poor in cells, settles into the anterior chamber to mix with the aqueous and to be deposited upon the posterior surface of the cornea. This form is called *serous iritis.*

(*c*) An inflammatory product rich in pus cells saturates the tissues of the iris, and its overflow settles into the anterior chamber as a hypopyon. This form is called *purulent iritis.*

(*d*) Finally, it may happen that some cells adhere to isolated points, to grow into nodules by means of a delicate connecting substance. This form may therefore be spoken of as *nodular iritis.*

Of course, every case cannot be made to fit into this category. Intermediate forms are not uncommon. Many a case begins as a serous iritis and changes during the course of weeks into a plastic iritis. Again, in a pronounced plastic iritis, deposits upon the back of the cornea are by no means unusual, nor should it be forgotten that posterior synechia, the diagnostic sign of plastic iritis, may accompany every form of the inflammation.

(*a*) **Iritis Simplex** seu **Plastica.**—The patient complains of pain, photophobia, lacrimation, and dimness of vision. The pain, the same ciliary neuralgia mentioned under diseases of the cornea, radiates from the eye to forehead and temple, even to the upper jaw and nose, and is particularly distressing at night. Pain is not always proportionate to the severity of the disease, the lacrimation and photophobia being in this respect much more trustworthy guides. Many patients have no symptoms, and consult a physician merely because the eye is clouded. In looking at an affected eye there is noticed :—

(*1*) *Pericorneal injection*, in which the red color due to the blood increases in intensity according to the severity of the inflammation ; the extent of this redness likewise differs accordingly.

(*2*) *A loss of the velvety blackness of the pupil ;* this is the result of a moderate haziness of the aqueous, and may be distinguished from corneal opacity by focal illumination (*p. 98*).

(*3*) *A loss of smoothness and polish in the iris*, which is discolored, and its "relief" is not so easily recognized. This is the result of a delicate fibrinous exudate upon the back of the iris.

Digitized by Illinois College of Optometry

(*4*) *A contracted, immovable, unsymmetrical pupil.* The posterior synechiæ protrude into the pupillary area as small, brown dotlets. This condition is detectable only by means of focal illumination and a lens or by the use of atropin. If such an eye is strongly atropinized, the edge of the iris lags behind at the points of adhesion, and forms somewhat horseshoe-like protrusions (*Fig. 96*). Atropin is, therefore, an indispensable aid to the diagnosis of iritis. Unfortunately, its use is often neglected, and many a case of iritis falls into the ophthalmologist's hands only after it has been mistreated as a conjunctivitis, with zinc solution or something similar.

(*5*) *Hyperemia of the optic nerve* is said to accompany iritis almost without exception. I am free to doubt, however, whether this can always be seen through the opacities in the pupil.

Course and Consequences.—An acute iritis may run its course in two to four weeks, even without treatment, and yet leave no par-

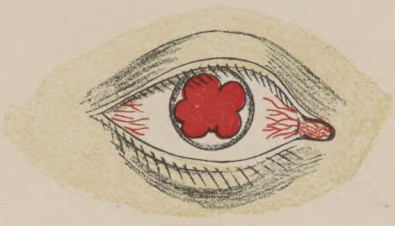

FIG. 96.—POSTERIOR SYNECHIÆ, BY TRANSILLUMINATION, AFTER ATROPIN. (*After Jaeger.*)

ticular disturbance in its trail. The exudate becomes absorbed; the adhesions are broken up by the ceaseless activity of the play of the pupil. Only the ophthalmologist is able, by means of focal illumination and the lens, to detect dotlets of pigment upon the anterior lens capsule,—the unabsorbed remnants of the adhesions.[1]

Such a favorable course must be an exception in untreated cases. It is rather the rule that adhesions of the iris to the capsule of the lens become permanent by the change of the exudate into connective tissue; this new-formed connective tissue looks—with focal illumination—grayish-white. Such a permanent adhesion is, of itself,

[1] Schubert has called attention to the fact that in about every fifth blue eye, and in every second brown eye, however healthy, a kind of pigment dust may be detected on the anterior lens surface; but this has nothing in common with pathological deposits of pigment.

Digitized by the College of Optometry

no great misfortune, as the visual acuity need not be especially impaired thereby; but it must be remembered that the iris is extraordinarily inclined to relapses, and that adhesions but increase this tendency. The greatest danger to vision lies in the circumstance that the entire pupil may be filled with exudate during a severe inflammation, that this exudate may become organized into a connective-tissue membrane, and that vision is necessarily reduced thereby to the mere perception of light—a condition called occlusion of the pupil.

This is by no means the worst that can happen. An occluded pupil need cause no further disturbance, for the eye may remain in this condition for years, and even then a useful visual acuity may be restored by an iridectomy. But matters change when—with or

FIG. 97.—CIRCULAR SYNECHIA WITH OCCLUSION OF THE PUPIL. (*After Pagenstecher and Genth.*)

without occlusion of the pupil—repeated relapses result in forming a circular adhesion between lens and iris (*Fig. 97*). Now, the aqueous accumulating in the posterior chamber has no way of escaping into the anterior chamber. The iris bulges forward, the eye's tension increases, and if an artificial pupil is not at once produced so as to reestablish the connection between posterior and anterior chambers, the eye will be hopelessly lost from the resulting increase of pressure within it. The most important element in the treatment of iritis must therefore be the effort to prevent or to overcome, as far as possible, these adhesions between iris and lens.

General Causes.—These may be separated into *idiopathic* (primary) and *consecutive* (secondary). A secondary iritis results as a consequence of severe inflammations of the cornea, sclera, ciliary body, or choroid; even a blennorrhea, that is, a conjunctival

Digitized by Illinois College of Optometry

inflammation, may lead to an iritis. An iritis from an injury (*iritis traumatica*) is probably due to both idiopathic and consecutive conditions. Of itself, a cut, a laceration, or even a bruise need not cause an iritis; but if the injury is made with unclean instruments, or if the conjunctival sac was not at the time quite free from bacteria, the result will be an iritis, although it need not be of a threatening character. From purely chemical causes, too, from irritation by swollen lens substance, or by an oxidizing bit of metal, for example, there may be an iritis produced.

An idiopathic iritis, where the iris alone is involved, is probably always the result or the manifestation of some general dyscrasia.[1] In the first rank as a cause stands syphilis. Mauthner says that *60* per cent. to *75* per cent. of all cases are due to syphilis. Others are satisfied with a smaller percentage; but we may at least ascribe one-half of all cases to this disease. It is often, but not always, easy to detect the syphilitic nature of an iritis objectively. Small papules (*iritis papulosa*) or particularly broad synechiæ, congestion of isolated areas of the iris, and a moderate brine-like exudate into the anterior chamber all indicate syphilis.

Tuberculosis, according to Michel, is nearly as common a cause of iritis as syphilis. This view seems unsupported by other observers. Proof—the detection of the tubercle bacillus—is in most cases lacking, since an opportunity for a microscopic examination is not often presented. We shall, however, discuss later on a form of iritis that is undoubtedly of tubercular origin. Articular rheumatism, gout, gonorrheal inflammation, diabetes, albuminuria, severe infective diseases like typhoid fever, small-pox, and recurrent fever, are all, in a decreasing ratio, causes of iritis. Finally, there are a few cases of iritis in which none of the causes enumerated can be discovered. A universally popular explanation is "catching cold." The physician must be satisfied with the term "idiopathic."

Treatment.—From what has been said it is clear that the general physical condition must be carefully examined in any case of plastic iritis; syphilis must be particularly traced and, if positively found, treated. If the examination is negative, the local treatment must begin with decided atropinization. The best plan is to place in the conjunctival sac a kernel of some salt of

[1] The only circumstance that cannot be made to accord with this proposition is the fact that iritis often occurs on one side only.

Digitized by Illinois College of Optometry

atropin about the size of a pin-head, and have the patient press on the tear-sac for fifteen minutes. If the adhesions are broken up, if the pupil becomes round and dilated, it is a probable token that the power of the disease is overcome and that a rapid improvement may be expected. If the effect of the atropin is unsatisfactory, try next a *5* per cent. solution of cocain, a drop every three minutes for five doses, and then use another kernel of atropin on the conjunctiva with the same care to prevent intoxication. If on the next day no decided improvement is evident and if the synechiæ seem not yet broken up, apply six to eight leeches to the temple and repeat the cocain and atropin. If there is still no effect, no time should be lost before beginning mercurial inunctions, even if syphilis is not demonstrable. Healthy adults—and these are the patients most usually attacked—can tolerate a daily inunction of *5.0 grams of the unguentum hydrargyrum cinereum;* weaker patients should use smaller doses, *3.0, 2.0, or 1.0 gram* daily. If the iritis is severe, a warm bath and profuse diaphoresis should be ordered before each inunction. Of course, the mouth should be carefully watched meanwhile. All this time the local treatment with cocain and atropin must be continued. The effect of this energetic mercurial treatment is remarkable; at the end of the first week decided improvement will be observed, even in the worst cases; the inflammation will subside, the adhesions will be to some extent loosened, and the noticeably reduced visual acuity will begin to be restored. In four weeks the cure will be about complete. Pain, which often robs the patient of his night's rest, may be combated by warm applications to the eye, by quinin *0.2 gram* or antipyrin *0.5 gram* internally, as occasion demands, and in the worst cases by morphin *0.01 gram* hypodermatically. If all such means fail, a corneal puncture with release of the aqueous will bring about immediate ease from pain; to be sure, the pain returns as soon as the former tension is restored, but it is seldom so distressing, and the corneal puncture may be repeated. If a circular synechia and the resulting heightened tension has not been avoided, the inflammation should be no bar to the performance of an iridectomy; but if even the slightest connection remains between anterior and posterior chambers, enough to exclude any immediate danger to the optic nerve, the iridectomy should be postponed until the inflammatory storm has passed. *In no case should the patient be discharged before an iridectomy is performed, if the adhesions are so plentiful or so extensive*

Digitized by University of Illinois at Chicago

as to threaten a total synechia during any future relapse. Severe cases of iritis should be confined to bed in a dark room; in milder cases the patient may go about, but should give up all work, reading especially. The eye must be protected against strong light by smoked glasses. Alcohol and stimulating food are to be avoided.

(*b*) **Iritis Serosa.**—This is of a decidedly chronic character and shows few of the signs of inflammation. The neighborhood of the cornea is a delicate rose color. The patient seldom complains of more than a cloud before the eyes and some dazzling. Objectively it is seen that the inflammatory products are deposited in the anterior chamber and on the posterior surface of the cornea (*Fig. 88*, see also *pp. 246* and *247*), and not, as in plastic iritis, on the iris or within the pupil. The aqueous is hazy and increased, this increase being recognized by the greater depth of the anterior chamber and the heightened tension of the globe. The pupil is of medium size, the iris a trifle discolored and sluggish in its movements. The disc, which at this stage of the disease can be quite well seen, is distinctly hyperemic, the retinal veins tortuous and swollen.

If the disease advances, the deposits on the back of the cornea increase and coalesce, forming semilunar lines. Wherever these lines are found we may expect opacities in the posterior corneal layers, which never quite clear up. Posterior synechiæ and vitreous opacities are other common results, the latter proving that the ciliary body has been sympathetically attacked—*iridocyclitis serosa.*

Serous iritis most usually occurs in young persons, particularly in young anemic women. Uterine derangements and inherited syphilis have been called causes. Since serous iritis is bilateral, as a rule, it is doubly proper to search for some general dyscrasia, although this inflammation is often a purely local disease occurring after cataract operations.

Prognosis is more favorable than that of plastic iritis, in so far as a complete cure may take place without synechiæ or other sequelæ, but it is more unfavorable on account of the great tendency serous iritis has to involve the posterior portions of the uveal tract, and thus seriously to injure or even to destroy the eye. The chronic course of serous iritis (six to eight weeks) must also be taken into account.

Treatment.—Owing to the fact that the patient is usually poorly nourished and in weak physical condition, a depressing mercurial treatment cannot be attempted. It is better to try to raise the

Digitized by Illinois College of Optometry

patient's strength by proper food and regimen. Diaphoresis, small doses of iodid of potassium or of iodid of iron, encourage the absorption of the inflammatory products. Locally, atropin in small quantity, say twice a day a drop of a ½ per cent. solution, is serviceable in keeping the pupil dilated and in breaking up any accidental adhesions. Repeated corneal punctures to release the aqueous are very useful, since the deposits are mechanically removed thereby, and absorption, even of vitreous opacities, is noticeably encouraged.

(*c*) **Iritis Suppurativa.**—In this form the inflammatory products —pus cells—are deposited within the iris itself, and in suppurative iritis the most prominent sign is an *increase in the thickness of the iris*. A *more pronounced discoloration* also characterizes it; the color may become quite yellow. Hyperemia is so intense that by using a lens the vessels can be clearly distinguished; in some cases they may be seen to have ruptured and to have allowed blood to escape into the anterior chamber. The pus cells, collecting in the anterior chamber, form a *hypopyon*, which is in two ways different from that of "ulcus serpens corneæ" (*p. 229*): it consists solely of pus cells (not, as in ulcus serpens, of both fibrin and pus cells), and therefore changes its location as the head is moved—a condition not so easy for a compact clot composed of both pus cells and fibrin. Again, this hypopyon is susceptible of such a rapid absorption that no trace of it may be detected on the next day. The pupil is distorted by a fibrinous or purulent exudate. It may be stated that this form is rare nowadays, since one of the chief sources of suppurative iritis, infection by a wound, has been overcome by antisepsis. Another cause, diabetes, is still of moderate influence.

Prognosis is doubtful, since there is danger that the disease may pass to the choroid and lead to suppuration of the eyeball. Cases are seen, however, due to some obscure cause, in which the hypopyon and the entire disease disappear as quickly and as mysteriously as they come.[1] Suppurative iritis from diabetes usually ends favorably.

Treatment should commence with rapid inunctions; in diabetes, with salicylate of sodium. Locally, atropin should be used, and after the severer inflammation has passed, the clouded aqueous with its hypopyon should be released by corneal puncture.

[1] A case of choroidoretinitis that I have just treated ran exactly this course.

Digitized by Illinois College of Optometry

(*d*) **Iritis Nodosa** (*Iritis gummosa et tuberculosa*).—A collecting of cells into small nodules may occur in both plastic and suppurative iritis, but it has no characteristic appearance in any one case. There are cases, however, in which the nodules attain the size of a millet seed, a pea, or even of a bean, and are therefore of the greatest diagnostic importance, since they are seated upon a healthy or nearly healthy iris. These nodules are either small gummata or tubercles; in the first case we speak of iritis gummosa, in the second, of iritis tuberculosa.

Gummata are most always solitary, rarely are there three or four. A gumma sits at the pupillary edge or (less frequently) at the ciliary edge of the iris, in the latter case being below and inward. Its size is, according to Alexander's observations, that of half a pea to half a hazelnut. It has a brownish-yellow or even a yellow color, and is surrounded by a brownish-red base composed of blood-vessels.

Tubercles are usually in groups. The nodules are at some distance from the pupillary edge and sit with preference on the lower half of the iris. The color, grayish-white or whitish-yellow, is essentially lighter than that of a gumma. The adjacent lymph glands of the same or of both sides are swollen. The physician should always make a careful examination of the general condition of the patient, and try to detect the history or the presence of syphilis or tuberculosis on other parts of the body. Tubercular iritis usually attacks young persons up to the twentieth year, gummatous iritis those in more advanced life.

Treatment.—Iritis gummosa is cured when the cells disappear, but there is left in their stead a cicatricial connective tissue. The iris is essentially changed in appearance thereby, its blue becoming gray, its brown, grayish-brown; the details of the surface of the iris are no longer to be recognized; its motility is diminished or lost. Such an iris is atrophic; atrophy of the iris is therefore always to be feared when any inflammatory product has been deposited within its tissue.

Iritis gummosa is, like gumma of other parts of the body, an expression of late or tertiary syphilis, and is consequently to be treated with iodid of potassium, not with mercury. The inflammation is to be attacked as in iritis plastica.

Iritis tuberculosa is divided by Haab into two groups. In the lesser of these, nodules are formed, increase, cause much distress, and gradually disappear. They leave the eye in a tolerable condition, or they may set up a chronic choroiditis that may finally destroy it. The other and large group is evidenced by pronounced hypertrophies that fill the anterior chamber and penetrate the cornea at last, so that the eye atrophies (phthisis). Such cases were formerly called *granuloma* of the iris.

Digitized by the Illinois College of Optometry

Prognosis in iritis tuberculosa is bad. In many cases the eye must be enucleated. In the milder form, however, we may hope that proper treatment of the general tuberculosis and local treatment of the iritis will bring about a favorable ending. Whether an early excision of the nodules will effect a cure has not yet been decided. Most observers are opposed to the operation.

3. INJURIES AND FOREIGN BODIES.

Wounds of the iris were formerly but erroneously considered a serious matter. They were blamed for the mischief that was really due to an injury to the lens. A wound of the iris may be caused directly by some penetrating instrument, like a fork, needle, a bit of iron, or a stone, or indirectly by a blunt weapon. It is detected by focal illumination or by transillumination, for beside the red luminous pupil there will be seen a distinct red luminous hole, assuming, of course, that the lens behind it is not already opaque.

An indirect wound usually results in tearing away the iris from the ligamentum pectinatum and ciliary body. The condition, called *iridodialysis*, may be caused by blows from a stick, a ball, or a branch of a tree. As a rule, there is a profuse hemorrhage into the anterior chamber—*hyphema*. Another kind of injury may result in a similar way, the inversion of the iris backward. If the entire iris is so inverted, the natural impression is that the pupil is extremely dilated; but if only a portion of the iris is so inverted, there is the appearance of a coloboma. Paralysis of the iris, *iridoplegia*, may be also caused by a blunt weapon. It is really a paralysis of the sphincter pupillæ, and is, therefore, evidenced by dilatation of the pupil, which never completely disappears, although the paralysis of the muscle may, after some time, appear to be cured.

By far the commonest injury to the iris is that made during an **iridectomy** for curative purposes. The indications for the operation are numerous, and are given in the different sections of this book. Only its description is given here. The instruments necessary are: A retention lid speculum (*Fig. 98*), a fixation forceps (*Fig. 78*), a straight (*Fig. 79*) or an angular (*Fig. 99*) keratome, an iris forceps (*Fig. 89*), scissors, a Daviel's spoon (*Fig. 127*), and a delicate spatula (*Fig. 100*). After the speculum is in position, a fold of conjunctiva should be seized near the cornea, opposite the place where the incision is to be made; then the keratome is entered at the scleral border, the point being kept nearly perpen-

Digitized by University of Illinois College of Medicine

dicular to the sclera till it has reached the anterior chamber, when the handle is depressed so as to bring the blade parallel to the surface of the iris; the knife is now pushed forward till the external wound is large enough for the particular purpose of the operation. As the blade is withdrawn the handle should be still more depressed, so that the point of the knife is in contact with the posterior surface of the cornea, since by this means an injury to the advancing lens is best avoided. The fixation forceps are now given to an assistant; the iris forceps, closed, are thrust through the wound to the edge of the pupil, then opened so as to seize the iris between its

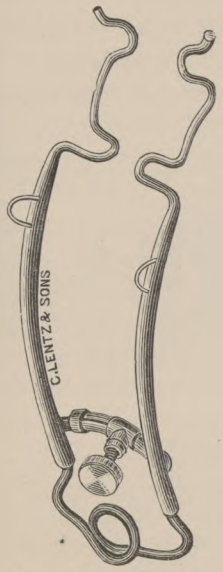

FIG. 98.—LID SPECULUM.

FIG. 99.—ANGULAR KERATOME.

FIG. 100.—SPATULA FOR REPLACING THE IRIS.

branches; the iris is drawn out of the wound far enough to see the pigment layer at the back, when a portion of it is cut off by the scissors held with firm pressure against the eyeball and parallel to the wound. *Fig. 101* shows the result after a proper excision, *Fig. 102* the not unusual case where a corner of the pupillary edge has been drawn into the wound. Here the effort should be made to replace this edge, either by stroking the cornea with a Daviel's spoon or by entering the spatula into the anterior chamber and so thrusting the iris directly into place. If this does not succeed, the iris forceps and scissors must be used again to excise the incarcerated

Digitized by the Illinois College of Optometry

bit of iris. All antiseptic precautions necessary and the after-treatment are discussed under the operation for cataract (*q. v.*).

The commonest foreign bodies in the iris are splinters of wood, stone, iron, or copper. Eyelashes, or the hairs of animals, are less frequent. An aseptic foreign body upon or in the iris may be tolerated for years, but no dependence can be placed on this. As a rule, inflammation is soon set up. Since any foreign body in the iris or anterior chamber is difficult to remove after the aqueous has become clouded, it must always be removed at once. This is by no means easy if it has dropped into the iritic angle. For its removal an incision should be made at the scleral border with a Graefe's knife (*Fig. 126*), and an attempt made to grasp the object with a Daviel's spoon, a forceps, or (if it is iron) with the magnet; if this does not succeed, or if it seems inadvisable to attempt it on account

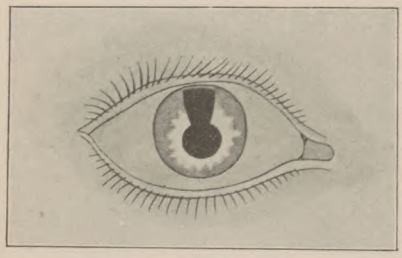

FIG. 101.—KEY-HOLE COLOBOMA, THE EDGES OF THE IRIS BEING IN THEIR PROPER PLACE.

FIG. 102.—INCARCERATION OF THE IRIS IN THE WOUND (AT THE RIGHT).

of iritis, it is best to enter the iris forceps open, to seize the iris to the right and left of the foreign body, to enclose the object within this fold, and to perform an immediate iridectomy.

Parasites in the iris are discussed under Parasites (*q. v.*).

4. NEW GROWTHS.

(*a*) **Cysts.**—True and false cysts are found in the iris. A genuine cyst protrudes from the iris as a whitish transparent nodule, with a clear fluid contents and a cyst wall of very thin iris tissue having an internal layer of epithelial cells. A false cyst is an atheromatous tumor; it is round and yellow, not transparent; its contents is not fluid but mushy, and consists of epidermal cells concentrically arranged.

The origin of these formations has been much discussed, but a satisfactory conclusion is not yet reached. There is no doubt that some, especially the atheromatous, cysts arise from invasion of the iris by corneal epithelium. These, as well as most of the genuine cysts, originate after some previous penetrating wound of the cornea, from which corneal epithelial cells have been crowded into the iris. An earlier injury is therefore

Digitized by the Boston College of Optometry

an extremely important factor in determining whether a cyst is of the atheromatous or nodular variety.

These new growths endanger the eye when they grow large enough to set up inflammation or to increase the tension. They should, therefore, be completely removed by an iridectomy.

(*b*) **Tumors.**—Occasionally there is in the iris a pigmented or unpigmented tumor, shown to be *malignant* by its rapid growth, and to be a sarcoma by its histologic structure; usually a melanosarcoma, rarely a leukosarcoma.

Benign tumors on the iris or extending into the anterior chamber are recorded. The pigmented edge toward the pupil has occasionally small pigmented nodules, such as are normal in the horse's eye, where they are sometimes loosened by the activity of the pupil.

Rapid growth in any tumor should suggest malignancy.

5. CONGENITAL MALFORMATIONS.

(*a*) **Albinism.**—The essential characteristic of this condition is a lack of pigment, not necessarily in the iris alone, but in all parts of the body, so that the whole body appears lighter-colored than normal. Lack of pigment in the middle and inner retinal layers causes dazzling and photophobia. Albinos often suffer from active movements of the iris, from nystagmus, and from diminished visual acuity. The condition is a morphological defect, explainable when we remember that the formation of pigment takes place during the latter months of fetal life and after birth, and that every embryo is, therefore, albinotic up to a certain stage of its life.

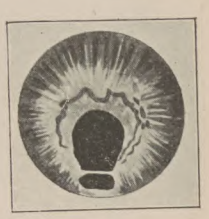

FIG. 103.—CONGENITAL COLOBOMA (WITH BRIDGE). (*After Sämisch.*)

(*b*) **Heterochromia.**—We sometimes see a person whose eyes are not of the same color, or whose irides may have sectors of different colors. In other cases dark or light blotches may be irregularly scattered over the iris. Many such persons reach a certain notoriety by the superstition of imaginative observers, who see indications of letter formation—the word Napoleon, for example—in these blotches. Anxious mothers often observe these irregularities in the eyes of their children and ask the physician's advice about them.

(*c*) **Coloboma.**—This is the most frequent defect in the iris. The aperture in it gives to the pupil an egg- or pear-shaped appearance. This aperture lies regularly beneath, or beneath and to the nasal side of, the pupil (*Fig. 103*). It is due to an incomplete closure of the optic fissure in the fetus. The aperture may nearly disappear as adult life is reached. There are seldom visual disturbances due to the defect, but if any are present, they can be usually traced to a corresponding defect in the choroid—coloboma choroideæ.

(*d*) **Corektopia** is the term used to describe a displacement of the pupil; it is usually downward and inward, and is, to a certain extent, but an exaggeration of the pupil's normal excentricity (*p. 266*). Displacements in other directions are rare.

(*e*) **Irideremia** is the lack of, or a mere suggestion of, iris. The condition is always bilateral, while coloboma is nearly always unilateral. The extraordinarily large pupil is not a deep black, but rather gray or even red.[1]

(*f*) **Membrana Pupillaris Perseverans.**—This term describes a condition in

[1] The optical reasons for this phenomenon are given in the study of the illumination of the eye (*p. 99*). Dazzling and reduced vision are very noticeable.

Digitized by Google College of Optometry

which fibers springing from the anterior surface of the iris pass over the pupil to be attached to the anterior surface of the lens (*Fig. 104*). It is not proper to consider this as a continuation of the iris inward. It is rather the remnant of a vascular connective-tissue layer that in the embryo enveloped the lens before the iris had been formed. The fibers are so long and elastic that they offer no hindrance to the play of the pupil. They usually cause no visual disturbances.

6. CHANGES IN SIZE AND MOTILITY OF THE PUPIL.

The diameter and activity of the pupil are subject to such great variations during health that there must be a decided dilatation or contraction before the condition can be called pathological. We do not know why one individual has narrow pupils, while another, under exactly the same circumstances—illumination, accommodation, and convergence—has wide pupils. We do know that the newborn have very small pupils, young people large and active pupils, and that the pupils of the old are again narrow and sluggish. It is an easy matter, however, to discover any disturbance in size or motility of one pupil, if it can be compared with the other. Always, therefore, search for any possible inequality between the two (*anisokoria*).

FIG. 104.—MEMBRANA PUPILLARIS PERSEVERANS. (*After Wicherkiewicz.*)

If anisokoria is detected, the next problem is to determine which pupil is diseased—the narrower or the wider one. To answer this the pupil must be set in motion; and that pupil which shows the lesser activity when the illumination is changed or when the object looked at is approached to or withdrawn from the far and near points, may, as a rule, be considered the diseased one.

There is still another question: What is the pathology? Is a pupil dilated by paralysis of the sphincter or by spasm of the dilatator? Or is a pupil contracted by spasm of the sphincter or by paralysis of the dilatator? As a matter of fact, all these conditions are possible. A conclusion can be reached either by demonstration or exclusion. Let us assume that we have a patient with a dilated and rigid pupil: obviously there must be a paralysis of the sphincter. Among the causes of this paralysis the commonest is atropin, and the patient should always be asked whether his eye has been previously treated by some one else.[1]

[1] A short time ago there was brought to me a little patient with dilated and rigid pupils. I told the father that atropin or some such poison must have been applied. The father

If atropin or other mydriatics (*p. 270*) are out of the question, we must bear in mind the possibility of:—

(1) Glaucoma;
(2) Injury, and
(3) Disease of the oculomotor nerve.

Paralysis of the sphincter is also, as a rule, combined with paralysis of the ciliary (accommodative) muscle.

In cases of dilated pupils due to spasm of the dilatator, the patients are not apt to ask advice. They are usually insane persons in a delirious condition, or patients suffering from severe dyspnea, or those in uremic, epileptic, or eclamptic convulsions,—patients, therefore, in whom the dilatation of the pupil is of secondary importance. Of course, spasmodic dilatation of the pupil may be produced by milder diseases if they cause irritation to the sympathetic; other evidences of this irritation will be discoverable, however, such as vesicles of that side of the face and widening of the palpebral fissure (Mueller's muscle supplied by the sympathetic). Intestinal worms have been accused of causing moderate irritation of the sympathetic.

A pathologically contracted pupil is rarer than a pathologically dilated one. It results from spasm of the sphincter produced by eserin or pilocarpin as well as from hyperemia or beginning inflammation of the iris, or from oculomotor irritation due to inflammation of the brain and its membranes. As a rule, there is an accompanying spasm of the ciliary (accommodative) muscle. Paralysis of the dilatator causes miosis when the medulla or spinal cord is affected by injury or inflammation. This is called *spinal miosis*.

Finally it must be mentioned that in monocular blindness the pupil of the blind eye no longer reacts to light falling upon it, but does react in harmony with the sound eye when this latter is illuminated or changes during an effort at accommodation. This "consensual movement," that is, contraction of one pupil due to illumination of the other eye, cannot, of course, be present in the healthy eye when the blind eye is stimulated.

Eyes with good visual acuity may show a "reflex pupillary rigidity," that is, loss of reaction to light stimulation, although normal

---

declared that it was not possible. I insisted on a thorough investigation, assuring him that we should discover something. The next day he came back to say that the child had squirted the juice of the thorn-apple (stramonium) into his eye!

Digitized by Internet Archive of Ophthalmology

reaction to accommodation and convergence may still be present. This is of the gravest significance, since it is a sign of beginning spinal cord disease—tabes dorsalis.

Hippus is a clonic spasm of the sphincter pupillæ, by means of which a rapid change in the size of the pupil takes place without external cause. The disease is usually associated with nystagmus. It need produce no visual disturbance.

Iris Tremulans, Iridodonesis.—A healthy iris neither trembles nor oscillates, thanks to the fact that the lens offers a firm and smooth support upon which the iris glides. But if the lens is crowded very much to the rear, as in myopia, for example, or as the result of atrophy of the vitreous, or if the lens shrivels, as it does in overripe cataract, or if it is lacking, as it always is after cataract extraction, the iris has no support, and it trembles.

B. DISEASES OF THE CILIARY BODY.

1. CYCLITIS.

Inflammations of one division of the uveal tract have an extraordinary tendency to involve the other divisions. This tendency is most clearly seen in inflammations of the ciliary body. The iris is always more or less involved, so that inflammation of the ciliary body is called by many authors *iridocyclitis*, and if the choroid is simultaneously affected, *iridocyclochoroiditis*.

Cyclitis is always a serious, often a dangerous, disease, and must therefore be sharply differentiated from the relatively benign iritis. This distinction is, however, not an easy one, because they both have in common the symptoms of pain, photophobia, lacrimation, and obscured vision. It is necessary, therefore, carefully to search for those signs that characterize cyclitis alone. These are:—

(1) Sensitiveness to pressure in the ciliary region;

(2) Cloudiness in the anterior portion of the vitreous;

(3) Noticeable changes in the intraocular tension, increased at first, diminished in the later stages of the diseases.

Sensitiveness to pressure is often so pronounced that the patient shrinks back with a start if the ciliary region (particularly the upper and outer area) is only lightly touched, while many a patient is made unconscious by it.

Three forms[1] are described: serous, plastic, and purulent cyclitis.

[1] A fourth might be cyclitis nodosa, since gummata of the ciliary body have been reported, which involved the iris only supplementarily. They are extremely rare, however.

Digitized by Harvard College of Optometry

Cyclitis serosa is comparatively benign, developes like a serous iritis (*p. 277*), and cannot be clearly separated from it.

Cyclitis plastica is the worst form. It begins with the signs of severe inflammation accompanied by swelling of the conjunctiva and lids. The inflammatory product is deposited chiefly in the posterior chamber and in the more anterior portion of the vitreous; it thus encourages adhesion between the back of the iris and the lens (*Fig. 105*), and after becoming organized into a connective-tissue membrane it produces a very extensive adhesion between lens and iris, which is called *synechia posterior totalis.* It is characterized by

FIG. 105.—TOTAL POSTERIOR SYNECHIA. (*After Pagenstecher and Genth.*)
The adhesion between iris and lens is so extensive as to obliterate the posterior chamber.

the depth of the anterior chamber, particularly at the filtration angle. There may be membranous formations in the vitreous as well. The nutrition of the lens suffers so severely on this account that total or partial opacity of the lens is unavoidable. As this pathological membrane contracts, it carries the disasters of detachment of the retina and atrophy of the eyeball in its trail. Plastic cyclitis results in the great majority of all cases immediately or sometime after an injury to the ciliary body. Foreign bodies within the eye are almost certain to destroy the eye by a plastic cyclitis (see Injuries to the Globe). Idiopathic cases are said to have resulted from syphilis, tuberculosis, and diseases of the uterus.

Digitized by the Illinois College of Optometry

Cyclitis suppurativa runs a stormy course. It is distinguished from plastic iritis by the presence of hypopyon, and of a purulent exudate behind the lens which was formerly called hypopyon posticum. It is characteristic of purulent cyclitis that the hypopyon comes and goes very quickly—it may disappear within a few hours If purulent cyclitis involves the choroid there is danger of that condition called *panophthalmitis*, in which the whole eyeball suppurates and finally atrophies. Such an ending is nearly always unavoidable if purulent cyclitis is due to infection after injury or operation. Purulent cyclitis ending in atrophy is said to follow severe infective diseases (small-pox, scarlet fever). Occasionally a purulent cyclitis from some unknown internal cause may run a favorable course.

Treatment of cyclitis, taken altogether, is that of iritis, but atropin must be used with caution, as it is often poorly borne. In serous cyclitis the not unusual appearance of increased tension demands particular care. To reduce this tension the local use of cocain is of service, as may be also diaphoresis by subcutaneous pilocarpin injections. If success is not reached, a corneal puncture should be tried, and may be repeated every second day if circumstances warrant. Plastic and purulent cyclitis may be treated with an impressive course of mercurial inunction; whether or not this really helps is questionable. When the inflammatory phenomena have completely subsided, an iridectomy should be performed. The disease tends to relapse, even after years have passed, and an iridectomy may help to prevent such an accident, but unfortunately the operation has not always the desired result, since the aperture in the iris may close up or the inflammation be lighted up anew. Purulent cyclitis after an operation is much rarer nowadays, thanks to antisepsis; if it does occur, even the worshipers of mercury will not resort to inunctions, but will restrict themselves to local treatment with atropin, antiseptic douches, and warm compresses.

Very recently subconjunctival injections of mercury have been tried (about 0.00003 of the bichlorid at a dose) at intervals of three to four days. A definite statement as to the efficacy of this method cannot at present be given. My own experience has not been very encouraging.

2. PARALYSIS AND SPASM OF THE CILIARY MUSCLE.

Paralysis or **Paresis** of the ciliary muscle is evidenced by a destruction of, or a diminution in, the range of accommodation. Since the range of accommodation becomes smaller with the senile

Digitized by Illinois College of Optometry

changes in the lens (*p. 45*), a paralysis of the ciliary muscle should not be diagnosticated unless the range of accommodation in a healthy lens is demonstrably smaller than that which corresponds to the age of the patient. Usually, but not always, some dilatation of the pupil (*p. 270*) is associated with a paralysis or paresis of the ciliary muscle. The optical conditions are discussed in the section on "The Range of Accommodation" (*p. 41*).

Another occasional result is *Micropsia*. We estimate the size of an object according to the size of its retinal image, and according to the distance at which we suppose it to be. If the retinal image of an object remains unchanged, it appears to us either small or large, according as we think of it as far or near. For example, a fly in the air may seem to us to be a large bird a long way off. In estimating the distance of any object we see, the feeling of effort we have made for the sake of accurate dioptric adjustment plays an important part. But since a patient with a weakened ciliary muscle makes a great effort to adjust his eye for a certain object, he thinks it must be nearer than it actually is. If the object were actually at the place he supposes, its retinal image would be much larger than it really is; consequently it appears smaller to him.

The causes of paresis or paralysis may be peripheral or central, that is to say, the ciliary muscle itself (or the nerve fibers ending in it) may be paralyzed, or the passage of a nervous stimulation may be prevented. For example, atropin causes a peripheral paralysis; that caused by disease of the oculomotor nucleus (see *Paralyses of the Eye Muscles* (*q. v.*) is central. A paralysis may be caused by intoxication (ptomaines, diphtheria, etc.), or by weakness (prolonged confinement, excesses, loss of blood, exhausting diseases), the seat of the trouble being then indeterminate.

Treatment depends upon the cause, and therefore is usually general. Locally, glasses, eserin, and electricity may be tried.

If there is **spasm** of the ciliary muscle, the far point of the eye draws nearer, that is, the emmetrope becomes apparently myopic, the myope still more myopic, and the hyperope less hyperopic than that which corresponds to the shape of the globe. The range of accommodation is therefore shortened but not destroyed. The near point also draws nearer, but relatively less so than the far point. Since, then, a weaker effort than usual suffices to attain a certain effect, objects are supposed to be further off than they really are, and consequently they are estimated to be too large—*macropsia*.

As causes, eserin and pilocarpin may be named, as well as the strain on accommodation resulting from hyperopia, or from holding books too close, or from weakness of the muscles of converg-

Digitized by Illinois College of Optometry

ence, for if the proper convergence can be attained only by a particularly strong effort of the will, an unduly powerful impulse is at the same time given to the muscle of accommodation. Finally, spasm of the ciliary muscle with miosis is often a sign of severe spinal-cord disease.

Treatment.—Spasm of the ciliary muscle may be overcome by atropin; but if it is of central origin, the spasm naturally returns as soon as the action of the drug passes off.

C. DISEASES OF THE CHOROID.

1. SCLEROCHOROIDITIS ANTERIOR.

This disease involves the anterior part of the choroid, inaccessible to the ophthalmoscope. The inflammation is at first local, leading to the development of an episcleral nodule (*p. 262*). At this stage it is difficult or impossible to diagnosticate sclerochoroiditis anterior from episcleritis. The results, however, make a diagnosis easy, since episcleritis is always a benign local disease, but anterior sclerochoroiditis shows a pronounced inclination to spread out on the surface, to attack the cornea and iris, to produce opacities in the anterior portion of the vitreous, and, by raising the tension, to cause ectasia of the sclera. The disease, with occasional improvement or subsidence, lasts for years, and finally leads to blindness through flatness and opacity of the cornea, increased tension, and change in form of the eyeball. The causes are not well defined; rheumatism, gout, or syphilis may be suspected.

Treatment can be successful only in the beginning. Mercury and diaphoresis are said to be of service. Tension must be carefully watched, and in suitable cases should be lowered by corneal puncture or iridectomy. These operations are occasionally successful in putting an end to an already beginning sclerectasia.

Sclerochoroiditis posterior (sclerectasia posterior, staphyloma posticum) is discussed in the section on Refractive Errors, under Myopia (*q. v.*).

2. CHOROIDITIS EXUDATIVA.

This disease is not, as might be supposed from the name, supplementary to plastic iritis and cyclitis. There is, of course, such a supplementary inflammation of the choroid, that is, a choroiditis

Digitized by Illinois College of Optometry

areas remain in the otherwise darkened field of vision—"Visus reticulatus."

Treatment is happily of great service in the disease. An impressive course of mercurial inunction, with complete rest to the eyes, may bring about improvement after several weeks, or may even effect a cure. Relapses are not unusual.

4. CHOROIDITIS SUPPURATIVA.

This is one of the eye's worst enemies, for it may take but a day or so to destroy the eye, while weeks and months may elapse before the eye, or what atrophied fragment of it is left, becomes free from pain. The disease begins with hemorrhage into the retina and choroid; then follows an abundant collection of pus cells, which

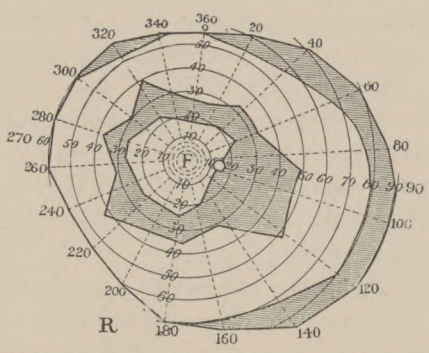

FIG. 107.—FIELD OF VISION IN CHOROIDITIS SYPHILITICA. (*After Wilbrand.*)
The darkened areas are defects in the field.

lie at first in the innermost layers of the choroid and along the vessels, but which soon invade the entire choroid, retina, and vitreous. Externally the eye has the following appearance: the lids and conjunctiva are red and swollen, and throw off a mass of purulent mucus; the cornea is somewhat hazy, its surface lusterless; in the anterior chamber there is found pus—hypopyon; the iris is discolored, swollen, and in places adherent to the lens; the pupil appears yellowish, the light entering it being reflected from the pus-infiltrated vitreous; the eyeball is hard. The patient complains of great pain in the eye and forehead; he is blind in the affected eye; he has fever, and general malaise. This description may apply to the disease at its height, and as the inflammation subsides, in the course of weeks, a cure may be effected—not a cure of the blind-

Digitized by the Illinois College of Optometry

ness, however, but only of the inflammation, for it is very rare that any visual perception is preserved.

This condition is not always applicable to the height of the disease. Fever may increase, pain may become unbearable, and suppuration may extend beyond the eyeball. Then exophthalmos is produced, the eye becomes immovable, and panophthalmitis is inevitable. The eye becomes an abscess cavity, but it is a matter of much time and agony before the sclera is perforated. The pus does finally escape, however, the pain subsides, the eye atrophies, and the patient gets well.

Purulent inflammation of the choroid, with its daughter, panophthalmitis, is caused by the entrance of germs (staphylococci, streptococci, bacilli). In some cases they are brought to the eye from other parts by the circulation, and, lodging in the choroidal capillaries, they form septic emboli.[1]

This occurs occasionally in puerperal fever, pyemia, and numerous other severe infectious diseases, but since patients are apt to die from the principal disease, the eye trouble plays but a subordinate part. In other cases germs enter the eye from without, either during operations or from injuries, or are easily carried by foreign bodies that penetrate to the interior. Thin cicatrices may admit the passage of these germs.

Treatment can do no more than to quiet pain by narcotics, or by the local use of atropin and hot compresses; or to end matters by an operation, consisting of an incision between the tendons of the external and inferior recti. Exenteration of the eyeball is surer still. Enucleation, the most radical remedy, was formerly avoided in panophthalmitis, because death from meningitis so often resulted; but, thanks to antisepsis, hundreds of cases are now treated with the best success by enucleation.

Choroiditis suppurativa chronica may run its course without any signs visible externally, but the ophthalmoscope detects the effect of the disease as a yellowish mass, consisting chiefly of pus cells, which the choroid throws out either behind the retina or into the vitreous. It may be comprised with glioma retinæ (*q. v.*).

5. TUBERCULOSIS OF THE CHOROID.

This appears in two different forms. Sometimes it is associated with general miliary tuberculosis, but as this is a severe and incurable disease the patient seldom comes to the ophthalmologist, and ophthalmoscopic examination is made at the suggestion of the attend-

[1] Hence the name *choroiditis embolica, septica, metastatica.*

Digitized by Illinois College of Optometry

ing physician, because the detection of the choroidal nodules of tubercle removes all doubt as to the nature of the systemic trouble, if there is any remaining uncertainty in distinguishing between tuberculosis and typhoid. The tubercles are found in the inner layers of the choroid, near the posterior pole; with the ophthalmoscope they are seen to be small, round or egg-shaped, whitish-yellow or white spots, the smaller ones being indistinctly, the larger ones sharply outlined, some having a pigmented edge. Those which happen to be crossed by retinal vessels are very clearly seen to protrude toward the center of the eye. The number of nodules visible with the ophthalmoscope is probably only one-tenth of those actually present, as the others are doubtless too small or too deeply imbedded to produce any atrophy of the retinal pigment epithelium. Their rapid development or growth is remarkable; new nodules may become visible within twenty-four hours. They have the histological structure of miliary tubercles, with the additional characteristic that the (comparatively infrequent) giant cells contain pigment, a condition that was at one time supposed to belong exclusively to miliary tubercles of the lung. The choroid between the tubercular nodules is hyperemic and diffusely infiltrated with round cells.

The second form is of more interest to the ophthalmologist. It is evidenced by the development of a tumor (spheroidal tubercle) which causes detachment of the retina and blindness, and which may set up inflammation of the eye, recognizable by the posterior synechiæ, vitreous opacities, and pain. Such cases have been reported in persons who are apparently free from other signs of tuberculosis; nevertheless, in most of them there was developed, after a longer or shorter interval, a tuberculosis of the cerebral membranes or of the lungs, which finally resulted in the patient's death. If the fundus is still visible, the diagnosis must be made between tubercle and sarcoma. The youth of the patient, the detection of other foci of tuberculosis, swollen lymph glands, bright color of the tumor, and the presence of smaller nodules around its base—all indicate tuberculosis. It makes little difference to the patient, however, what the diagnosis may be; in both cases enucleation is unconditionally indicated, for the tubercular nodules not only grow toward the vitreous but they penetrate the sclera, attack the cellular tissue of the orbit, and may even spread backward along the optic nerve. The eye is lost and life endangered thereby.

6. SARCOMA OF THE CHOROID.

The disease is very rare; it appears but 5 to 7 times in 10,000 cases of eye trouble. The tumor develops slowly at first, but later on it involves the surrounding tissue with great rapidity. This tumor consists of a delicate, connective-tissue framework, filled with numerous large, round or jagged or spindle-shaped cells, which look like embryonic cells, and may in the same way develop into the different forms of the connective-tissue group. In about 90 per cent. of cases the sarcoma cells contain pigment granules, and the tumor is called a melanosarcoma, in contradistinction to the leukosarcoma, whose cells have no pigment. Probably a sarcoma arises always in the layer of the larger vessels. The causes are obscure.

Knapp and Fuchs have divided the course of the disease into four stages. *The first stage* is that of freedom from irritation, the

Digitized by Illinois College of Optometry

only subjective symptom being disturbance of vision. If, as is usually the case, the sarcoma grows near the posterior pole (*Fig. 108*), the disturbance consists of reduction in visual acuity, lessened refractive power, myopia becoming hyperopia, for example, and distortion of images. If the sarcoma is at the periphery, the visual disturbance is detectable as a dark spot (scotoma). Some patients do not notice this gradual approach of visual disturbance, and the physician does not, therefore, have occasion to make an examination during the first stage. The tumor may be objectively detected by the ophthalmoscope, especially if a detachment of the retina (*q. v.*), with nodular form and abrupt sides, arouses the suspicion of an underlying tumor. In many cases the tumor appears yellowish-red or brown, covered with a fine network of blood-vessels, which shimmer through the still transparent retina. If a fluid exudate is deposited between tumor and retina, this characteristic picture disappears, and the ophthalmoscope discovers nothing but the retinal detachment. The first stage varies from six months to four years.

FIG. 108.—SARCOMA OF THE CHOROID. (*After Pagenstecher and Genth.*)

The second stage is that of inflammation. Severe pain is the symptom most noticed by the patient. In the majority of cases this pain is caused by the increased tension produced by the tumor; this may, therefore, be called the glaucomatous stage. In the minority of cases the pain is caused by iridocyclitis (*p. 286*). Visual acuity declines as the pain continues, until total blindness is reached, since increased tension makes the retinal detachment complete. The diagnosis of the tumor may be impossible in this stage, owing to cloudiness of the refractive media. This stage is shorter than the first, lasting about one year on the average.

The third stage is marked by the perforation of the sclera by the unrestrainable growth of the tumor. The perforation is announced by the appearance of dark, hard nodules on the sclera and is gratefully welcomed by the patient on account of the relief from pain which it brings. If perforation occurs at some posterior portion not accessible to the observer, he is aware of the condition only when exophthalmos and restriction in eye movements are produced by the increase in the tumor's size. It now makes rapid strides;

Digitized by Illinois College of Optometry

the eye becomes a mere tumor mass protruding between the lids; there is pain, hemorrhage, and abundant secretion, so that the patient may die of exhaustion even if no metastasis has occurred.

The fourth stage, and the last, is the stage of metastasis, in which elements of the sarcoma are carried by the circulation most often to the lung and liver, where new tumors are developed which lead to the inevitable death of the patient.

From what has been said it will be seen that the diagnosis of the disease is sometimes easy, sometimes difficult, sometimes impossible. An accurate history of the patient will often simplify matters. Confusion with retinal or choroidal detachments, with primary (acute) glaucoma, and with spheroid tubercle is most likely to happen. Increased tension caused by sarcoma is absent in simple retinal or choroidal detachment; retinal detachment is absent in primary glaucoma, and it may be added that sarcoma is almost without exception unilateral, while on the contrary primary glaucoma, which has already caused blindness, will most probably show some traces of its presence in the other eye.

The prognosis is fatal if no treatment be instituted; always unfavorable even if treatment is begun early.

Treatment must, of course, proceed to the radical removal of all diseased tissue; the eye must be enucleated in the first and second stage, or the entire orbit must be cleaned out in the third stage. Experience has shown that the danger of local relapse is practically nothing if the eye is removed during the first stage of the disease; that it is still neglectable if the operation is performed during the second stage, but that it is very threatening (22 per cent.) if delayed till the third stage. It should by no means be concluded from this that an early operation insures a bright future for the patient, for, although local relapse is avoided, metastasis is still to be feared. Indeed, Fuchs declares that the danger of infection by metastasis is not essentially influenced by the time at which the operation is performed. It may be imagined that small sarcomatous elements, retained within the closed capsule of the eye, have passed into the circulation. The reverse is also true, that the germs of malignant tumors—say of the lacteal glands—may be carried to the choroid by the blood. Numerous cases have recently been reported of metastatic carcinoma of the choroid.

Digitized by Illinois College of Optometry

7. RUPTURE OF THE CHOROID.

Ruptures (lacerations) of the choroid are very common; v. Wecker says they occur regularly after all injuries to the eye with a dull weapon. The medical significance is, however, slight, since the accident always takes place in eyes severely injured in other ways, and cannot therefore be immediately recognized, on account of hemorrhage in the vitreous and other causes of opacity. If the vitreous becomes transparent again, a recent rupture appears as a yellowish, blood-specked stripe, lying usually between the macula lutea and the papilla, and embracing the latter with a gentle curve. Its location at the posterior pole is ascribed to the fact that at this place the choroid is bound down to the sclera by the entering ciliary vessels, and is not, therefore, so easily displaceable as the portion further forward. Old choroidal ruptures are lighter and whiter, and are bordered with black pigment (*Fig. 109*). Small ruptures may become completely united. The effects of a rupture on the visual power depend essentially upon its involvement of the retina and especially upon the area affected: the nearer to the macula lutea the graver the consequences to vision.

FIG. 109.—TWO RUPTURES IN THE CHOROID. (*After Knapp.*)
The retinal vessels pass unbroken across the rupture. The dark spot to the right is a hemorrhage.

Treatment.—Atropin and rest.

8. DETACHMENT OF THE CHOROID.

A detachment of the choroid is recognizable ophthalmoscopically as a roundish, brown, smooth tumor near the equator of the eye. The retina above it is faintly clouded, but does not, as a rule, prevent the true choroidal vessels from being visible through it. While detachment of the retina (*q. v.*) is detected by a trembling or shivering movement accompanying a movement of the eye, this is not the case in detachment of the choroid. Again, to distinguish the latter from a tumor, the eye's tension should be taken; in tumors this is usually increased, while in choroidal (and retinal) detachment it is diminished. Choroidal detachments may reunite completely. Many of the hitherto reported cases have been due to a loss of vitreous during cataract operations; others occurred without antecedent injury.

Treatment.—Rest.

Digitized by Illinois College of Optometry

9. CONGENITAL DEFECTS IN THE CHOROID (COLOBOMA CHOROIDEÆ).

These appear in the choroid as well as in the iris; their ophthalmoscopic image is very characteristic. On the floor of the fundus, below the disc, at a distance of about three to four times its diameter, there is seen a large, whitish or bluish, glistening area, irregular in shape, sometimes flap-like, sometimes oval, with the long axis in the direction of one of the eye's principal meridians. Its edges are strewn with pigment. Retinal (as well as scleral) blood-vessels pass across it. The retina above a choroidal coloboma is essentially modified and degenerated, and can, therefore, functionate only imperfectly. Cases have been described in which a choroidal coloboma had no scotoma in the visual field corresponding to it. Visual acuity may be normal, $\frac{4}{5}$ in one case reported by Saemisch; but, besides the coloboma, there may be other anomalies present to reduce the eye's functionary power.

10. NODULES (WARTS).

Thickening of the lamina vitrea of the choroid near the equator is a not unusual occurrence in elderly persons. They form nodule-like prominences, having a concentrically laminated structure and a meshed covering of pigment epithelium. Ophthalmoscopically, they appear as small, round or egg-shaped, or irregularly bordered, bright patches, that reflect light strongly—the wavy reflex. As they lie near the periphery they seldom cause visual disturbance, and are, as a rule, discovered only by accident. Occasionally they are found near the posterior pole, and they then affect the visual power to some extent.

DISEASES OF THE RETINA AND OPTIC NERVE.

INTRODUCTION.

The third and innermost tunic of the eye is called the *retina*. It covers the inner surface of the choroid as far as the pupillary border. It is closely attached to the ciliary body and iris and is adherent at the aperture of entrance of the optic nerve, but it is only loosely attached to the choroid. There are to be distinguished:—

(1) An optical,
(2) A ciliary, and
(3) An iritic portion.

The optical portion is the only one that plays any part in vision or that need be discussed here. Its structure is extremely complex. In section at the "pars optica retinæ" (*Fig. 110*) there are seen ten layers lying parallel to the wall of the eye. There are also some fibers perpendicular to the wall of the eye, the supporting fibers of Mueller, a connective-tissue framework in which the nervous elements are retained. The function of each layer in vision is but little understood. There is no doubt that the rods and cones are sensitive to light, that is, by their function the physical phenomenon of ether oscillations becomes a physiological process.

It was at one time supposed that the stimulation produced by light in a rod or cone was passed on through the nerve-element of the retina and through a fiber of the optic nerve to the brain cortex—the abode of consciousness,—just as a message is sent along a telegraph wire.

Later histological investigation has shown that the process is by no means so simple. A glance at *Fig. 111* shows that the visual cells (rods and cones) are not at all in direct

Digitized by the College of Optometry

or uninterrupted connection with the brain. Light stimulation, which has affected the single cone in *Fig. 111*, is modified as soon as it reaches the external reticular layer. Here as well as in the inner granular layer there are cells of a ganglionic nature whose roots are buried in the confused mass of the external reticular layer and between the nuclei of the visual cells, and whose axis-cylinders lead to the confused mass of the internal reticular layer, ending as terminal branches, or continuing as cell *b* directly into the nerve-fiber layer and the optic nerve itself. Stimulation, which has arrived at the confused mass of the internal reticular layer, experiences here a second modification. Stimulation here affects a second "neuron," [1] a ganglion-cell having its terminal branch in the external corpus geniculatum of the brain (*Fig. 113*). A third modification is effected here, other ganglion-cells receiving the stimulation and conducting it through

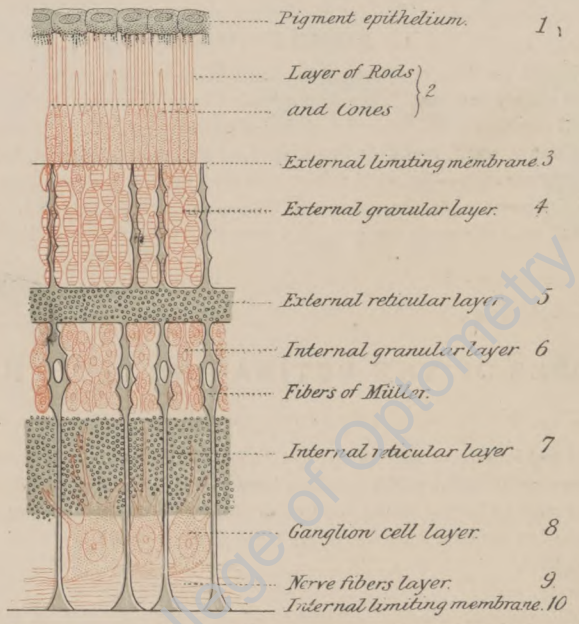

FIG. 110.—RETINA, WITH ITS NERVOUS, EPITHELIAL, AND CONNECTIVE-TISSUE ELEMENTS. SOMEWHAT DIAGRAMMATIC. (*After Schultze.*) [2]

the "optic radiation" to the terminal branches in the cerebral cortex of the occipital lobe. The ganglion-cells of the cortex convert it into a visual perception.

Let us examine again the innermost or nerve-fiber layer of the retina. It consists chiefly of axis-cylinders having their ganglion-cells in the retina, their terminal branches in the external corpus geniculatum; they are therefore assumed to be centripetal conduct-

[1] The morphological unity is expressed as ganglion-cell, axis-cylinder, terminal branch.

[2] Referring to (*5*) external reticular layer, Stoehr's latest investigations show it to consist really of two layers, (*a*) Henle's fibrous layer, (*b*) essentially reticulated layer. Formerly the fibrous layer had been recognized only at the macula lutea, where it is particularly broad.

Digitized by Illinois College of Optometry

ing fibers. Some axis-cylinders, however, have their ganglion-cells in the corpus geniculatum and the terminal branches in the retina (inner nuclear layer); they are therefore assumed by many investigators to be centrifugal fibers. The fibers of the nerve-fiber layer converge toward the foramen scleræ, where they are here collected together to form the head (beginning) of the optic nerve (*Fig. 50*). From its exit from the eyeball to its entrance into the canalis opticus the nerve measures *28* to *29 mm.* Owing to this considerable length the nerve is not straight, but has a rather S-shaped curve, and is, therefore, capable of being stretched quite an interval without restricting the eyeball in any of its rotations. The nerve is covered by three sheaths, the closely approximated and adherent pial sheath, and the looser dural sheath (*Fig. 50*); between these two lies a lymph space, separated into two compartments by the extremely thin membrane, the arachnoid sheath. The optic nerve itself is composed of bundles of nerve-fibers varying in thickness; it is so richly supplied with egg-shaped nuclei that they have been taken for evidence of inflammatory cell infiltration. Krause estimates the number of nerve-fibers at "*400,000* coarse and fine, with about the same number of very finest fibers." We may assume that they are very unevenly distributed over the retina. The region between macula and disc is most abundantly supplied, the nerve-fibers destined for it being designated as the papillomacular bundle. This lies close behind the eyeball at the temporal side of the optic nerve, but further backward it passes to the center of the nerve.

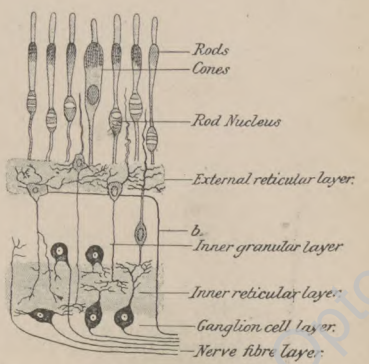

FIG. 111.—NERVOUS AND EPITHELIAL ELEMENTS OF THE RETINA. (*After Stoehr.*)

It is an important question whether the optic nerve of one eye proceeds only to the cortex of the opposite half of the cerebrum, or whether it proceeds to the half of the same side as well; in other words, whether the optic nerves of the two eyes experience a complete or only a partial decussation at the chiasm. It is a general law that nerves decussate in passing from their centers to their peripheral terminations. From the smallest vertebrates up to man the right brain perceives that which stimulates the left half of the body, and the right side of the body obeys the nervous impulse that originates in the left brain. This law is applicable also to the visual sense. In fishes, for example, whose eyes are on the side of the body, each possessing an absolutely independent field of vision, the decussation of the optic nerves is complete; this may be easily demonstrated in the herring, where there is no intermixture of fibers, but in which one optic nerve passes in its entirety through a slit in the other. The matter becomes more complicated in the higher vertebrates, where the eyes are closer toward the front of the body, the necessity for a right- and left-sided visual apparatus being thus lost. If we imagine a median section through a body of the higher vertebrate, it is obvious that the left eye will still see a large proportion of the objects lying to the right of this plane, and *vice versa*; in other words, in the higher vertebrates the visual fields of the two eyes coincide to a greater or less degree. If, now, a complete decussation of the optic nerves took place, the right brain would nevertheless still see a portion of the outer world at the right. As a matter of fact this is not the case. Experience has shown that if the right brain loses its function—say from a hemorrhage—the left eye is not blinded, but that that portion of

both visual fields lying to the left of the fixation point is obliterated. That is to say, everything lying to the right of the fixation point is perceived by the left brain, everything to the left by the right brain. It is evident that this can be possible only when the left brain is connected with the temporal half of the left and with the nasal half of the right retina, and, *vice versa*, when the right brain is connected with the right halves of the two retinæ (*Fig. 112*). It is a consequence of this that each optic nerve must send part of its fibers into the right brain, the remaining part into the left brain,—there must be a partial decussation of the optic-nerve tracts. The location of this decussation becomes a question by itself. It is easy to assume that the chiasm is the location of this partial decussation, and the most recent investigations of the course of the fibers in the chiasm, carried on by various methods, have completely confirmed this view,[1] although this has not put an end to the opposition to this theory.

The nerve-fibers proceeding from the eye continue from the chiasm along the optic tract, to terminate, as has been already mentioned, in the external geniculate body (*Fig. 113*). A small number, however, proceed to the anterior corpora quadrigemina; these are the fibers that control the reflex pupillary activity, which is thus completely outside

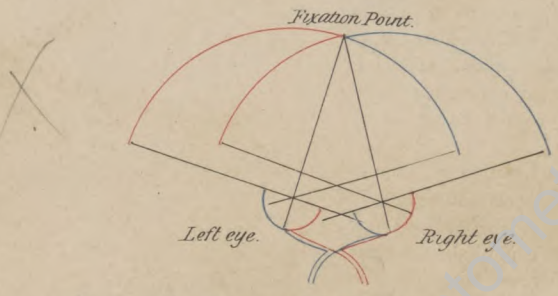

FIG. 112.—THE BINOCULAR FIELD OF VISION. (*After Foerster.*)
The tracts from the *R*ight brain are in *R*ed, those from the *L*eft brain are in b*L*ue. The corresponding retinal halves and their fields of vision are correspondingly colored.

of man's will, and is not, therefore, like the other eye-movements, started by an impulse from the cerebral cortex. Consequently the pupil remains active, even if a person is blinded (psychical blindness) by disease of the cortex of both occipital lobes. In such a case light stimulation is carried from the retina through these fibers to the anterior corpora quadrigemina, from there transferred to the anterior nuclei of the oculomotorius, and, finally, to the iris muscle, by means of the oculomotorius nerve.

The retina has its own vascular system. It is supplied with blood from the arteria centralis retinæ, a small branch of the arteria ophthalmica entering the optic nerve from below about *15 mm.* behind the eyeball. Beginning at the disc the central artery branches out over the retina (*Fig. 51*). After the blood has passed through a network of the very finest capillaries it returns through the retinal veins into the vena centralis retinæ, which runs beside the artery in the optic nerve. With the ophthalmoscope the retinal vessels can be seen through the eye's refractive media, and on account of the refraction of these media they are actually magnified. The magnification is not enough, however, to make visible the blood-current within the vessels, although this is the case in

[1] Vesal thought he had proved this partial decussation by demonstrating a bundle of fibers that had no decussation in their course.

the vessels of the frog's vitreous. The pulse beat can be easily perceived in man. The venous pulse is common and is to be considered a physiological phenomenon. It is seen at the centermost end of the retinal veins, where they bend at right angles from the surface of the nerve sheath, to disappear within the optic nerve; this pulse appears as a regular paling and reddening of this central portion of the vein. The observer has the impression that the blood stream is at each stroke dragged back toward the periphery. This paling of the veins is not synchronous with the radial pulse or the cardiac systole, but pre-

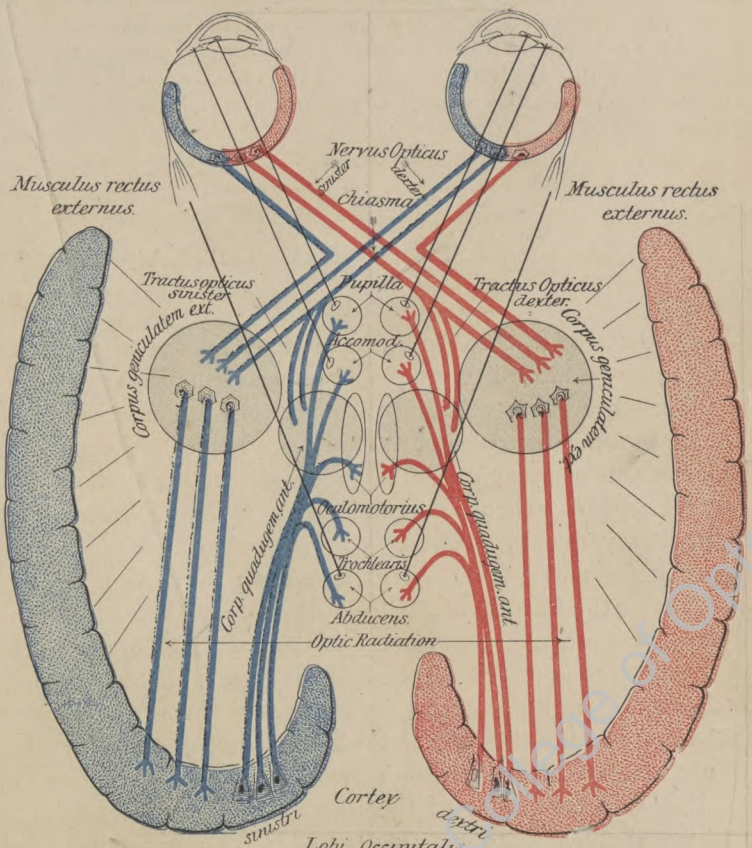

FIG. 113.—SCHEME OF THE OPTIC TRACTS. (*After v. Monakow.*)

cedes them. The cause of this venous pulse is not yet fully explained. A visible arterial pulse can be obtained by continuous but gentle pressure upon the eyeball. This is not by any means, as is the venous pulse, confined to the center of the papilla, but may be followed as a regular swelling of the arteries far out upon the retina; this swelling makes on the observer the impression as of an impulse in the direction of the vessels. The phenomenon is explained by the fact that under increased internal tension the blood pressure in the arteries is not enough to effect a continual flow of blood, but that rather the stream goes in spurts only at the moment of the cardiac systole. An arterial pulse is

Digitized by the Illinois College of Optometry

therefore always pathological and signifies a lack of equilibrium between arterial blood pressure and internal tension in the eye.

It is due to this visibility of the retinal vessels that we can recognize with the ophthalmoscope certain diseases of the general system, such diseases in which the vessel walls, or the amount, character, and distribution of the blood have undergone changes. It must, therefore, be an inviolable rule to examine kidneys, blood-vessels, and heart, as well as other structures of the body, whenever this pathological sign is revealed by the ophthalmoscope. It may happen that the physician thus recognizes a mortal disease in a patient who has sought advice on account of some apparently transient disturbance of vision.

It must be a rule, also, carefully to examine the nervous system whenever the ophthalmoscope reveals anything pathological in the optic disc, since diseases of the brain and spinal cord very often affect the optic nerve sympathetically, or, indeed, make their first visible impression there.

A. DISEASES OF THE RETINA.

1. HYPEREMIA.

This is detected at the disc by an increase in size of the retinal vessels and by a more lively diffused redness, the capillaries of the retina itself being too thin and their network too expanded to influence essentially the color of the fundus. The enlargement of the vessels consists in an increase in thickness, detectable by their darker color and broader reflex, and in an increase in length, detectable by their greater varicosity. There is a hyperemia from stasis and a hyperemia from irritation. *Stasis hyperemia* depends upon some hindrance to the flow of blood from the retinal veins; they are, therefore, broadened and varicose. If the supply of arterial blood is at the same time restricted, the arteries appear thinner and more stretched out than normal, and the contrast between the thickness of the veins and the thinness of the arteries becomes then particularly noticeable. The diagnosis of retinal hyperemia is often very difficult, because the color of the disc and the appearance of the retinal vessels have quite wide limits within the normal, just as the young have, on the average, redder cheeks and papillæ than have the old. In case only one eye is affected, it is advisable to compare one eye with the other, paying especial attention to the entrance of the vessels into the optic nerve. The disc is usually very bright in the healthy eye, and any hyperemia present is therefore most easily detected at that location.

Irritation hyperemia is usually an accompanying sign of inflammation of the cornea, iris, or even of the conjunctiva; it may be a

Digitized by Illinois College of Optometry

sign of disease of the retina itself. In other and not uncommon cases, it is an independent disease due to abuse of the eyes. Persons suffering from refractive errors, weakness of the internal recti, an old conjunctival catarrh, are especially prone to retinal hyperemia. The symptoms produced by it consist in sensitiveness to bright light, exhaustion on continued nearwork, pain and a feeling of pressure within the eye, and nervous asthenopia.

Treatment demands the correction of any refractive errors, conjunctival troubles, etc. Protective glasses and rest to the eyes must be advised. Congestion hyperemia is almost always of symptomatic significance.

2. RETINAL HEMORRHAGE.

This is, as a rule, only a symptom, appearing in almost all diseases of the retina. In some cases it has more of an independent nature. Since the tension of the eye presents a natural obstacle to the rupture of an artery, and since the ophthalmoscope shows nothing that is significant of a rupture of a vessel, we may assume that retinal hemorrhages usually result "per diapedesis," and that the cause is to be found in a pathological relaxation of the vessel-wall through which the blood-corpuscles escape. Apart from inflammations already mentioned and from injuries, diapedesis may result from arteriosclerosis, jaundice, pernicious anemia, diabetes, scorbutus, purpura hemorrhagica—in fact, from all conditions that encourage hemorrhage in other organs. A further group of retinal hemorrhages is to be ascribed to occlusion (embolus, thrombosis) by which the blood-current is disturbed and the vessel-wall insufficiently nourished. The form of the blood-clot differs according to the retinal layer in which the hemorrhage occurs. In the innermost layer the clot is spread out in the direction of the nerve-fibers, and is therefore marked by meridional striations. In the middle and outer layers the blood follows the supporting layers of Mueller's fibers perpendicular to the retinal surface, and appears to the observer, therefore, as a round or irregularly bordered blotch. The age of the clot may be estimated from its color, a fresh hemorrhage appearing bluish-red on the bright red background of the fundus, older clots being rather brownish-red.

The number and size of the hemorrhages differ decidedly in different cases. If they are seen in an otherwise normal fundus a "retinal hemorrhage" may be diagnosticated. If, on the other

Digitized by Internet Archive in Ophthalmology

hand, the retina and disc are hazy, or if other white blotches are to be seen, it is called "*retinitis hemorrhagica.*" In either case there is, strictly speaking, only one pathological lesion, the question still remaining as to the cause, from which alone the real disease and the future of the patient can be clearly determined. In the majority of cases arteriosclerosis or some heart disease can be demonstrated, and this may without further evidence be set down as the cause of the retinal hemorrhage, particularly if it happen to be on one side only.

The prognosis is unfavorable, since a cerebral hemorrhage is apt to follow a retinal hemorrhage sooner or later. The visual disturbance depends upon the location and size of the clot; it may be of little consequence if seated in the periphery. As the blood is absorbed the visual disturbance may disappear altogether. The occurrence of multiple hemorrhages may have a bad local prognosis, since they may be advance symptoms of a hemorrhagic glaucoma, which nearly without exception ends in blindness.

Treatment must be directed to the maintenance of the patient's health. Locally, a pressure bandage should be used to encourage absorption. Of course the eye must be kept at rest.

3. INFLAMMATIONS.

The retina is little inclined to idiopathic disease. Its inflammations are almost always due to some disease of the general system, the nature of which produces a corresponding change in the retina, so that it is at times possible to infer from the ophthalmoscopic picture whether the retinitis is albuminuric, leukemic, or syphilitic. In other cases, to be sure, the ophthalmoscope shows nothing diagnostic, while it does infrequently happen that the fundus changes of one disease are due to another of entirely different origin. The condition discovered by the ophthalmoscope is, therefore, but an indicator; the actual diagnosis must be sustained by systematic evidence of albuminuria, diabetes, or of syphilis.

(*a*) **Retinitis Albuminurica.**—This disease is almost always bilateral. Light-sense, color-sense, and field of vision remain unchanged. Visual acuity is in some cases unaffected, so that the kidney disease is first recognized, the retinal inflammation later. In other cases vision is slightly disturbed, fine print seeming to be read through a veil; but in others again, it is difficult even to count fingers. Complete blindness is not produced, for though it occa-

Digitized by Union College Library

sionally occurs, it is not due to the retinal changes but to uremia (uremic amaurosis, *q. v.*). In a disease which extends over months or years, the ophthalmoscopic changes differ obviously in its various stages. All stages, however, have this in common, that *the changes in the fundus are confined to the posterior pole and a region beyond it of 3 to 4 papilla breadths.* At first there is hyperemia and haziness of the disc, occasionally hemorrhages in the nerve-fiber sheath, which are therefore striated and arranged like spokes radiating toward the papilla. As the disease advances there are seen white spots arranged in circles about the papilla, leaving the macula lutea

FIG. 114.—PAPILLO-RETINITIS IN BRIGHT'S DISEASE. (*After Liebreich.*)

free, however; but the latter is marked by very fine white dots, giving the darker macula the appearance of being specked with white paint (*Fig. 114*). These specks form a star-figure, at the center of which lies the fovea centralis. They are areas of Mueller's supporting fibers infiltrated with fat. The large white spots are areas of the two granular layers that have undergone fatty degeneration. During the last stage of the disease the hemorrhages and fatty foci disappear as the signs of atrophy become evident—paleness of the disc and contraction of the vessels. The last stage is seldom reached before the patient dies.

Digitized by Illinois College of Optometry

Albuminuric retinitis may at times be evidenced, not by the white spots and few hemorrhages, but by congestion and redness of the disc, a true papillitis (*Fig. 114*); or by numerous hemorrhages scattered over the whole fundus, a retinitis hemorrhagica. It must be stated, too, that hemorrhages and hyperemia may both be present with the fatty foci.

The intimate connection between kidney and retina is not quite clear. Many assume that the retinitis is caused by the nephritis; others—Michel, for example—declare that both diseases have the same pathological basis, a hyaline degeneration of the vessels of the choroid and retina, and of those of the kidney.

The prognosis is unfavorable, less for visual acuity than for life. Retinitis albuminurica is seen oftener with the contracted kidney (nephritis interstitialis), a chronic disease leading to death within a few years. Even in these cases a temporary improvement in the retinitis is not impossible. If retinitis albuminurica appears during acute nephritis, the retina may become normal again if the kidney trouble is cured.

Treatment must coincide with that for the original disease; systematic diaphoresis, with plain milk diet, will perhaps give the best results.

(*b*) **Retinitis Diabetica.**—The most general sign of retinal inflammation produced by glycosuria is hemorrhagic retinitis. The second and very common sign is opacity of the vitreous, which probably is due to hemorrhage within it. Less common signs are white spots that may present a picture similar to that of a retinitis albuminurica. The ophthalmoscope alone, therefore, is not able to establish the diagnosis. Hirschberg has lately declared that there is a form of retinitis diabetica not to be confused with other retinal inflammations, especially retinitis albuminurica. He calls this form *retinitis centralis punctata diabetica*. The most important signs are:—

(1) Non-involvement of the optic-nerve sheath;

(2) Numerous and very small white dots at the macula lutea and its immediate neighborhood;

(3) Numerous and very small punctate and striate hemorrhages between these white dots and outward from them.

Of course the discovery of such a fundus by no means releases us from the necessity of examining the urine. The disease is bilateral, although not the same in both eyes. The visual acuity and prognosis are that of albuminuric retinitis, although there are, especially in elderly persons, comparatively mild forms of glycosuria. The **treatment** is not quite so hopeless. A diet of meat and fats, bodily hygiene, muscular exercise, a course at Carlsbad, may remove the sugar from the urine and inhibit, if it cannot cure, the disease.

(*c*) **Retinitis Leukemica.**—In pronounced cases of leukemia the changed character of the blood is to be detected by the noticeably pale color of the fundus. Instead of being red or reddish-brown it looks yellow; the retinal arteries are pale yellow, the veins

Digitized by the Internet Archive in 2010 with funding from Illinois College of Optometry

pale red, and are accompanied by whitish lines; the retina itself is moderately cloudy. In about one-third of the cases a retinitis is produced, always bilateral. If this appears in the typical form, it is recognized by the circular clots and white, prominent blood-bordered spots, which lie at the periphery of the retina rather than at the neighborhood of the disc. This is, however, not always the case. Retinitis leukemica may assume the character of the hemorrhagic type. The distinction must be made by a microscopical examination of the blood, in which the increased proportion of white and decreased proportion of red blood-corpuscles is demonstrated.

(*d*) **Retinitis syphilitica**, in contradistinction to the three localized diseases, is a diffuse retinal inflammation. It may be either unilateral or bilateral. It is evidenced by a cloudiness of greater or less density, most apparent at the entrance of the optic nerve, the edge of the disc being quite obscured, the cloudiness gradually disappearing only at quite a distance into the retina. It follows the course of the large blood-vessels in the character of white striations obscuring or completely covering them in places. These striations give the ophthalmoscopic picture of a round-cell infiltration in and along the vessel wall. The real periphery of the fundus remains free. Hemorrhages and signs of great hyperemia are usually lacking. If the vitreous is at the same time opaque there is a chororetinitis syphilitica (Foerster); for the prognosis and treatment of which the student is referred to *p. 294*.

4. OCCLUSION OF THE RETINAL VESSELS.

(*a*) **Embolus of the Arteria Centralis Retinæ.**—The retinal vessels form an independent territory in the circulation, there being a connection with the posterior ciliary arteries through capillary anastomoses only at the region of the optic nerve (*Fig. 95, p. 268*). For that reason the nutrition of the retina ceases at any stoppage of the arterior centralis, since there is no anatomical assumption for the development of collateral circulation. The blood would flow back from the veins into the empty retinal arteries and cause a hemorrhagic infarct if it were not that the tension within the eye is higher than the blood pressure in the veins, and that, therefore, the return wave is prevented. The ophthalmoscope shows in a recent case of embolus of the central artery an extreme degree of ischemia, with the papilla pale, the arteries reduced to threads, the veins thinned (but not so conspicuously as the arteries) and pulseless. The retinal starvation produces, within a few hours even, certain visible ophthalmoscopic changes, such as striated cloudiness of the disc and a milk-like cloudiness of the macula lutea in which the fovea centralis is outlined as a blood-red point, the retina being here so thin that the red of the choroid is transmitted; this dark point must be considered as an effect of contrast, not as a hemorrhage. There are, however, small punctate or striate hemorrhages to be found, generally between optic nerve and macula lutea. During the next few weeks the circulation is to some incomplete

Digitized by Illinois College of Optometry

extent restored, the retinal cloudiness and the redness of the fovea centralis disappear, but the evident signs of atrophy develop; the disc is pale and the vessels persist only as thin white lines. It is easy to imagine the effect of an embolus on the visual acuity! At the moment of the accident the circulation stops, vision ceases, the eye is blind. This may happen so instantaneously that the patient in full health stoops to pick up an object, only to find himself blind when raising up again. There may be a temporary improvement during the succeeding weeks, but the result is incurable blindness, amaurosis.

The diagnosis of the strange disease depends upon the sudden blindness in one eye, the characteristic ophthalmoscopic image, and the discovery of some source of the embolus, either an endocarditis, an aneurism, some valvular disease, or a new growth in some part of the body; it is not improbable that some fragment may be loosened from new growths and become carried along the blood current. In an examination of reported cases Kern has been able to demonstrate one of these causes in only one-third of them. We must assume, therefore, that in the majority (two-thirds) of cases the circulation is interrupted by some local disease of the central artery rather than by an embolus. We may assume that a thrombus suddenly results from an endocarditis (due to syphilis, arteriosclerosis, or nephritis), and have the same mechanical effect as an embolus. We must recall v. Graefe's theory, too, that a severe inflammation of the optic nerve with the associated compression of the artery with it, may simulate embolism.

(*b*) **Embolism of individual branches of the retinal artery** has been often observed and described. At the spot where the embolus lies the artery appears swollen and spindle-shaped; beyond it, the artery is thread-like, thin, and empty. The conditions for the production of a hemorrhagic infarct are, of course, much more favorable than in stoppage of the main artery, and consequently there are apt to be numerous hemorrhages within the territory of the occluded branch; there is also cloudiness of the retina and the final atrophy. The condition corresponds to that of "retinitis hemorrhagica," and Leber may be correct in tracing retinitis hemorrhagica to multiple embolism of the finer vessels. The visual disturbance—apart from the immediate but transient obscuration of the central vision—is limited to a portion of the field. If the upper or lower principal branch is occluded, the perimeter shows a lower or upper scotoma. If a branch of the second degree is occluded, a correspondingly situated scotoma in the form of a sector will be demonstrated. If the case is very recent and treated at once, the attempt may be made to drive the embolus into a smaller artery by massage to the eye or by reduction of the internal tension (sclerotomy).

(*c*) **Septic Embolism.**—If the occluding plug consists of or contains bacteria it acts not only mechanically but septically, that is, it produces suppurative infiltration of the

pigment degeneration occurs commonly in members of the same family, and associated with deafness, idiotism or some abnormality, supports the conviction that the patient's parents bear the guilt. Blood-relationship is probably of significance. Syphilis may play its part, and especially congenital syphilis, since choroiditis from it (*p. 294*) may present a condition so similar as to lead to confusion with pigment degeneration. A thorough inquiry into the patient's history may aid in distinguishing the two conditions.

Treatment is futile. The patient must be kept in good health and spirits, and made to look upon the matter as hopefully as possible.

6. DETACHMENT OF THE RETINA.

This implies a detachment of the retina from its natural bed, the choroid. Every retinal detachment begins in a partial manner, and if it increases, it gradually extends until it finally becomes complete (*Fig. 116*). The retina is then attached only behind, to the optic nerve, and in front to the ciliary body, forming a funnel something like a convolvulus blossom.

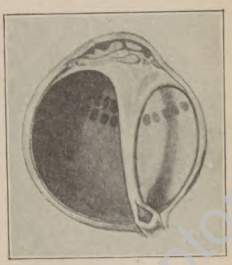

FIG. 116. — PEDUNCULATED RETINAL DETACHMENT. (*After Pagenstecher and Genth.*)

Before the detachment occurs, there are usually such warning symptoms as flickerings, the appearance of sparks, and attacks of momentary blindness. The detachment then takes place suddenly, the effect on the patient being that of a dark cloud before his eyes obscuring the field of vision. The function of the detached portion of the retina is only impaired, but not at first destroyed, for it is still nourished by its own vessels. This detached portion falls in front of the posterior focal point of the (emmetropic) eye, and therefore receives only an indistinct dioptric image, like that of a hyperopic eye at rest. The refractive condition is changed, so much so that in pronounced myopia the patient may imagine his myopia has been cured! The detached portion is not, however, parallel to the posterior focal surface, but is thrown into folds; external objects appear, therefore, bent and distorted—metamorphopsia. This curtain is not quiet, but swings hither and thither at every movement of the eye, because there is fluid before and behind it; objects, therefore, appear to float through each other. These phenomena

disappear after the detachment has lasted some time, since the detached portion gradually fails in function. The perimeter shows a scotoma corresponding approximately in size to the extent of the detachment.

The undetached portion also is usually injured, as may be recognized by the reduction of the central visual acuity and by the torpor retinæ: the sluggish response of the retina to moderate impressions of light. These subjective phenomena vary considerably, since the detachment changes its position as a rule. If, as usually is the case, the retina was first detached above, it separates gradually downward, the upper retinal half becomes again attached, its function returns, and, after the appearance of sparks and such like phenomena of light, the lower retinal half is partly and later entirely incapable of functionating.

Detachment of the retina is demonstrable objectively if the ophthalmoscope shows in the fundus a membrane marked like the retina with blood-vessels. The color of the prolapsed retina is from white to bluish-gray. Pigment can seldom be seen, as the pigment epithelium remains, as a rule, adherent to the choroid. The surface of the detached portion of the retina is thrown into many folds after having such regular striæ that it looks like a series of steps; it waves to and fro as the eye is moved; sometimes a rent with inverted edges may be found. The vessels appear very dark, nearly black, and have no reflex; where they pass over a fold they seem to be broken off. This picture may be confused by vitreous opacities that are to be discovered to some extent in nearly all retinal detachments. The tension is probably, and in old cases certainly, reduced.

Detachments of the retina occur in various diseases. In injuries, both old and new, for example—in the latter case there being the traction made by cicatricial tissue that has developed within the eye. Chronic inflammations of the eye or of the retina alone may lead to a detachment. The most common cause is, however, disease of the choroid and indirectly of the vitreous, resulting from pronounced myopia. New growths (sarcoma, tubercle) and parasites (*q. v.*) must be thought of. If none of these causes can be discovered we must call it an idiopathic detachment, which only means that we do not know the cause. We may assume that occasionally a thread-worm or some other parasite has caused the mischief.

Digitized by Union College of California

The mechanism of a detachment is not yet quite clear, in spite of numerous and painstaking investigations. The conditions after an injury are the easiest to explain. If, in a cataract extraction or any other opening in the eyeball, some vitreous escapes, the eye's tension falls, and the retina, being no longer pressed against the choroid, there is nothing to prevent a hemorrhage due to the injury from taking place behind the retina and pressing it forward. If any disease of the vessel walls predisposes to hemorrhage, a loss of vitreous may not be necessary, the sudden reduction in tension due to escape of aqueous sufficing. It is, therefore, a good rule, where performing an iridectomy for glaucoma, to allow the aqueous to escape very gradually. Even if the capsule is not opened, a sudden blow (champagne corks striking the eye!) may cause small hemorrhages behind the retina and a subsequent detachment. Strange to say, the tension is reduced after such an accident. The opposite would be expected, since a hemorrhage behind the retina, even of only a few drops, would increase the contents of the eyeball. In the same way increased tension would be expected in detachments due to other extravasations (serum or pus) behind the retina. Except in the case of new growths, however, such is not the case. Leber has attempted to explain this apparent contradiction as follows: the ultimate cause of a detachment of the retina is usually a contraction of the vitreous; this results in a vitreous detachment, leaving between contracted vitreous and retina a space filled with serum (*Fig. 138*). But the atrophic connective-tissue fibers of the vitreous are in some places adherent to the retina, and in contracting they drag the retina with them to produce a retinal detachment or laceration. The fluid in front of the retina can now pass behind it through the laceration and so increase the detachment.

This theory is, for the present, antagonized by the "diffusion theory." If an eyeball is preserved in alcohol, a retinal detachment always takes place. This is explained by the fact that the alcohol penetrates the retina and extracts water from the vitreous; the vitreous, therefore, contracts, while the fluid between retina and choroid increases, the result being to push the retina into the space occupied by the vitreous. The basis of the diffusion theory lies—

(*1*) In the fact that the fluid found behind the prolapsed retina is always quite albuminous, although the vitreous has only a trace of albumin (1 : 1000); and

(*2*) In the fact that a retinal detachment can be produced artificially by injecting sodic chlorid solution into the vitreous, while the exposed choroid is simultaneously dipped into a solution of albumin.

The philosophy of the matter seems to be this: some chemical change in the vitreous, not yet understood, but probably demonstrable by the ophthalmoscope as "fluidity of the vitreous" (*q. v.*), proves the starting-point. The diffusing "vitreous salts" cause a very albuminous fluid to collect behind the retina; since, by diffusion, more and more of the ingredients of the vitreous collect behind the retina, it is pushed more and more inward till it finally gives way.

In support of the diffusion theory, and in opposition to that of Leber, Raehlmann has introduced a number of clinical and pathological facts. Clinically, for example, it is known that: retinal detachments occur not only in eyes of reduced and of normal, but also in eyes of increased (glaucomatous) tension; they may occur suddenly, at night; they not infrequently progress downward (a solution of albumin being specifically heavier than vitreous); and that the prolapsed retina attaches itself again and heals in place if the albuminous exudate is absorbed. Pathologically, it is known that fibrillary vitreous contraction and adhesion between vitreous and retina have not been demonstrable in all cases of retinal detachment, and that demonstrable atrophy of the vitreous has not always been attended by a retinal detachment.

Digitized by Illinois College of Optometry

The prognosis depends upon the cause. Relatively, the best case is that due to a parasite in the eye, since its early extraction may effect a cure. It is very grave in pronounced myopia, since one eye after the other is attacked in spite of all precaution, and blindness becomes unavoidable. If the cause is undiscoverable, the outlook is bad. The prognosis is very grave in sarcoma and tuberculosis (*p. 296*).

Treatment, too, depends upon the cause. If the cause is unknown, or if there is nothing particularly to attack, we should try prolonged rest in bed with pressure bandage, and salicylate of sodium (to 4.0 grams daily), or muriate of pilocarpin (to 0.02 gram daily), with the hope of obtaining their resorptive action through the diaphoresis they produce. If no result shows itself, an operation may be thought of. Sichel recommended puncture through both exterior membranes in order to allow the subretinal fluid to escape. Schœler injects a few drops of tincture of iodin into the vitreous in front of the prolapsed retina. Sichel's principle is about as easy as Schœler's is hard to understand. Both are reported to have given brilliant results—and very bad ones as well, for the injection of iodin has caused death. It is hard to estimate the value of these methods, since it not infrequently happens that the prolapsed retina becomes again attached with no treatment whatever, and occasionally a cure is thus obtained.

7. GLIOMA RETINÆ.

The connective tissue of the central nervous system is called neuroglia; as the retina is morphologically a part of the brain, its connective tissue also is neuroglia. A tumor developing from the cells of this neuroglia is called a *glioma*. It is soft and rich in blood, having a great resemblance histologically to a sarcoma, for it consists, as do sarcomata, almost entirely of small round cells with a large nucleus and but little protoplasm, having a very trifling amount of connective tissue. Gliomata belong with sarcomata among the malignant growths. The glioma has, therefore, been called a neuroglia-sarcoma.

A glioma usually begins as a flat nodule in one of the inner retinal layers, most frequently the inner granular layer. As this nodule grows toward the surface it reaches the exterior of the retina and produces a detachment—the more common occurrence; or it grows toward the vitreous and projects into it as a lump or promi-

Digitized by Illinois College of Optometry

nence. From now on all the signs of an eye tumor become evident, as have been described under Sarcoma of the Choroid (*p. 297*). Glioma has much in common with this disease: blindness, perforation of the wall of the eye, involvement of neighboring tissues, metastasis to other parts of the body, and the final death. There are, however, some differences depending less upon the nature of the tumor than upon the fact that glioma occurs nearly without exception in children from one to four years old, sarcoma attacking adults from forty to sixty.

The *first* stage of the disease is apt to be quite overlooked, since small children take no notice of the early subjective symptom—visual disturbance. When the tumor or the detached retina has come so far forward that the light reflected from it is visible as a bright shimmer in the pupil, the parents themselves notice it, and then they find that the eye is already blind.[1]

The ophthalmoscope shows a reddish or yellowish-white prominence surrounded by small, pale yellow nodules; numerous well-dilated retinal blood-vessels converge toward this tumor. Beyond it the retina may appear either normal or prolapsed.

In the *second* stage, increased tension with its consequences approaches (*p. 298*) slowly at first, because of the elasticity of the juvenile sclera; or there may be the signs of internal inflammation, opacity of the cornea and aqueous, occasionally posterior synechiæ, dilatation of blood-vessels in the conjunctiva and lid; the cornea may ulcerate, and after perforation takes place the eye may collapse. But this condition does not last very long. After a longer or shorter interval the tumor grows more rapidly and escapes through the perforation or makes a way for itself through the sclera. Thus the *third* stage begins. The tumor now appears between the lids as a spongy, bleeding mass, ulcerated on the surface—*exophthalmia fungosa*. It extends also in the optic nerve backward toward the cranial cavity. If the chiasm becomes involved the blindness may be bilateral. The *fourth* stage, that of metastasis, now develops in the neighboring bones and lymph-glands. In about 18 per cent. of all cases a glioma develops in the second

[1] The name "Cat's-eye" is sometimes given to this. In the cat, light is reflected outward from a choroidal layer called the *tapetum cellulosum*, and the eye may shine if the pupil is wide enough. Blindness, with illumination from the pupil, may, however, arise from other conditions, and the term cat's-eye should not be used as a synonym for glioma retinæ.

Digitized by Illinois College of Optometry

eye, but is to be considered as an independent growth, not a metastasis.

The diagnosis is easy after the second stage has been reached. There may be some confusion in the first stage, most commonly with chronic suppurative choroiditis (pseudo-glioma), arising often from a meningitis or cerebro-spinal meningitis, or from abscess of the vitreous. It should be observed that in choroiditis there is first inflammation with subsequent blindness; in glioma the reverse is the case; in choroiditis the eye is soft, in glioma hard; and in glioma the ophthalmoscope reveals the swollen, protruding nodules. If a diagnosis is impossible—supposing the eye to be blind—it is best to treat it as if a glioma were present, since it is no great calamity to enucleate an eye already blind, but to neglect or to postpone the **treatment** (enucleation) in glioma may cost the patient his life.

8. INJURIES.

Injuries to the retina are, as a rule, combined with injuries to other parts of the eye, and are therefore mentioned again under Diseases of the Eye as a whole (*q. v.*). Only two particular varieties are discussed here.

(*a*) **Commotio Retinæ** (Berlin).—After an injury to an eye by a blunt instrument the retina becomes cloudy at and in the vicinity of the disc at first. This cloudiness is demonstrable soon after the accident, increases during the next day, and reaches its height twenty-four to thirty-six hours afterward, subsiding slowly in about three days. This is probably due to an edema of the retina dependent upon hemorrhage between choroid and sclera. Visual acuity declines to $\frac{15}{40}$ or $\frac{15}{100}$, light perception is reduced, and there are dark spots in the field of vision. There are, besides, other signs of the injury, such as hemorrhage in the anterior chamber, contraction or dilatation of the pupil, and episcleral injection.

Prognosis is favorable. **Treatment** need be limited to a mere removal of all chance of irritation to the eye.

(*b*) **Dazzling.**—An eclipse of the sun can be looked at without danger only when a well-smoked glass or an arrangement of glasses of complementary colors is held before the eye. This rule is, however, again and again neglected, and it happens after every eclipse that the ophthalmic surgeon is consulted by patients who have been injured by looking at the sun with the naked eye. They

Digitized by Illinois College of Optometry

complain that there is a dark spot before their eyes and that they cannot see distinctly. In the severer cases the ophthalmoscope shows a grayish spot in the center of the macula lutea. In the eclipse of 1890 Haab saw eight such cases; in three of them the grayish spot was a true optogram of the sun, on which could be distinctly seen an impression corresponding to the round disk of the moon. It is supposed that the gray spot results from coagulation of albuminous corpuscles. In the milder cases the disturbance subsides, but in the severer form a permanent scotoma remains. **Treatment** consists in rest and confinement in a dark room.

9. CHANGES DUE TO AGE.

(*a*) **In the lamina vitrea of the choroid,** see *p. 301.*

(*b*) **Senile disease of the macula** is a rather common occurrence, and destroys many a surgeon's and patient's hope of the success of a cataract operation. It consists of bright, yellowish-red spots lying in a black dotted field. These spots become white later on. The visual disturbance is excessive, much greater than in other senile changes near the macula lutea.

10. MEDULLATED (OPAQUE) NERVE-FIBERS.

These are almost always discovered accidentally by the ophthalmoscope, since they cause no symptoms and, at least in the vast majority of cases, no visual disturbances. An eye in which they have been found owes its subnormal visual acuity to refractive errors or other pathological conditions, but in a perimetric examination a scotoma or an enlarged Mariotte's spot will be discovered, the edges of which correspond to the area of the opaque nerve-fibers.

The characteristic ophthalmoscopic image is the following: Upward or downward, seldom inward, and very rarely outward, from the papilla, there are seen white, striated blotches with fringed edges; these take preferably the direction of the principal vessels. They may be confounded with pathological changes (fatty deposits, etc.), only when they are not contiguous to the disc (an exceptional though recorded appearance), but are separated from it by a distinct interspace. Even then the reflection from the nerve-fibers, the striation, and the flame-like shape of the figure ought to be characteristic enough. Retinal vessels course over the fibers, or sometimes dip in among them, appearing then as if broken off. The phenomenon arises from the fact that part of the fibers of the optic nerve retain their opaque medullary sheath for a short distance after passing through the lamina cribrosa of the sclera. The condition is an anomaly of development, and is usually associated with some abnormality of the skull, or of the spinal column, and with squint. In the retina of the rabbit, medullary nerve-fibers are normally present.

Parasites are discussed later, under Entozoa.

Digitized by Illinois College of Optometry

B. DISEASES OF THE OPTIC NERVE.

1. CHOKED DISC (STAUUNGSPAPILLE).

This begins with an indistinct hyperemia and moderate cloudiness of the edges of the disc. Gradually, swelling and opacity become evident in the disc and its immediate neighborhood. As the disease develops, the following ophthalmoscopic image is found:[1] The papilla seems decidedly larger than normal; it projects into the vitreous, as may be proven by using the "parallax test" in examining different sections of the same vessel (*p. 135*); its edges are abrupt, but not well defined against the surrounding retina; the color is reddish-white, the striations spoke-like; the arteries are narrow, and indistinct or invisible toward the disc; the veins are dark, dilated, and tortuous, beginning at the disc with a pale-pointed end; at times small hemorrhages are present at the edge of the disc.

FIG. 117.—MERIDIONAL SECTION THROUGH A CHOKED DISC. (*After Pagenstecher and Genth.*) The swelling subsides abruptly at the right, gradually at the left.

After this condition has lasted a long time, often for months, there begins a gradual recession, characterized by increasing paleness and flatness of the disc.

Choked disc of itself does not cause visual disturbance. It is due less to inflammatory round-cell infiltration than to the dilatation of the vessels, the saturation with serum, and the thickening (hypertrophy) of the non-medullated nerve-fibers. The most recent investigations have, however, shown that actual inflammation is never quite lacking; in any case there is bound to be, sooner or later, an infiltration with round cells and hypertrophy of interstitial tissue (*Fig. 117*). This new-formed tissue finally shrinks and by its

[1] *Fig. 114, p. 309*, papillitis nephritica, gives at the same time a good illustration of a choked disc.

Digitized by the College of Optometry

pressure causes the atrophy of the nerve-fibers. Impairment of vision is the result, passing slowly into total blindness. This impairment is detectable as :—

(1) Diminution of central visual acuity;

(2) Contraction of the visual field, unsymmetrical;

(3) Color blindness or dullness.

Diminished visual acuity comes gradually, but may be occasionally exaggerated by attacks of amblyopia, or even of blindness, which may not always subside completely.

Choked disc is almost always bilateral and usually the result of a brain tumor.

There has been plenty of discussion concerning the relation between a tumor in the cerebral cortex, or even in the cerebellum, and choked disc. Just at present two theories contest for the honor of being the only satisfactory explanation—the mechanical and the inflammatory theory. According to the mechanical explanation the tumor raises the accustomed pressure in the skull; cerebrospinal fluid is consequently driven forward between the sheaths of the optic nerve and a "hydrops of the nerve sheaths" is produced (*Fig. 118*). The serous saturation of the nerve-fibers, once they reach the constricted network of the lamina cribrosa, produces a pressure that prevents the return of the venous blood, and thereby produces the stasis. This theory seems to be continually losing ground before the inflammatory theory. Numerous pathological examinations have shown that choked disc is a regular and early sign of simple inflammation in the head of the optic nerve; that histological evidence of inflammation is regularly found, not only in the optic nerve head, but also in the optic nerve itself, in its membranes, and even at times in the retina. Now, to establish the relation between the inflammation with inflammatory edema—that is, between the causative brain lesion and the choked disc—the assumption is made that germs or some chemically acting material is carried by the lymph-current from the brain to the papilla, where its destructive influence is developed.

FIG. 118.—NEURITIS OPTICA WITH HYDROPS OF THE OPTIC-NERVE SHEATHS. (*After Pagenstecher and Genth.*)

This inflammatory theory does not, however, explain everything. Particularly does it leave unsolved the question why the inflammation of the optic nerve head is so regularly productive of choked disc when the causative lesion is a new growth in the brain, but is only exceptionally so productive when this inflammation of the optic-nerve can be traced to a parasite in the brain, to a cysticercus or an echinococcus, to hydrocephalus, to a brain injury or abscess, or to any other inflammation of the contents of the skull.

Unilateral choked disc is usually caused by tumor or inflammation within the orbit. The diagnosis is easy, since there is present, in addition to the onesidedness of the fundus change, the condition of exophthalmos on that side. It must be borne in mind that in rare cases retinitis albuminurica (*p. 308*) runs its course with the signs of choked disc.

Prognosis is unfavorable. Cerebral tumors generally end in death after months or years. The picture may meanwhile change

from that of choked disc to that of optic-nerve atrophy. New growths lying on the surface and admitting of accurate localization may be reached by operative treatment.

Treatment.—If the new growth is a syphilitic gumma, mercury and iodid of potassium may effect a transient if not a lasting cure. The choked disc will, of course, subside, but the visual acuity will be permanently impaired.

2. INFLAMMATION OF THE OPTIC NERVE (Neuritis Optica, Papillitis).

It is not always possible to distinguish this disease from choked disc by the ophthalmoscope. In neuritis optica the papilla is seen to be swollen and clouded (*Fig. 114*). The swelling is less than in choked disc, and consequently extends further and in a flatter manner into the retina, so that the observer misses the decided effect of a prominence. The arteries are only slightly, or not at all, contracted, the veins are dilated and tortuous. If the opacity extends noticeably into the retina, usually along the vessels, the condition is called *papilloretinitis*. In chronic papilloretinitis hemorrhages and white spots are found in the retina, an appearance similar to that of retinitis albuminurica. Confusion may be easily avoided, however, by observing that in neuritis optica the more intense changes are seen at the disc, while in neuritis albuminurica they usually are greatest in the retina. In doubtful cases the necessary examination of the urine will, of course, decide.

In many cases there are seen along the vessels peculiar, glittering reflexes that move as the mirror is rotated and give a satin-like appearance to the fundus. The phenomenon may be observed in children having no pathological manifestations, but it is always suspicious if there is any visual weakness in addition.

The visual disturbances (amblyopia, constriction of the field of vision, impaired color-sense) differ in different cases and have no exact relationship to the visible objective changes. The disease affects the entire optic nerve, while the ophthalmoscope can give us information only of the peripheral end of it. It is a general rule that—

(1) Visual disturbances appear earlier than in choked disc, and

(2) The disease leads to atrophy of the nerve and to blindness oftener than does choked disc.

Inflammation of the optic nerve is, in the majority of cases, an

Digitized by the Internet Archive

extension from some lesion of the brain and its membranes; it was therefore called by Graefe *neuritis descendens*. Tubercular basilar meningitis of children, epidemic cerebrospinal meningitis, meningitis from suppurative otitis and from other infectious diseases, may all be considered causes. Infectious diseases, syphilis, and systemic intoxications may cause an optic neuritis directly.

The pathological evidence differs according to the cause. In tubercular basilar meningitis, tubercles have been found in the three membranes of the nerve. In suppurative meningitis the characteristic is an abundance of pus cells in the intermembranous spaces and in the connective tissue of the optic nerve. In syphilitic neuritis there is an extraordinary thickening of the optic nerve, occasioned by hypertrophy and cell infiltration of the interstitial connective tissue and of the pial sheath.

Besides these optic-nerve inflammations from a known cause, there are others, the cause of which is unknown. To these belong "neuritis from heredity." It is a fact that the members of many families (males particularly) are attacked between the eighteenth to twenty-fourth years by a bilateral optic neuritis from no apparent cause. The parents may be quite healthy, and there is, therefore, no direct heredity. Even if there were, it would but throw the question one generation back, not answer it. "Optic neuritis from cold" is quite as obscure, and also "optic neuritis from suppression of the menses." With the innumerable cases of "catching cold," and the rarity of an attendant optic neuritis, suspicion must be aroused that it is an already affected (latent) optic nerve, which responds to the cold by becoming inflamed.

There are, too, cases of neuritis optica in which not even a cold or such an intangible cause can be detected. Leber's opinion is that the condition probably rests upon a latent meningitis. There have recently been reported several cases of optic neuritis appearing in young mothers during the weaning period. The assumption has been made from this that during the secretion of milk some poisonous albuminoid by-product has been originated, which caused an optic neuritis by autoinfection of the mother.

Prognosis is doubtful; cures with restoration of normal visual acuity, cures with amblyopia of every degree, and, finally, a lapse into total blindness have all happened.

Treatment must depend on the cause. If this is not discoverable, diaphoresis or mercury and iodid of potassium may be tried.

Digitized by the Internet Archive of Ophthalmology

Some claim good effects from blood-letting from the temporal or mastoid region by means of Heurteloup's artificial leech. The reports of results of such treatment encourage the suspicion that mild cases may get well of themselves.

3. RETROBULBAR NEURITIS.

If the optic nerve beyond the bulbus becomes inflamed, the disc is not necessarily, certainly not immediately, involved. At the commencement of a retrobulbar neuritis the fundus, therefore, appears normal, or, at the most, slightly hyperemic with moderate haziness of the edges of the disc. At a later stage of the disease there is, however, a very characteristic ophthalmoscopic image, that is, a discoloration of the temporal halves of the papillæ, where the grayish-white is in sharp contrast to the dull red of the smaller nasal halves. This atrophy may advance so far that the lamina cribrosa of the sclera becomes visible.

Under certain circumstances the diagnosis may be made solely from the subjective symptoms, they being often quite characteristic enough for this purpose. The patient complains that he sees poorly, especially in bright daylight, but somewhat better in a dimmer light (*nyctalopia*). If the examination is made by test-type and perimeter, the reduction in visual acuity will be found to depend upon a scotoma at the center of the retina, and that peripheral vision, and particularly the extent of the field, is quite or nearly normal. At first there is only a color scotoma,[1] within this spot green and red appearing gray. As the disease advances, the extent of the color as well as the light scotoma increases, until, finally, there is an "absolute" dark spot. Fixation then becomes impossible, the eye makes uncertain movements hither and thither, and nystagmus results. The field of vision may be gradually obliterated and the disease end in blindness.

The nature of the disease consists of an inflammatory hypertrophy of connective tissue which, by its later cicatricial contraction, causes an atrophy of the nerve-fibers. Uhthoff says that all fibers of a diseased nerve do not perish. At first the disease is confined to the papillomacular fibers (*p. 303*); it is usually bilateral, attacking with great preference men in the prime of life. It may be either

[1] Brauchlis states that besides the central color scotoma there is regularly a contraction of the field for colors.

Digitized by Illinois College of Optometry

acute, in which case blindness may be the result after a few days; or chronic, and then weeks, months, or years may pass before the patient seeks medical advice. In the acute form there is often a complaint of pain deep within the eye, on moving the eye or from pressure upon it.

As causes of neuritis retrobulbaris may be mentioned: acute infectious diseases, syphilis, lead poisoning, cold (?), but all these together are not such disastrous agents as the *abuse of tobacco and alcohol.* The disease is, therefore, often called *tobacco* or *alcohol amblyopia*, or *intoxication-amblyopia.*[1]

As a rule, both tobacco and alcohol are used and abused together, but either one may cause the trouble.

The prognosis is favorable in so far as it is possible in recent cases to promise complete recovery to patients who agree to give up their bad habits; it is unfavorable because one of the worst results of continued abuse of alcohol is to depress the strength of the will. Patients soon relapse, therefore, when they have noticed improvement after some time of self-denial, and after the specter of blindness seems to have been laid for the moment. It is remarkable, however, that even after a relapse from grace the patient's symptoms of neuritis do not always come back again.

Treatment need not be local; abstinence from tobacco and alcohol is quite sufficient. The usual accompanying chronic gastritis must be treated, since most all drinkers suffer from it, and since it is often the exciting cause of the breaking out of the disease. In those few cases of retrobulbar neuritis due to other influences the rules of treatment given on *p. 325* should be followed.

4. ATROPHY.[2]

The visual power of an eye is destroyed if the fibers of the optic nerve in any place become atrophied and incapable of functionating. As far as vision is concerned, it is a matter of indifference whether the atrophy occurs within the orbit or in the optic canal. This is by no means so of the ophthalmoscopic image! If the

[1] Many authors distinguish between intoxication-amblyopia and a retrobulbar neuritis from other causes.

[2] Atrophy really signifies "not nourished," but the characteristic of atrophy is diminution in the size of the elements. The word atrophy is also (not quite correctly) used to designate the condition which, from a standpoint of pathological anatomy, ought to be called degeneration.

Digitized by Illinois College of Optometry

papilla becomes inflamed and subsequently atrophies, the ophthalmoscope reveals a condition recognizable as a disappearance of nerve-fibers and a simultaneous deposit of new-formed and subsequently contracted connective tissue. If, on the other hand, the interruption in the path of the optic nerve is due to inflammation, injury, or pressure upon the nerve behind the eyeball, the papilla appears quite unchanged at first, and only gradually assumes the atrophic look, because the disappearance of the nerve-fibers has taken place only at the inflamed, injured, or compressed spot, and only gradually passes down to the papilla (*atrophia descendens*). The appearance of the papilla is, however, not the same as in papillary atrophy, because at the papilla there is in the former case only the disappearance of the nerve-fibers and blood-vessels, new-formed connective tissue being altogether absent.

Besides papillary and descending atrophy, there is a simple atrophy, in which there has been no inflammation of any part of the optic nerve at all. The condition might be called essential atrophy, that is, a disappearance of the medulla of the nerve and a destruction of the function of the axis-cylinder. Such a nerve appears gray and shimmery—gray degeneration—and is associated with corresponding changes in certain tracts of the brain and spinal cord. This third form presents the same image to the ophthalmoscope as does the descending atrophy. An ascending atrophy is possible, for supposing the retina to become incapable of functionating, the optic nerve would undoubtedly degenerate, and the papilla would, after a time, give evidence of a pure atrophy, assuming, of course, that the papilla is still visible and is not associated with the retina in the disease. For example, after embolus of the central artery there is regularly a simple atrophy, and after albuminuric retinitis a similar condition has been frequently observed.

What are the ophthalmoscopic differences between papillary atrophy and simple or descending atrophy? The color and the presence or absence of "atrophic excavation" (*q. v.*). In papillary atrophy we find the nerve-sheath whitish, its edge hazy, particularly on the nasal side, at times also irregular; there is no difference in the level (*p. 135*) between papilla and retina; the lamina cribrosa is not visible; the retinal vessels are narrow. (If the papillary atrophy follows a retinitis pigmentosa or a choroiditis syphilitica, the disc appears grayish-yellow and waxy.)

In uncomplicated or simple atrophy the disc is of a pure white

or bluish-white color. Since the space left open by the disappearance of the nerve-fibers is not occupied by any new-formed connective tissue, the disc appears sunken, excavated, and allows the network of the lamina cribrosa to be seen. The disc is round, regularly and sharply outlined. The retinal vessels are at first normal.

After this description it is best to study from a clinical standpoint—

(*a*) Simple atrophy, and

(*b*) Descending atrophy.

(*a*) **Simple atrophy,** called also *progressive amaurosis.* The patient notices an early disturbance in vision, because the condition is a bilateral affection. Examination shows that this disturbance consists of diminution in central visual acuity and of contraction of the visual field. The form of the latter varies considerably, being in one case concentrically contracted, in another strewn with irregular scotomata; as a rule, the outer and upper parts of the field of vision are more contracted than the inner and lower parts. Color-sense is early affected, green being lost first, then red, then yellow, blue last. Light-sense is longest retained. The end is total blindness. Objectively, the papilla is seen to be either gray or quite white. This appearance goes hand in hand with the decline of visual acuity and the contraction of the visual field, or may even precede these disturbances of function. There must, then, be some system disease in which the nerve-fibers are equally attacked in their entire course. In descending atrophy the condition is obviously reversed; here the change in the disc, demonstrable by any objective examination, is not visible for months or years after the disturbances of function.

The great majority of all cases is due to some disease of the brain or spinal cord, especially of syphilitic origin: in the brain, disseminated sclerosis, progressive paralysis, and general paralysis; in the spinal cord, tabes dorsalis.[1]

It is necessary, therefore, to make a thorough examination of the brain and cord whenever optic-nerve atrophy is discovered, and the neurologist should be consulted to evolve order out of the chaos of paralysis, anesthesia, paresthesia, and hyperesthesia. In tabes, optic-nerve atrophy is not apparent until the dis-

[1] The nature of the relation between diseases of the cord and brain on the one side, and optic-nerve atrophy on the other, is not exactly known.

Digitized by Illinois College of Optometry

ease of the cord has betrayed itself by other signs and symptoms; the "lightning pains," the loss of patellar reflex, unevenness of the pupils, and ataxic gait, for example. In progressive paralysis, on the contrary, the optic-nerve atrophy is said occasionally to be the first sign, although even in such cases a careful examination may bring to light various mental symptoms, such as hypochondria, irritability, weakness of judgment and of memory. In a number of cases of progressive atrophy of the optic nerve no brain- or cord-lesion can be discovered, and the eye-lesion must be considered as idiopathic. Catching cold (??), excesses, undue physical and mental effort and excitement, as well as syphilis, have all been called causes.

Treatment is unsuccessful, the prognosis hopeless. The continuous electric current is said to have stopped and improved the disease, but nothing has as yet prevented it from resulting in total blindness.

(*b*) **Descending atrophy** requires the more time to reach the papilla and to make itself visible, the more central its origin and the older the affected individual. For example, if a lesion of softening attacks the optical centers in the cerebral cortex, the atrophy descends through the "optic radiation" (*Fig. 113, p. 305*) into the external geniculate body, which, as Monakow has shown, disappears so rapidly that even with the naked eye its decrease in size can be detected. Further on, the atrophy attacks the optic tract, chiasm, and nerve, and after years becomes visible at the disc, if the patient does not die meanwhile. If the causative disease is on the optic nerve itself, where it passes through the canalis opticus, descending atrophy may become visible at the disc within a few weeks. A descending atrophy which has become visible to the ophthalmoscope is, as a rule, therefore traceable to some disease within the orbit, at the canalis opticus, or at the base of the brain. *Within the orbit* there may be injuries or tumors. The diagnosis is supported if the atrophy is unilateral, if there is a history of an accident in one case, or an exophthalmos in another. *At the canalis opticus* syphilitic ostitis and periostitis may so contract the aperture that the nerve atrophies on account of the pressure. *At the base of the brain* inflammations of the sphenoid bone or aneurysms of the internal carotid artery may interrupt the transmission of optic impressions, and hemorrhage near the external geniculate body may lead to softening of the primary optical centers. Of

Digitized by Illinois College of Optometry

course, such lesions will occasion other disturbances of function besides those of sight, and the combination of all the symptoms will aid in the localization of the disease.

It deserves mention that blindness, or at least a high degree of amblyopia, occasionally develops after severe hemorrhage, particularly from the stomach; the ophthalmoscope shows a disc, normal at first, but after some weeks manifesting the characteristic signs of atrophy. The cause of this evident atrophy is explained by many observers as a fatty degeneration; others consider it as an interstitial inflammation of a retrobulbar part of the optic nerve.

The prognosis is not quite so bad as it is in simple atrophy, since many diseases that may cause descending atrophy, as syphilitic periostitis, for example, are amenable to treatment. Atrophic nerve-fibers cannot, to be sure, be restored, but the progress of the atrophy may be cut short, and the visual acuity yet remaining will thereby be preserved.

DISEASES OF THE LENS.

INTRODUCTION.

The lens, lens crystallinea, consists of a transparent material enclosed in an equally transparent, homogeneous capsule. Its posterior surface rests against the vitreous in the fossa patellaris; its anterior surface rests against the posterior surface of the iris (*Fig. 4, p. 27*). The lens possesses an anterior (*b*) and a posterior (*c*) pole (*Fig. 49, p. 118*), and an equator (*d*). At the anterior pole the capsule has a thickness of *0.016 mm.*, at the posterior pole only half as much. The diameter of the equator amounts to about *9 mm.*; the distance of anterior pole from posterior pole, that is, the thickness of the lens, is about *4 mm.*

The first evidence of the lens in the embryo consists of a thickening of the epiblast above the primary optic vesicle (*Fig. 119*). This collection of epithelial cells grows inward and depresses a thin layer of the mesoblast and the anterior wall of the primary optic vesicle. The lens is now hollow, its wall consisting of epithelial cells. The cells of the posterior wall grow forward into the long lens-fibers hexagonal on cross-section, which carry the nucleus (*Fig. 120*) forward along with them. Gradually the hollow of the lens vesicle disappears and the lens now consists of the original posterior epithelial cells changed into lens-fibers, and the original anterior cells still epithelial in character.

The lens capsule is developed at the same time and is considered by some as a derivative of the mesoblast, by others as a cuticular formation from the epithelial or lens-cells. The development of the lens is not completed at birth, but continues till about the twenty-fifth year, during which time the change at the equator from epithelial cells to lens-fibers is still in progress. The anatomical and physical results are explained on *p. 39*.

From the above it is obvious that only the anterior capsule is covered with epithelial cells, and that the normal posterior capsule has no such covering.[1]

[1] Pathologically epithelioid cells are found on the surface of the posterior capsule.

Digitized by Illinois College of Optometry

The lens-fibers, each confined to its own layer, pass from the anterior toward the posterior pole. All the fibers of one layer do not unite at one single point, but pass rather along certain lines, thus producing the so-called sutures at the lenticular poles, visible in the hardened lens as a triradiate figure. In the new-born this is in the shape of a Y, but in later life is much more complicated owing to various branched processes that follow no definite path. The anterior triradiate figure can, in elderly persons, be beautifully seen by means of a lens and focal illumination.

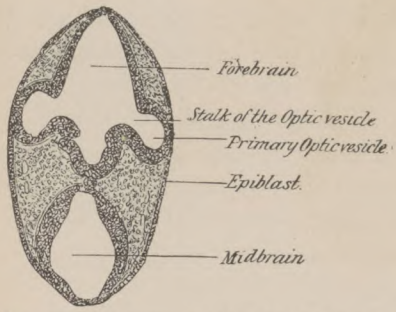

FIG. 119.—BEGINNING OF THE EYE IN A CHICK. (*After Koellicker.*)

The lens in the adult by no means remains permanently in the same condition. Rather is there a continuous change going on, which may be called a nuclear sclerosis (*see p. 38*). This is a change in the oldest and innermost fibers, which from early youth have been growing denser and losing their water constituent, while at the same time the newer layers of the lens periphery are attacked by this sclerosis; the nucleus is constant, therefore, but the outer part of the lens decreases. It may happen that the entire contents of the lens-capsule hardens into a homogeneous substance. A sclerosed nucleus looks like amber.

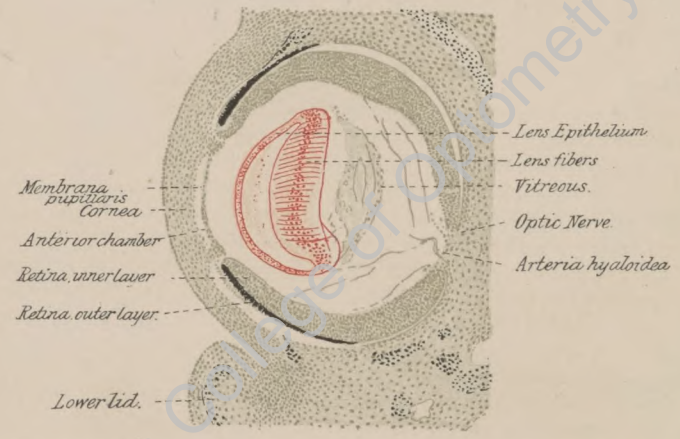

FIG. 120.—DEVELOPMENT OF THE LENS IN A CAT. (*After a preparation by Prof. Stoehr, with one change.*)

The color is the darker, the denser and harder the nucleus. In a large nucleus it may be reddish-brown, and if the entire lens is sclerotic, even dark brown.[1] The color of the nucleus perceptible by focal illumination gives some clue to the size of the cataract.

[1] Obviously the visual acuity is then extremely reduced. This condition is called black cataract (*cataracta nigra*) in distinction to (gray) cataract. In a gray cataract the pupil looks whitish-gray when light is thrown into it, but looks black in a black cataract. The

Digitized by Illinois College of Optometry

The Zonula of Zinn (*Fig. 4, p. 27*, and *Fig. 97, p. 274*) (Ligamentum suspensorium lentis) serves to retain the lens in place; it is a transparent, fibrous, perforated membrane, stretched between the processus ciliares and the lens, passing gradually into the lens capsule, partly in front of, partly behind, partly at, the equator. Between the folds of the zonula is the canal of Petit [1] encircling the equator. This canal is supposed to be filled with a fluid that assists the nutrition of the lens. This nutritive fluid, according to Magnus, surrounds the lens in two engirdling zones, one close in front of, the other close behind the equator. Lymphatics are said to enter at the posterior pole, and to find their exit near the anterior pole, the evidence being based on pathological observations.

I. CATARACT.[2]

Any pathological change in the lens diminishes its transparency. As soon as the smallest area of the lens loses this transparency we call it cataract. Opacities in the capsule are called *capsular* cataract, opacities in the lens substance are called *lenticular* cataract.

A lenticular cataract may be either *cortical* or *nuclear*. If both cortex and nucleus are involved, we speak of *complete* cataract. If cataract is in connection with or is the result of other eye diseases, it is called *cataracta complicata;* if there are adhesions between iris and ciliary body on the one side and the diseased lens on the other, we call the condition *cataracta accreta.*

What influence has such an opacity on the visual acuity? Often no influence, often a very important one, much depending on the size, location, and nature of the opacity. For example, opacities lying in the periphery, and covered by the iris, cause, as a rule, no disturbance whatever. It must not be forgotten that the pupil is at one time dilated and at another contracted, and, therefore, the same opacity may at one time be noticeable and at another be altogether without influence. The influence of the intensity of the

---

pupil in black cataract cannot be illuminated with the ophthalmoscope, the light being so completely absorbed by the lens that it is neither reflected outward nor allowed to pass through onto the retina, as it does normally.

[1] Some authors ignore this canal of Petit, and apply the name to certain bulgings of the posterior chamber. Others, again, call the canal of Petit the space between vitreous and posterior surface of the zonula.

[2] The name cataract (waterfall) comes from the mistaken notion as to the nature of the condition, which was current nearly to the end of the last century. It was thought that cataract was caused by some fluid falling in front of the lens and gradually hardening into a membrane. The German word *Star* is derived from the same source as our stare, originally stiff.

Digitized by Illinois College of Optometry

illumination may be analogously explained. Many patients see better in a dim light; these are cases with an opacity in the pupillary area, the periphery remaining clear. Others see better in a bright light with a contracted pupil; these are cases with an opacity extending toward the pole, but leaving the pupillary area clear.

Opacities at the pole, or on the axis between the two poles, may escape the patient's notice if they are small, dense, and sharply defined, but they may be a great detriment to vision if they include the entire pupillary area in the form of a translucent veil (*see p. 254*, the optical effect of corneal opacities). Even a completely opaque lens does not destroy vision. Although the largest part of the entering light is absorbed by the lens or reflected from it, yet some rays may pierce the lens by the same path they would all take under normal conditions. It is therefore possible for the eye with a cataract, even if it involves the whole lens, to recognize the direction from which luminous rays proceed, and to indicate correctly their origin. We may consequently estimate the visual field and any defects in it, in spite of an opaque lens. Obviously, the disk for testing must be some luminous object, like a candle flame. As a rule, it is sufficient to use the ophthalmoscope for the purpose of throwing light into the eye from various directions and to ask the patient to tell where it comes from. If a correct answer is quickly given, it is assumed that retina and optic nerve are healthy. To be absolutely sure, the patient's light-sense must be tested. An eye with a totally opaque lens ought to be as sensitive to light as a healthy eye with the lids closed. A patient with cataract should recognize in a dark room an ordinary candle flame at *6 m.*, and a very small lamp (that is, a lamp with its wick turned so low that the flame is only a blue color) at *0.3 m.* The play of the pupil must also be noticed; with a normal light perception the eye having a cataract should contract distinctly if light is suddenly thrown into it.

Even colors may be recognized in spite of total opacity of the lens, but the patient may make certain mistakes in naming them if the nucleus is sclerotic and therefore yellow or brownish-red; only such mistakes, however, as a healthy person would make if he should look through yellow or brownish-red glass.

Other signs for the diagnosis of the conditions found within the eye itself are supplied by the ophthalmoscopic examination of the other eye, assuming, of course, that its fundus is visible.

Digitized by Illinois College of Optometry

Objective evidence of an opacity in the lens is at times given by merely looking at the eye. If, for example, the vicinity of the anterior pole is cloudy, the pupil appears grayish-white instead of the normal black. It must not be supposed, however, that every grayish discoloration in the pupil is caused by cloudiness of the lens; it merely indicates that light is diffusely reflected back from the lens, the amount being, perhaps, only the minutest portion of all the entering light, while the largest portion passes unhindered to the retina. Pupils of old persons seldom appear quite black, but usually, especially if they are dilated, the color is gray or a grayish-yellow, the sclerotic lens nucleus reflecting some diffused light back again. *We are justified in assuming an opacity only when a distinct area in the lens appears gray or white to light thrown onto it, and black to light thrown through it.* The examination for the former appearance is made by focal illumination (*p. 98*); for the latter appearance by the ophthalmoscope (*p. 118*).

To bring the whole lens completely under observation it is necessary to dilate the pupil with cocain or homatropin, although even with their aid the extreme edge may still be invisible. In eyes on which there has been performed an iridectomy extending to the periphery, the edge of the lens is perceptible, as a rule looking like a golden ring under focal illumination, and like a broad, dark band under transillumination with the ophthalmoscope.

Cataract is seen at all ages, but by far the most frequently in old persons, next in young infants, and most rarely in the prime of life. The probability of the development of cataract increases rapidly from the fiftieth year on, and reaches its maximum at the eightieth year.

2. DIFFERENT FORMS OF CATARACT.

(*a*) **Cataracta Senilis.**—Senile cataract develops usually between the fiftieth and seventieth year of life, that is, in lenses having a nucleus already sclerotic. *A hard, unclouded and transparent nucleus, and a soft, but clouded and therefore untransparent cortex are characteristic of senile cataract.* It attacks both eyes, seldom at the same time, however. There are often early symptoms preceding a cataract, such as multiple vision in one eye (*polyopia monocularis*). This depends upon the division of the cortex into sectors, and since these sectors do not lie exactly symmetrical to the axis of vision, each sector projects its own image of the object looked at, and these

Digitized by Illinois College of Optometry

different images do not coincide. Another early symptom is short-sightedness, not an apparent condition depending on reduced visual acuity, but an actual condition due to a real approach of the far point toward the eye. This may be due to a change of the refractive index, or to an expansion of the lens with the accompanying advance of the anterior lens surface.

If myopia were caused by a thickening of the lens nucleus it would certainly result in every aging eye. It is well known that such is not the case. On the contrary, many aging eyes lose in refractive power (*pp. 38 and 45*). This may be explained thus: Thickening of the nucleus raises its refractive index, and consequently the refractive power of the eye; but while the nucleus is thickening it is at the same time flattening and thereby losing its converging strength. If thickening and flattening maintain an equilibrium, there is no change. If the thickening predominates, myopia is the result.

Whether with or without the preceding segmentation in the lens, wedge-shaped opacities are formed, each with apex toward the

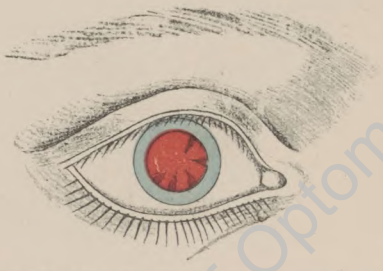

FIG. 121.—BEGINNING CATARACT, UNDER TRANSILLUMINATION, WITH DILATED PUPIL. (*After Jaeger.*)

pole and base toward the equator (*Fig. 121*); the narrower the wedge the slower is the progress of the cataract. These spoke-like opacities are soon accompanied by lines, dots, and clouds.

As Foerster shows, the first spokes are only fissures or cleavages filled with fluid of a refractive index different from that of its surrounding. This fluid coagulates into "Morgagni's drops." As cataract develops the lens-fibers degenerate, as may be recognized microscopically by fine punctate molecular opacities. The points coalesce to drops, and the fibers are stretched till they finally burst. These points look like fat-drops, and are held to be myelin; they can be recognized even after the rupture of the lens-fibers by their possessing a higher refractive index than that of the surrounding fluid. Close to them are seen also cells of swollen epithelium varying in shape, and of appreciable size.

Digitized by Illinois College of Optometry

In proportion as the opacities increase in number and size and encroach upon the pupillary area the visual acuity declines. The patient, who is probably presbyopic and has worn reading glasses for years, usually complains that his glasses "don't fit," or he says there are black spots in front of his eye, which means that when he moves his eye the retina perceives the flitting of the shadows which the opacities throw on it. The physician makes a diagnosis of beginning cataract (*cataracta incipiens*), and has now to choose whether he shall tell the patient or keep silent. It is best to let the decision rest upon his estimate of the time that will elapse before an operation will become necessary. This may often, but not always, be estimated by the condition of the cataract. Small spokes of grayish-yellow color indicate a slow course, while broad, bluish-white spokes of a silken luster are more probably of a rapid course. If the patient is old the cataract probably grows slower. In very old persons an opacity may never reach maturity. If the appearance of the cataract is not indicative of its rate of growth, it is a good plan to draw for record the size and position of the more prominent opacities, and to measure the visual acuity, and to compare these with the conditions when the patient presents himself two or three months later. If the visual acuity is reduced and if the opacities are increased, a rapid course may be assumed. If progress is slow, conditions may not materially change for months or years.

As the opacities increase and as the visual acuity diminishes correspondingly, the lens swells. This is recognized by the fact that the anterior chamber grows shallower. This swelling of the lens depends upon an absorption of water by the lens cortex. The cataract in this stage is called *cataracta immatura maturescens*, or nondum matura, not yet ripe for extraction. *The iris-shadow test*, used to demonstrate that the lens cortex is not yet fully opaque, is performed as follows: The eye is illuminated from one side by a convex lens, while the physician looks into the eye from the other side; if the lens is completely opaque, it is seen that the white reflected from it and the dark brown of the pigment layer at the edge of the iris lie immediately against each other. If, on the contrary, the external cortical layer of the lens is still unclouded and therefore does not reflect light, there will be seen between the white of the pupil and the pigmented edge of the iris a dark interspace or ring: an expression of the fact that the iris and that part

Digitized by the International College of Optometry

of the lens which reflects light do not as yet lie in immediate contact.

After a longer or shorter time the stage of ripeness is reached, cataracta *matura*. The cortex is now fully opaque, the swelling has disappeared, and the anterior chamber is again of normal depth; the iris throws no shadow on the lens. Visual acuity is reduced to counting fingers or to the mere recognition of the movements of the hand; a candle is recognized by the eye, if otherwise normal, at *6* to *10* meters. The thicker the opacity, which means the younger the patient, the worse will vision be.

If the cataract is not operated on, it changes gradually into an overripe condition, *cataracta hypermatura*. This overripeness finds expression in a decrease in size of the lens, in consequence of which the anterior chamber grows deeper than normal and the iris trembles. It may also be noticed that the spoke-like opacities are crossed and connected together by encircling bands.

The character of overripe lens substance is varying:—

(*α*) Either the contents of the capsule is poor in water and hard, "like dried glue," *cataracta dura hypermatura*. This character of the capsular contents acts as an irritant on the epithelium of the anterior capsule, so that an inflammatory growth is set up which leads to capsular cataract, not a happy designation, for the capsule itself does not become opaque, but rather the new tissue formed from the epithelium and deposited within the capsule. Capsular cataract looks chalky, is not translucent, shows no spokes or bands but a uniform distribution toward the surface, and lies—an important factor, too—in the pupillary plane. For this reason it might be mistaken for deposits on the anterior capsule; to avoid such an error, it is best to remark that deposits, according to their origin, are connected with the pupillary edge of the iris and appear grayish-white, neither of which conditions is the case in capsular cataract.

(*β*) Or, the overripeness leads to fluidity of the cortex. The spokes and bands disappear, the cortex changes to a homogeneous grayish-yellow mush in which floats a brownish nucleus that shows its edge when the head is turned in certain directions. This condition is called *cataracta morgagniana*. Here also the anterior chamber is deeper, the iris trembles, and capsular cataract is developed. Vision, owing to definite optical principles, is in cataracta dura hypermatura better, and in cataracta morgagniana worse than in cataracta matura senilis.

Digitized by Illinois College of Optometry

(*b*) **Cataracta Juvenilis** (*Phakomalacia, Soft Cataract of Young Persons*).

The young are, to be sure, although much less frequently than the old, subject to cataract, but since their lenses have not as yet a hard nucleus, the development of cataract takes a somewhat different course. In senile cataract the nucleus remains, as a rule, unchanged, and appears about the same as any nucleus in a healthy lens of the same age, but in juvenile cataract the nucleus goes through the above-mentioned stages of splitting, degeneration of fibers, liquefaction, and perhaps absorption. In juvenile cataract the appearance of the first opacities is not noticed at the equator, but rather can any part of the lens, even the nucleus, be strewn with punctate opacities. In certain cases the posterior pole is the point of origin, and from there an opacity may spread to the posterior edge (posterior cortical cataract, *Fig. 122*) till it finally destroys the transparency of the whole lens.

The results of juvenile cataract are atrophy, fluidity, or calcification. In an atrophic soft cataract there is found within the capsule a thick mush consisting of myelin, fat, cholesterin, lime, and detritus. In a fluid cataract the same constituents are found floating in water; the lime kernels may so predominate that the contents of the capsule looks

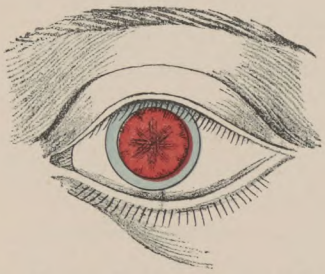

FIG. 122.—CENTRAL POSTERIOR CORTICAL CATARACT.
The spokes with points toward the middle are partly at the anterior, partly at the posterior edge.
(*After Jaeger.*)

like milk, *cataracta lactea*. In a calcified cataract the whole lens is changed to a thick, lumpy mass, *cataracta calcarea* or *gypsea*.

In a few cases the contents of the capsule of an atrophied or fluid cataract is absorbed. There remains then only the capsule itself, *cataracta membranacea*, with its growth of epithelium (capsule cataract) and the debris of the cataract milk. Individual areas of such a membranous cataract may become again so translucent that the blind eye regains part of its visual strength.

The diagnosis of juvenile cataract must be made by its general appearance. Broad spokes, deep clefts, and a bluish-white color prove that there is much soft cortex present. Moreover, the youthfulness of the patient shows that a hard nucleus cannot as yet have developed. This form of cataract may be congenital in all stages of its growth.

(*c*) **Cataracta Traumatica.**—If the anterior lens capsule is injured and if as a result the lens fibers come into contact with the aqueous humor, they become cloudy and swollen. The swollen matter crowds through the capsule wound into the anterior cham-

Digitized by Illinois College of Optometry

ber and is gradually dissolved. If the capsule wound is small or blocked by the overlying iris, the process may stop here, the wound healing quickly and the rest of the lens remaining uninjured, leaving a capsule cicatrix as memento of the accident. But if the wound was larger, the whole lens becomes cloudy, new flakes of lens matter pass into the anterior chamber and are dissolved, the process being repeated till the entire contents of the capsule has disappeared.

Accidental capsular injuries have shown surgeons one way of disposing of the cloudy contents of the lens capsule, but an incision through the capsule (Discission, *p. 346*) is not free from danger. The epithelium of the anterior part of the capsule, if brought into contact with the aqueous, may grow so luxuriously as to produce a secondary cataract—*cataracta secundaria* (*p. 354*)—which consists of new-formed tissue and insoluble capsule. If the capsule wound is large, the swelling of the lens matter may be so angry as to cause iritis and secondary glaucoma (*q. v.*).

The age of the patient plays an important part in the danger of a traumatic cataract. The younger the patient, the quicker does the opacity and absorption follow, and the less inclination is there to inflammation and increased tension. Complete absorption cannot be expected if the nucleus becomes sclerotic. The older the patient, the slower does clouding advance, and the greater is the danger of inflammation and increased tension.

In injuries to the lens it not infrequently happens that a portion of the lens already opaque becomes again transparent—as, for example, in injuries from foreign bodies. Suppose a splinter of iron to have passed through the entire lens; the path pursued by the foreign body becomes opaque, and this opacity extends over a larger portion of the posterior cortex (*Fig. 122*). Meanwhile the anterior and posterior capsule wounds close up, the foreign body having been removed. Some weeks later the posterior cortex may be found transparent, and the opacity is restricted to the path of the bit of iron.

If a very small and aseptic foreign body enters the eye and remains in the lens, a cataract may result so gradually that the patient forgets the injury before his increasing visual disturbance leads him to the surgeon. Cases have been reported where a foreign body long since forgotten has been found in a lens extracted for what was supposed to be senile cataract.

Digitized by Illinois College of Optometry

Cataract can arise from a severe concussion to the lens without an actual capsular wound (see Causes, *p. 343*).

(*d*) **Cataracta Stationaria.**—One factor is common to all forms of cataract yet discussed, namely, that the disease finally makes the whole lens (or rather the whole cortex) opaque, even if after years or decades. There is another class in which the condition is not that of a gradually progressive opacity, but of a fixed and completed opacity remaining unchanged the whole life long. Examples are furnished by small capsular injuries. Another example is that mentioned on *p. 225* under diseases of the cornea, as anterior central capsular cataract, consisting of a small, roundish, glittering, white opacity at the anterior pole of the lens. Such an opacity protrudes at times into the anterior chamber, and is there called *cataracta pyramidalis*. It must not be supposed that the opaque mass is outside of the capsule. The opposite is the case. All investigators are unanimous in saying that the "pyramid" is covered by the uninjured capsule, lacking its epithelium, however; and the capsule, where it passes from the normal surface onto the pyramid, is thrown into delicate folds. The opaque mass consists of spindle-formed cells, the offspring of the missing epithelium. Anterior central capsular cataract may be congenital, due probably to some intrauterine corneal inflammation. The disturbance to vision depends essentially on the size of the cataract and on the folds in the capsule. Becker and others have seen cases with normal visual acuity.

A form of cataract quite similar in appearance is found at the posterior lens pole, and is called posterior polar cataract, *cataracta polaris posterior*. This, too, is characterized by a glistening, white, round opacity. With focal illumination it is seen to be like a concave mirror with the concavity directed forward. It must not be confused with posterior cortical cataract (*Fig. 122*), which has a quite different, radiating shape, a yellow color, and is by no means stationary. Anatomical investigations have shown that posterior polar cataract is not a genuine lens opacity, but a deposit on the posterior capsule analogous to the iritic deposit (*p. 274*) at the anterior pole. This posterior polar cataract is the result of some disease of the fetal arteria centralis corporis vitrei.

There is still another form of congenital nuclear cataract, *cataracta centralis*. It is recognized as a white, circular, sharply outlined opacity in the depth of the pupil. Vision may be very good, as the patient looks through the side of the opaque nucleus which, by the denseness of the opacity, acts rather to diminish light instead of cutting it off altogether.

The commonest form of stationary cataract is the lamellar or zonular cataract. It appears as a delicate gray, completely homogeneous opacity. With a dilated pupil one sees that the sharply defined circular opacity is surrounded by a more or less broad, deep black edge. By focal illumination it may be seen that the lens cortex is clear; the cone of rays entering the eye undergoes reflection at the anterior capsule on the one hand, and at the opaque anteriorly convex lamella on the other; the distance apart of these two reflexes indicates the distance of the lens surface from the clouded lamella. In case the opacity is so very delicate that it can be transilluminated, the cloudiness of the layer lying behind the nucleus, with the opaque zone anteriorly concave, may be demonstrated.

Digitized by National College of Optometry

The ophthalmoscope provides a further means of diagnosis. If light is thrown by it directly into the pupil, the sharply defined, circular opacity appears dark, not, however, uniform, as under oblique illumination, but brownish-red in the middle;[1] the equatorial zone, black by oblique light, now appears red.

From this we conclude that nucleus and cortex are transparent, and that the opacity is restricted to a zone (lamella) lying between nucleus and cortex.

The results of clinical investigation are confirmed by the anatomical examinations (*see Fig. 123*). Deutschmann, in one case, found the nucleus clear, but closely surrounded by a thin layer of opaque cortex. This opacity was due to the fact that the fissures and gaps between the lens-fibers were filled with fine-grained detritus and myelin drops; the fibers themselves were uninjured, but saturated by "vacuoles" and myelin drops. Around this opacity was a zone of clear cortex, then a second belt of opacity, not yet completely closed. Outside of all was the rest of the cortical substance, still perfectly normal. Further investigation has shown that the vacuoles may be present in the nucleus, but not in such abundance as to make it opaque. If this latter happens, however, the condition is that of stationary nuclear cataract and is closely related to lamellar cataract.

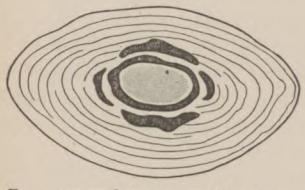

FIG. 123 — LAMELLAR CATARACT (SCHICHTSTAR). (*After Deutschmann.*)

The cortex is not clear in all forms of lamellar cataract, but there are often found, particularly in the region of the equator, dots or spokes, the latter of a fork-like form, with one tooth reaching to the anterior, the other to the posterior part of the cortex; these are called saddle opacities, because the forks seem to ride upon the edge of the lamellar cataract. Schirmer explains them as fissures resulting from an abnormally strong contraction of the nucleus. The presence of these opacities arouses the suspicion that a lamellar cataract has ceased to be stationary and that a total lens opacity is to be expected. The thicker the dots and the broader the spokes, the quicker is the advance of the cataract to be assumed.

---

[1] The phenomenon is explained by v. Graefe as follows: In direct transillumination the middle of the opacity is struck by perpendicular luminous rays, while the edge of the opacity is struck only by oblique rays. Consequently, at the edge of the opacity more light is reflected and thus prevented from entering the interior of the eye. The same condition is true of light which returns from the fundus and makes the pupil appear red. This brighter center distinguishes lamellar from nuclear cataract; the latter is obviously least transparent in the middle and therefore appears by transillumination darkest in that area.

Digitized by Illinois College of Optometry

Lamellar cataract appears nearly always in both eyes. It may be congenital or developed during the early years of life. As a rule, however, it is not recognized till later, when the child shows its inability to keep up with school requirements. An examination made at this time reveals a decidedly reduced visual acuity ($\frac{20}{70}$ to $\frac{20}{200}$ according to Becker's experience), a noticeably small range of accommodation, and moderate myopia.

Diminution in range of accommodation may be observed in other forms, in senile cataract, for example, when the accommodation is less than that which corresponds to the age of the patient. The reason is that the diseased lens loses the power of changing its shape.

Shortsightedness is said to depend occasionally on spherical aberration. That is, if the opaque zone is so small that the patient can look to one side of it, his retina receives images from rays which enter at the peripheral parts of cornea and lens, and which are, therefore, owing to faulty or incomplete aplanatic conditions, more strongly refracted than central rays would be. Myopia may also, of course, depend on the length of the eyeball.

3. CAUSES OF THE FORMATION OF CATARACT.

It is reasonable to suppose that a transparent tissue composed of cells is in a condition of unstable equilibrium, and will lose this equilibrium if the adjustment of the cells to each other, the uniformity of its contents, or its chemical components experience any change. This of itself corresponds to or explains a phenomenon of daily life, that a lens opacity may be noticed after cold and disappears after heat. Obviously this is a coagulation of certain substances, perhaps composed of fat and albumin.

The formation of secondary cataract after injuries to the capsule needs no particular mention, since it is not to be expected that the proliferated and changed epithelial cells will produce a transparent tissue. But opacities result from injuries that have caused no real wound to the capsule. The explanation for these is not so obvious. It must be assumed that the lens is not shut off from its surroundings by the capsule in an absolutely watertight compartment, but that an exchange of fluid takes place between the lens on the one side, and the anterior chamber, the vitreous and the spaces of the zonula of Zinn on the other. But the great thickness of the anterior capsule, and particularly the epithelium here present, prevent this exchange of fluid from being too active; at the back of the lens this danger is lessened by the semifluid character of the vitreous. If now any injury tears the lens free from its normal connection, or if any part of the protective epithelium dies, the normal exchange of fluid ceases, nutrition is disturbed, and an opacity results. For instance, a dislocated lens regularly becomes opaque, and even an incomplete laceration of the suspensory ligament may produce cataract. Cataract resulting from a lightning stroke may be used as an example of opacity due to the destruction of epithelial cells.

If the above view concerning the relation of the lens to its surroundings is correct, any qualitative change in aqueous, vitreous, and zonula may endanger the lens. This is actually the case. We know that lens opacities result

(1) From chemical alterations in the fluid constituents of the body in general, and

(2) From diseases of the uveal tract.

Examples under (1) are furnished by the cataracts from salt, naphthalin, and sugar. A *salt cataract* can be produced in frogs by injecting chlorid of sodium or any other rapidly

Digitized by Illinois College of Optometry

diffusible salt beneath the skin. Small quantities of this salt reach the lens and effect such a chemical union with the materials present as to destroy the transparency. *Naphthalin cataract* can be produced in rabbits by feeding them with naphthalin. This begins like senile cataract in man, with streaks and spokes in the cortex at the equator. *Sugar cataract* (cataracta diabetica) has been seen in man as the result of diabetes. It is supposed that it is not the passage of sugar into the lens, but the presence of sugar in the vitreous, aqueous, and zonula, which causes the opacity. The why and wherefore is still dark, since not enough sugar has been found in the aqueous to ascribe the lens opacity to a reduction in the normal proportion of water.

Examples under (2) are furnished by the numerous cases of cataract which appear as a pathological result of an acute or chronic inflammation, or of some non-inflammatory disease of the eye. Among them may be mentioned the diseases of the uvea—iritis, iridocyclitis, choroiditis—and myopia, the result being explained by the fact that the inflammatory products are deposited in the vitreous, in the anterior and posterior chamber, that is, in the tissues adjacent to the lens. Retinitis pigmentosa, detachment of the retina, and glaucoma may also be mentioned.

The preceding explains the origin of many forms of cataract, but the very commonest, senile and lamellar cataract, are not touched upon. Both these forms occur, as a rule, in healthy persons and in otherwise healthy eyes. With reference to lamellar cataract clinical observation has suggested a reason for its origin. In about four-fifths of the patients with lamellar cataract a persistent rachitis (rickets) has been found, especially faulty development of the dental enamel, or malformations of the skull, or nodules at the joints of hollow bones, or the "rachitic rosary," or perhaps many of these signs together. Lamellar cataract is therefore assumed to be a rachitic eye disease, and we suppose that the cortical zone developed during the period of rachitis became cloudy through nutritive disturbances, but that lamellæ deposited after the rachitis ceased were clear. But why the lack of earthy salts in the tissues of the body—and that is the essence of rickets—can induce the formation of opaque lens fibers is of itself not quite plain.

Senile cataract has found no explanation which is at the present day universally accepted. We know only that age predisposes to cataract. We do not know why. We might assume a senile atrophy of certain parts of the uvea and a consequent malnutrition of the lens. We might assume a mechanical explanation; Becker supposes that with the sclerosis of the nucleus there is also an atrophy which the equatorial region cannot follow so easily as the polar regions: there is consequently a fissure at the equator. Thus the formation of cataract is begun by a cause ascribed to disturbance of nutrition, at one time little understood. There is also no light thrown on the matter by the circumstance that cataract is hereditary in certain families. Schoen's view, that senile cataract is the result of undue strain on the accommodation, is so far more opposed than upheld. Michel's doctrine, that senile cataract is due to some such cause as atheroma of the arteries, has made no greater impression.

4. TREATMENT OF CATARACT.

An opacity of the lens once formed cannot be cleared up. This admits of very few exceptions, one such being mentioned on *p. 340*, while diabetic cataract may be an exception, and some physicians claim to have seen opacities disappear after treatment at Carlsbad. Indirectly a disappearance, complete or incomplete, may be effected by absorption (*p. 339*). (A form of spontaneous cure results from

luxation of the lens, *q. v.*). The treatment of unripe cataract must therefore be restricted to the prescription of proper "reading glasses," or glasses with a handle. Occasionally smoked glasses are serviceable by effecting a reduction of the light so frequently complained of, or by a dilatation of the pupil reflexly (*p. 333*). For the same reason atropin may be of service for a period of time. The general health of the patient must be protected, since cataract may make rapid advances after exhausting diseases.

The essential treatment of cataract consists in removal of the opaque lens, and is therefore operative.

What cataracts can be operated on? Those cases must be rejected in which a better visual acuity cannot be obtained by reason of some other disease (of the retina, choroid, or optic nerve) existing behind the lens. The presence of complications can at times be assumed by the appearance of the cataract; for example, cataracta calcarea occurs almost always in eyes already totally blind. Moreover, many a complication may be discovered by examining the light sensation and the field of vision (*p. 334*). No operation should be performed on a stationary cataract in which the visual acuity suffices for the patient's vocation or may be made to suffice by the production of an artificial pupil. Finally, a cataract operation should be postponed if only one eye is affected, the other remaining healthy, since the advantage of an increased visual field does not compensate for the danger that always threatens the other eye during an operation for cataract. Even a successful operation cannot add other advantages than this just mentioned, for essential binocular vision cannot be expected, owing to the great optical disparity between the eye operated on and the unaffected eye. If, however, the second eye shows a beginning cataract, or for any other reason is unserviceable, the first must be operated on.

If an operation is decided on, the next question is as to the proper time for it. Overripe and ripe cataracts can be attacked at once. Unripe cataracts, on the other hand, should be waited for, since the chances of success in the operation on unripe cataracts are never so good. In cases where maturity is approached very slowly, or where the patient for any reason does not wish to wait, Foerster's (Bettman's) method of *artificial ripening* may be tried. This consists of performing an iridectomy or of releasing the aqueous by a corneal puncture, and of then massaging the cornea with a strabis-

Digitized by Illinois College of Optometry

mus hook; the lens cortex in its uninjured capsule is thus irritated and the opacity makes rapid strides.

Many ophthalmic surgeons operate on unripe cataracts in patients of sixty years and over. In such old people an easy delivery may be expected even if the lens is not totally opaque, especially if a few individual opacities are to be seen in the outer cortical layers. Landolt declares that the age of the cataract is of more importance in this respect than the age of the patient; the longer the unripe cataract has existed, the sooner may an easy delivery of the lens be expected.

If now a cataract is pronounced to be ripe or at least operable, it only remains to choose the method of operation. There are three at our disposal:—

(1) The lens in its uninjured capsule may be pressed downward, that is, pushed out of the pupillary area into the vitreous by means of a needle entered through the cornea or sclera—*Depression* or *Reclination;*

(2) The anterior capsule may be torn by a cataract needle, and the capsular contents left to be gradually absorbed—*Discission;*

(3) The opaque lens may be removed from the eye—

(*a*) By drawing it out through a hollow needle—*Suction.*

(*b*) By releasing it from the eye by an incision—*Extraction.*

The first method may be passed without consideration. Formerly it was universally resorted to, but is nowadays seldom or never applied, since not only may an eye so operated on go blind by slow inflammation, but the other eye may also be destroyed by sympathetic ophthalmia. The method is admissible in atrophied cataracts having but little substance and no power of swelling.

Suction is worth remark only for the fact that it may be applicable in a fluid cataract without nucleus. The choice lies really between Discission and Extraction.

Discission is applicable in soft cataracts without hard nuclei, a condition usually the rule in young persons up to the twenty-fifth year. Lamellar cataract is therefore almost always operated on by discission. The proceeding is as follows: The pupil must be dilated as much as possible, and if the dilatation is only moderate, it is better to give up discission. The necessary instruments are a lid speculum (*Fig. 98, p. 281*), fixation forceps (*Fig. 78, p. 213*) and a discission needle (*Fig. 124*). The needle is made to enter to the under and outer side of the center of the cornea, perpendicular to its surface. After the needle reaches the anterior chamber it is pushed on till its point touches the capsule a few millimeters beyond the

Digitized by Illinois College of Optometry

anterior pole. The handle is now raised and withdrawn a bit, so as to cut the capsule with the point without pressing deep into the lens or touching the nucleus. Then the needle is pulled out in the same path it was pushed in, so as to avoid the escape of the aqueous as much as possible. A deep cut into the lens would excite too much swelling, a danger already mentioned (*p. 339*). The escape of aqueous produces a contraction of the pupil and the accompanying danger that the iris may be brought into contact with the wound in the capsule and adhere to it. For this reason the pupil must be kept dilated with atropin. If the swelling is too active, ice compresses may be used, and if the eyeball shows increased tension in spite of this, the swollen mass must be let out by a corneal incision about *5 mm.* long: simple linear extraction.[1] It often happens that after a time the lens substance ceases to be absorbed, either because the capsule wound has closed, or because the aqueous has become saturated with the substance already dissolved. In the latter case the promise of success may be held out that release of the aqueous by a corneal puncture will at least set up further absorption. If the capsule wound is closed it will not be opened by a simple release of aqueous, and the discission must therefore be repeated. A cure of cataract by discission requires several months.

FIG. 124.—DISCISSION NEEDLE.

The treatment of senile cataract—cataract with sclerotic nucleus—is summed up in the word **Extraction.** There are two methods: Daviel's, or *flap extraction*, and v. Graefe's *peripheral linear extraction.* The latter implies an iridectomy, the former does not.

(*a*) **Flap Extraction,** *Below.*—Instruments: Lid speculum (*Fig. 98, p. 281*), fixation forceps (*Fig. 78, p. 213*), v. Graefe's (*Fig. 126*) or Beer's (*Fig. 125*) cataract knife, Daviel's spoon with v. Graefe's cystotome (*Fig. 127*). The patient lies, the surgeon stands at his head if the right eye is to be operated on, at his side if the left eye is to be operated on. After the lid speculum is adjusted, the surgeon seizes a fold of the conjunctiva and enters the knife at *a* (*Fig. 128*), about *0.5 mm.* inside the corneal margin, carrying it parallel to the plane of the iris through the anterior chamber; at *b* the knife is brought out and the flap completed downward, by a straight cut if Beer's knife is used, by a sawing movement if the instrument is v. Graefe's. The red line shows the location

[1] Simple linear extraction is applicable to totally opaque cataracts of young persons. But, of course, the capsule must be opened after the linear incision, and this may be effected by the lance knife (keratome).

Digitized by Illinois College of Optometry

of the flap. The surgeon now introduces the small hook turned flat and with the back in advance into the anterior chamber, turns the point toward the capsule and tears it open with gentle pressure; a second incision perpendicular to the first completes the opening in the capsule. All the instruments are now removed, and the delivery of the lens is accomplished by the surgeon, who lays the index finger of one hand on the lower lid and the thumb of the other hand on the upper lid, and with gentle pressure with the latter on the upper part of the cornea turns the lens on its horizontal axis; the lens thus presents its lower margin in the wound, and by moderate pressure on the upper lid it is worked out. The somewhat prolapsed iris is replaced with a spatula or Daviel's spoon, and any lens fragments are removed by scooping them out with Daviel's spoon.

FIG. 125.—BEER'S KNIFE.

FIG. 126.—V. GRAEFE'S KNIFE.

FIG. 127.—DAVIEL'S SPOON, WITH SHARP HOOK FOR TEARING THE CAPSULE.

This procedure gradually drove from the field the method of depression that had alone ruled to the middle of the eighteenth century. Brilliant results were obtained by it, but certainly in one-

FIG. 128.—DAVIEL'S FLAP INCISION.

tenth of the cases there was suppuration of the cornea, or, at least, an inflammation in the eye that led to complete and hopeless blindness. As the suppuration was explained by the separation of the flap, v. Graefe decided to avoid a corneal flap by (*1*) making the incision in the sclera, and (*2*) carrying it along a great circle of the sphere; but since in such a cut the iris prolapsed, an accompanying excision of the iris became imperative. To prevent the aperture in the iris

Digitized by Illinois College of Optometry

from admitting too much light, incision and iridectomy were made above, where the upper lid could cover them. The result justified expectation. Suppuration of the cornea became noticeably less, while the failures and losses were reduced one-half. On the other hand, chronic iritis and cyclitis were more frequent than before, and led occasionally to sympathetic inflammation of the other eye.

(*b*) **V. Graefe's Peripheral Linear Extraction.**—Instruments: Lid speculum, fixation forceps, v. Graefe's cataract knife, iris forceps and scissors, hook, two Daviel's spoons, Weber's scoop (*Fig. 129*) or lens spoon (*Fig. 130*). The surgeon stands at the patient's head for the right eye, he sits or stands at the left side for the left eye. For the first step, the *incision*, the knife is entered at *a* (*Fig. 131*) toward the center of the anterior chamber, in order to make the wound on the inner surface of the sclera as large as that on the outer surface. When the point of the knife has reached the center of the pupil it is directed toward the spot of exit, *b*, and the cut is completed by a sawing motion. If the knife were held parallel to the plane of the iris, it would cut its way out in the red dotted line; but since this is not the intention, the knife must, during the cut, be turned on its long axis so as gradually to bring the edge more and more forward (or upward). When the sclera is pierced, the blade is again turned so as to lie parallel to the conjunctiva, in which position the conjunctiva is separated from the sclera; after this has been accomplished for the distance of *2 to 3 mm.* the blade is again turned forward and the conjunctival flap completed. This serves to effect an immediate closure of the scleral wound.

FIG. 129.—WEBER'S SCOOP.

FIG. 130.—LENS SPOON.

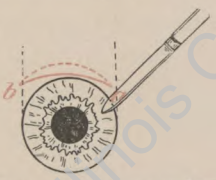

FIG. 131.—V. GRAEFE'S PERIPHERAL LINEAR EXTRACTION.

The cut is not absolutely linear, that is, it does not coincide with a great circle; it is rather an incision with the formation of a very small flap of *1.5 to 2 mm.* breadth.

The second step, the *iridectomy*, is now made. Occasionally the iris is floated out by the aqueous as it escapes after the incision is completed. The iris is in any case seized by the iris forceps (*Fig. 89*), pulled from the wound, and cut with one stroke of the

Digitized by the Illinois College of Optometry

scissors curved on the flat, the scissors being held parallel to the scleral wound and pressed firmly against the eyeball. The third step, *cystotomy*, consists in opening the lens capsule. For this purpose a capsule hook (*Fig. 127*) is introduced into the wound at the angle to the right and passed obliquely to the left till it reaches the edge of the iris, and is then turned to bring the point toward the capsule, over which it is drawn in a horizontal direction; the point of the hook is thus made to cut a flap in the anterior capsule. The fourth step is the *delivery*. For this purpose one Daviel's spoon is placed at the upper lip of the wound parallel to it, and a second is pressed gently against the lower third of the cornea until the greatest diameter of the lens has passed beyond the wound. Pressure is then stopped, and the lens is pushed out from below. Any remaining fragments of cortex may be expelled by stroking the cornea with the Daviel's spoon. Care must be now taken that the iris is not engaged in the wound; if it is, it must be pushed back into the anterior chamber, or if this is not successful, it must be picked up again in the iris forceps and cut off. If vitreous presents in the wound before the lens is delivered, all instruments that might cause pressure on the eyeball must be removed, and the lens extracted by the wire scoop (*Fig. 129*) or by the spoon (*Fig. 130*).

In the last twenty years we have learned that in suppuration of the cornea, it is not bad nutrition of the flap but infection which plays the principal rôle! Since at the present day we can with almost absolute certainty prevent infection, the dispute over Daviel's and v. Graefe's operations (long ago decided in favor of v. Graefe's) has broken out anew. In favor of Daviel's operation is the retention of a round and movable pupil, which looks better, causes no dazzling, and to a certain extent offsets the lack of accommodation by the fact that it is reflexly contracted when near objects are gazed at; peripheral vision is also better with a round and contracted pupil than with an iris coloboma; and the danger of sympathetic inflammation in the other eye is less in Daviel's operation. On the other hand, the danger of iris prolapse and its attendant evils is greater in Daviel's.

Landolt has instituted inquiries among ophthalmic surgeons of all countries. As the result of his questions, and of his own experience, Landolt has formulated the rule that the operation without iridectomy is suitable only for the best cases, that is, for cataracts in which a smooth and complete delivery of the lens may be anticipated in patients of a healthy, calm, and intelligent disposition.

I have myself always operated with an iridectomy, and shall for the present stick to it. I acknowledge that "complete success" with Daviel's method is of more value to the patient than the same visual acuity obtained after a v. Graefe's operation, but that the chances are less to attain this result in Daviel's operation. Moreover, the danger of making v. Graefe's incision too peripherally is essentially reduced by using *Jacobson's incision* at the corneal limbus. (*Fig. 132.*)

Digitized by University of Illinois College of Medicine

The length of the incision depends upon the size of the nucleus. In case this cannot be correctly estimated in advance, it is best to allow room for the passage of a very large nucleus, say from *7 to 8 mm.*

The ideal of a cataract operation is without doubt the delivery of the lens in an unruptured capsule. This method has been developed and recommended by the Pagenstecher brothers. It deviates from v. Graefe's extraction only in this: that after the iridectomy is completed a spoon is passed behind the upper edge of the lens, and by gentle pressure on the lower third of the cornea the lens is encouraged to come out. If this does not succeed, the spoon is passed still deeper in, up to the posterior pole, and the lens is slipped out by pressing it lightly against the inner surface of the cornea. This method is applicable if the capsule is tough, the Zonula Zinnii (suspensory ligament) weak, and if there is any fluid between vitreous and lens. Experience teaches that in over-

FIG. 132.—JACOBSON'S INCISION.

ripe cataracts the capsule is tough and the ligament relaxed. Looseness of the lens in the saucer-shaped depression of the vitreous may be expected in cataracta accreta and in overripe cataracts coupled with glaucoma. The few cases in which I have operated by Pagenstecher's method have been among my most successful ones.

5. TREATMENT—BEFORE AND AFTER.

In a cataract operation the greatest danger comes from infection. The surgeon must therefore exercise all his skill to find any sources of infection and to counteract them. Particular attention must be given to the lacrimal passages and the nose, the conjunctiva and lids. Diseases of these structures must be treated and cured according to principles already given. Unfortunately, in diseases of the lacrimal apparatus this is a wearisome task, and many surgeons prefer to shut off the tear sac from the conjunctiva, either by Eversbusch's method of ligating the duct, or by Haab's method

Digitized by Illinois College of Optometry

of sealing the punctum by the galvano-cautery; others either expose the sac and fill the space with iodoform gauze, or extirpate it. Chronic conjunctival catarrh in old people can be merely bettered, not cured. In such cases a radical disinfection immediately before the operation must be relied on.

The general health of the patient needs attention as well. We know that old, and particularly poorly nourished persons, are prone to hypostatic congestion of the lungs during continuous rest in bed. We know also that the closure of both eyes may induce physical disturbances, alcoholics being noticeably affected. Many old persons suffer from chronic bronchial catarrh and cough, or bladder troubles, all being conditions in which rest in bed is an aggravation or an impossibility. In such cases we must be content with a shorter or less constant period in the recumbent position. To alcoholics it is best to give a modicum of beer or wine. Active catharsis must be induced in all cases before the operation.

The immediate preparation of the patient consists of a good soap and water bath to the whole body including the head, and a wet bandage of sublimate over the eye to be operated on. This bandage is to be removed on the operating table, the head enveloped in a cloth wet in sublimate solution, the vicinity of the eye thoroughly washed in sublimate *1:1000*, and a second sublimate cloth, with a hole cut in it for the eye, is to be spread over the face. The eye is now cocainized with a drop of a *five per cent.* solution applied five times at intervals of one minute; the entire conjunctiva, especially the caruncles and the adjacent tissue, is to be wiped off with cotton wet in sublimate *1 : 1000*, followed by a copious douche of sublimate solution *1 : 5000*. The operation is now begun. During it no more sublimate is used for fear of provoking corneal opacities, but the eye is repeatedly flushed with a fresh and warm *three per cent.* boric acid solution. In case the conjunctiva or lacrimal passages are not absolutely healthy, the wound and the inner canthus of the eye are powdered with sterile iodoform.[1]

It is assumed that the cocain solution, the dropper, the instruments, surgeon's and assistants' hands are aseptic. The instruments are taken directly from a *four per cent.* carbolic acid solution

[1] The sterilization of the iodoform I leave to the druggist. About *5.0 gm.* of iodoform are placed in a wide-mouthed flask with about *10.0 c. c.* of sterilized water, and boiled on a water bath for an hour. The water is then poured out of the flask and the moist iodoform dried on the water bath in the same flask corked with cotton.

Digitized by the Internet Archive in 2010 with funding from University of California Libraries

and the adherent fluid shaken off. The bandage consists of cotton dipped in *1 : 1000* sublimate, and gauze. To avoid entropion the under lid is kept in place by a sausage-shaped roll of moist cotton.

The dreaded suppuration in the wound may be avoided with certainty by following these precautions. According to my experience, the same cannot be said of iritis and cyclitis. These conditions are seen in cases where the wound was closed and remained so after the first change of bandage, the wound itself not being infected. In such cases we must assume that with some one of the instruments germs have been introduced into the interior of the eye without finding a resting-place at the scleral wound. It must also be remembered that inflammation may be produced by chemical irritation, or by the swollen lens substance not yet removed. An iritis or a cyclitis may even result mechanically by rupture of an adherent remnant of capsule or iris.

As a matter of routine I open the bandage on the afternoon of the second day, that is, thirty hours after the operation, because a moderate adhesive iris causes no particular pain, and may be present with no complaint from the patient. If I find the bandage dry, the lid edges not reddened, no photophobia in the eye, I assume that no wound infection has taken place, even if the eye itself is quite red and the conjunctiva somewhat swollen (chemotic)—this last might be due to the sublimate alone. Sterile atropin solution is now dropped in, and a bandage reapplied. The same treatment is continued on the next day. If all goes smoothly the patient may sit up in bed the third day, and stand the fifth or sixth. The healthy eye is kept bandaged with the eye operated on for about five days. At the beginning of the second week the bandage may also be omitted from the eye operated on. Dark glasses should be used for protection against strong light, and the ciliary muscle with the iris must be kept at rest by continuing the atropin. After two or three weeks the patient may be dismissed if the vicinity of the cut on the eye has meanwhile become pale. The eye is not to be used yet. Cataract glasses with permission to use the eye must not be given till two months after the operation. If healing does not take place kindly—if iritis, cyclitis, or suppuration in the wound appears—the eye must be treated according to circumstances. Energetic atropinization and warm compresses with boric acid solution are the principal remedies for iritis and cyclitis; disinfection, or if neces-

Digitized by University College of Optometry

sary the cautery, is the best remedy for the suppuration. The striated keratitis (*p. 252*) needs no particular treatment.

The results of cataract extraction are very good. In preantiseptic days the loss was about *five to six per cent.* An eye was called lost which could not count fingers. Thanks to antisepsis, this proportion has noticeably diminished, at the hands of many operators sinking close to the vanishing point. "Unsuccessful result" may be entered, if the patient has less than $\frac{1}{10}$ visual acuity; "successful result," if more than $\frac{1}{10}$. In nearly one-fourth of the operations a claim is made for V = 1.[1]

In a considerable number of cases the visual acuity first obtained will gradually decline. This depends upon the development of secondary cataract.

6. CATARACTA SECONDARIA.

After the extraction of the cataract, the fragments of the anterior capsule are drawn out of the pupillary area—if everything goes well—and resting on the posterior capsule they finally become adherent to it. Capsular epithelium and the remnants of the cataract are therefore removed from the irritating action of the aqueous. The nutritive cells at the lens equator do hypertrophy, to be sure, but they are changed into normal lens fibers as far as their physical characteristics, if not their form, is concerned. The contents of the intercapsular space consists of new-formed, transparent lens substance, and of cataract debris, called lenticular membrane (*Fig. 133*). Any eye operated on and found in such a condition shows a black pupil, but by focal illumination there is seen behind the pupillary plane a delicate, striated, silk-like, often tremulous membrane,—the posterior capsule. Unfortunately, this typical condition is not always present. The fragments of the anterior capsule do not always withdraw from the pupillary area, nor adhere early to the posterior capsule; for this reason the debris of the cataract swells up in the anterior chamber, the epithelium of the capsule continues to grow, and as a result of this activity there is seen in the pupillary area a delicate or tough gray membrane, the simple secondary cataract. Visual acuity may be reduced to

[1] It has seldom been my experience that a patient can read line No. 4 at 4 meters without error; but we may record V = $\frac{4}{4}$ if one or several of the letters of line No. 4 are named or guessed correctly.

Digitized by Harvard College Library

counting fingers. Even this is not the worst that can happen. In many cases the capsular fragments adhere to the iris or to the edges of the wound, a condition termed *cataracta secundaria accreta.* The contraction in the cicatrix, the movements of the iris and ciliary muscle, all drag continuously on the secondary cataract, which gradually increases in prominence through this irritation; the contraction in the secondary cataract, too, drags on the suspensory ligament and the ciliary body, and provokes a chronic cyclitis. In consequence of all this the adherent fragments may develop into a tough membrane, and the eye gradually perish by atrophy. Fortunately, however, the eye in most cases calms down after a few months, so that the operative treatment of the secondary cataract may be discussed.

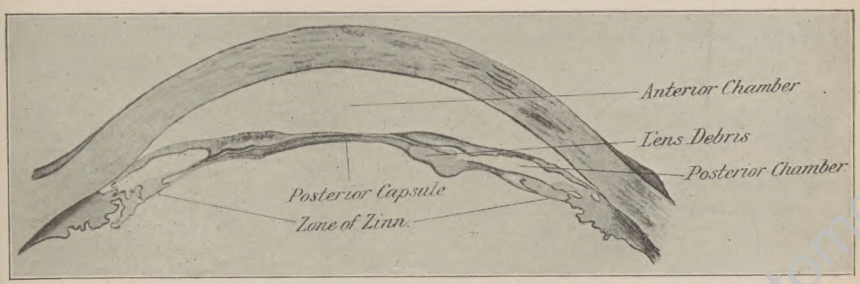

FIG. 133.—CLOSURE OF THE PUPIL AFTER EXTRACTION OF CATARACT. (*After Pagenstecher and Genth.*)

The **treatment** is discission. After thoroughly atropinizing the eye, the largest possible hole in the membrane should be torn with a discission needle or cut with a Graefe's knife exactly at the center. If the membrane is so tough that a dangerous dragging on the ciliary body is to be feared, dislaceration should be substituted for discission. Dislaceration consists in piercing the center of the membrane with two needles, and then by a leverage motion in tearing as large a hole as possible from the center toward the edge. Although the injury itself is trifling, there is developed at times after operations on secondary cataract a cyclitis resulting in phthisis bulbi, or even panophthalmitis. One must be careful, therefore, not to operate before the irritation caused by the first operation has completely subsided. On the other hand, the delay should not be unnecessarily long, since a recent secondary cataract is more delicate than an old one, and since the contraction going on helps

Digitized by the Internet Archive of Optometry

to keep open a hole made seasonably enough. If the wound from the first operation heals kindly, the proper time for discission of the secondary cataract will be about two months afterward.

Many surgeons say that division of the secondary cataract by a fine scissors forceps introduced into the anterior chamber is free from the dangers of discission. I have had no experience in this method.

II. APHAKIA.

An eye from whose dioptric system the crystalline lens has been removed is called aphakic. All eyes operated on for cataract are therefore in this condition. The absence of lens can be recognized by a depth of the anterior chamber and by a tremulousness of the iris in case it is not adherent to the secondary cataract. The essential proof of aphakia lies in the detection of the absence of the Purkinje-Sanson's lens-images. Since the ophthalmologist can easily demonstrate the presence or absence of these images (*p. 100*), the detection of aphakia is correspondingly easy. With focal illumination we see in the pupil the shimmering striations of the posterior capsule or the whitish gray stripes of the anterior capsule. Even when the lens has been removed in its unruptured capsule there is a moderate reflection at the border between aqueous and vitreous. This must not be confused with the lens-images: there are two of the latter, of unequal size,—the anterior image making the same movements, the posterior image making contrary movements, if the illuminating lens is moved back and forth in its own plane.

The refractive power of the lens is about *10.0* Diopters, and this amount of power is lost to the eye by a cataract operation. An emmetropic eye becomes therefore in its aphakic condition one of *10.0 D* Hyperopia. An axis myopic eye of *4.0 D* becomes *10.0* — *4.0* = *6.0 D* hypermetropic. A hypermetropic eye of *4.0 D* becomes *10.0* + *4.0* = *14.0 D* hypermetropic.

The manner in which the eye is robbed of its lens has an especial influence on the refractive condition. A horizontal incision almost always flattens the cornea in healing in the perpendicular principal meridian, and the result is a corneal astigmatism, regular in the best cases, irregular in the worst, generally both regular and irregular.

An aphakic person, if he did not happen to have a myopia of *10.0 D* before the operation, cannot see distant objects distinctly, not to mention near ones; and he must resort to cataract glasses

Digitized by Illinois College of Optometry

(*p. 38 et seq.*). If the astigmatism is regular, the lens must be ground sphero-cylindrical. A moderate degree of regular astigmatism may be overcome by the patient's adjusting his glasses in an oblique position (*p. 379*). When the lens is gone the eye loses its ability to accommodate for a near point. To take the place of this the artifice must be resorted to of setting the glasses further away from the eye, or the neutralizing lens must be exchanged for stronger ones. For example, if the aphakic person has a hyperopia of *10.0 D*, his eye with $+15.0\ D$ can be adjusted for about $\frac{1}{5}\ m$. As a rule, patients learn this themselves, and they make an adjustment for middle distance by placing the glasses lower down on the nose.

The statement that the effect of a convex lens is increased by setting it further from the eye is generally true only under the assumption that the object lies at a greater distance than twice the focal distance of the lens. In aphakic persons this condition is fulfilled; not so in emmetropic presbyopia. In this latter condition, therefore, to set the glasses further off does not increase, but does on the contrary decrease the convergence of the luminous rays. Examples: An emmetrope with the lens removed reads at *25 cm.* with $+14.0\ D$; the book is therefore removed more than twice the focal distance of the lens; for the focal distance is $\frac{100}{14} = 7\ cm.$, twice this distance equals *14 cm.* An emmetropic presbyope reads at *25 cm.* with $+4.0\ D$; the book is therefore not twice the focal distance of the lens, for $\frac{100}{4} = 25\ cm.$, and twice this equals *50 cm.*

That setting the glasses further from the eye increases their effect, if the object is removed more than twice the focal distance of the lens, depends upon the following easily demonstrated fact: if the object is to the left at a great distance, the lens throws an image to the right nearly at its focal point. If I move the lens toward the left, the image passes—toward the right if reckoned from the lens, but—in space with the lens toward the left until the distance between object and lens equals twice the focal distance; if the lens is moved still further toward the left, the image passes toward the right away from the lens, so that from now on it passes toward the right in space.

The proof of this statement cannot be given in an elementary way.

From what has been said above, it is clear that an aphakic person can see as well with the glasses bought of the optician as he sees through the trial lens used by the surgeon only when the spectacles purchased by him are set as far from the eye as the lenses were in the trial frame of the surgeon. We must not neglect, therefore, to give the optician some suggestion concerning the desired distance at which the glasses should rest in front of the eye. This is of particular importance in sphero-cylindrical glasses. The reasons cannot be explained in a few words.

Visual acuity of an aphakic person appears at the test greater than it actually is, because the letters seem enlarged. The nodal point of the new dioptric system—cataract glass plus aphakic eye—lies further in front of the retina than it does in the normal eye, and therefore everything is presented to the aphakic eye at a larger visual angle.

Digitized by University of Illinois Library of Ophthalmology

The aphakic eye suffers at times from dazzling. This is due in part to the aperture in the iris made for the extraction of the cataract. Another reason may be found in the reflection produced on the curved surfaces of the cataract glasses. Many patients complain about occasional red vision, *erythropsia*, which appears incidentally when looking at bright surfaces. Perhaps red vision may be but a kind of dazzling. It disappears after a time. In one case I noticed rapid improvement after using iodid of potassium. Suggestion?

III. CHANGES OF POSITION OF THE LENS.

1. **Ectopia Lentis** (*Congenital Dislocation*).—This anomaly occurs usually on both sides symmetrically. It is most common upward. Becker explains the condition as due to an unequal

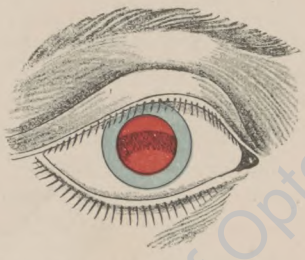

FIG. 134.—DOWNWARD DISPLACEMENT OF THE LENS, UNDER TRANSILLUMINATION. (*After Jaeger.*)

development of the suspensory ligament. A displacement of the lens effects a decided disturbance of vision which can be improved in some cases by concave, in other cases by cylindrical lenses. If the pupil is so large or the displacement so pronounced that the edge of the lens presents within the pupillary area (*Fig. 134*), the result is "double vision in one eye," although it is not necessary that the double images be perceived by the patient's consciousness. It depends on the distance of the object whether one of the images is more hazy than the other, and whether or not it is therefore neglected or excluded. Luminous rays from infinity striking that part of the pupil which has no lens are focused at a point behind the retina, while, on the contrary, rays passing through the edge of the retina may be focused in front of the retina. If the object fixed lies at a proper distance, rays refracted at the edge of the lens are

Digitized by Illinois College of Optometry

focused exactly at the retina, and the object is therefore seen distinctly. In some instances a well selected convex glass may serve to unite into a sharply defined image rays passing through that part of the pupil without a lens.

The objective examination shows the anterior chamber to be abnormally deep, while the deeper part of the iris trembles at every movement. By transillumination with the ophthalmoscope the lens margin is seen as a black ring (*Fig. 134*). The fundus appears in the upright image of different magnification according as one looks at it past the edge of the lens or (with concave glass) through the lens itself.

2. **Luxatio Lentis Spontanea** (*Spontaneous Dislocation*).—The subjective and objective phenomena are the same as in ectopia, transparency of the lens being taken for granted. The origin is different, however. Two modes of origin may be assumed. First, fluidity of the vitreous, *synchysis corporis vitrei*. It is supposed that the same cause which thins the vitreous leads also to softening of the suspensory ligament. Second, overripeness of a cataract. The new-formed tissue of the capsular epithelium contracts and thereby drags on the suspensory ligament adhering to the anterior capsule, which becomes loose and relaxed. An accidental sneeze, or vomiting, or any such shock to the body will accomplish the rest. Both cause downward displacement of the lens, because it is specifically heavier than aqueous or vitreous. After the displacement the visual disturbance due to the cataract disappears. Displacement is therefore a natural method of curing senile cataract.

3. **Luxatio lentis traumatica** (*Displacement of the lens by injury*), with or without injury to the external parts of the eye, may be caused by a blow or fall upon the eye. Displacement is either complete or incomplete (subluxation). In the complete form the suspensory ligament is torn through a large segment of the circumference, and the lens sinks into the vitreous, or becomes wedged in the pupil, or dislodged into the anterior chamber, or is crowded through a wound in the sclera onto the eyeball beneath the conjunctiva, or may entirely escape through a conjunctival wound caused by the same injury. Any lens displaced from its natural bed will sooner or later become opaque.

4. **Movable Lens.**—Dislocation of the lens sometimes associates motility with it, irrespective of the cause. Motility may be recognized by the fact that the lens will be

Digitized by the Illinois College of Optometry

found in various parts of the eye according to the position in which the head is held—in either the anterior chamber, the pupil, or in the vitreous. In other cases a slight tremulousness may be noticed by a change of posture of the head. This condition implies some abnormal length or elasticity of the suspensory ligament, or some incomplete rupture in it. Obviously, the optical phenomena differ according to the location and posture of the lens. The unavoidable tension on the suspensory ligament caused by this condition endangers the eye.

The **treatment** of dislocation of the lens is restricted to the use of suitable glasses or to an operation, either iridectomy or extraction of the lens.

DISEASES OF THE VITREOUS.

INTRODUCTION.

The *corpus vitreum* (*vitreous body*) consists of 98.6 per cent. water. If the water is pressed out of the vitreous there remains only an extremely small mass of glass-like tissue as solid constituent, which is composed of transparent fibers extending in all directions. Between these are spaces connected with each other and filled with nearly pure water, the vitreous humor. At the periphery of the vitreous are complex and peculiarly formed cells, the ameboid cells, which, according as they are adherent to the fibers or float in the free fluid, are different in form and nature. The latter cells may be perceived entoptically as the "mouches volantes." The vitreous is pierced in an irregular sagittal direction by a canal about *2 mm.* in diameter, called *the central canal of the vitreous*. This begins at the axis nerve sheath and ends at the posterior pole of the lens; it is provided with a lining membrane and filled with vitreous humor. In the embryonic stage there is an artery in this canal, the *arteria hyaloidea* or *centralis corporis vitrei*. At times it persists after birth, the *arteria hyaloidea persistens*, and is then noticeable by the ophthalmoscope as a grayish thread passing from the optic papilla to the posterior pole of the lens.

The vitreous is retained in a comparatively firm membrane, the *membrana hyaloidea*. There arise from it near the ora serrata fine glass-like fibers that pass to the equator of the lens, and have been mentioned as the suspensory ligament; between ora serrata and equator they rest against the ciliary processes and are adherent to them.

The vitreous is but little disposed to independent disease. A pathological condition in it is, therefore, always a reason to examine for disease of the uvea, particularly the ciliary body, since the vitreous is nourished from this source.

On the other hand, diseases such as may be caused by an entering foreign body or by a parasite, are inclined to draw the eye as a whole into sympathetic inflammation—a condition to be discussed later.

1. **Myodesopsia** (*Muscæ Volitantes, Opacitates Corporis Vitrei*).—It has already been mentioned that microscopic vitreous opacities are of normal occurrence. They are found at the posterior part of the vitreous 0.3 to 3.0 or 4.0 *mm.* in front of the retina. There is no great difficulty in seeing them in one's own eye (*p. 19*). It often happens, however, that they make themselves too evident, and on that account disturb and distress the patient. Such patients

Digitized by the Internet Archive

are usually but not exclusively myopic. They describe their opacities as threads, strings of beads, flakes, spider-webs, or flies, that float about when the eye is moved, and then sink slowly through the field of vision when the eye is at rest. Since everything is projected into the outer world inverted (*p.* 70), we must assume with Helmholtz that these microscopic opacities are specifically lighter than the fluid in which they float, and that, therefore, when the eye is at rest they float upward. This is not altogether probable, for we know that vitreous opacities visible by the ophthalmoscope are seen to sink when the eye is at rest. I shall make no attempt to explain this contradiction. The "flying specks" are not visible by the ophthalmoscope; there is nothing pathological to be found in the eye, and the visual acuity is normal.

Treatment consists of assuring the patient that the condition is of no significance. The opacities do not disappear under this treatment, but the patient learns to overlook them.

As soon as opacities are rendered visible by the ophthalmoscope, "flying specks" are no longer spoken of, but the term is—vitreous opacities. They are generally movable but may be stationary. Most commonly they appear as threads and flakes, less often as vitreous dust or membrane. The favorite location is the anterior and posterior portion of the vitreous. The center is least affected. Opacities appearing suddenly usually come from blood that has exuded from the ciliary body, papilla, or retina into the vitreous. They naturally alarm the patient exceedingly. Opacities appearing gradually may remain for a long time unnoticed; they have been spoken of as organized ameboid cells.

Opacities are always a sign of disease of the choroid, the ciliary body, or of the retina, and usually, too, the only and first, or the only and last sign. For example, if hemorrhage has taken place into the vitreous and gradually disappeared, some kind of opacity generally remains. Or a lesion of the ciliary body may cloud up the anterior part of the vitreous without evidence of other disturbance, since the ciliary region is not accessible to the ophthalmoscope. Visual acuity will be reduced by vitreous opacities only if they intercept luminous rays proceeding to the center of the retina.

If the nature of the lesion can be made out, it has of course its influence on prognosis and **treatment.** If this cannot be done, such opacities must be treated by themselves. Mild salt aperients,

Digitized by the College of Optometry

mercury, iodid of potassium, or a diaphoretic treatment may be tried. The result cannot be foretold. Surgical interference has been attempted by sucking out movable opacities, or cutting out stationary ones by means of a needle properly introduced. The most important point is to use the eyes as little as possible in order to dispel any choroidal inflammation that may be in its incipiency.

2. **Synchysis** (*Fluidity*).—If the fibers of the vitreous are dissolved, the vitreous changes into a light yellow, stringy fluid. This change in condition brings of itself no disturbance and is betrayed by no special signs. The fluidity is first recognized if opacities are at the same time present, when a pronounced change in location establishes a proof that the normal confines are lacking. There are conditions, however, in which vitreous opacities can be diagnosticated without added proof,—a high degree of myopia, spontaneous luxation of the lens, or chronic glaucoma, for example. As cause of this fluidity we assume a chronic inflammation of the choroid or ciliary body. Consequently the **treatment**, if we may call it such, must begin at these tissues. This fluidity is of great significance in cataract operations, since the danger of loss of vitreous is in such a case very much greater than under normal circumstances.

Synchysis Scintillans.—In rare cases the ophthalmoscope reveals a picture that may be compared to the shower of sparks in fireworks. This depends upon the presence of minute granules and needles, partly of cholesterin and tyrosin crystals, and partly of phosphates, dispersed here and there in the fluid vitreous. If light is thrown into such a vitreous while the patient moves his eyes, some of these floating crystals reflect the light back again so that the observer sees them as luminous points.

If the vitreous is not very fluid, the movement of these bodies is too small to show the phenomenon in its greatest brilliancy. The observer can then make them more apparent by rotating the mirror or by moving his own head. If the pupil is well dilated these golden points of light may be seen by focal illumination. The disease appears in advanced old age, sometimes in otherwise healthy eyes, sometimes in connection with vitreous opacities. In one case of this latter kind I found $V = \frac{4}{5}$. In pure synchysis scintillans normal vision is the rule.

ERRORS OF REFRACTION.

In this and the four next sections diseases of the eye as a whole are discussed.

Since refractive errors have already been treated from the standpoint of physiological optics (*p. 28 et seq.*), they are spoken of here only as they produce clinical signs and symptoms.

Digitized by Illinois College of Optometry

I. HYPEROPIA (Farsightedness), H.

Complaints of farsightedness are various. Many patients seek aid because, after a period of reading and writing, the letters run into one another, and are so confusing as to become illegible. The patients must stop to rub their eyes; but the same trouble comes anew and is intensified by burning, pressure on the eyes, or even headache; these necessary interruptions occur more frequently until the book or work is laid aside. Others complain chiefly of headache, and say that the family physician sent them because he thought that this headache was due to the eyes. Such troubles are called "*accommodative asthenopia.*"[1] They arise from exhaustion of the muscle of accommodation, which persists in continued contraction even if the hyperope tries to look at distant objects. If now this hyperope uses his eyes for a near point—reads or writes, for example,—there is demanded of his muscle of accommodation a further contraction, which, this having already approached the maximum, is greater than can be continuously maintained. Indistinct vision will be added to the feeling of strain.

Asthenopia and indistinct vision appear in many cases earlier than might be expected from what is said above, because the relative range of accommodation (*p. 80 et seq.*) is no longer extensive enough. For example, a person twenty years old with *2.0 D* of hyperopia would be able to work (with one eye) at *33 cm.* distance without discomfort, since in this case he uses $2 + 3 = 5$ Diopters, that is, only one-half of his range of accommodation of *10.0 D*. But with an accommodative act of *5.0 D* there is associated a convergence only to a point $\frac{1}{5}$ *m.* = *20 cm.* distant. Consequently, in that accommodative act of *5.0 D*, *2.0 D* belong to the positive interval of accommodation which are applied to convergence at $\frac{1}{3}$ *m.* Both eyes are fit for use, however, only if the positive interval of the accommodation applied (to convergence at $\frac{1}{3}$ *m.*) is considerably greater than *2.0 D*. If this is not the case, the patient can avoid asthenopia in two ways: He may give up short dioptric adjustment, and be content with binocular vision while seeing everything with circles of diffusion; or the necessity for

[1] There is a muscular asthenopia that produces the same symptoms (*p. 368*); and a conjunctival (*p. 183*), a nervous (*q. v.*) or retinal (*p. 307*) asthenopia.

Digitized by Illinois College of Optometry

accurate vision may predominate, and accurate dioptric adjustment will be obtained, but with deviation of one eye inward, that is, with sacrifice of binocular vision. Since the second way is often (unconsciously) chosen by the patient, hyperopia becomes one of the most common causes of internal squint (*q. v.*).

It has been said that complaints about farsightedness are various. It sometimes happens that the complaint is made, not of farsightedness but of nearsightedness. The patient holds his book or other objects close to his eyes. The explanation is simple. If the hyperopia is pronounced, the range of accommodation is not great enough to neutralize it and to adjust vision for a near point at the same time. The patient, therefore, gives up any attempt at exact dioptric adjustment, and prefers to replace it by enlargement of the visual angle. By bringing the object close to his eye this visual angle increases more rapidly than do the circles of diffusion, and the pupils become so contracted that the latter dioptric error is somewhat minimized.

It happens also that the symptoms do not refer at all to vision, but to burning in the eyes and to their sticking together, all of which is apparently explainable by the inflamed condition of the conjunctiva and lids. The usual treatment for such trouble is, however, futile, because a hyperopia or an astigmatism is at the bottom of it. Donders insisted on examining the refractive condition in every disease of the eye, a step not always taken nowadays by the practising ophthalmologist, but the experienced observer will never neglect such an examination if he finds that a conjunctival or palpebral irritation resists ordinary treatment.

The distress from hyperopia drives the patient, who has been farsighted from his youth, to the physician, at different ages. This depends on several circumstances—the degree of hyperopia first of all. Slight hyperopia up to *2.0 D* will be tolerated longer than moderate hyperopia, *2.0 D* to *5.0 D*, or than pronounced hyperopia of more than *5.0 D*. The range of accommodation present, that is, the age of the patient, is the next important factor. The third is the occupation of the individual; the tiller of the soil is less troubled by his hyperopia than the clerk, the seamstress, or the delicate artisan. Finally comes the general health; those who have tolerated their hyperopia without complaint become asthenopic after an exhausting illness.

Anatomy.—It has been said that hyperopia depends upon the shape of the eyeball. The hyperopic eye is smaller than normal in all diameters; it may therefore be considered an incompletely developed organ. The sclera is flat near the cornea, sharply curved near the equator. The anterior chamber is shallow. The visual axis cuts the cornea at a point lying relatively near the nasal side of the center of the cornea; the angle *gamma* (*p. 84*) is large, about 7°. Since the position of the two eyes is estimated rather accord-

Digitized by Illinois College of Optometry

ing to the direction of the corneal apices than to that of the visual axes, two eyes with a large angle *gamma* give us the impression of divergence. The sclera is thick and consequently pure white, in contrast to the bluish appearance of the sclera in a myopic eye. Although a skilled observer may make a guess at hyperopia from these signs alone, the diagnosis must be supported by the objective (*p. 125*) and subjective (*p. 37*) examinations, while the visual acuity can be estimated at the same time. It is a regular result to find that pronounced hyperopia is associated with a reduced visual acuity. The reason lies in the corneal astigmatism, which of itself characterizes the hyperopic eye as incompletely developed. The range of accommodation in pronounced hyperopia may be less than the normal, in consequence of insufficient development of the ciliary muscle; and in the same way the range of movement (excursion) of the two eyes may suffer by faulty development of the eye-muscles.

After measuring the visual acuity and hyperopia of each eye separately, the two eyes together should be tested. It will often be found that the manifest hyperopia in two eyes is *0.5*, *0.75*, or even *1.0 D* greater than in each eye alone. The result of the test of both eyes together indicates the glasses to be worn.

In myopia also there is found at times a weaker refractive condition, that is, a lower degree of myopia when both eyes are used than with one eye. How can that be explained? Many think that the refractive condition found in one eye alone is the correct one, and that the acceptance of stronger convex or weaker concave lenses at the test with both eyes together rests on an error which is counterbalanced by greater visual acuity of both eyes together contrasted with the lesser visual acuity of a single eye. Others think that the refractive condition found in both eyes together is the correct one, and that the weaker hyperopia or the stronger myopia of the test with one eye alone is confused by a spasm of accommodation. Neither of these views seems to me to settle the question.

Another strange fact is the following. It not seldom happens that a hyperope, in spite of a range of accommodation greater than his hyperopia, and in spite of the closure of one eye, sees with the other eye distant objects very poorly without a convex lens. One would suppose that a hyperope with *2.0 D* of hyperopia and *5.0 D* range of accommodation would always be able with one eye to neutralize his *2.0 D* of hyperopia by a corresponding effort at accommodation. Why is this not possible for many such hyperopes? This question is answered by some authorities as follows: When a child has learned to use his eye—that is, in his earliest years—he has a range of accommodation of about *20.0 D*. If the child is hyperopic, he is accustomed, when looking at distant objects, to contract his ciliary muscle just enough to neutralize his hyperopia. The degree of contraction necessary for this is said to be exercised instinctively or even against the will, the whole life long, whenever a distant object is looked at. Accordingly the entire hyperopia is said to remain latent during life just as it was in youth,

Digitized by Illinois College of Optometry

when the range of accommodation remains unchanged. This cannot be the case, however. Since the range of accommodation does, on the contrary, decrease from year to year (*p. 45*), the dioptric result of such an unchanged muscular contraction must, in a corresponding degree, decrease; in other words, only a portion of the total hyperopia is latent, another portion, increasing with years, is manifest. In old age, when the range of accommodation has noticeably decreased, the contraction of the ciliary muscle produces no result worth mentioning, and consequently the entire hyperopia becomes manifest.

Undoubtedly the idea here developed is the correct one, but it does not exhaust the subject. As a matter of fact, it is not true that every twenty-year-old hyperope has one-half of his hyperopia latent, the other half manifest. There are plenty of hyperopes who, either with or without the neutralizing convex lens, can adjust their eyes for distant vision; their hyperopia is therefore "*facultative.*" In others, even in the twentieth year, the entire, or nearly the entire hyperopia is latent. In still others, even in early youth, the entire or nearly the entire hyperopia is manifest. This is all easily explained if we consider that the impulse of the will is not alone determined by what has become habit in early life, but may also be modified later in life by the necessities of occupation and the activity of the muscle itself.

Treatment.—A cure of hyperopia by art is impossible. Nature is able, however, to change a young, hyperopic eye into an emmetropic or even into a myopic eye, in the course of the body's development. This is not the case in the adult. Treatment must therefore be confined to overcoming the complaints of the patient by suitable lenses. But not every hyperope has symptoms. Young persons with slight hyperopia (up to *2.0 D*) can usually see well both near and far objects. They need no treatment. Not until the range of accommodation decreases is asthenopia added to slight hyperopia. Such cases are aided by suitable reading glasses. Until the fortieth or forty-fifth year those glasses which just neutralize the hyperopia, will, as a rule, suffice. Beyond the forty-fifth year reading glasses must replace the diminished range of accommodation, and must therefore be the stronger the older the patient. It is a good rule that the patient should read with his glasses at the usual distance, without calling into play any more than two-thirds of his range of accommodation. For example, a man of fifty years with hyperopia of *2.0 D* is accustomed to read his newspaper at *30 cm.* distance; he has at that age a range of accommodation of *2.5 D*. To adjust his eyes for *30 cm.* the refractive strength of his eyes at rest must be increased by $2 + \frac{100}{30} = 5.33\ D$. But with this increase his accommodative mechanism can only take part to the extent of $\frac{2}{3}$ of $2.5\ D = 1.75\ D$ (in round numbers). The balance, $5.33 - 1.75 = 3.5\ D$ (in round numbers) must be supplied by glasses.

Digitized by Illinois College of Optometry

In many cases, especially of moderate (*2.0* to *5.0 D*), and strong (over *5.0 D*) hyperopia, vision is indistinct for distance with both eyes together, either because the range of accommodation is not extensive enough to adjust the eye for parallel rays—*absolute hyperopia*, or because such an extensive contraction of the accommodative muscle prevents a parallelism of the visual axes (*p. 79*). In this case the patient must wear glasses continuously. If there is presbyopia as well, he must have two pairs of glasses, neutralizing lenses for distant, and stronger ones for near objects. In ordering glasses it must be stated that the distance of each lens from the other equals the pupillary distance, for otherwise an artificial "muscular asthenopia" (*p. 368*) will result. The stronger the lenses, the greater is the prismatic effect, and therefore the more significance has the distance of the lenses from each other.



FIG. 135.—(*a*) COLLECTING, (*b*) DISPERSING MENISCUS.

It takes a long time for some persons to get accustomed to the inconveniences of glasses—the dazzling, the pressure on the nose and behind the ears, and the distortion of objects to one side. This last may be somewhat avoided by using biconvex and biconcave lenses, the so-called meniscus glass, which, according as the convexity (*Fig. 135, a*) or the concavity (*Fig. 135, b*) is the stronger, acts as a collecting or dispersing lens. Such lenses are called "periscopic," because sharp retinal images are formed even if lens and eye are not exactly centered.

II. MYOPIA (SHORTSIGHTEDNESS), M.

Symptoms.—Slight myopia up to *2.0 D* is often tolerated without complaint or even suspicion. An accidental examination may be the first means of discovering the shortsightedness, and of showing the patient the treasures of nature and art that may have been lost to him.

In moderate myopia, *2.0 D* to *7.0 D*, the visual disturbance is so noticeable that the patient himself must see how defective he is in comparison to his fellowmen. He applies therefore to the physician with the complaint that he sees poorly, or that he needs glasses because he is shortsighted. In other cases it is pain, photophobia,

Digitized by Illinois College of Optometry

and inability to work for which he seeks aid. These symptoms depend partly upon muscular asthenopia, a painful exhaustion of both internal recti. The myope brings everything that he wishes to see distinctly so close to his eyes that it lies at, or even within, his far-point distance. He therefore makes such great demands upon convergence that even normal eyes could not stand such a continuous strain. It happens, moreover, that convergence is very difficult for axis-myopic eyes, on various grounds: First, because of the disproportion between the required accommodation and the convergence (see Causes of Concomitant Squint); second, because of the length of the eyeball, which renders all movements, especially that for convergence, difficult, since long eyeballs would naturally lie with their long axes in the direction of the orbits, which would bring them distinctly divergent. Other cases come to the physician on account of "flying specks;" the myopic eye is to some extent in the condition in which it would be artificially placed if one wished to examine himself for entoptic opacities. Therefore, in many myopes, this seeing of specks ceases when the more diffuse illumination of the retina is changed to sharp images on the retina by concave lenses.

In pronounced myopia, from *7.0 D* upward, there are symptoms that are partly dependent upon the refractive error itself, and are partly the direct consequence of it. One direct result is the reduced visual acuity, which cannot be improved even by neutralizing lenses. The posterior nodal point of the combined system—eye plus concave lens—lies nearer to the retina than it does in the eye alone; consequently external objects appear under a visual angle, smaller in proportion as the neutralizing lens is stronger, that is, the higher the myopia the smaller the visual angle. But a more important factor is the reduction of visual acuity as a consequence of the stretching of the retina[1] and impairment of the macula lutea. The appearance of macular changes is often first noticed by the patient as distortion of images, *metamorphopsia*. Other occasional symptoms of pronounced myopia may be mentioned, such as the light phenomena or photopsia, disturbances of light perception, and dark spots in the field of vision.

[1] In a stretched retina the individual optic-nerve cells lie further apart than normal; consequently a retinal image must be larger than normal, in order to cover a sufficient number of these cells.

Digitized by the Google Collage of Optometry

Anatomy.—The shortsighted eye is enlarged, generally from before backward, less often in all directions. An enlargement of the latter kind is called buphthalmos. An enlarged eye protrudes from the eyeball, and is less movable than the emmetropic or the small, hyperopic eye. An eye enlarged only from before backward is egg-shaped, and may often be recognized in the individual (*p. 30*). Donders has demonstrated an increase in the diameter of the eyeball as great as *33 mm.*, Arlt even to *37 mm.*, the normal length from corneal apex to posterior surface of sclera being *24.3 mm.* At times only the region of the posterior pole bulges out, *sclerectasia posterior;* the form of the eyeball is then obviously irregular. Another peculiarity lies in the fact that the angle between visual line and axis passing through the corneal apex (angle *gamma*) is small or even negative, that is, that the visual line (and visual axis) passes through the temporal side of the cornea. This condition may simulate convergent squint.

The diameter of the pupil in myopia is said to be on the average greater than in other refractive conditions, although this statement has been recently disputed.

The lens lies deeper than in emmetropia or hyperopia, as may be recognized by the depth of the anterior chamber, and occasionally by tremulousness of the iris. The sclera of the myopic eye is thin, often no thicker than paper at the bulging posterior pole. The vascular coat beneath may shimmer through a thin sclera, so that the "white of the eye" often appears bluish-white in a myopic person.

The ciliary muscle is differently constructed than it is in emmetropia or hyperopia. It consists almost exclusively of meridional muscular fibers (Bruecke's muscle, *Fig. 94, p. 266*), which form a powerful band extending much further backward than normal. In the choroid there are atrophic areas, especially abundant in the immediate neighborhood of the optic nerve, *sclero-choroiditis posterior* (*staphyloma posticum*,[1] *conus*), less frequently at the macula lutea, and occasionally at other places at random, *choroiditis disseminata.* The changes in the choroid can be seen with the ophthalmoscope during life.

---

[1] The name really refers to the bulging of the sclera, but is also used to describe the atrophic areas of the choroid. Staphyloma posticum is, moreover, not restricted to myopic eyes, but is seen, though less frequently, in emmetropic and hyperopic eyes.

Digitized by Indiana College of Optometry

The illustrations, *Figs. 136* and *137*, show a sickle-shaped and a cone-shaped staphyloma posticum at the temporal side of the optic disc. In the latter there is a sickle-shaped, white portion sharply demarcated from a cone-shaped, black-spotted portion. Within the area of the pure white crescent, the choroid and pigment epithelium have completely disappeared and the sclera is quite exposed. As it develops, the staphyloma gradually involves the nasal side of the disc, until the crescent becomes a circle.

Another common sign in myopia is an egg-shaped pupil, with the long diameter perpendicular. This oval appearance probably depends upon certain anatomical changes,—a contraction of the optic nerve papilla (*Fig. 138*) and the choroid toward the temporal side.

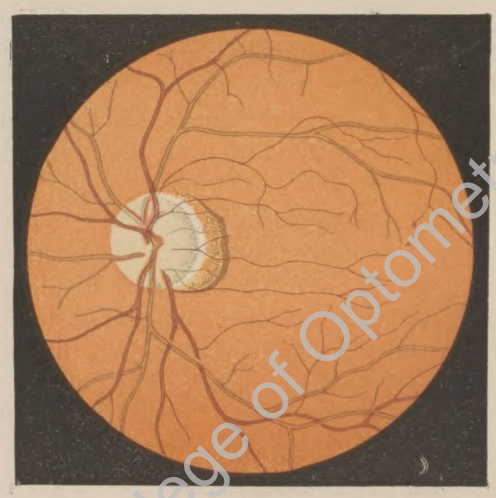

Fig. 136.—Sickle-Shaped Staphyloma Posticum, Upright Image. (*After Jaeger.*)

The vitreous is fluid, and there are floating in it a few fibers and flakes which may be recognized as vitreous opacities with proper magnification in the ophthalmoscope. At times the vitreous is separated from the posterior pole by a layer of fluid, *posterior detachment of the vitreous* (*Fig. 138*). The vitreous may also be detached from the lens in front, *anterior detachment of the vitreous* (*Fig. 138*).

The optic nerve sheath is reddened, *neuritis myopum*. The intramembranous space about the optic papilla is noticeably widened (*Fig. 138*). The retinal vessels have a somewhat more direct

Digitized by Illinois College of Optometry

course, due to the tension of the retina. In the area of a staphyloma the pigment epithelium and the layer of rods and cones may have disappeared, and a dark spot (scotoma) in the visual field will correspond to such an atrophic retinal area. And finally, retinal hemorrhages and retinal prolapses (*p. 315*) may be mentioned as results of pronounced myopia.

Course.—The anatomical changes just enumerated are not present in every case of myopia. They develop, however, during the course of years in which slight myopia is progressing into pronounced myopia. This point is the most important in the discussion of myopia, its tendency to progress. This is strongest from

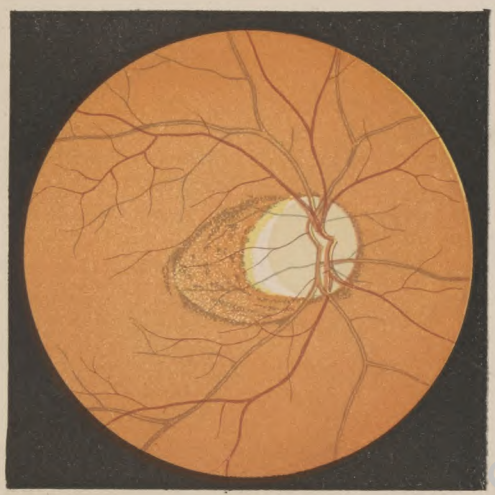

FIG. 137.—CONE-SHAPED STAPHYLOMA POSTICUM, UPRIGHT IMAGE. (*After Jaeger.*)

puberty to about the twenty-second year. Fortunately, the tendency ceases at this period in most cases; it becomes *stationary*. After this, as a rule, nothing pathological can be demonstrated during life except a staphyloma posticum. In a few cases, however, myopia continues to develop after the body has reached full maturity, and is therefore continuously *progressive*. During its increase, symptoms like pain, sensitiveness to light, and lack of strength are particularly distressing. The advance of myopia is characterized not only by the approach of the far point, but also by the appearance, or rather the increase, of the choroidal atrophy and the other changes in the fundus. One may often recognize as a sup-

Digitized by Illinois College of Optometry

plementary condition the various stages of progressive myopia by the various colored or pigmented zones that compose the staphyloma (*Fig. 137*). A sharp outline to the staphyloma indicated by a black pigment zone (*Fig. 136*) denotes a pause in the progression; small blotches near the staphyloma, on the other hand, denote a continued progression of the disease. In pronounced myopia, particularly if it continues to progress, there finally result, although it may not be till advanced life, these changes in the retina above enumerated, through which complete blindness, or at least destruction of direct vision (macula affection) is accomplished.

Pronounced and progressive myopia is, by many ophthalmologists, sharply differentiated from the relatively benignant form of myopia, which becomes stationary in adult life; the former is con-

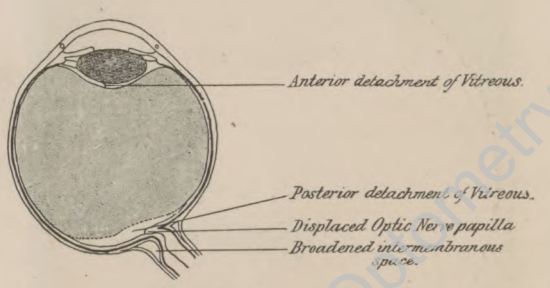

FIG. 138.—A MYOPIC EYE.

sidered an essential inflammation of the posterior pole, a *sclerotico-choroiditis posterior*. In favor of this view there is the fact that the malignant, progressive myopia is found among country people, and even in children, who really supply only a small proportion of the ordinary cases of myopia. (See sections on *Causes* and *Extent*.) Such a differentiation is, after all, of no practical significance, since benignant myopia may at any time change into the malignant, progressive form.

Diagnosis.—The fact that an eye sees distant objects less distinctly than, but near objects quite as well as, the normal eye, is the proof of the presence of myopia. To complete the diagnosis, the degree of myopia must be estimated. The objective method is given on *p. 152*, the subjective method on *p. 31*.

Causes and Extent.—Myopia is a very common and widespread disease. Native peoples are comparatively free from it, and

Digitized by Illinois College of Optometry

in that respect, at least, are "better men" than we are. In cultured races, only the age of childhood is free from myopia. As soon as school-life begins, cases of myopia show themselves, and increase in number the higher in school the children advance. H. Cohn found

in	5 village schools,	1.4 per cent.
in	20 elementary schools,	6.7 per cent.
in	2 higher girls' schools,	7.7 per cent.
in	2 grammar schools,	10.3 per cent.
in	2 preparatory schools,	19.7 per cent.
in	2 colleges,	26.2 per cent, myopic![1]

He found also that the degree of myopia increased with the length of the period of school. Axis-myopia has, therefore, been called school-myopia.[2]

It is intended to imply that attendance at school is the cause of myopia because during the growth and development of the general system, the eye is, at school, compelled to do too much near work. This near work, like reading and writing, acts very harmfully. Boys who leave school when fourteen years old, to become tailors or watchmakers, continue in the new field of labor to strain the eyes with near work, but experience teaches that, in spite of this fact, myopia is not so frequent among them as it is among their former comrades remaining at school.

The essential connection between school work and the lengthening of the eyeball is still problematic. An assumption—unproved as yet—may help to make the matter clear: children, when reading and writing, are accustomed to bend their heads forward to bring them close to the books. In many this is due to poor visual acuity from astigmatism or corneal opacities, but in others it is only a bad habit. The eyes are made strongly convergent, the visual plane is lowered, and the muscle of accommodation is kept tense. On account of the convergence the interni as well as the superior and inferior recti are kept tense, the obliqui and inferior recti also, by the lowering of the visual field. The other muscles are at least strained. They all press upon the eyeball and increase its internal tension, while the contraction of the ciliary muscle has the same effect. The eye becomes overfilled with blood by the hyperemia from work on the one hand, and, on the other, by the fact that with the head bent forward the return of venous blood from the cranium is retarded. It may be seen that an increased internal pressure causes the eye's envelopes to yield, although this does not explain why the eye is lengthened from before backward as the result of tension. This may be comprehended by studying the position and the necessary action of both obliqui. They surround the eye, at least when looking straight ahead, like a girdle, and must therefore press it into the shape of an egg if the

[1] The statistics are from German sources.—TRANSLATOR.

[2] I have just had in my care an eight-year-old boy with a myopia of *5.0* to *6.0 D*, very strong for his age. In asking him about it, I discovered that he was going to two schools, the usual elementary school and an Italian night school, for his father was Italian and wished the boy to continue his native tongue. Was this cause and effect?

Digitized by Internet Archive in Ophthalmology

contraction is sufficiently strong. In looking toward the median line, this girdle-like action is less marked, but in doing this the eye is drawn forward, and consequently raised from the fat layer in the orbit, against which the recti muscles are trying to press the posterior pole; this posterior pole is therefore robbed of its support, and a bulging is made possible.

Not all school children, not even all gymnasium pupils, are myopic. We must therefore assume that some are, some are not, predisposed to myopia. We say it is congenital. What is this congenital predisposition? Stilling deserves credit for having attracted the attention of ophthalmologists to the great differences in direction and insertion of the superior oblique tendon. The thickness and resistive power of the sclera differ in different individuals. There are probably personal differences in the structure of the ciliary muscles. Even supposing that a ciliary muscle consisting chiefly of meridional fibers relaxes the Zonula of Zinn quite as well as one supplied with circular fibers, there can be no doubt that the other mechanical effects of each, the effect upon the sclera, for example, will be quite different. The smallness of the angle *gamma* is also an anatomical peculiarity that, by making convergence difficult, may become a cause of myopia. Weiss suggests that a longer or shorter optic nerve may have its significance, since, if the optic nerve is short, convergence of the visual axes causes tension at the posterior pole, and aids therefore in the development of myopia. Thus we see that there are numerous reasons for supposing that the inclination to myopia lies in inherited anatomical peculiarities of the eyeball itself.

Treatment.—Myopia cannot be cured, but it may be prevented. If the eye is used only for distant vision it will not become myopic (neglecting exceptional cases). In a cultured people, however, school and a sacrifice of eyes to it cannot be avoided. The school must therefore be so arranged that the number of eyes so sacrificed does not pass the minimum. In Germany and Switzerland this arrangement has not up to now been satisfactorily accomplished. The rules that ought to govern house and school are the following:—

(1) The quantity of the customary daily work should be reduced, especially in the high schools. In many of these, upper-class students have, besides the six school hours, five to seven hours more of work at home, that is, eleven to thirteen hours of daily near work!

(2) Between hours of work at school and at home there should be suitable intermissions.

(3) At home and at school the student should work only in good daylight or in good artificial light.

(4) Books should be large enough, and printed in clear, well-defined type.

(5) Students should have their work at a distance of *35* to *40 cm.* from the eyes, with the visual plane only moderately lowered, and with a natural position of head and body. Benches and type should be properly adjusted for this purpose. The upright is

Digitized by Illinois College of Optometry

better than the usual oblique style of writing. This perpendicular writing is particularly advised by Schubert and others. Undoubtedly upright writing has its advantages, but the most important point is, after all, as Ritzmann observes, that the teacher should have judgment and self-denial enough to insist with an iron pertinacity that the proper distance from the work be maintained by the students.

It is the parents' duty to see that the children avoid all reading (novels !) and writing which is not indispensable for their advancement in school. All these rules must be doubly enforced if myopia is already present. If myopia increases in spite of all, a long rest should be ordered, or the school should be entirely given up. The general health should be looked after, and plenty of fresh air provided.

To prevent the advance of myopia some recommend atropin, others the very opposite, eserin. One claims that atropin is no good, another that eserin is of like value. The advantage gained from the use of either remedy does not lie in the remedy itself, but in the prolonged cessation from near work. Atropin is useful and indicated when part of the myopia is apparent, and conditioned by spasm of the ciliary muscle. Such a spasm disappears only after continued and energetic application of atropin.

The disadvantages of myopia can be, in part at least, neutralized by glasses. Should every myope wear glasses ? No ; they are often harmful and unnecessary. The following rules will generally apply :—

Myopes of *2.0 D* or less, who have no trouble at near work, but wish glasses for distant vision, should wear eyeglasses and not spectacles, and should be advised to use them only for distance. In myopia from *2.0 D* to *4.0 D* or *5.0 D*, neutralizing lenses for both near and distant work may be used, assuming that the range of accommodation is still large enough, and that the patient is young. Spectacles thus allow the book to be held at a suitable distance (*40 cm.*), and they prevent too strong convergence. Any muscular asthenopia is at the same time combated, first by a demand for more powerful accommodation, and the greater call upon the muscles of convergence associated with it; second, by the greater working distance permitted, that is, by a lessened use of convergence ; and third, by placing the lenses further apart, if this seems necessary, since by having the patient look through the inner half of the lenses instead of through their center, we obtain the effect of a prism in the position of abduction (*p. 93*).

Digitized by the Internet Archive for Optometry

In myopia from *4.0 D* or *5.0 D* to *7.0 D* or *8.0 D*, glasses for near work must be ordered which displace the far point to about *40 cm.*, and additional eyeglasses for distant vision. Suppose there is myopia of *6.0 D*, the far point then lies at only $\frac{1}{6}\ m = 16.66\ cm.$, which is much too near for comfortable convergence; if the myopia is reduced by a lens of *—3.5 D* so that it remains *2.5 D*, the far point now lies at $\frac{1}{2.5}\ m = 40\ cm.$ At this distance accommodation is not required, and only moderate convergence is necessitated. If the patient intensifies his spectacles by adding eye-glasses of *—2.5 D* his myopia is neutralized and distinct distant vision is made possible.

With myopia higher than *7.0 D* to *8.0 D*, the same plan may be pursued if no pathological condition within the eye prevents the use of lenses, or if the patient—which is usually the case—is doubly distressed by the lenses. In pronounced myopia it is often necessary to give up glasses altogether. Such a condition has induced many ophthalmic surgeons to treat pronounced myopia by extracting the lens. This method is still the subject of warm discussion. I have recently resorted to it. My first result was very encouraging; a patient had before the operation $V = \frac{4}{12}$, with *—15.0 D* ⌒ *—2.0 D cyl;* after the operation $V = \frac{4}{8}$ with *+1.5 D cyl.* When we know that patients often refuse to wear strong concave lenses, although without a lens they may not have even $\frac{4}{60}$ of the normal vision, it is plain that the removal of the crystalline lens is of great advantage to the patient.

It has been recently stated, by American ophthalmologists particularly, that total neutralization of even pronounced myopia was not only possible but even desirable; and that the patient's original repugnance to strong glasses would disappear after using them. My experience is that the glasses disappear before the repugnance does!

III. ASTIGMATISM. As.

1. REGULAR ASTIGMATISM.

The normal eye is, to a very slight degree, regularly astigmatic. This can be called physiological astigmatism, so long as it causes no visual disturbances or symptoms. Such a definition must, to be sure, allow an astigmatism of *0.75 D* to be at one time physiological, at another pathological, since in early life, so long as the

Digitized by Illinois College of Optometry

range of accommodation is large, this slight astigmatism may cause no disturbance, but in the thirties it may lead the patient to the physician. Astigmatism of more than *1.5 D* always causes disturbance, even in youth. In physiological astigmatism the perpendicular meridian is the meridian of strongest curvature; the horizontal, that of weakest curvature. This is usually the case, too, in pathological astigmatism. It is seldom the reverse, that the horizontal meridian is the stronger refractive, such a case being spoken of as against the rule, *astigmatismus perversus*. It does, however, happen often enough that the meridians of stronger and weaker curvature are not exactly perpendicular and horizontal, but are more or less oblique.

The symptoms of an astigmatic consist of reduced visual acuity or of asthenopic troubles, or of both. The reduction in visual acuity depends upon distortion of the retinal images (*p. 49*). The asthenopic troubles depend in part upon the effort the individual makes to neutralize his astigmatism by unequal contraction of his ciliary muscle, in part also upon the fact that he brings objects nearer to his eyes, in order to compensate for the indistinctness of these retinal images by increasing the visual angle; but in doing this he uses accommodation and convergence improperly. The increased effort necessitated by working with indistinct retinal images must be somewhat of a factor also. Finally, there are cases in which the complaints of the patient do not immediately suggest astigmatism, but are classed by the physician among diseases of the conjunctiva (*p. 97*).

Anatomy.—The total astigmatism of an eye depends partly upon meridian-asymmetry of the lens, partly upon meridian-asymmetry of the cornea. Corneal astigmatism being the stronger, decides the condition. In a few cases it is increased by the lenticular astigmatism, but in most cases is reduced by it; astigmatism in the lens is, therefore, as a rule, the opposite of that in the cornea.

Corneal astigmatism may be congenital or acquired—usually congenital in eyes highly myopic. In early life astigmatism is, in most cases, "with the rule." In the course of years the form of the cornea may change essentially so that from adult life on, astigmatism against the rule becomes more and more common. Astigmatism is acquired after certain operations, such as cataract extractions, iridectomy and sclerotomy; some months after the operation it is less than at first, but it never entirely disappears.

Digitized by the Internet Archive of Optometry

Lens astigmatism—apart from any congenital meridian-asymmetry—may be due to some acquired obliquity of position (*p. 358*), and is then particularly strong.

Diagnosis.—In every estimation of hyperopia and myopia by means of lenses, astigmatism must be thought of if perfect visual acuity is not obtained with the ordinary spherical lenses. It is particularly suspicious if in the rows of letters of different sizes some letters are read correctly, others incorrectly. The character of the indistinctness of the retinal image, and the form of the letter itself, will give some clue to the refractive error. For example, if the retina is at f'' (*Fig. 12, p. 48*), a small L will be recognized more easily than a large B, because in the L the perpendicular line at any rate is distinct, while the perpendicular line in the B is proportionally indistinct on account of the three confusing horizontal elements of the letter. The objective demonstration of astigmatism may be made by the ophthalmoscope (*p. 128*), while the position of the principal meridians and the degrees of their refraction may be determined by the shadow test (*p. 134*). Simple corneal astigmatism may be determined by the keratoscope (*p. 97*) and measured by the ophthalmometer (*p. 98*). The difference between total and corneal astigmatism as determined by keratoscope or ophthalmometer equals the lenticular astigmatism.

Treatment of astigmatism consists in prescribing the proper neutralizing cylindrical lenses, with the necessary correction, of course, of any hyperopia or myopia present. If there is mixed astigmatism (*p. 50*), two cylinders are required, one convex and the other concave, their axes being perpendicular to each other. Instead of two plano-cylindrical lenses with their plane surfaces joined, a single glass may be used, with the cylindrical surfaces ground upon it.

There is, in general, no contraindication to the use of cylindrical lenses. In spite of this, however, no ophthalmologist can escape the chagrin of seeing a patient neglect the glasses which have been selected with great care and which essentially improved the vision. If the patient is asked why he does not wear these glasses, he will answer that they make his head ache or cause vertigo. The reason for this is not always clear. Much depends upon having the axes of cylindrical lenses correspond exactly with the principal meridians of the eye. For this purpose test frames (*Fig. 139*) have been arranged so that the cylindrical lenses in a separate clasp can be

Digitized by Illinois College of Optometry

revolved about the rigid part of the frame, the circumference of which is divided into degrees. The best position for the cylinder must be found by trial, and the position of its axis noted on the test frame. It is always advisable carefully to see that the physician's prescription for glasses is followed by the optician in every detail of refraction, position of axes, pupillary interval, and distance from the eyes. Errors are not uncommon.

Just as astigmatism may be caused by an obliquity of the crystalline lens, so may astigmatism be neutralized by holding spherical lenses obliquely before the eyes. Myopes with astigmatism (astigmatismus myopicus compositus) are very often content with simple spherical lenses, for they have noticed by accident that they can see much better when looking obliquely through their glasses, and they make practical use of the discovery by turning the head in one direction and the eyes in the other, thus looking obliquely through the glasses.

There is another explanation for the fact that myopes are inclined

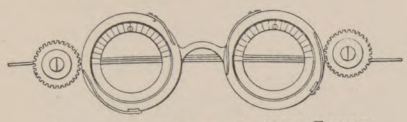

FIG. 139.—RODENSTOCK'S TEST FRAME.

to look obliquely through their glasses. In many cases the myope does not try to correct astigmatism, but to produce it, in order to acquire better visual acuity. Such a myope has too weak glasses; the image of a distant object still falls in front of his retina, in spite of his glasses, while on the retina there is an image combined with diffusion circles. If now such a myope looks obliquely through his glasses, he produces an astigmatism in which each luminous point has an anterior and a posterior linear focus, the posterior linear focus falling (under certain conditions) exactly on the retina. Objects whose linear prolongations coincide with the direction of these linear foci are therefore seen more distinctly than if they were looked at directly through the glasses.

2. IRREGULAR ASTIGMATISM.

This is understood to signify a condition of the dioptric system in which there is no image formed even by the rays of a homocentric pencil—that is, by rays falling upon the same principal

Digitized by Illinois College of Optometry

meridian. The normal eye is irregularly astigmatic, although to a slight extent only. This may depend upon "spherical aberration," that is, upon the fact that luminous rays in passing through a spherical surface are united the sooner the greater the angle of incidence; in *Fig. 140* angle β is greater than angle α, consequently the image *b* is nearer to the refracting surface than the image *a*. The flattening of the cornea at the periphery reduces the spherical aberration of the eye and makes it to some extent aplanatic, while the exclusion of the excentric incident rays by the iris accomplishes the rest. The noticeable irregular astigmatism of a healthy eye depends upon the structure of the lens. A star does not appear to us as a luminous point, but as "star-shaped"—that is, as a point with rays, the structure of the crystalline lens being responsible for the condition. In the aphakic eye this phenomenon is not present.

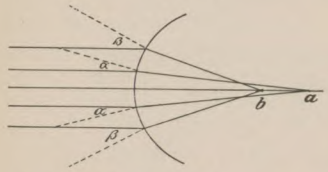

FIG. 140.—SPHERICAL ABERRATION. The dotted lines are perpendiculars to the spherical surface.

Irregular astigmatism of pathological nature causes reduction of visual acuity below the normal. Sulzer assumes that the extraordinarily numerous cases of imperfect visual acuity without visible cause depend upon irregular curvature of the cornea. The same is true for the numerous cases of regular astigmatism in which perfect visual acuity cannot be obtained even after correction with cylindrical lenses—a combination of regular with irregular astigmatism. A very common cause of irregular corneal astigmatism is a corneal opacity (*p. 254*); an uncommon cause is keratoconus (*p. 259*).

Irregular lenticular astigmatism is produced by opacities or by clefts in the lens, which precede genuine cataract (*p. 336*). There is no treatment for irregular lenticular astigmatism. Great optical success has been attained in correcting corneal astigmatism with "stenopaic glasses" (*p. 51*), that is, untransparent disks having a small hole in the middle for looking through. The smallness of this hole prevents rays from being received on all but an extremely limited corneal area, the curvature of which may be considered regular; the practical use of stenopaic glasses is, however, decidedly limited by the circumstance that such a small hole admits of only an extremely restricted visual field, and of no excursional field at

all! Roth tries to overcome this drawback by using disks—"sieve glasses"—provided with numerous small holes of *1.4* to *2.2 mm.* diameter. The visual field is not narrowed by such a disk, but only interrupted by unimportant shadows; eye-movements are not excluded, since at every change in the position of the eye another hole lies in front of the pupil, which may be used directly to look through.

3. ANISOMETROPIA.

Anisometropia is the term used to indicate an inequality of the refractive condition in the two eyes. It may be present in innumerable modifications—as myopia and hyperopia of different degree, as emmetropia in one eye, myopia or hyperopia in the other, or myopia in one eye, hyperopia in the other. If both eyes are myopic, but in different degree, the right eye has usually the greater error, since even in normal binocular vision the right eye is used for greater precision than is the left.[1]

Occasionally anisometropia of the two eyes is associated with distinct asymmetry of the orbit, forehead, and face.

How does the anisometrope see? There are three possibilities to be considered:—

(*1*) He sees with only one eye and completely neglects the other for both near and far objects. This is the case if the visual acuity of one eye is unusually better than that of the other. This may generally be surmised from the position of the eyes, since the eye excluded from vision deviates outward.

(*2*) The anisometrope uses his eyes alternately, that with the weaker refractive power being used for distant objects, the other with the greater refractive power for near objects. In this condition there may be such a correct position of the eyes and such good vision that the patient himself is not aware of any defect, or is, on the contrary, rather proud of an extensive range of accommodation (when the eye with greater refractive power is myopic).

(*3*) The anisometrope fuses the two retinal images, and has, therefore, binocular vision in the narrower sense of the word. He can do this, even though the retinal images are unequally distinct, or perhaps even of different size. If vision is concerned with an object lying within the range of accommodation of both eyes, exact

[1] Other investigators find greater myopia quite as frequently in the left eye as in the right.

Digitized by Illinois College of Optometry

dioptric adjustment in both eyes may be attained by accommodating unequally for each eye. The majority of ophthalmologists, Donders included, consider this impossible. On the other hand, a minority, with v. Graefe,[1] are of the opinion that the association of both eyes in an exactly equal accommodation may be to a slight degree dissolved by a natural or artificial difference in refraction.

I think that I have offered a proof that unequal accommodation is possible within certain limits and actually does occur in anisometropia, although my proof has been attacked by Greeff, and particularly by Hess. In spite of that I cannot admit that my view has been refuted, and I hope to be able later to contradict the objections raised against it.

I had a short time ago a case that seemed to me to demonstrate unequal accommodation in a manner quite free from objections. A woman consulted me on account of asthenopic troubles. The shadow-test disclosed compound hyperopic astigmatism; the test letters showed this condition only in the left eye, while the right eye accepted a cylindrical but no spherical lens. I concluded that in the right and more acute eye there was latent hyperopia, but in the left eye manifest hyperopia as well. Two doses of homatropin proved that my assumption was correct, for now not only the left but the right eye also accepted a spherical lens—on the right a lens of $+3.0\ D$. If this clearly indicated unequal accommodation, it became a certainty when I had occasion eight days later to test the glasses prescribed by me. I examined the patient again with the following result: while the right eye, with a simple cylindrical lens, was fixing letters ($D = 4$) at $4\ m.$, the refractive condition of the left eye was determined by skiascopy; then the test letters were removed, and as the right eye was gazing into space, the left eye was again tested by skiascopy; in both cases the refractive condition of the left eye remained the same, that is, unchanged, while the refractive condition of the right eye had varied to the extent of $3.0\ D$.

In choosing glasses we must consider which of the three possibilities is present. In (*1*) no attention need be paid to the weaker and neglected eye, and only the refractive error of the better eye need be neutralized by the rules already given. In (*2*) some cases need no glasses at all, at least so long as the range of accommodation is not too small. If, for example, the left eye is emmetropic and the right myopic $4.0\ D$, and if the eyes are used alternately, the patient can cover as much ground with an accommodative range of $4.0\ D$ as can a normal pair of eyes with an accommodative range of $8.0\ D$, that is, from ∞ to $\frac{1}{8}\ m. = 12.5\ cm.$ in front of the eye. If the range of accommodation of this patient sinks to $2.0\ D$, he will see distinctly with the left eye from ∞ to $\frac{1}{2}\ m. = 50\ cm.$, and with the right eye from $\frac{1}{4}\ m.$ to $\frac{1}{6}\ m.$, that is, from 25 to $17\ cm.$, but between $50\ cm.$ and $25\ cm.$ he will not see distinctly with either eye; a convex lens of $2.0\ D$ in front of the left eye

[1] Symptomenlehre der Augenmuskellähmungen. Berlin, 1867. Seite 63.

would be of service in this case. In (*3*) the anisometropia should be totally neutralized. If the patient is young and hindered by no latent squint, he will grow accustomed to the glasses after a period of discomfort. Equally strong accommodation on both sides is only desirable in getting accustomed to the neutralizing glasses. If the total correction is not borne, a partial correction of the anisometropia must suffice, or the anisometropia left quite uncorrected. I have never had an example of this last.

AMBLYOPIA AND AMAUROSIS.

Dulness or weakness of vision and blindness are pathological signs with which we are often met. We are accustomed, however, to use the terms amblyopia and amaurosis in a narrower sense, also, for diseases whose anatomical characteristics are either quite unknown or at least productive of no demonstrable changes in the eye itself.

1. AMBLYOPIA WITHOUT LESION.

(*a*) **Amblyopia ex Anopsia** (*Weaksightedness from Disuse*).—If a child hitherto healthy begins to squint, he will see double. To obviate this distressing symptom the child learns by a mental act to suppress in the squinting eye the image of the object fixed by the other eye. If this suppression is practised for weeks, months, or years, there results a permanent change in the nervous apparatus of the visual organ, which is recognized as a greater or less reduction in visual acuity, and is called weaksightedness from disuse—*amblyopia ex anopsia.*

It is evident from the above that weaksightedness from disuse does not develop in adults beginning to squint (from a muscular paralysis, perhaps); the nervous apparatus in the latter case is at complete maturity, and the suppression is therefore unsuccessful. It is quite as evident that weaksightedness from disuse does not result in children whose eyes are prevented from seeing by some optical hindrance (corneal opacities or cataract); suppression is here not called for; the eyes rather seek to make use of all light penetrating to the retina. If, on the contrary, an eye is optically of little value, squint almost always results and there is an associated amblyopia of that eye.

The development of amblyopia may be prevented by daily compelling the squinting eye to perform independent vision, even if only for half an hour, the other eye being bandaged. It must be confessed that this method soon becomes tedious to the patient and the parents, but even an amblyopia already existing may at times be improved by such exercise to the weak eye.

(*b*) **Hemeralopia** (*nightblindness, night-shadows, pp. 53 et seq.*)

Digitized by Illinois College of Optometry

indicates a reduced sensitiveness of the visual organ to a weak stimulation of light. The result of this condition is such that acuteness of vision and color-sense begin to decline, or are quite obliterated in an illumination that permits normal vision to a healthy eye. Nightblindness is either a symptom, and as such has been already mentioned in retinitis pigmentosa, chororetinitis syphilitica, choroiditis, and prolapse of the retina, or it is a disease of itself. It may be congenital, and is then a rare condition perpetuated unchanged during life; it is, however, oftener acquired and may then be cured in a few weeks, this, as an acute form, being distinguished from the chronic, congenital condition.

Nightblindness may be due to two causes:—

(1) Overstimulation (blinding) to the eye.

(2) Lack of proper nourishment to the general body.

If both conditions occur, the disease is more certain to show itself. For example, "night-shadows" are nearly endemic at Easter among Russians of the lower class; these people are greatly impoverished by the rigor of the northern winter and by the severe seven weeks' religious fast, but they must at that time begin outdoor work again and thus expose themselves to the blinding rays of the spring sun. Sailors, after a long cruise, are similarly affected; the plain sea diet with no fresh meat and vegetables reduces the bodily strength and leads probably to scorbutus; the reflection of the sun's rays from the sea's surface is dazzling. Prolonged marches on plains of snow lit by a bright sun (Alpine tours) may cause nightblindness. It must be observed, however, that in this "snow-blindness" there is not only hemeralopia, but also, and principally, a genuine inflammation of the anterior segment of the eye—conjunctiva, cornea, and iris—which is produced through the ultra-violet "chemical" rays of the light reflected from the snow.

Since hemeralopia is a symptom of certain retinal diseases, it may justly be assumed that "nightblindness without lesion" is still situated in the retina. The nature of the disease may be imagined as a disturbance of equilibrium between production and consumption of visual material.

Many ophthalmologists consider dazzling and poor nourishment insufficient to cause nightblindness. They think, rather, that these conditions only incline a person to sicken, but that the essential cause of the disease consists of a miasm (only suspected, to be sure, but not yet demonstrated).

Treatment consists—

(1) In withdrawal from all bright light by confinement in a darkened room or by the use of protecting glasses.

(2) In improvement of the general health by proper nourishment, fresh meat, and vegetables; if the patient wishes medicine, cod-liver oil may be prescribed; it tastes like medicine and is a good food.

(*c*) **Color-blindness** (*pp. 57 et seq.*).—There is partial or complete color-blindness. Complete color-blindness is the inability to distinguish qualitative (color) differences, the spectrum being recognized only as light or dark. Partial color-blindness is the condition in which only some of the spectrum waves are recognized as specific (color) sensations. By far the most common form of partial color-blindness is Daltonism,[1] or red blindness. The majority of cases are associated with green blindness. The red-green blind person, or the one whose blindness alternates—either red or green—sees the spectrum in two colors, yellow and blue. What the healthy person perceives as red, orange, yellow, and green, he perceives as different shades of yellow; what the healthy person perceives as blue-green, appears to the latter as colorless, the rest of the spectrum being blue. In a corresponding way the blue-blind person is at the same time yellow-blind; the spectrum is for him composed of only two colors, green and red. Blue-yellow blindness is extraordinarily rare. Complete color-blindness implies that no colors at all are seen in the spectrum, and that the entire spectrum appears to be composed of lines of brighter or darker grays.[2]

Color-blindness, complete or partial, may be either congenital or acquired. If acquired, it is a pathological sign that in the majority of cases is to be referred to a disease of the optic nerve, less frequently to disease of the inner retinal layers or of the brain. Congenital color blindness is a condition about the cause of which nothing is known. It is commoner in men than in women, and has a tendency to jump over a generation in its inheritance.

(*d*) **Nervous asthenopia** (Wilbrand) shows itself in many forms. In school children it causes complaint of haziness, dimness of letters and lines, occasional double vision, blinding by lamp or even daylight, lacrimation, pain in the forehead and eyes. In examination we find reduction of visual acuity to $\frac{2}{3}$, or even $\frac{2}{7}$, and concentric narrowing of the visual field growing more prominent as

[1] Dalton, an English physicist, suffered from red blindness and was the first (in 1798) to describe the condition accurately.

[2] An examination of the various theories of light and color sensations is not within the plan of this book.

Digitized by Illinois College of Optometry

the perimeter is used, a fact explainable as a phenomenon of exhaustion. This restriction is peculiar in that it appears of varying magnitude according to the size of the test object used. This explains the fact that such children are not in the least hindered in finding their way about the room, a condition that obviously must be noticed in a visual field absolutely narrowed, as in atrophy of the optic nerve, for example. Color sense is normal and the fundus unaffected. The examination of the body in general shows hyperesthesia and anesthesia of the skin in various localities.

A similar condition is found in adult neurasthenics, but in their cases the complaints of eye pain and dazzling are more prominent. The visual acuity is normal; narrowing of the field for white and often for colors can be demonstrated. In pronounced hysteria[1] the condition is very marked; *Kopiopia hysterica* is the name given to it. Besides pain, dazzling, reduction of visual acuity, and narrowing of the visual field, usually in one eye, there may be spasm of the lid, weakness of the ciliary muscle, eye-muscles, and of the levator; greater disturbance of color sense, and, finally, a host of sensible and motor paralyses and pareses in all regions of the body.

Before the diagnosis of nervous asthenopia is made from the foregoing subjective symptoms, we must see whether the pathological condition does not depend upon some refractive error, such as hyperopia or astigmatism, or upon some conjunctival trouble or weakness of the internal recti. The ophthalmoscopic evidence also must be negative.[2]

In cases where there is a doubt whether reduced vision with concentric narrowing of the field and disturbance of color-sense is due to hysteria or to a deep lesion of the optic nerve, the further course of the disease will explain matters; optic-nerve atrophy leads continuously to the bad; hysterical amblyopia, on the other hand, arises suddenly, remains for some time unchanged, and disappears as suddenly as it arose.

Opinions differ as to the localization of the disturbances. Knies thinks that they are peripheral, about at the place where the nerves pass through narrow, bony canals and are

[1] From ἡ ὑστέρα, the uterus. It was once the belief that the chameleon-like disease called hysteria was seen only in women and had its origin in the uterus. It is now known that men, too, are similarly affected.

[2] Bernhardt finds that in many cases of nervous asthenopia there is really a slight paleness of the temporal half of the optic disc.

Digitized by the Columbia College of Optometry

easily compressed by dilatation of the blood-vessels. Most authorities think that they are central, that is, located in the cerebral cortex.

There is a particular tendency to such diseased conditions among hereditary sufferers—persons whose parents have been victims of nervous diseases. As immediate causes may be named over-exertion at school or in the struggle for existence, injuries (traumatic neuroses), often of a trifling nature, and diseases of the female genital organs (Kopiopia hysterica).

Treatment must be chiefly—

(1) Relief to the eyes by rest from work and by the use of dark glasses; these may even restore normal vision for a moment; it may then be assumed that the reduced visual acuity was due to dazzling.

(2) Improvement in physique by wet dressings, massage, open-air exercise, and good food.

(3) By suggestion in the form of simple medicines and metallo- and electro-therapy.

APPENDIX.

Simulation, Malingering.—It occasionally happens that a person declares that he is blind or weaksighted in one eye; if this eye is normal, we speak of simulation; if the eye is really amblyopic and the symptoms merely exaggerated, we speak of aggravation. Simulation and aggravation are not really diseases, but as the ophthalmologist is often concerned with them, they must be briefly considered.

Simulants (malingerers) state as a rule that only one eye is weak or blind, since it is easier to play that part than it is to pretend to be weaksighted or blind in both eyes. Their reason for simulation is the wish to escape military service or to get damages on account of an injury from some corporation or insurance company; other simulants, particularly hysterical women, have only the impulse to make themselves interesting. In some cases, especially in children, no rational cause can be discovered.

The physician's task is to unmask the simulant. Many ingenious devices have been used, all depending upon the fact that the normal individual does not, in his visual perceptions, take into account whether they come from his right or from his left eye, or from both. For example, if a pencil is held between a book and

Digitized by Illinois College of Optometry

the eyes, the pencil does not obscure the same word or part of it from the right eye as it does from the left; reading can go on, then, uninterruptedly, the reader being unconscious of which word is seen by the right eye alone, which by the left alone, and which by both eyes together. An individual who claims to be blind or weak-sighted in one eye, is proved to be simulating if he can read uninterruptedly under the condition just given. The size of the type read is at the same time a test of the visual acuity of the eye assumed to be blind or amblyopic.

Another trap—place before the eye asserted to be normal a strong convex lens, say of *10.0 D.* Assuming it to be emmetropic, it can then read fine type at $\frac{1}{10}$ *m.* from the lens at the most. Now, appearing to pay no attention to the eye asserted to be blind or weak, the test-type is gradually removed beyond the focal distance of the convex lens. If the person is still able to read in spite of this, it is evident that he reads with the blind or amblyopic eye!

A third method depends upon the production of double images by prisms, for which certain precautionary measures must be adopted. Simulants suppose that the acknowledgment of double images is equivalent to the confession of binocular vision; they therefore persistently deny double images. It consequently becomes necessary to convince the person examined that he can see double with only one eye. For this purpose the eye asserted to be blind is covered, and in front of the other eye there is placed a prism so adjusted that it covers only one-half the pupil, the other half being left uncovered. Any object fixed will now appear double, since rays refracted by the prisma produce one retinal image lying beside the image produced by the rays entering the pupil directly. After the person has acknowledged the double images and described their location, the cover of the (asserted) blind eye is as if by chance withdrawn, the prisma being at the same time advanced so that it now covers the entire pupil of the sound eye. If the person now acknowledges the appearance of double images, it is a proof that he can see with each eye.

Still another method depends on the fact that colored letters on a dark ground cannot be seen through glasses of the complementary colors,—green-blue letters, for example, are invisible if looked at through red glasses, because the green-blue rays proceeding from the letters are not transmitted through the red glass. If now green-blue test letters on a dark ground are offered to the person

Digitized by Illinois College of Optometry

for reading while he wears a green glass over the (asserted) blind eye and a red glass over the sound eye, the sound eye will be prevented from seeing the letters, and if the person says he recognizes and reads the letters under these circumstances, it can be done only by the (asserted) blind eye! The size of the letters read is at the same time a test of the visual acuity.

2. INTOXICATIONS.

(*a*) **Uremic Amaurosis.**—In many diseases of the kidneys, particularly in scarlet fever nephritis and in the nephritis of pregnant and puerperal women, uremia may result, a pathological condition dependent upon supersaturation of the blood with urinary ingredients. Uremia shows itself in mild cases by headache, dulness, oppression, nausea, and vomiting, and by twitchings and tonic contractions of the face and limbs; in severe cases there are also spasms and coma. An occasional result of uremia is uremic amaurosis, that is, total blindness of both eyes, appearing sometimes suddenly, sometimes after a day or so of diminished visual acuity. Blindness may be so complete that light cannot be distinguished from dark, or even that the pupils no longer react to light stimulation. If the patient survives an attack of uremia, the blindness may completely disappear in a few days. Since the ophthalmoscopic examination shows a normal fundus, this amaurosis depends obviously upon some disturbance in the brain. In cases (rare, indeed) where even the pupillary reflex is lost, we must assume that not only is the center for optical perception, but also the region of the corpora quadrigemina, in which lies the center for reflex pupillary action (*Fig. 113, p. 305*), diseased.

(*b*) **Diabetic Amblyopia.**—The numerous diseases of the eyes resulting from diabetes include also an amaurosis without lesion. This may lead the patient to the physician before the usual symptoms—loss of flesh, muscular weakness, great hunger and thirst, increased excretion of urine—have made it clear that there is a deep-seated disease. Nothing positive is known of the cause of diabetic amaurosis, but small hemorrhages or fatty degeneration in the optic nerve have been suspected.

(*c*) **Blindness from Malarial Fever and Quinin.**—Cases of malarial fever have been reported in which bilateral blindness occurred every time at the beginning of the febrile attack, and disappeared with the critical sweat, after six to eight hours. The remedy

Digitized by Illinois College of Optometry

for malaria, quinin, proved itself to be effective against this amblyopia also. Strange to say, other cases have been reported in which large doses of quinin have produced bilateral amblyopia. An analogous effect of quinin upon the auditory apparatus is a well-known phenomenon, a small dose, even one gram, being enough to produce ringing in the ears and deafness. A reduction of visual acuity by quinin (quinin amblyopia) is not uncommon. In rare cases this amblyopia may go on to complete blindness. The retinal vessels are then seen to be narrow, the discs pale. It may be assumed that quinin amaurosis depends upon ischemia of the retina.

3. WEAKSIGHTEDNESS AS A SIGN OF CEREBRAL DISEASE.

(*a*) **Hemianopsia.**—Semi-blindness denotes the obliteration of half the visual field in both eyes, arising from a localized cause common for both eyes. If this obliterated half of the field is the

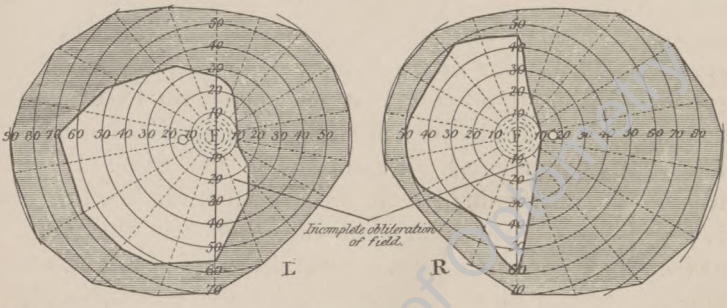

FIG. 141.—HOMONYMOUS HEMIANOPSIA, RESULTING FROM UNILATERAL CEREBRAL HEMORRHAGE. The darkened areas indicate the obliterations. The normal areas remaining are contracted.

same in both eyes, for example, that half of the field to the right of both eyes, we speak of homonymous hemianopsia. This occurs most commonly in a lateral half of the field, rarely in the upper or lower half of the field. The line of separation between the normal and the obliterated halves of the field in lateral homonymous hemianopsia runs perpendicularly through the fixation point; in many cases, however, it passes to the side of this point, so that the normal portion of the visual field extends 2°, 5°, or even 10° into the territory of affected area. This area is called the "atypical field" (*Fig. 141*).

The anatomical reasons for this atypical field are still under dispute. Wilbrand advances the view that fibers from both optic tracts supply the central retinal area. Foer-

Digitized by Illinois College of Optometry

ster has described a case of bilateral homonymous hemianopsia in which complete blindness did not occur, as naturally would at one time have been assumed, but there remained a small central field with retention of good visual acuity (about ½). Foerster, therefore, repudiates the theory of a supply to the retina from both tracts, and concludes that that part of the cerebral cortex connected with the center of the retina is more luxuriantly supplied with blood-vessels than is the rest of the cortex, and that, therefore, in spite of thrombosis of the principal vessels, such a part of the cortex would still be nourished with blood. Finally, v. Monakow, who disputes the theory that certain areas of the retina are exclusively associated with certain areas of the cortex, or considers such a theory at least unproven and improbable, explains the escape of the central area of the retina by the assumption that it is in association with a much larger part of the cortex than is any other area of the retina.

Visual acuity, color sense, and the edges of the field of the retinal halves still functionating, may all be normal. There is, to be sure, a gradual contraction of the field still remaining. A right-sided hemianopsia causes more disturbance than does a left-sided one, because we read and write from left to right. The ophthalmoscopic examination is normal.

If both obliterated halves of the visual field are at the temporal side of the fixation point, that is, one to the left side and one to the right, the condition is spoken of as "temporal hemianopsia." A "nasal hemianopsia" is perhaps possible, but no such case has been described which might not have another significance. It must be supposed that disease of the retinæ and optic nerves can produce all possible forms of restrictions in the visual fields, but according to the definition given above (*p. 390*) they are not to be considered hemianopic in their nature.

The reason for hemianopsia will be seen by examining *Figs. 112* and *113* (*pp. 304, 305*). If the right optical tract or its connections with the cerebral cortex are interrupted, or if the center for optical perception (cortex of the occipital lobe) becomes incapable of functionating, a left-sided hemianopsia must result, and *vice versa*. Temporal hemianopsia is obviously produced by a lesion at that part of the chiasm where the decussating fibers of both tracts are interwoven. Since the fibers that do not decussate are never in contact with each other, it is scarcely possible that the same single lesion can affect both bundles of fibers and destroy their function of caring for the temporal halves of the retinæ (nasal halves of the visual field) at the same time.

As anatomical causes of hemianopsia have been found cerebral hemorrhages, emboli, injuries and tumors, seated partly in the cortex, partly at the base of the brain.

The clinical significance of hemianopsia is of pathological import, since, taken with other signs (hemiplegia, aphasia, hemianesthesia), it may be used for the localization of a brain lesion.

Digitized by Illinois College of Optometry

(*b*) **Amaurosis partialis fugax**, transient hemianopsia, may occur as an attack of blindness lasting usually no more than fifteen or twenty-five minutes. The attack begins with the phenomenon of a dark spot at the same place (homonymous) in both eyes. This scotoma spreads centrifugally but remains confined to the temporal half of one visual field and the nasal half of the other. Flickering shadows are now seen, which move about in a zigzag manner (*teichopsia*), while the edge of the dark spot expands toward the edge of the visual field. The flickering finally ceases and the dark spot disappears.

The disease must be seated in the brain cortex. It is often associated with unilateral headache (migraine), vertigo, malaise, disturbances of speech and of memory, and other like irregularities referable only to the brain. It may be assumed that the symptoms are due to arterial spasm, and that the flicker scotomata, malaise, and vertigo refer to such a spasm in the cortex, the unilateral headache to spasm in the dura mater.

The first attack distresses the patient very much, but he soon convinces himself of the harmlessness of the symptom. **Treatment** must consist of regulation of the daily life and restriction in mental exercise. Quinin and bromid of potassium have been advised.

GLAUCOMA.

1. INTRODUCTION.

Glaucoma[1] is applied to a disease still obscure in many respects, but *characterized by* the essential sign of *increase in intraocular pressure*. This does not imply that every eye with increased tension is glaucomatous, or that an eye is not glaucomatous because at a particular instant the tension is normal. The interpretation is rather the following: nearly all pathological signs of glaucoma are directly or indirectly the results of increased tension, but the cause of this tension modifies the diagnosis and is still the starting point for all theories of glaucoma. These theories agree in only one particular,

[1] The name refers to the greenish discoloration of the pupil; although the same appearance is commonly seen in old and healthy eyes, if only the pupil is dilated enough. The discoloration is, therefore, suggestive of glaucoma only in cases where the pupil is dilated, as it is in glaucomatous eyes, whereas old persons usually have contracted pupils.

Digitized by Illinois College of Optometry

namely, that increased tension depends upon increase in contents within the eye. The deeper question as to the cause of this increase in contents is, even to-day, an unfailing source of scientific battle.

On the other hand, there is general unanimity concerning the changes in the eye which may be considered as resulting from this increased tension. These changes appear in different forms, according as the increase in tension is rapid or slow; in the latter case the consequences are less conspicuous, because the eye has time to accommodate itself to the altered relations of tension.

(*a*) Let us assume that there takes place a rapid increase of tension resulting from increase in vitreous in an eye quite healthy up to that time. The immediate consequence will be that the lens is pressed forward and the zonule of Zinn stretched. The advance of the lens is shown by *shallowness of the anterior chamber;* the stretching of the zonule of Zinn by *reduction in range of accommodation,* the contraction of the ciliary muscle being now unable to relax the suspensory ligament completely.[1]. A further consequence is a profound change in the circulation in the eye. The blood passes into the retinal vessels only during the systole of the heart, while at the moment of diastole the eye's internal pressure overcomes the blood pressure and the arterial walls are squeezed together. For this reason an *arterial pulse in the retina* becomes visible with the ophthalmoscope. *The retinal veins are tortuous and swollen* in consequence of the compression on the spot where the vein bends at right angles in passing from the retina into the optic nerve. In the same way the venæ vorticosæ are squeezed by the pressure within the eye just where they pierce the sclera obliquely. The result is that an abnormal amount of blood is discharged from the eye through the *anterior ciliary veins* and they become therefore *dilated and tortuous.* A third consequence is a *cloudiness of the cornea.* Pressure opacity may be produced at any time in the eye of a cadaver or of an animal; it might be supposed, therefore, that the opacity of glaucoma was a purely mechanical pressure opacity explainable by unequal stretching of the corneal fibrils; but the matter is not so simple (compare *p. 253*), since pressure opacity disappears as soon as the pressure is removed, while glaucoma opacity disappears only by degrees. Nor is the cornea alone

[1] Knies explains the reduction in range of accommodation to be due to round-cell infiltration into the ciliary muscle.

Digitized by the Columbia University Library

cloudy, the aqueous, perhaps even the vitreous, showing the same condition.

Further results of rapid increase in pressure impress the ciliary nerves in the form of pain radiating toward the forehead and upon the face (ciliary neuralgia), and the nerve fibers supplying the sphincter pupillæ and cornea (paralysis). A paralysis of the sphincter makes the pupil large and immovable (iridoplegia), and paralysis of corneal nerves makes the cornea insensitive.

Finally, a result of rapid increase in tension may show itself as inflammation. A purely mechanical explanation of this fact is quite impossible. The inflammation is evidenced by lacrimation, redness, and swelling of the conjunctiva and lids, by cloudiness of the aqueous (and vitreous ?), and by discoloration of the iris ; even posterior adhesions have been observed. The corneal opacities and the pain may, of course, be ascribed to the inflammation itself (*p. 402*).

It is obvious that these changes must severely disturb the visual acuity, which, with a cloudy cornea, may sink even to the mere ability to count fingers. If this reduction in vision depends solely upon opacity of the refractive media, the field of vision will be of normal extent ; but if retina and optic nerve are injured by interruption to the blood current, there will be, besides a reduction in visual acuity, a distinct contraction of the visual field. If the increased tension is very decided, retina and optic nerve refuse altogether to functionate, the eye cannot even distinguish light from darkness, and is therefore amaurotic.

(*b*) Let us assume another case, in which, by increase in the vitreous, an increase in internal pressure results very gradually. There is no sign of inflammation, pain only slightly or not at all complained of ; but the anterior ciliary vessels are dilated and tortuous, the anterior chamber is shallow, the pupil moderately dilated, and the iris sluggish in movement. In addition, there is one more sign that is of the greatest diagnostic importance—*the excavation of the optic-nerve sheath*. This sheath is the portion of the fundus offering the least resistance, and has been softened, perhaps, by some inflammatory process (*p. 402*). As a consequence of continued increase in pressure, the nerve gives way, and in time an excavation is produced. Hand-in-hand with the crowding of the optic nerve backward there is *atrophy of the nerve fibers*. The result is that the field of vision becomes contracted, and the acuity of vision declines till total blindness is the final outcome.

Digitized by Illinois College of Optometry

Glaucoma as an idiopathic disease usually attacks persons of fifty or beyond, although younger persons are not altogether out of danger; a case of glaucoma has been reported in a five-year-old boy. Hyperopes are more disposed to glaucoma than emmetropes; myopes are least affected; a particular predisposition is found in those who suffer from trigeminal neuralgia. Both eyes are attacked, as a rule, although not necessarily at the same time; the interval between the disease in the first eye and that in the second may be only a few hours, or it may be twenty years.

2. VARIETIES OF GLAUCOMA.

A. PRIMARY GLAUCOMA.

Glaucoma is called primary if it occurs in an eye previously healthy; secondary, if in an eye already affected by some disease.

(*a*) **Glaucoma Acutum** (*Inflammatory Glaucoma*).—*Prodromal symptoms* usually precede an attack of idiopathic glaucoma. They consist of moderate pain in the eye and its surroundings, haziness or actual cloudiness of the visual field, and the appearance of colored rings about flames of light, this last being a phenomenon of diffraction due to a moderately diffused corneal opacity.[1]

If occasion offers to examine an eye during such a prodromal stage, it is found to be of moderately increased tension; the conjunctiva is hyperemic, the cornea soft and delicately "smoky," the aqueous similarly cloudy, the pupil moderately dilated—in short, all the consequences just described of rapid increase in tension of moderate degree. Such symptoms appear at intervals, and each attack may subside without injuring the eye. It may be repeated for weeks, months, or even years, but finally a severe attack occurs, which is the fully developed glaucoma, *glaucoma evolutum*.

A developed glaucoma is easy to recognize during an attack. The association of inflammation and dilated pupil is seen in no other disease of the eye,[2] while it may be noted that the redness of glau-

[1] Colored rings around flames are seen by any person whose corneal surface is smeared over by a finely diffused conjunctival secretion (see *p. 186*).

[2] Of course, it is assumed that the dilatation of the pupil is not the effect of atropin. The very first question addressed to any patient with an inflamed eye and dilated pupil must, therefore, always be whether he has not already been treated by a physician.

Digitized by the University of Illinois College of Optometry

comatous inflammation has its own peculiar somberness. If there is also an increase in tension, the presence of glaucoma can no longer be in doubt.

In spite of all this an attack of acute glaucoma is at times mistaken. It may happen that intense headache, fever, and vomiting takes away any suspicion that the eye is involved, and leads to the diagnosis of some general systemic disease. Confusion with serous iridocyclitis is also possible, since in the latter the pupil is dilated, though not so noticeably as in glaucoma, and the tension is increased; but in serous iridocyclitis the anterior chamber is deep; in glaucoma, on the contrary, it is shallow. Moreover, the deposits on the posterior surface of the cornea, which are so unusually characteristic of serous iridocyclitis, are never, or only in the most insignificant degree, present in glaucoma.

The course of the disease may vary considerably. In the worst, and, fortunately, the rare cases, the result of the first attack may be, within a few hours, total and incurable blindness—*glaucoma fulminans.* The rule is that the storm breaks after days or weeks of severe pain, but leaves behind it a permanent increase of tension with all its dire consequences. This is shown in excavation of the disc, reduction in visual acuity, and contraction of the visual field. After a time a new attack occurs, producing further impairment, until finally the eye becomes of stony hardness and totally blind; this condition in progressive glaucoma is called *glaucoma absolutum.* The pathological storm may not calm down, the eye may remain somewhat inflamed and, of course, with increased tension, and this condition is called *chronic inflammatory glaucoma.*

(*b*) **Glaucoma Simplex** (*Simple Glaucoma*).—The essence of simple glaucoma, also, is increase in tension, but this increase develops so slowly that the patient fails to notice its consequences. Gradually, however, after these consequences have made a lasting impression, the patient notices some impairment in vision. An examination by the surgeon at this time shows reduction in visual acuity and contraction of the visual field, more or less marked as the disease has been of longer or shorter duration. The form of the visual field is somewhat peculiar; that is to say, it is contracted with preponderant involvement of the nasal half (*Fig. 142, a, left visual field*). As the disease progresses the visual field contracts more and more, so that finally there remains only a segment on the temporal side (*Fig. 142, b, right visual field*).

The objective examination shows that the visual disturbances are not due to changes in the refractive media, but depend upon the excavation within the optic nerve sheath and upon the associated atrophy of the nerve fibers.

Digitized by Illinois College of Optometry

measured by a practical tonometer (*p. 139*), which might have supplied trustworthy evidence. Second, it may be assumed that tension is increased only at intervals; this accords with the fact that in simple glaucoma, also, haziness and the appearance of colored rings around flames are noticed only at intervals. Finally, it must be remembered that there are hard eyes and soft eyes, but that in neither does the tension go beyond the normal; and that the resistance of the optic-nerve sheath is not the same in all eyes. It may therefore happen that a moderate increase in tension in an originally soft eye, with a disc lacking resistive power, may result in an excavation, although the eye appears no more than "physiologically hard."

All these explanations are still unsatisfactory, since there are cases in which an artificial reduction of tension does not at all check the decline of visual acuity. We must, therefore, assume that occasionally there are cases diagnosticated and treated as "simple glaucoma," which depend upon accidental coincidence of physiological excavation and some form of optic-nerve atrophy.

The differentiation of these cases may be very difficult. It is relatively easy if the disc of the other eye is smooth, for a deep excavation in the diseased eye must be due to pressure—pathological—and cannot be physiological. If this distinction is lacking, continued observation of the patient, or careful study of his own case by himself, will be the only means of furnishing proof that increase in tension does occasionally occur, and that, therefore, the disease is to be considered glaucoma.

The preceding description makes it evident that inflammatory and simple glaucoma are only different forms of the same disease, but that for practical purposes it is necessary to consider each as a distinct pathological picture. The intimate connection between them can be seen in various clinical manifestations. For example, cases have been reported where simple glaucoma was found in one eye and inflammatory glaucoma in the other of the same individual; simple glaucoma has of a sudden changed into the inflammatory form, the obvious reason being that the hitherto moderate tension became suddenly alarmingly increased. The reverse has happened: oftener than the surgeon likes, probably, he discovers that an eye, after an operative cure of an inflammatory glaucoma, gradually becomes hard again, that the visual field becomes narrower, the visual acuity reduced—in other words, that a simple glaucoma has replaced the inflammatory glaucoma supposed to be cured. Moreover, it must be observed that there are various stages between the inflammatory and simple (non-inflammatory) glaucoma; such intermediate conditions being sometimes grouped apart as "chronic inflammatory glaucoma." (*p. 396*).

Digitized by the Internet Archive in 2010 with funding from Microsoft Corporation

(*c*) **Glaucoma Infantile** (*Glaucoma of Childhood*), **Hydrophthalmos or Buphthalmos Congenitus.**—Considering the delicacy and tenderness of fetal and children's tissue, it is easy to see that increased tension will stretch a fetus' or child's eyeball. Consequently, in infantile glaucoma a pathological picture is developed which bears but little external resemblance to the glaucoma of adults. The essential resemblance, however, is seen in the increased tension and in the gradually resulting excavation of the optic-nerve disc. The earliest changes will be noticed in the cornea; this becomes larger than normal, the diameter of the circumference at the margin between cornea and sclera being as great as *19 mm.* The cornea is more or less hazy, and there are blood-vessels at its edge. Such a condition may lead to comparison with keratitis parenchymatosa. The tension must therefore be carefully tested, a difficult matter in children, and often impossible without resort to narcosis. The anterior chamber is extraordinarily deep—*12.8 mm.* in one case! The iris is dull and lusterless, the pupil dilated, sluggish, or rigid. The lens is small, sometimes cloudy, and insecure, owing to stretching of the suspensory ligament.

B. SECONDARY GLAUCOMA.

Many diseases of the eye may cause increased tension. This increase in tension is called secondary glaucoma in case it is pronounced and lasting enough to influence the visual field and visual acuity. Since it is sometimes difficult or impossible to say in an individual case whether impaired vision is due to the original disease alone, or to the increase in tension, the expression "secondary glaucoma" enjoys a remarkable elasticity. Secondary glaucoma has, of course, the same effect as primary glaucoma.

(*a*) Among diseases of the *iris*, total synechia (*p. 277*) plays the most important part. The reason for increased tension is in this case very evident. The natural current from the posterior to the anterior chamber is blocked, and the fluid secreted by the ciliary body must therefore overfill all this space, as is evidenced by the bulging forward of the iris. Less certain to lead to increased tension are isolated adhesions of the ciliary edge of the iris to the cornea, or to a scar in the sclero-corneal margin. The causal connection is nevertheless quite evident. (See *Theories, p. 402.*)

(*b*) Among diseases of the *lens*, injuries and luxations are the principal conditions leading to increased tension. With reference

Digitized by Illinois College of Optometry

to injuries to the capsule the question has already been discussed in the section on traumatic cataract (*p. 339*). The swollen lens substance is the more certain to cause increased tension, the more capable of swelling the lens is, and the more rigid the sclera. Elderly persons are more in danger than the young, chiefly on account of the rigidity of the sclera. How a luxation of the lens can cause glaucoma is not so clear. The best explanation is that the movable lens irritates the ciliary body by dragging on the zonule of Zinn, exciting it to pathological secretion and to inflammation.

(*c*) *Retina.*—Atheroma of the retinal vessels not infrequently causes hemorrhage. From two to eight weeks later there is increased tension and "hemorrhagic glaucoma." This form is particularly dangerous, and in spite of prompt treatment usually ends in blindness.

(*d*) *Tumors* of the interior of the eye, particularly of the ciliary body, may cause increased tension by occupying all the space, and perhaps by hindering the discharge of lymph from the eye.

3. PATHOLOGICAL ANATOMY.

The number of glaucomatous eyes that have been examined microscopically is large, but most of them were already blind and were removed for the severe pain they caused. The changes found in them are, therefore, doubtless in great part, not causes but results of glaucoma, and of but little value in support of any "glaucoma theories."

Leber found droplets in the epithelium of glaucomatous corneæ, and Fuchs in both epithelium and cornea proper, particularly in the anterior layers. Fuchs consequently denominates glaucomatous corneal opacity as "inflammatory edema" (*p. 253*).

The neighborhood of the canal of Schlemm is, according to Knies, infiltrated with round cells even before the real disease begins, and the same is true of the root of the iris and of the ciliary body. As the disease progresses there may be a circular adhesion of the root of the iris to the posterior surface of the cornea, which would obliterate the recess in the anterior chamber between them and block up the chief channels of the circulation within the eye.

Iris and ciliary body show at first round-cell infiltration, and later atrophy; and this round-cell infiltration has been found in the cho-

Digitized by the Illinois College of Optometry

roid, particularly along the veins. Hyaline degeneration of the vessel walls has been described, as well as atheroma of these vessels and of those in the retina (hemorrhagic glaucoma).

In the optic nerve are found the most important and most regularly occurring changes. According to Schnabel they are due to an interstitial neuritis in the part of the nerve still provided with its medulla, that is, behind the eyeball; or to inflammation or mere atrophy of the nervous and connective-tissue elements in the optic-nerve sheath.

4. THEORIES.

In speaking of secondary glaucoma it was pointed out that some cases need no theory, that is, no explanation built up from assumptions. As a matter of fact, increased tension resulting from swollen lens substance, or from a tumor increasing faster than the vitreous can decrease, or from total synechia, explains itself. In the first two cases it is the increase in the contents of the eyeball, in the last the retarded circulation between posterior and anterior chambers, which causes the increase in tension.

But what—in other cases of glaucoma, especially the primary forms—causes the increase in tension? Is it the blood pressure? Then without doubt the tension of the eyeball will be a criterion of the blood pressure. The attempt has been made on animals to raise the eye's tension by pressure on or ligation of the jugular veins, but this by no means produced glaucoma. Moreover, it is known from observations on men with high blood pressure—fever patients, for example—or on men with low blood pressure—those near death—that the internal tension of the eye is very far from following the variations of the blood pressure. Again, the assumption that disease of the iritic or choroidal vessels can block the circulation and cause stasis needs a much more substantial support of pathological facts than we have as yet.

The study of the circulation in the eye (*v. 269*) has been productive of more fruitful results. In order to retain the internal tension of the eye at a normal equilibrium, there must also be equilibrium between the secretion of the ocular fluid on the one hand, and its escape on the other. Hindrance to the escape of fluid, or increase in its secretion, or both together, must cause increased tension. Many ophthalmologists lay particular stress upon the hindrance to the escape of fluid, assuming, with Knies, that the essential and final cause of glaucoma is an inflammatory infiltration at the root of the iris and at the sclero-corneal margin. The resultant cicatricial contracture would block up the angle between iris and cornea, where the principal drainage canal for the aqueous lies. Increased tension with all its consequences would naturally result from it.

Other ophthalmologists contend that the shallowness of the anterior chamber stands in direct contradiction to this theory. It is evident that hindrance in the path of a stream must cause backward stasis and a consequent broadening of the path itself. It is, therefore, more logical to consider the blocking up of the angle to be rather the result of increased tension, the cause being sought in increase in the eye's contents lying behind the iris and lens. In favor of this "secretion theory" it may be adduced that many circumstances indicate that primary glaucoma is connected with disturbances in the nervous system. For example, in many cases trigeminal neuralgia precedes an attack of glau-

Digitized by Google

coma; or glaucoma may appear at intervals with the peculiar characteristics of neuralgia; or glaucoma may often be produced by mental states of shock and anxiety.[1]

Again, many of the phenomena of secretion are directly under the influence of the nervous system—the secretion of tears, for example. By artificial stimulation of the ciliary ganglion in dogs the internal tension of the eye can be noticeably and permanently raised, and we may therefore assume that when this ganglion is stimulated, the secretion of fluid is increased, and that glaucoma depends upon an analogous process.

This by no means exhausts the number of glaucoma theories, but there is nothing to be gained by pursuing the subject farther, for theories that appear to one man to solve the problem seem to another as mere fantasies of the brain. It may be mentioned, perhaps, that Schoen, after years of study and investigation, ascribes glaucoma to overexercise of the accommodation, and would lay more weight upon prophylaxis of glaucoma by properly selected glasses than upon mere operative treatment.

I once performed an iridectomy for the ripening of cataract. Both eyes were soft, the anterior chamber noticeably deep, and there was no suspicion of glaucoma. Immediately after the iridectomy the anterior chamber filled with blood. The next day the blood was to a large extent absorbed, and I then gave atropin. When the bandage was again changed it was spotted with blood, there was blood in the conjunctiva and in the anterior chamber. I feared an injury, but on the next day the blood was again diminished. Unsuspectingly, I again gave atropin. On the next day the eye was as hard as a stone, the cornea cloudy, the chamber full of blood—hemorrhagic glaucoma. With eserin, cocain, and warm compresses the cyclone passed by, with no worse results than a line of delicate posterior synechiæ.

This case shows that in spite of deep anterior chamber, in spite of softness of tension, in spite even of a preceding iridectomy, an eye may be the victim of glaucoma; the case supports the suspicion, too, that the disposition to glaucoma consists of a pathological character of the blood-vessels, and that an attack of glaucoma is excited by the nervous system; for the effect of atropin upon the smooth muscular fibers in the eye, and therefore upon the condition of the vascular walls, is probably brought about by paralysis of the peripheral nerve-endings.

5. PROGNOSIS AND TREATMENT.

Every case of glaucoma, if untreated, will surely end in complete and incurable blindness. It is, therefore, much to be regretted that many and many a time the error is made by physicians of diagnosticating any decline in visual acuity in elderly persons as due to cataract, and that physicians send such patients to the ophthalmologist only when the neglected "simple glaucoma" has already approached the stage of incurable blindness. Quite as serious is it to confuse acute glaucoma with iritis, a mistake that would seem impossible if the dilated pupil of glaucoma is considered, and yet it

[1] This explains the fact that often enough during operative treatment for glaucoma on one eye, the other sound eye is attacked by the disease. It is advisable, therefore, during an operation for glaucoma to instil eserin or pilocarpin into the apparently healthy eye.

Digitized by the College of Optometry

is made again and again. Overlooking the effect of such serious errors, the prognosis is decidedly favorable for acute glaucoma if treated properly, doubtful for simple and infantile glaucoma, and unfavorable for hemorrhagic glaucoma.

The aim of **treatment** *is the reduction of tension.* To reach this goal we have three methods at our command:—

(1) *Medication*, by eserin or pilocarpin.

(2) *Massage.*

(3) *Operation*, by corneal puncture, iridectomy, sclerotomy, and (the newest) incision of the ligamentum pectinatum.

The effect of *myotics* such as eserin and pilocarpin, as well as that of their antagonists, the mydriatics—atropin, homatropin, and cocain—has already been discussed (*p. 270*). We need mention here only their effect on the eye's internal tension. In the healthy eye they produce no appreciable change in tension. Cocain is an exception, for it has been frequently observed that healthy eyes of elderly persons are made noticeably soft by cocain. The effect may be quite different if there is a pathological increase of tension already present. Myotics reduce tension, but mydriatics, even cocain at times, increase it. To use atropin if there is the least suspicion of glaucoma is, therefore, unconditionally forbidden, and even homatropin or cocain are to be used only with the greatest caution.

The connection between dilatation of the pupil and increased tension is not quite clear. Many suppose that the iris when dilated rolls up into the filtration angle and retards the outflow of aqueous, and that contrariwise an expanded iris leaves free the filtration angle, and therefore offers no obstruction to the principal outlet for the eye's fluids. The fact admits of other explanations, however.

Glaucoma cannot be healed, but single attacks may, in favorable cases, be cut short by means of *pilocarpin* or the stronger *eserin.* These remedies are therefore of inestimable value, especially if the problem is to obviate the danger of increased tension until the patient can consult an ophthalmologist. Myotics are also of value in simplifying the performance of a sclerotomy or an iridectomy. And, finally, they are used extensively in the after-treatment.

The second method, *massage*, is used principally in the after-treatment, and in cases of simple glaucoma for which one or more futile operations have been performed, and in which, therefore, the surgeon's task is to retard as long as possible the unavoidable decline in visual acuity. The result of massage is instantaneous, the hard

Digitized by the College of Optometry

eyeball grows soft under the physician's finger, so to say, but its effect is not lasting. The patient should, therefore, learn to massage himself, and practice it daily. In massage it is quite practical to use a salve containing eserin and cocain: *Eserin sulf.*, *0.025*; *Cocain muriat*, *0.25*; *Vaselin*, *5.0*.

Corneal puncture is a method of the moment. As the aqueous escapes the contents of the eyeball is of course reduced, the tension decreases, the consequences of the previously increased tension disappear—for a short time only. The essentially curative method in glaucoma is *iridectomy* (*p. 280*). A. v. Graefe devised it, and it is one of the services he performed for science which renders his name immortal. Preparations to prevent infection are the same as in the operation for cataract (*p. 351*). If the anterior chamber is shallow (as it usually is) and the iris small, the careful performance of a broad iridectomy extending to the ciliary border is made unusually difficult and of danger to the lens. It may be somewhat facilitated by instilling eserin in advance, and by making the incision with v. Graefe's cataract knife (*Fig. 126, p. 348*) instead of with the keratome; of course, with the knife the iridectomy can be made only above or below. Iridectomy upward is almost always the rule, since the space left by removal of part of the iris is covered by the upper lid. The incision should lie in the opaque tissue of the sclera.

The effect of an iridectomy in cases of acute glaucoma is extraordinarily favorable. Tension becomes normal and all visual disturbances due to increased tension disappear. Visual acuity may, in the course of time, become normal, even when it has been reduced to counting fingers or to a mere perception of light from darkness. How this effect is produced is at present as much a matter of discussion as is the nature of glaucoma itself.

In my experience I have very often seen posterior synechiæ (plastic iritis) after an iridectomy, in spite of the most scrupulous antisepsis. I suppose that it is to be ascribed not to infection but to increase in the inflammatory condition which the glaucoma had produced in the iris. The iritis can be antagonized with cocain or, in some cases, with homatropin and with warm compresses of boric acid solution—compresses being used, of course, only after the wound has healed and the anterior chamber filled.

Iridectomy makes a hole in the iris which, if it lies below the palpebral fissure, causes dazzling and distortion. There is, as a rule, a change in the shape of the cornea, evidenced by an astigmatism that somewhat influences visual acuity. Not infrequently

Digitized by Illinois College of Optometry

there are hemorrhages in the retina as the result of the sudden reduction of the internal pressure. In case they are in the center of the retina they cause noticeable visual disturbances; if very numerous, they may be quite destructive, but, as a rule, they are without serious effect. They should be avoided by allowing the aqueous to escape very slowly during or after the completion of the incision. The scar in the sclera made for glaucoma is somewhat peculiar; it is broader and strewn with dark spots, while an iridectomy in a healthy eye leaves a very narrow, or, perhaps, an invisible scar. These dark spots are from the glistening pigment of the iris or ciliary body. The scar tissue often shows little vesicular elevations; such a scar is called cystoid. In case a cystoid scar does not of itself contract, it may be obliterated by the cautery.

In many cases glaucoma is cured by an iridectomy and remains so. In others tension increases again after a longer or shorter interval, and the result is the picture called simple or chronic inflammatory glaucoma. It is evident that in simple glaucoma iridectomy can be of but little service, since the visual disturbance depends essentially upon the changes in the optic nerve, which, even in the best cases, can be brought to a standstill but not overcome. In

FIG. 147.—SCLEROTOMY.

about one-third of the cases even this result is not obtained. Effort has been made, therefore, to find some other method of treatment, and *sclerotomy* was resorted to. According to v. Wecker, iridectomy is to be replaced by sclerotomy—

(1) In certain cases of simple glaucoma.
(2) In infantile glaucoma.
(3) In hemorrhagic glaucoma.

A prime condition is that the pupil can be well contracted by eserin. The operation is performed in the following way: A v. Graefe's cataract knife is introduced *1 mm.* from the corneal edge (at *a*, *Fig. 147*) into the anterior chamber and is brought out at a corresponding point (at *b*) on the other side. The tissue is now cut with saw-like motions, as if a flap were to be formed, but finally a bridge of tissue is left just about as long as each of the two incisions. As the knife is withdrawn, its point should be brought into the filtration angle and the "arch of the spaces of Fontana" cut

Digitized by the College of Optometry

through. This last step in sclerotomy—the incision of the ligamentum pectinatum—has been performed by Taylor as an operation of itself for glaucoma, with good results.

Sclerotomy is said to make a "filtration scar," that is, to provide porous tissue for the aqueous. According to this, a cystoid scar ought to be the type of a filtration scar, but even after a cystoid cicatrization, tension may rise again. The good effect of sclerotomy is therefore not yet quite clear. In the patients I have treated with sclerotomy I have only twice seen a really satisfactory reduction of tension.

If the iris tissue is atrophic, iridectomy usually produces no perceptible reduction of tension. The operation may also be incomplete. It may happen that neither iridectomy nor anterior sclerotomy is applicable, because the iris is atrophic, the anterior chamber very shallow, and the pupil unaffected by eserin. In such a case we may try posterior sclerotomy, that is, a meridional section through sclera into vitreous, which allows some fluid, yellowish vitreous, to escape. I have several times resorted to this method with comparatively good success. For example, I have now a patient with visual acuity and visual field about as they were two years ago when she came to me for treatment on account of relapsing glaucoma; during this time I have performed posterior sclerotomy twice on each eye, instilled pilocarpin, and ordered daily massage. The patient stopped the treatment several times on her own responsibility, but the rainbow vision returned, and she was only too glad to begin vigorous massage and pilocarpin treatment once more.

ENTOZOA—PARASITES IN THE EYE.

I. CYSTICERCUS.

The larva of the tape-worm (tænia solium) is called cysticercus cellulosæ. It may be found in all parts of the human body. These larvæ cause disturbances chiefly when located in the brain and in the eye, the latter location only being of interest to us. How does the larva reach the eye? It is found in men in whom a tape-worm has already found lodgment, or in those who are bedfellows of tape-worm patients, or in others in whom no tape-worm infection can be demonstrated. A tape-worm host can infect himself, either because the segments reach the stomach from the intestine during vomiting, or because the eggs are carried by dirty fingers and swallowed with the food. This may be the same process by which a person becomes infected from a companion. In any case the egg of the tape-worm must reach the stomach. The gastric juice dissolves the shell of the egg, the embryo is released, pierces the

Digitized by Illinois College of Optometry

stomach wall, reaches the blood current, and lodges finally in the eye.

The cysticercus consists of head, neck, and body (vesicle) (*Fig. 148*). The head bears four suckers and a row of hooklets. Head and neck may be withdrawn into the body so that the whole figure looks like a bladder (*Fig. 149*) of *4 mm.* diameter, in which a white, opaque spot may be recognized as the head with its suckers. The parasite floats in a second bladder filled with fluid; it is supposed that this external vesicle—the house of the larva—is supplied by the tissue of the host.

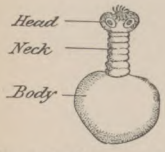

FIG 148.—CYSTICERCUS, WITH EXTENDED HEAD AND NECK. (*After Stein.*)

The larva has been found beneath the skin of the lids, below the conjunctiva, within the orbit, in the anterior chamber, in the vitreous, and behind the retina. The commonest occurrence is that the larva rests at first behind the retina, and during its growth, either with or without the external vesicle, breaks into the vitreous. Such a case is most important, not only on account of its comparative frequency, but also with reference to its treatment, and is, therefore, used as the basis for the following description:—

The first sign of the larva within the eye is a visual disturbance in the form of a dark spot, whose location in the visual field is dependent upon the location of the larva in the eye. Later on, there is distortion and finally cloudiness of the entire visual field, and consequently a reduction of vision, even if the larva lies eccentrically in the fundus. In cases observed by v. Graefe from the beginning with the ophthalmoscope, there was at first a bluish-gray haziness at a certain spot on the fundus. This opacity grew larger during the succeeding weeks and protruded distinctly. Then the larva burst out of the apex of the protrusion, into the vitreous; or in other cases it first made a path downward between retina and choroid before it finally broke out. The original location of the larva remained a grayish-blue spot with white, somewhat prominent edges. If the larva is seen while the vitreous is still unclouded, the

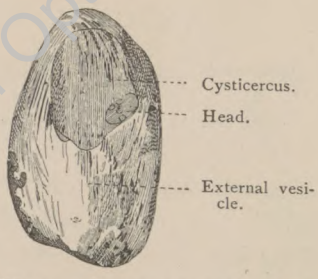

FIG. 149.—CYSTICERCUS, WITH NECK AND HEAD WITHDRAWN, LYING IN THE EXTERNAL VESICLE. (*After Stein.*)

Digitized by the College of Optometry

recognition of the disease is easy. The examination in the inverted image should be made with a strong convex lens (*25.0 D*) in order, if possible, to see the whole larva at one time. We would find a blue-gray vesicle about four times the diameter of the papilla, the edges of the vesicle being a sharply defined, yellowish-red, glistening circumference; the play of color on the circumference is seen most distinctly in the upright image by rotating the mirror. Not unfrequently we may succeed in detecting through the external vesicle movements of the larva itself; this is particularly easy if the larva is naked, that is, if it lies in the vitreous (*Fig. 150*) or in the anterior chamber without any second vesicle. We see peri-

FIG. 150.—OPHTHALMOSCOPIC IMAGE OF A LIVING CYSTICERCUS IN THE VITREOUS. (*After Liebreich.*)

staltic-like movements passing up and down the vesicle, and if they are very active they give a swing-like motion to the whole body. The picture is most fascinating if the animal extends its neck and head with its suckers and moves itself about in an apparently tireless way.

This condition may last for weeks or months, but gradually the parasite or its morphological products will act as a source of irritation; the vitreous becomes opaque, obscuring the image, but of itself possessing such characteristics that the condition will establish the diagnosis for one who has had experience. These vitreous opacities are like curtains looped together, extending through the entire vitreous, somewhat transparent and slightly movable, the

Digitized by Illinois College of Optometry

appearance being quite different from that presented by the torn and untransparent lumps, threads, and shreds of the usual vitreous opacities. On account of their relative transparency they permit for a long period the recognition, at a certain spot on the fundus, of a bright, bluish-gray reflex—the larva.

These opacities become denser, the retina finally prolapses, until the diagnosis becomes impossible, or can be only conjectured. Finally, we find numerous signs of a chronic iridochoroiditis. It need scarcely be mentioned that at this stage all vision has been long since obliterated. With varying cessations or relapses of the pain and other symptoms of inflammation the eye becomes soft and contracted. The sensibility of this "phthisical" eye may be gradually lost, and the eye become permanently quiet. Sympathetic inflammation is not to be feared.

Prognosis is always unfavorable. Without interference every parasite causes blindness in the eye attacked within *three* to *fifteen* months.

Treatment should be prophylactic if possible,—such methods as are used for the prevention of the tænia in general. Since the introduction of a municipal meat inspection, cases of the disease in Berlin have become noticeably less. Personal cleanliness, the avoidance of raw meat, ham, and sausage, and the cure of tape-worm in one's self or in one's bedfellow, must be insisted on. If a larva reaches the eye, it must be removed by operation, which consists of a meridional scleral incision for the introduction of a toothed forceps. If the incision has been properly located, the delivery of the parasite is usually an easy matter, provided that it is not floating freely in the vitreous, but is attached to the eye-wall, and that the opacity of the vitreous has not already developed beyond the point where a proper localization of the larva is still possible. If the operation is done early enough, that is, particularly before prolapse of the retina has resulted, a good vision—even $V = 1$—may be retained.

Here in Zürich a cysticercus is the greatest rarity. I have seen only one case, probably the first in Zürich, and I operated on it. The patient was Swiss, but had worked for a long time in Hamburg as a butcher. The eye was already blind. The operation could not, therefore, restore vision, but only prevent inflammation and atrophy.

The rarity of the parasite in the eye in many districts is remarkable, considering that in these very districts tape-worm itself is by no means uncommon. For example, in many localities of Switzerland tape-worm is very prevalent, while cysticercus is very rare. The explanation may lie in the fact that not all tape-worms are capable of spreading larvæ

Digitized by Illinois College of Optometry

through the human body. To illustrate, all larvæ seen in the eye are from the tænia solium, while the tape-worm so common on Lake Geneva is the bothriocephalus.

II. FILARIA—(Thread-Worms).

It has happened repeatedly that remnants of the embryonic arteria hyaloidea have been taken for thread-worms. Thread-worms have, however, been found in opaque lenses removed on that account. Kuhnt has recently described a case in which a thread-worm was seen in the vitreous, by the ophthalmoscope, removed by operation, and demonstrated as an anatomical specimen. The matter would be of little practical interest on account of its great rarity, were it not that, as Kuhnt emphasizes, the possibility ought to be thought of that many cases of retinitis with vitreous opacities and retinal prolapses of unknown origin may be due to undiscovered parasites. Independent movements of the questionable object ought to be of great importance in making a diagnosis.

INJURIES TO THE EYEBALL.

Injuries to individual parts of the eye have been already discussed in previous sections. There remains for discussion the effect of an injury upon the eye as a whole, in other words, how injuries of several parts are associated in one pathological picture. In view of the extraordinary complexity of such pictures a description of all of them is scarcely possible, and only a few examples can be made use of. It is therefore unavoidable that something of what has previously been said should be repeated.

Those persons are most often injured who have certain dangerous occupations, stone-masons or bricklayers, for example. Such injuries connected with occupations might be to a great extent avoided if the workmen could be induced to wear protecting spectacles.

Unfortunately, this is seldom done. Man's carelessness to the danger of his calling is traditional. A mason, from whose cornea I had repeate dly removed foreign bodies decided finally, at my request, to use protecting spectacles. A short time afterward a large splinter struck one glass and smashed it, but the eye was uninjured, a splendid proof of its efficiency. The mason, however, was in no hurry to get his spectacles repaired, and soon came to me again with another foreign body in his cornea.

Digitized by University of Illinois College of Optometry

1. INJURIES BY PUNCTURE AND INCISION.

Puncture wounds may be made by forks, needles, scissors, thorns, pens, and such sharp implements; incisions, by knives, swords, glass, and the sharp edge of any such hard objects. The danger to the eye arising from such a wound depends not only upon the anatomical injury, but also upon whether the wound has or has not been infected by pathological germs. The dangers of infection are greater in punctured wounds because disinfection by the physician is, as a rule, impossible on account of depth and narrowness of the traumatic canal. Piercing wounds of the sclero-corneal margin are particularly to be feared, because the ciliary body also is injured, or prolapses into the wound and becomes incarcerated in the scar. Such adhesions of the ciliary body lead most usually to chronic cyclitis or even to sympathetic inflammation of the other eye.

The reason of the danger of injury to the ciliary body is not yet satisfactorily explained. We may suppose that the entrance of germs is in this case particularly easy, or, perhaps, takes place subsequently through the very thin scar; or that the contraction of the scar tissue produces a laceration in the sensitive ciliary body which, in its turn, may be the cause of inflammation. A retraction of the scar is always a sign of such an atrophy and is to be considered the eye's death-warrant.

Wounds of the sclera are almost always accompanied by prolapse of choroid and retina and by more or less loss of vitreous. The unprolapsed portion of the retina may be loosened—in which case perception of light is lacking and the restoration of visual energy must be given up.

An important question in every injury to the eyeball is as to whether or not the lens is injured. Every injury to the lens capsule ends in traumatic cataract (*p. 339*). Injuries to the lens, therefore, impair the prognosis materially, all other conditions being equal.

Treatment consists in radical disinfection of lids and tear sac (if this is diseased), in douching the conjunctival sac with *1 : 5000* sublimate solution, closure of the wound with conjunctival suture, dusting with finely powdered iodoform, antiseptic bandage, and rest. If the iris has prolapsed, the attempt should be made to replace it by a spatula and to retain it in place by eserin; if this does not succeed, or if, by reason of size and position of the wound, it is irreplaceable, the prolapsed portion must be seized with forceps, drawn out, and cut off. If the lens capsule is injured, atropin and ice

Digitized by the Arthur Conan Doyle Memorial Library

compresses are to be used. In case the retina is completely prolapsed on account of loss of vitreous, and if light sense is destroyed, enucleation of the eye should be performed at once.

2. INJURIES BY BLUNT INSTRUMENTS.

Severe pressure on the eye may have manifold results. Most of these results I had a chance to study in a case recently treated by me, and I therefore substitute a description of this case in place of a systematic relation of these results. A workman was injured by a severe blow from a heavy chain. On the next day the appearance was as follows: there was a gaping, horizontal skin wound above the tear sac; the eye was red, weeping, painful, photophobic; there was a small conjunctival wound on the nasal side of the cornea, the vicinity being ecchymosed; the cornea, particularly below, was both diffused and linearly opaque; the anterior chamber deep; the pupil dilated and motionless—*iridoplegia* (*p. 280*); at the edge of the pupil upward and inward there was a small laceration; with focal illumination the lens reflexes were not visible, but the gray lines of light (*p. 100*), although very weak, were yet evident enough to prove the presence of the lens; the fundus was invisible, no red reflex being obtainable in the pupil. $V =$ Fingers at *0.5 m.*

After several days the cornea cleared, the irritation subsided, and a second examination showed new discoveries. The nasal half of the iris trembled when the eye was moved—*iridodonesis*; it was also translucent. The posterior layer of the iris (the pigment layer) had obviously been loosened from the anterior; a remnant of this posterior layer hung in the pupil like a loose strand upward and inward, but behind the plane of the iris. The lens reflexes were now visible, the lens being plainly displaced toward the temporal side. The lens trembled when the eye was moved.

Some weeks later the eye was nearly, though not quite, free from irritation, the lens was totally opaque, still more displaced and movable, and at the same time so revolved on its perpendicular axis that its anterior surface faced toward the nose. The eye was blind beyond mere light perception.

There quite gradually developed other disturbances, such as attacks of pain and increased tension; at the same time peripheral light projection became uncertain. Rest in bed, bandage to both

Digitized by the Internet Archive of Ophthalmology

eyes, and eserin seemed to remain without effect, and consequently the extraction of the lens was decided on. There was, of course, prolapse of vitreous. Healing progressed slowly; even in the third week after the operation there was still vitreous in the somewhat contracted wound. In spite of this, douches of warm sublimate solution and abundant use of iodoform powder prevented all suppuration. In the fifth week the wound was completely healed, but the eye was still somewhat reddened and sensitive. $V =$ Finger at *0.3 m.* Two months after the operation the eye was quiet, but the pupil was shut off by a membrane, the eye blind beyond sensitiveness to light.

If the effect of a dull instrument is still more powerful than in the above case, the globe may burst; this is generally associated with hemorrhage into the anterior chamber and vitreous. The rent in the sclera always lies parallel to the corneal margin and only a few millimeters from it, opposite the spot where the blow was received by the eye. It occurs most commonly upward, upward and inward, or inward, because the eye is least protected downward and outward, and is therefore most apt to be struck in this spot.

The process of rupture may be conceived as follows: The instrument causing the blow increases the tension to such a degree that the fibers of the sclera yield at the weakest spot; the rent takes place, therefore, from within outward. The fact that the vicinity of the cornea shows itself to be the weakest depends probably on the direction of the scleral fibers, since the thinnest of the sclera lies, as is well known, somewhat further back, near the equator.

The elastic conjunctiva does not necessarily tear as the sclera bursts. Through the opening in the sclera more or less of the contents of the eye prolapses—iris, ciliary body, retina, vitreous, and sometimes the lens itself. If the injury occurred to an eye already blinded by a cataract, it may really be of advantage in encouraging the expulsion of the lens. As a matter of fact, cases have been observed in which an accidental blow removed a cataractous lens and thereby restored vision. It may be further mentioned that occasionally the whole iris is torn off at the ciliary margin and escapes from the eye through the scleral wound. Rupture of the eye is caused by blows from the horns of cattle, by falling upon hard, jagged objects, by blows from the fist, canes, or feet, and by similar accidents.

The diagnosis of a scleral rent is easy. Either the iris has prolapsed into the wound, in which case, besides the wound itself and

Digitized by Illinois College of Optometry

the iris lying in it, we see an aperture in the iris corresponding to the location of the rent; or the iris has not prolapsed, but the pupil is at least dragged in the direction of the rent. In all cases the eyeball has lost its normal tension; it is soft.

Prognosis is serious; many injured eyes become phthisical.

Treatment consists in disinfection, bandage, and rest in bed. A prolapsed iris must be carefully cut off. If the case is not seen early, the iris may be allowed to heal in the wound, the prolapsed portion being destroyed later by the cautery.

3. FOREIGN BODIES WITHIN THE EYE.

In every penetrating injury to the eye the question must be asked whether the injuring body—all or any part of it—remains within the eye. In many cases this may be unnecessary, owing to the nature of the accident or to the size and construction of the object. In other cases the answer is easy, since the foreign body may be seen with the naked eye or by means of focal illumination or the ophthalmoscope, either in the anterior chamber, in the lens, in the vitreous, or on the posterior wall; at times there are air bubbles on the foreign body, recognizable as dark, circular areas with a bright point of light in the center. In other cases the answer is very difficult, either because the foreign body lies in a recess of the chamber, where it is concealed by the sclero-corneal covering, or because of the rapid opacification of the lens, or of hemorrhage into the vitreous, or of inflammatory exudate, or because the foreign body is located so near the ciliary body that it cannot be seen by the surgeon.

In such difficult cases we must question the patient as to the manner of the injury, examine him carefully, and take all the circumstances into consideration. There must always be suspicion of foreign body in the eye if, after an accident, there are pain, photophobia, sensitiveness to pressure, and visual disturbance at one time, unexplainable by any visible, external injury. The suspicion increases to certainty if we can find changes in the eye which unmistakably indicate a canal of passage for a foreign body. We must then examine for a canal of entrance, that is, for a wound or scar in the cornea or sclera. The size of this canal (it is often very minute) will serve as a hint as to the size of the foreign body, at

Digitized by Illinois College of Optometry

least in two dimensions. It may be incidentally remarked that the smaller the canal of entrance, the greater is the probability that the foreign body still remains within the eye. We must next look for an aperture in the iris, or in the anterior and posterior lens capsule. If this last can be demonstrated, the foreign body must obviously rest in the vitreous or fundus, since the active force of minute particles is never sufficient to penetrate the eye's envelopes a second time. Any particle, then, remains adherent or rebounds and sinks in the vitreous to the bottom; in such cases the point of contact in the fundus appears as a bloody or as a white spot.

If the patient is not examined till traumatic cataract has already appeared, and the vitreous and fundus are invisible, the physician must content himself with examination of the field of vision, which may be of diagnostic value in spite of the opacity of the lens. Near the foreign body the retina will be incapable of functionating on account of the atrophy of the layer of rods and cones with the external granules,[1] and consequently the patient will not perceive the light from a candle when it is brought into an area of the visual field corresponding to the neighborhood of the injured area in the retina.

The further fate of the eye—apart from the mechanical effect of the foreign body—is influenced by three factors:—

(1) The location of the foreign body;

(2) Its chemical nature; and

(3) Whether or not disease germs were adherent to the foreign body during the injury.

If bacteria were introduced, the result would be an acute abscess of the vitreous passing into panophthalmitis or a subacute inflammation, according to the number and pathological character of these germs,—both ending in destruction and atrophy of the eye. Only when the foreign body remains in the anterior chamber, iris, or lens, is our art able, perhaps, to avoid the worst; if germs have reached the vitreous, even an immediate extraction of the foreign body will not help to save the eye.

If the foreign body was aseptic, it may be tolerated in the lens in spite of its chemical effect—the result being traumatic cataract, but no necessary inflammation. Cases have been reported in which the removal of the lens revealed a small foreign body, the presence of

[1] At least, such was the condition in a case under my observation.

Digitized by Illinois College of Optometry

which was quite unsuspected by the patient. If the foreign body was of iron, the lens becomes a diffused yellow on account of the oxid of hydrogen; or there are rust-colored points near the foreign body. Splinters of lustrous metal are easy to recognize, even through an opaque body, on account of their bright reflex.

In the vitreous and in the fundus uncontaminated bits of iron or copper may retain lodgment, even if the eye at first was more or less irritated. Moreover, even in these favorable circumstances changes in the fundus may take place in a quiet way, especially at the macula lutea, and vision may be damaged. It must be finally mentioned that even if the eye remains absolutely quiet, a foreign body is a veritable sword of Damocles, threatening its own and the other eye, too.

The ciliary body is the most sensitive. Foreign bodies chemically unirritating and free from germs may here produce an alarming inflammation.

From what has been said it is evident that for "a foreign body within the eye" the prognosis is extremely unfavorable. Left to themselves the majority of cases will end in destruction of one eye and sympathetic inflammation of the other. The prognosis is bad even with proper treatment. An analysis by Weidmann of the cases under Horner and Haab showed the following proportion of losses:—

If the foreign body is in the anterior chamber, ... *0 per cent.*
If the foreign body is in the lens, ... *30 per cent.*
If the foreign body is in the vitreous, ... *71 per cent.*

The prognosis is particularly bad in the case of bits of iron which are chipped off old and fragile instruments used when working in a stony soil and which have lodged in a workman's eye. The loss in such cases is about *85 per cent.*

Treatment. Since a foreign body has often enough been seen to find lodgment without causing harm, it is not necessary that every foreign body known to be within the eye must be without ceremony attacked by an operation. It is better to weigh the chances for healing with the danger of the operation. When the foreign body is in the anterior chamber the danger of the operation is slight;[1] consequently it should always be removed, even if long, unirritating residence seems to confer upon it the rights of citizen-

[1] The danger may be slight, but not the operation itself! This operation, with that for the removal of bits of iron, are among the most difficult of ophthalmic surgery.

Digitized by the Internet Archive in 2010 with funding from University of California Libraries

ship. A lens with a foreign body in it must be sooner or later removed on account of the opacity, the foreign body being then extracted with it. The treatment of foreign body in the vitreous depends upon the material composing it. If—as is the case in the majority of such injuries (74 per cent., Weidmann)—the foreign body is of iron, the hope of a cure must be abandoned and immediate resort must be made to an operation which, at the present day, has become a comparatively easy and mild one, thanks to the use of the electro-magnet. If the foreign body was a splinter of copper, wood, stone, glass, or china, an inactive treatment may be followed. If the eye does not calm down the sclera should be incised, and through it an attempt made to seize and to draw out the foreign body with forceps. If this is unsuccessful the eye must be removed to avoid danger to its fellow.

The credit of introducing the magnet into ophthalmic practice belongs to Hirschberg. His method has already saved innumerable eyes that would have been lost without the "magnet operation." The conditions for a successful result are:—

(1) An accurate localization of the foreign body;

(2) Careful antisepsis; and

(3) An absolutely quiet patient, obtained usually by chloroform narcosis.

The approach to the foreign body is obtained either by the magnetic sound, that is, by pushing through the canal of entrance a sound armed with an electro-magnet as the most usual method—by making a meridional scleral incision at the equator and near the foreign body, through this introducing into the vitreous a properly shaped probe with electro-magnet attachment which must be brought into contact with the foreign body. If this can be done, or even if the magnet attachment can be brought near enough to the iron, the latter is attracted to the magnet with appreciable force and sound.

Haab has quite recently devised a new magnet operation. It depends upon the fact discovered by Knies that by simply bringing the eye into the vicinity of a *very strong* electro-magnet a bit of iron can be drawn from the vitreous into the anterior chamber, where it may be released in a suitable position and then delivered by a comparatively harmless operation. With Haab's electro-magnet a bit of iron may even be quite withdrawn from the eye in the tract of the entrance canal, this succeeding, too, as I have myself observed, even when the entrance canal had been closed for several days. Of course the very strongest magnet cannot draw a bit of iron through the intact membranes of the eye. It should be remembered, too, that the iron must not have become lodged in the sclera, nor be retained any place by inflammatory products.

4. SYMPATHETIC INFLAMMATION OF THE EYE.

In many cases of injury to an eye the history of the trouble does not by any means end with the injury to or even loss of the eye first involved. It may rather begin the last and most distressing

Digitized by Illinois College of Optometry

chapter, the passage of the inflammation to the other eye, **sympathetic ophthalmia.** This consists of a plastic cyclitis or iridocyclochoroiditis (*p. 286*). It may be the result of a cyclitis in the other eye from some other than a traumatic origin, but such cases are rare. Usually it is an injury to the ciliary body, or a scleral wound into which ciliary body and iris have prolapsed and become incarcerated—but especially a foreign body within the eye, which causes a chronic cyclitis in the first eye and a subsequent sympathetic inflammation in the other.

Other diseases also may arise sympathetically, particularly iritis serosa, which is in no way so serious as the sympathetic iridocyclitis plastica. There have also been reported cases of choroido-retinitis, and even diseases of a non-inflammatory nature, such as spasm of the orbicularis and optic-nerve atrophy, ascribed to "sympathy;" whether justly so or not is still an open question.

The interval of time between the injury and the outbreak of the sympathetic affection is quite indefinite; it usually amounts to *four* to *eight* weeks, but cases have been reported *sixteen* days after, and *twenty-six* or even *forty* (?) years after!

The disease is announced by premonitory symptoms—moderate photophobia, reduced strength for near work, cloudy vision. Corresponding to these symptoms there are a mild pericorneal injection, moderate opacity of the aqueous, and, perhaps, some kind of posterior synechia; redness of the disc has been occasionally observed. Gradually these signs of sympathetic irritation pass into those of sympathetic inflammation, the pain and cloudiness increasing, visual acuity decreasing. The internal tension is changed, being at the commencement of the disease noticeably increased, but declining below normal as atrophy begins.

It is the rule that after varying improvement and relapse the pupil is displaced by adhesions, the iris adheres to the surface of the lens capsule (*p. 287*), the vitreous atrophies, the retina prolapses, and incurable blindness results. A cure with indistinct vision may be obtained.

The nature of the inflammation is not yet explained. Mackenzie, who first described sympathetic inflammation, supposed that it passed from the retina of the injured eye through the chiasma to the retina of the other eye, and that it became now an "iritis sympathetica." This old and rejected view has been recently brought again into prominence by Leber and his pupils. Deutschmann thinks he has proved that germs have traveled from the injured eye backward along the optic nerve, have reversed their course at the chiasma, have ascended in the lymph channels along the optic nerve of the other side, and thus caused the direful inflammation in the second eye. This doctrine, so clear

Digitized by Illinois College of Optometry

to the mere reader, has found many doubters. In numerous cases of sympathetically diseased eyes, examined with the greatest care, no germs could be found. Moreover, it has been shown that all sympathetic inflammations caused by him with bacteria were but a local manifestation of a general infection of the entire animal. In short, Deutschmann's theory has not as yet been able to depose the hitherto ruling one that the second eye was in some unknown way involved through the ciliary nerves. To be sure, we have no convincing proof of this theory, but a series of clinical facts that are in accord with it are unexplainable on the Mackenzie-Deutschmann theory. For example, the fact that sympathetic irritation may develop within a few minutes, and that a foreign body on the cornea of one eye may arouse photophobia and injection of the uninjured eye, and that if the tear passage of one eye is sounded and some difficulty is met in reaching the meatus, the eye on the same side becomes red, while the other eye is similarly, although to a less extent, affected. A second indication is the fact that the inflammation in the eye sympathetically affected is at times restricted to exactly the same place which in the first eye was injured or sensitive to pressure. A third indication, observed by Mayweg and Schmidt-Rimpler, is the fact that the sympathetically affected eye becomes at once red if the first eye is pressed on. And, finally, the ciliary nerves would seem to be involved by the fact drawn from experience, that atrophic cicatrices of the ciliary body and atrophic deposits dragging on the ciliary body are particularly prone to produce sympathetic inflammation, while there seems little to be feared in suppuration of the eyeball, in spite of the active bacteria present, presumably because the ciliary nerves are at the same time destroyed. Again, atrophy or even excision of the optic nerve appears to offer no absolute protection against sympathetic inflammation so long as any of the ciliary nerves remain.

Treatment must begin by interrupting the nervous connection between the eye first involved and the one sympathetically affected. This can be accomplished in two ways :—

(1) *By cutting the ciliary nerves.* This was proposed originally by v. Graefe, his plan being to sever only the ciliary nerves supplied to the injured area and then only from within, by introducing a knife through the membranes of the eye. The operation has found little favor. Snellen has found more followers; he severed the ciliary nerves before their entrance into the eyeball and by this means overcame pain otherwise unbearable. In operating he loosened an eye muscle, passed the scissors to the back of the eye, and cut something near the optic nerve, hoping to be fortunate enough to include the proper ciliary nerves in the incision.

If it is desired to sever all the ciliary nerves before they enter the eye the optic nerve itself must be cut through—*neurotomia opticociliaris.* If the theory of inflammation through or along the optic nerve is accepted, a mere cut through the optic nerve will not suffice, but a piece of it must be excised—*neurectomia opticociliaris.* To perform this operation the internal eye muscle must be detached, the eyeball rolled energetically outward, the scissors glided along the sclera till it reaches the optic nerve, which is then severed some

Digitized by Illinois College of Optometry

distance away from the eyeball. It is now possible to rotate the eyeball completely so that the posterior pole lies exposed in the conjunctival wound, when all the ciliary nerves entering at that place can be cut. The optic nerve stump still attached to the eye is now cut off, the eye replaced in its normal position, and muscle and conjunctiva sutured.

These different methods of severing the ciliary nerves are not a trustworthy protection against sympathetic inflammation, because all the ciliary nerves do not enter the eye in the vicinity of the optic nerve, and consequently the sensitiveness of the eye operated on is not necessarily destroyed after neurotomia opticociliaris. To be quite sure, the second way must be followed—enucleation.

(2) *Enucleation* of the eye first affected is the most serviceable, prophylactic, and curative remedy for sympathetic inflammation. It is easy to understand why patients should decidedly oppose this mutilating operation. If it is remembered, too, that it must, if possible, be performed before sympathetic inflammation begins, if the desired result is to be obtained and that every iridocyclitis does not necessarily lead to sympathetic ophthalmia, we can see that it is one of the most difficult tasks of the ophthalmic surgeon to decide when and when not to resort to enucleation.

The following rules may serve as guide:—

(1) If the first eye is blind, painful, and sensitive to pressure, enucleation is to be advised; it is to be urged, if the patient lives away from a surgeon, and thus may be in danger of overlooking the beginning of sympathetic inflammation. If the patient will not consent, he should be told to seek aid at the first sign of visual disturbance or of inflammation in the other eye.

(2) If the first eye has a foreign body, is painful and sensitive to pressure, enucleation should be urged even if the eye sees; it is to be supposed, of course, that the foreign body cannot be removed independently (*p. 417*).

(3) If sympathetic irritation or even inflammation appears in the second eye the first must be enucleated at once. If the first eye is not blind but still retains a certain visual acuity and is to some extent quiet, both patient and surgeon will hesitate at such radical proceedings. There is, however, no general rule for such a case; we must carefully compare the visual acuity of the first eye with the degree of irritation in the second; the more there remains to rescue in the second eye the greater price can be paid by the first.

Against fully developed sympathetic inflammation the physician is powerless. A late enucleation is usually of no effect and the inunction method so strongly advised by Wecker is designated by others (Michel) as of no value. Under such circumstances we must be content to prevent new accidents, to lessen pain by cocain, warm compresses, and to use similar symptomatic remedies. There may

Digitized by Illinois College of Optometry

be some hope for the subconjunctival sublimate injections so warmly recommended by French and Italian confrères. My own experiences have not been encouraging. Hydrargyrum oxycyanatum has been warmly praised for this purpose in solution of *1 : 5000*. Whether it is better than sublimate, or better than a quite indifferent solution (the physiological chlorid of sodium solution), is not as yet decided.

Months or years must elapse after all inflammatory phenomena have subsided before operations such as iridectomy or cataract extraction can be considered. Noticeable increase in tension forms an exception. If this is present (at the beginning of sympathetic inflammation) repeated corneal punctures or iridectomy may be performed in spite of the inflammation.

Enucleation of an eye is mutilation. The patient should, therefore, wear an artificial eye of glass or celluloid, which often is so like the real eye that even the nearest associates of the patient may not be aware of the deformity. This glass eye should be movable, since the muscles ought not to be injured in enucleation. The tendons of three recti muscles are separated from the bulb, the eye is then turned around so that the optic nerve can be reached by the scissors, the eyeball is luxated and the three remaining eye muscles cut off. These six eye muscles form, after healing, a flat stump covered with conjunctiva, which follows all the movements of the healthy eye and transmits them to the artificial eye resting upon this stump. If the movements of the healthy eye are extensive the artificial eye lags behind, but extensive movements are usually not resorted to.

To aid still further the associated movements of the artificial eye, *exenteratio bulbi* has been substituted for enucleation. This consists of scooping out the eye, so that cornea, lens, vitreous, uvea, and retina are removed, leaving sclera behind. The cavity closes, and a stump, consisting of scar-tissue, sclera, and muscles, remains. The stump is still better if, after scooping out the eye, an "artificial vitreous" of glass or unoxidizable metal is introduced and allowed to heal in place. Exenteration with the use of an artificial vitreous is, however, so new that at present it is still doubtful whether the cosmetic effect is not purchased at the cost of lessened security against sympathetic inflammation.

An artificial eye must produce no discomfort, and the stump particularly must be kept from irritation. Irritation of the stump by an artificial eye has led to sympathetic inflammation of the other eye. At night the artificial eye must be taken out and placed in water.

Digitized by Illinois College of Optometry

APPENDIX.

The question is often raised after injuries to the eye, how much the injured person is harmed in his ability to earn a living. According to the effect on such ability is the compensation to be paid the injured person estimated. If, for example, the injured person suffers a loss of 30 per cent. of his working power, and has therefore been injured 30 per cent. in his wage-earning capacity, there should be paid him for the remainder of his life 30 per cent. of his wages (income) as compensation.

It is a very difficult task to estimate the injury to wage-earning capacity, because there must be taken into account a number of factors which cannot be measured, but can only be guessed at. The most important factor is, of course, the amount of injury to the two eyes. It must be mentioned at the outset that a mere injury is not of itself a justifiable claim for compensation; the injury must be of such a nature as to hinder the patient from pursuing his vocation. It stands to reason that an injury to the visual organ may, in certain vocations, impair the wage-earning capacity, while the same injury may be no drawback to a man in another profession. It is, therefore, necessary to consider also the optical necessities of the vocation followed by the injured person. Seamen, railway employés, mechanics, and those in technical trades, require greater refinement of vision than do day-laborers, miners, coopers, millers, brewers, drivers, etc. Even workmen of the first group have no need for absolute $V = 1$ in order to be perfectly capable in their vocation. Again, a workman of the second group with possible $V = \frac{1}{20}$ is completely incapacitated, while a workman of the first group is incapacitated with V no lower than $\frac{1}{7}$, or even $\frac{1}{6}$.

The damage done to the eyes themselves is a product of three factors:—

(1) Visual acuity, (V)
(2) Visual field, (G)
(3) Excursional field, (B)
} and any impairment to them.

Of course, visual acuity is of more significance for the wage-earning capacity than is the visual field or the excursional field. Consequently, each one of these three factors is of different weight in the estimation of damage done. Finally, account must be taken of a fourth (but minor) factor, namely, that a workman finds it less easy to obtain employment after it is known or recognized that his

Digitized by Illinois College of Optometry

eyes have been injured. Many factories will not under any circumstances employ a one-eyed man, although with his one eye he may be able to satisfy all requirements of his trade.

The problem just examined has been mathematically presented in the following formula :—

$$E = V\sqrt{G} \times \sqrt[4]{B} \times \sqrt[x]{K}.$$

E signifies the earning capacity.
V signifies the visual acuity.
G signifies the visual field.
B signifies the excursional field.
K signifies the competitive element, that is, the capacity for obtaining a situation in the labor market.

All these values are either equal to unity ($E = 1$), that is, the injured person is not permanently impaired; or he is impaired in working power, and then the values all become real fractions. V is the most important factor and has no root sign; the other three quantities are represented with increasing root signs proportionate to their decreasing grade (value), since the root of a real fraction approaches closer to unity (that is, it has less influence on the product E) the higher its root sign.

By means of this formula Magnus has worked out a large series of cases of damage through injury. From his results I present in modified tables such cases as are of most common occurrence.

Loss of earning power, *one eye* being *damaged*, the other unaffected :—

V. of the Damaged Eye.	Loss of Working Power	
	In vocations demanding great technical skill and hence acute vision.	*In vocations with but slight need of acute vision.*
1 : 0.75	0. per cent.	0. per cent.
0.7	0.4 "	0. "
0.6	1.3 "	0. "
0.5	2.3 "	0. "
0.4	3.4 "	1.2 "
0.3	4.6 "	2.5 "
0.2	6.0 "	4.0 "
0.15	6.7 "	4.8 "
Less than 0.15	15.6 "	—— "
Less than 0.05	—— "	15.6 "
0.	31. "	27. "

Digitized by Illinois College of Optometry

Loss of earning power, *one eye* being *blind*, the other damaged in visual acuity. *Technical vocations demanding acute vision* :—

V.	Loss of Earning Power.
0.7	37.8 per cent.
0.6	51.0 "
0.5	63.8 "
0.4	75.8 "
0.3	86.9 "
0.2	96.5 "
0.1	100.0 "

LOSS OF EARNING POWER IF THE VISUAL ACUITY IN BOTH EYES HAS SUFFERED; TECHNICAL VOCATIONS DEMANDING ACUTE VISION:—

V. of the other eye. ↓ / V. of one eye. →	1 to 0.75	0.6	0.4	0.2
1 to 0.75	0	1.3	3.4	6.0
0.6	1.3	27.1	29.0	31.3
0.4	3.4	29.0	61.8	63.7
0.2	6.0	31.3	63 7	93.5

% of loss of earning power.

DISTURBANCES IN THE MOVEMENTS OF THE EYES.[1]

1. STRABISMUS PARALYTICUS (Paralytic Squint).

1. DIAGNOSTIC SIGNS.

Those who seek aid for paralytic squint are nearly always adults. They complain, as a rule, of *vertigo* and *diplopia* (double vision).

[1] To understand this section, an accurate knowledge of, or repeated reference to, Section V., *p.* 70 *et seq.*, is indispensable.

Digitized by Illinois College of Optometry

The vertigo is the result of a false projection (*p. 71*), and is consequently present only when using the diseased eye. The double vision is the result of the squinting position (*p. 72*), and, like this position, is present only in those areas of the visual field to reach which the paralyzed muscle must be called into play (*p. 85*).

In many cases double vision is rather masked. The patient complains that objects appear indistinct in some positions, and that at such times he has a feeling of discomfort. This depends upon masked diplopia, and implies that the patient has been at an earlier period accustomed to give particular attention to the images of only one eye, and that, consequently, the double images do not make a proper impression on his consciousness. By using a colored glass it is generally easy to change such a masked diplopia into clearly perceived double images (*p. 87*).

The complaints of the patient differ, according to whether the loss of muscular power is complete (*paralysis*) or incomplete (*paresis*); and according to the importance of the

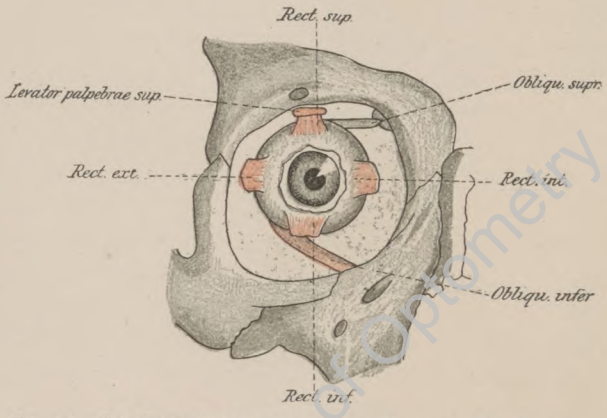

FIG. 151.—THE EYE MUSCLES SEEN FROM IN FRONT. (*After Merkel.*)

diseased muscle for covering particular areas of the visual field. In reading and writing, for example, paralysis of a muscle involved in movement to the right (rectus internus of the left or rectus externus of the right eye) causes far more disturbance than paralysis of the muscle involved in movement to the left; in going up stairs (in all motion, in fact), paralysis of the depressor muscles (recti inferiores and obliqui superiores) causes more disturbance than paralysis of the elevators (recti superiores and obliqui inferiores).

Often, in looking at a patient making such complaints, an oblique position of the head may be noticed. The patient soon learns, when looking at objects in front of him, to use a position of the eyes in which as little demand as possible is made upon the paralyzed muscle. If, for example, the left rectus externus is paralyzed, the patient turns his head toward the left; his eyes must, therefore, make a compensatory movement toward the right in order to look

Digitized by Illinois College of Optometry

straight ahead. If a superior rectus is paralyzed, the patient throws his head back in order to bring his eyes under the control of the depressor muscles, the recti inferiores and obliqui superiores. These positions of the head are so significant that of themselves they may betray the condition to the experienced observer. A long continuance in such positions of the head may cause contractures of the neck and back muscles. Cases are reported in which stiff neck (torticollis) has been treated in vain, until the cause for the stiff neck was discovered to be an eye-muscle paralysis.

In making a diagnosis it is of the greatest importance to be sure that the double vision is not confined to one eye (*p. 358*); in such a case, of course, double vision remains when the other eye is closed. It must be further tested to see that the disturbance in movement does not depend on some simple external cause, as a pterygium, a collection of pus or blood, or some new growth behind the eyeball.

If such causes can be excluded we may assume the squint to be paralytic and try to find out which is the paralyzed eye. In pronounced cases a simple test of the excursion of movement in each eye will suffice (*p. 85*), since the recognition of a lapse in either eye proves that this eye is diseased. But in other cases this method of examination gives no exact results,—either because the paralysis is not complete, and consequently the lapse of movement is too small, or because the paralysis involves muscles, the obliqui, for example, which are of minor importance in performing the visual excursion. In such cases the position of the other eye remaining covered must be compared with the position of the fixing eye. If, for example, the rectus externus of the left eye is half paralyzed and the eye in consequence is unable, even with the greatest effort, to follow to the normal limit of its excursion a finger moved in front of it toward the left, the right and covered eye will pass into the position of extreme adduction and its visual line will finally aim toward the left of the finger followed by the left eye. This is a proof that the same impulse of the will affected the externus of the left eye less than it did the internus of the right eye, and that, therefore, the left is the eye paralyzed. There results from this the general rule that "the more squinting eye is the healthy eye," because when the diseased eye looks toward the side of the paralyzed muscle, the healthy eye passes into the deviation of squint (*p. 85*), which is greater than the primary deviation which the dis-

Digitized by the Internet Archive in 2010

eased eye assumes if the healthy eye fixes. A further sign is given by the fact that the vertigo ceases when the diseased eye is closed. This sign may have been noticed by the patient, who is accustomed, therefore, to squeeze his bad eye shut. To be sure this is not always the case, for it may happen that the diseased eye possesses the better visual acuity, in which case the patient neglects the unparalyzed eye and fixes with the paralyzed one, attempting, meanwhile, to protect himself against false projection of images and the vertigo accompanying it by moving his head. If these methods still leave the diagnosis uncertain, we must resort to the double image test as explained by the rules given on *pp. 87, 433*.

The diagnosis must now be extended to the detection of the paralyzed muscle or set of muscles. This task, so easy in some cases, may in other cases be one of the most difficult in the whole extent of ophthalmology or neurology. In one instance several muscles of one or of both eyes may be paralyzed, in another instance the paralysis may attack eyes in which the muscle balance has already been previously disturbed. Finally—a frequent result, too—when the paralysis of one muscle is of long standing, there develops a secondary contraction of its antagonist. It is evident that to keep all these circumstances clear in one's mind must be an extremely difficult task. We can now examine the simplest cases, namely:—

(*a*) Isolated paralysis of a rectus externus;

(*b*) Isolated paralysis of an obliquus superior;

(*c*) Paralysis of the muscle group supplied by the nervus oculomotorius.

These three cases are the commonest and the most practically important. The reason for this will be explained in the discussion of causes.

In A. Graefe's rich experience of eye-muscle paralyses the following were the usual percentages in each 100 cases:—

32 per cent. isolated paralysis of a rectus externus;
16 per cent. isolated paralysis of an obliquus superior;
8 per cent. isolated paralysis of one of the four remaining muscles;
44 per cent. combined paralysis of all these four remaining muscles in one or both eyes.

(*a*) **Paralysis of the Left Rectus Externus.**[1]—The patient holds his head to the left. If his right eye is now closed and if he

[1] For simplicity's sake I shall describe a left-sided paralysis in each instance. The student can make out a right-sided paralysis by changing the words in the text.

Digitized by Illinois College of Optometry

is asked to walk rapidly about the room, he will grow dizzy enough to fall. If a finger is then held toward the right,[1] and if he is asked to fix this finger, both eyes take the proper position with reference to it; but if the finger is now moved over the median line of the patient toward the left, his left eye remains still, or moves only in a jerky manner, with alternate rotatory movements in opposite directions, upward outward and downward outward, this being the result of the contraction of the two obliqui, which are vainly endeavoring to act in place of the paralyzed externus. The farther the finger passes to the left, the more evident is this lagging behind of the left eye and the accompanying position of convergence caused by it.

Fig. 152 illustrates the position of the double images for nine

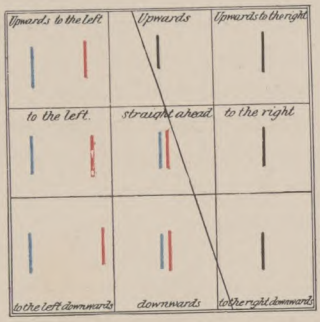

FIG. 152.—DOUBLE IMAGES IN PARALYSIS OF THE LEFT RECTUS EXTERNUS. A Red mark is the image of the Right eye; a bLue mark that of the Left eye. The words on the chart indicate the areas of the field of vision.

different areas of the visual field; they appear as they would to the reader if his left rectus externus were paralyzed. It will be seen that the line separating the field into two parts—one containing double images, the other a single image—is not perpendicular but runs from above and to the left downward and to the right. This depends on the fact that, when looking upward, convergence is physiologically favored, and when looking downward, divergence is so favored. This fact is explained by the habit of looking at distant objects with the eyes somewhat raised, but at near objects, the book, for example, with the eyes lowered. It may be added that occasionally a moderate obliquity and inequality of elevation in the two images is admitted.

[1] Right and left always refer to the patient.

Digitized by Illinois College of Optometry

If the paralysis is incomplete, the dizziness may be quite prevented by the patient's turning his head to the left. The left eye follows the finger more or less toward the left past the median line of the body, but the external edge of the cornea cannot be brought to the outer canthus. If this lapse is too small to establish a diagnosis, the physician must observe the secondary deviation of the healthy eye, which seemingly exaggerates the disturbances of movement in the diseased eye. The line separating the visual field into parts of single and double images lies rather more to the left than in *Fig. 152;* in the minimum degree of paralysis the double images may quite escape notice, since by an unequal innervation of the two muscles involved in movement toward the left (stronger impulse to the left externus, weaker to the right internus)



FIG. 153.—DOUBLE IMAGES IN PARALYSIS OF THE LEFT OBLIQUUS EXTERNUS.
A Red mark is the image of the Right eye; a bLue mark that of the Left eye. The words on the chart indicate the areas of the field of vision.

a fusion of the images may be accomplished. The desire to fuse, and the range of fusion, differ in different cases. If we wish to make the position of the eyes independent of fusion, we should use a prism, base downward or upward, held before one eye. Fusion will now be impossible, and a latent separation of the images will be easily discovered.

(*b*) **Paralysis of the Left Obliquus Superior.**—The patient turns his head downward toward the right, that is, about an axis running in the same direction as the line (*Fig. 153*) separating the field into two parts, from below to the left upward to the right. He thus brings the upper left part of the visual field immediately to the front, this part being usually but little used. This position of the head is therefore particularly noticeable, and is diagnostic of paralysis of the trochlearis.

Digitized by Illinois College of Optometry

The restriction in movement is much smaller than in paralysis of the rectus. It is best demonstrated, however, by moving the finger downward and to the right, into the lower right ninth of the visual field; in this case the eye cannot follow the finger; the eye is too high. To understand this, the student should refer to *Fig. 27* (*p. 78*). It will be noticed that if the left eye is rotated sufficiently to the right, the horizontal axis, that is, the axis of rotation for depression, forms a right angle with the direction of traction of the tendon of the superior oblique muscle; consequently to effect a sufficient turn to the right in the left eye, the superior muscle must become a pure depressor. Since the lower right area of the visual field can be reached only by means of the left superior oblique, a paralysis of this muscle must cause the left eye to remain the furthest away from this position. The condition is reversed in looking downward to the left. In this direction the rotatory muscle becomes purely a muscle for circular rotation, and consequently a paralysis of it has no influence upon such available positions of the visual lines.

Double images are of particular importance in overcoming the difficulties encountered in perceiving and measuring any restrictions in movement. They are illustrated in *Fig. 153*, and correspond to the position of the eyes in the diagram. In looking to the right there is seen a difference in elevation, which increases as the candle (the test fixation-point) is lowered. In looking downward to the left there is seen the greatest obliquity, an evidence of rotatory movement exaggerated in an eye in which the inferior oblique has lost its antagonist. The image is moderately depressed and removed to the side. In looking straight ahead or directly downward, there is obliquity, depression, and removal to the side, the last condition allowing the recognition of homonymous double images. Since the superior oblique muscle causes abduction as well as depression and rotation, its paralysis must result in adduction or a position of convergence.

Many patients assert voluntarily that the lower image—belonging to the diseased eye, therefore,—appears nearer and, perhaps, smaller than the image of the healthy eye. The smallness of the image is to be taken as the result of its apparent nearness. We may decide that two retinal images of the same size belong to two objects of different sizes, in case we choose, for one reason or another, objects at different distances (*compare p. 288*). The apparent nearness of the image is itself not yet satisfactorily explained, and the views of various authors are not harmonious. Two facts in this connection may be mentioned: first, that the nearness of the lower image is not apparent in trochlear paralysis alone, but

Digitized by the Boston Public Library Ophthalmology

may be produced artificially in the higher image by means of a prism, or displacement of the eye with the finger; and, second, that the surroundings of the double images have a distinct influence on the lower image. For example, a ball hanging on a thread appears as two images exactly over each other, while the same ball on a plate appears as two images, one in front of the other. (*Nagel's experiment.*)

If the paralysis is incomplete, the obliquity of the images or the restriction in movement will not be evident, or will be demonstrable only in the lower right corner of the visual field. The diagnosis depends then exclusively upon the double images, that is, upon double vision, with predominant elevation to the right below, and with predominant obliquity to the left below.

(*c*) **Paralysis of the Muscle Group supplied by the left Nervus Oculomotorius.**—*Rectus superior and inferior, rectus internus and obliquus inferior.* The recognition of this pathological condition is easy, since a complete paralysis of so many muscles must produce appreciable disturbance. The position of the two eyes when looking straight ahead is one of divergence. The movement of the diseased eye inward, upward and downward, is prevented; movement outward (to the left) and outward downward (downward to the left) is still possible with the rectus externus and obliquus superior. Consequently, divergence increases decidedly when looking toward the right. When the eyes are directed upward there is depression—when downward, elevation—of the diseased (left) eye.

In an incomplete paralysis, on the other hand, the visible defects of movement are less apparent, and the diagnosis must be made from the location of the double images. As *Fig. 154* shows, these are crossed; in looking upward the image of the left eye is higher, in looking downward, lower, than the image of the right eye; but the difference in elevation is less in looking downward than in looking upward, because one of the muscles concerned in depression, the superior oblique, is not affected. The distance between the two images increases in looking toward the right, and disappears in a small area of the visual field lying to the left and below when looking in that direction. There is also obliquity of one of the images, but this is usually noticed by the patient only when the images are close together, as in looking directly outward or downward, or toward the left downward.

In the majority of cases, even in those of hemiparalysis, the diagnosis is essentially simplified through the involvement of other muscles. To make this clear we must understand and apply what

Digitized by Illinois College of Optometry

is said further on concerning the nature of eye-muscle paralysis,—that in the great majority of cases the condition is of disease of the nerves rather than of the muscles. Since the nervus oculomotorius supplies a lid muscle, the levator palpebræ superioris, and two internal eye muscles, the sphincter iridis and the musculus ciliaris, as well as the four external eye muscles already mentioned, the typical pathological picture is the following: The upper lid droops and its horizontal folds are obliterated; if the lid is elevated, the pupil of the diseased eye is found to be moderately dilated and irresponsive to any of the three methods of stimulation (*p. 269*)—it is rigid. The power of accommodation is lost, causing more or less disturbance of vision according to the refractive condition.

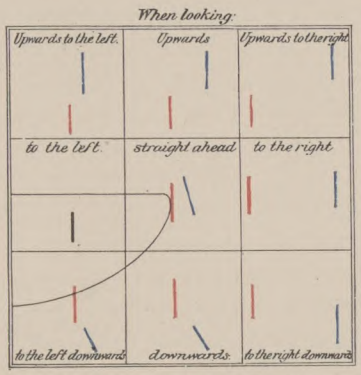

FIG. 154.—PARALYSIS OF THE LEFT OCULOMOTORIUS.
A *R*ed mark is the image of the *R*ight eye; a b*L*ue mark that of the *L*eft eye. The black mark is the single image for the two eyes.

There is some exophthalmos, because three of the four recti muscles which draw the eye backward are paralyzed.

The general rule for determining a paralyzed muscle may be deduced from what has been said: place a candle in each of the above-mentioned nine areas of the visual field and ask the patient, his sound eye being particularized by having a red glass disk in front of it, to fix this candle without turning his head. The patient's responses as to the location of the double images are to be noted by a red and a blue pencil. From a diagram thus made it is not difficult to form a diagnosis, provided that the action of each muscle (*p. 76*) is known and that the case is a fresh and uncomplicated one. But since there are some patients in whom the distinct type of an eye-muscle paralysis is obscured, the most important complications need a short analysis.

(*a*) **Secondary Contractures.**—If the paralysis has lasted some time, the antagonist of the paralyzed muscle is accustomed to drag the eye more and more to its own side, even in a condition of rest, and "secondary contracture" is the result. Consequently, squint and diplopia are present even in those areas of the visual field in which the paralyzed

Digitized by the College of Optometry

muscle is inactive. If, for example, in the above case of paralysis of the left rectus externus, a contracture of the left rectus internus had supervened, the line separating the visual field into its two parts of areas with and without double images would lie farther to the right or, perhaps, would fall quite at the edge of the visual field; and in the left part of the field the double images would be wider apart than before. The differential sign in the association of paralysis of the left externus with contracture of the left internus depends upon the fact that in looking toward the left the double images flit apart in the left half of the visual field, while in looking toward the right the same distance is maintained in the right half of the visual field.

(*β*) **Preexisting Disturbance in Equilibrium of the Muscles.**—If a patient suffering from latent squint (*p. 89*) is attacked by paralysis in the muscles of one eye, the latent squint will change into manifest squint for that part of the visual field in which binocular fusion is now rendered impossible on account of this muscle paralysis. In this case the location of the double images is influenced both by the paralysis and by the latent squint. For example, if a weakness of both internal recti (lateral divergent squint) is associated with paralysis of a depressor muscle, there will be crossed double images in looking downward, irrespective of whether it is the inferior rectus (with its adduction) or the superior oblique (with its abduction) which is paralyzed. For the slight convergence that may be expected as the result of paralysis of the oblique as abductor will be more than neutralized by the preexisting latent, divergent squint now become manifest.

How can we distinguish in such a case whether the rectus inferior or the obliquus superior is paralyzed? How can we be sure whether actual latent squint is present? The first question is answered by the statement of the fact that the mode of action of an inferior rectus and of a superior oblique is subjected to exactly opposite changes in adduction or abduction of the eye. (*See Fig. 27, p. 78*). By a definite movement of the eyes toward the right the rectus inferior of the left eye becomes a pure muscle of rotation and the obliquus superior a pure depressor; by a definite movement of the eyes toward the left the rectus inferior becomes a pure depressor and the superior oblique a pure muscle of rotation. Consequently, if the candle is moved to the right and then downward, the difference in elevation between the double images increases when the obliquus superior is paralyzed, but decreases if the rectus inferior is paralyzed. No attention need be paid to the obliquity of the double images, since the statements of the patient are quite untrustworthy and since the elevation of the images will differentiate as completely as will be necessary.

The second question is answered by using a prism before one of the eyes, base downward or upward. By this means the desire to suppress the latent, divergent squint is overcome for the upper half of the visual field, and the double images will, therefore, appear in this upper half as well, but obviously without difference in elevation.

Paralysis of all the external eye muscles is called, since Mauthner, *ophthalmoplegia exterior*, while paralysis of the sphincter pupillæ and the ciliary muscle is termed *ophthalmoplegia interior*; association of both conditions is called *ophthalmoplegia totalis*.

2. LOCATION AND CAUSES.

The optical symptoms of an eye-muscle paralysis can be produced by cutting one of the six muscles concerned in the eye's movements. This has often enough been done, as a "myotomy" for

the correction of squint. At the present day, when section of the tendon has displaced section of the muscle, it may yet occasionally happen that the effect of a tenotomy is too strong, and produces a paralysis or hemiparalysis of the incised muscle. In some cases the obliquus inferior is loosened by an accident from its origin—the lateral bony edge of the lacrimal fossa—and is then in reality paralyzed. We may, however, pass over such cases recognizable by the history or by an external scar, as well as other cases due to hemorrhages, inflammations, or new growths in the orbit, all of which may lead to restriction in eye movements. There still remains the majority of all cases of squint paralysis, in which there is no demonstrable lesion or disease of the muscles themselves; the cause for these must, therefore, be sought for in the nerves of the eye—the oculomotorius, the abducens, the trochlearis—or in their tracts in the brain.

It may be mentioned here that an isolated lesion of the individual eye muscles is by no means impossible. Why is it not probable that the same process is at work in the orbit, which here and there affects individual muscles of the extremities and makes them painful and destroys their function by rheumatism? Such a process, considering the inaccessibility of the eye muscles, would, to be sure, be hard to diagnosticate or to differentiate from disease of the nerves.

Assuming that a disease of the nerves is present, an exhaustive diagnosis must elucidate a three-fold problem :—

(*1*) The spot in the path of the nerve which is incapable of functionating.

(*2*) The nature of the disease,—whether the nerve is idiopathically affected, whether it is involved in disease of adjacent structures, or whether it is merely mechanically implicated.

(*3*) The ultimate cause of the disease, whether infection, intoxication, or injury.

Only in exceptional cases is it possible to demonstrate these three points with satisfaction. The first offers extraordinary difficulties on account of the very complicated path of the nerve in the brain, and since many questions of brain anatomy are yet unsettled, the description here given can be only an incomplete one.

(*1*) The most important aid to exact localization of that portion of the nerve deprived of function consists in establishing the presence of other nerve paralyses not necessarily limited to the eye, and confirmed by a careful examination made by the neurologist. As it may be assumed that such paralyses arise from the same focus in

Digitized by Illinois College of Optometry

the brain, we may localize the disease at the spot where the paths of the paralyzed muscles are close together. For example, if paralysis of the left abducens occurs with paralysis of the right arm and leg, we may assume a focus in the lower left portion of the pons, since in this spot the abducens for the same side of the body, and the nerves for arm and leg of the opposite side, lie close together.

Localization in oculomotor paralysis is particularly difficult, since this nerve in its entrance into the orbit divides into numerous branches and twigs, and since it arises with many roots from its nucleus on the floor of the aqueduct of Silvius (*Fig. 113, p. 305*). There is little difficulty if all muscles innervated by the oculomotor are paralyzed and if play of pupil, accommodation, most eye movements, and elevation of lid are lacking. In such a case we may assume a disease of the origin of the nerve at the base of the brain. In rare cases a paralysis of all oculomotor branches is to be referred to disease of the nucleus in the medulla, but such a condition can be diagnosticated only by the course of the disease. The paralysis of the iris and ciliary muscle appears earlier or later than that of the external eye muscles. The nuclei for the pupil and for accommodation (*Fig. 113, p. 305*) are quite independent of the others in spite of their great proximity. According to Mauthner this depends upon the fact that these nuclei are nourished by different terminal arteries, and that the brain area nourished by each terminal artery is of itself a focus for an independent lesion. If accommodation and pupillary action are unimpaired we are, therefore, warranted in assuming an oculomotor paralysis to be a nuclear paralysis. Even if the diseased focus increases in dimension and if paralysis attacks all the external muscles of one or both eyes, those supplied by abducens and trochlearis included, the retention of pupillary action and accommodation warrants the diagnosis of nuclear paralysis, because in the nuclear region the individual oculomotor nuclei are comparatively wide apart, while in the nerve itself all fibers are crowded comparatively close together. For the same reason Mauthner assumes a nuclear paralysis if the inner eye muscles—sphincter pupillæ and ciliary muscles—are paralyzed, or if a definite movement, convergence, for example, is impossible.

If a single muscle supplied by the oculomotor is paralyzed, we speak at once of nuclear paralysis. It is a question whether or not this is correct. The possibility of disease of the muscle itself has been already mentioned. By neglecting this, there are still other possibilities which must be thought of, especially since the latest investigations have

shown that circumscribed groups of ganglion cells, so-called nuclei, may have the significance of functionating centers, that is, they may control certain movements through which different muscles are brought into play. This all indicates that a paralysis of convergence is a nuclear paralysis. But isolated paralyses of single muscles, say of the internal rectus, may be otherwise explained. The following possibilities may be thought of :—

(*a*) The nerve might be diseased close to the entrance into the muscle ;

(*b*) The fibers to each muscle might be independently diseased in the nerve trunk ; a condition well recognized by neurologists, who have frequent opportunity of observing that a toxic neuritis, such as lead or arsenic paralysis, attacks special fibers of a nerve trunk ;

(*c*) The intracerebral roots of the nerve fibers and the ganglion cells belonging to them, though perhaps separated in space, might degenerate independently. Such a case, as well as the one mentioned under *b*, might be designated "systemic disease" in the physiological sense of the word.

Whatever may be the conclusion about such possibilities, I am sure that the diagnosis —nuclear paralysis—has been used altogether too freely. Siemerling has recently published a case of ophthalmoplegia externa, in which anatomical examination showed the oculomotor nucleus normal, while the intracerebral roots, their continuation in the nerve trunk, and their terminal branches, as well as the muscles themselves, were all found diseased.

Uhlhoff's investigations also have shown that it is sometimes going too far when the conclusion is drawn from functional disturbances seen during life that there must be definite anatomical changes. Uhlhoff has found at the autopsy that the oculomotor root at the base of the brain was the seat of the lesion, although only particular muscles of those supplied by the oculomotor were paralyzed during life ; and in other cases the muscles supplied by the oculomotor functionated normally during life, although at the autopsy the oculomotor trunk was found diseased.

The brain cortex or the track between cortex and nuclear region must finally be mentioned as a location for the lesion. If a diseased focus lies here, the condition is to be termed a "conjugate" or "associated" disturbance of movement, and not an eye-muscle paralysis in a restricted sense. This disturbance of movement consists of inability on the patient's part to carry out those associated visual movements which respond to light stimulation, while the same visual movements may be properly performed either voluntarily, or through aural or tactile stimulation. As a rule, this conjugate disturbance of eye movement shows itself as a conjugate deviation. An exception from this is the "cerebral ptosis," that is, an isolated paralysis of one levator palpebræ superioris, the cause of which may be found at the autopsy to be a lesion in the anterior portion of the cortex of the opposite side.

(*2*) As far as concerns the nature of the disease we may distinguish :—

(*a*) Independent affections in the course of the nerve, as neuritis,

Digitized by the College of Optometry

perineuritis, inflammation of the nuclei (polioencephalitis, inflammation of the gray matter in the ganglia on the floor of the fourth ventricle and aqueduct of Silvius), with destruction of the ganglion cells, scleroses, and degeneration of individual groups of ganglion cells.

(*b*) Diseases of neighboring tissues which involve the nerves or their roots, as inflammations, new growths, softening, and degeneration foci.

(*c*) Diseases of remote tissues which, in a mechanical way, interrupt or hinder conduction along the nerves, as new growths and hemorrhages.

Which of these causes is at work can be found out only by studying the history and the general condition of each case. Often enough this does not suffice. Not infrequently paralysis of a lid or eye muscle may be the first and but fleeting sign of a grave brain or spinal cord lesion, such as tabes dorsalis, multiple sclerosis, or progressive paralysis. Tubercular meningitis and tumors of all kinds may produce an eye-muscle paralysis.

(*3*) As essential causes of the brain lesions here enumerated, various infections must bear the blame. Syphilis especially must be charged with causing ten to 20 per cent., or according to v. Graefe 50 per cent. of all cases. Equally as common are the paralyses from tuberculosis of the meninges, other forms of meningitis being less disastrous. Another group of paralyses, those caused by the poison of diphtheria, is of great interest to the ophthalmologist. Usually the muscle of accommodation, less so an external eye muscle, is affected. Finally, Grippe, rheumatism, typhoid and other poisons like nicotin, alcohol, lead, ptomains, carbonic oxide gas, have all been causes. Occasionally an eye-muscle paralysis has been traced to a cerebral hemorrhage due to arterial sclerosis, diabetes, or fractures at the base of the brain.

3. PROGNOSIS.

This is favorable in paralyses that result as a sequel to diphtheria or from some mild injury or transient intoxication. It is doubtful in paralyses from some unknown cause, or from what for tradition's sake we love to call "catching cold." Such "colds" may return after a time, bringing associated paralyses of other nerves with them, and then the true nature of the disease may be made out. The prognosis is bad in paralyses which are recognized

Digitized by Illinois College of Optometry

with the presence of other pathological signs as but a part of some grave spinal cord or brain lesion.

4. TREATMENT.

This should begin by covering the unsound eye to prevent the double vision and the accompanying vertigo, after which the cause of the trouble must be attacked, supposing that it can be discovered. If there is syphilis, mercury, diaphoresis by medicine or bath, and large doses of iodid of potassium are to be used. Diabetes demands the proper diet and hygiene. Injuries must be treated by rest. Diphtheritic paralysis usually heals by proper bodily nutrition, as do also cases due to mild intoxication; a deep-seated lead palsy, on the contrary, heals neither of itself nor by treatment. In all cases due to some obscure cause, a specific treatment is impossible, but we need not, therefore, condemn the numerous remedies so warmly recommended for "paralysis." Bleeding, cathartics, diaphoresis, large doses of iodid of potassium, exercise to the (half) paralyzed muscle, and electricity—either the galvanic or faradic current—are at our disposal. A trial of iodid of potassium is always to be recommended, even if the patient confesses no syphilitic infection and if no signs of it are present.

If the paralysis continues in spite of these methods and there is no likelihood of cure, there remains the task of relieving the patient from the severest and most distressing disturbance, the double vision. In some cases this is not present, for, besides the eye muscles themselves, the levator may be paralyzed and the drooping lid will, therefore, exclude the unsound eye from its part in vision; or tabes may have progressed so far that the diplopia is no longer perceived because the optic nerve is attacked and visual acuity thus reduced in addition to the oculomotor paralysis.

If double images are present to the patient's discomfort an attempt can be made to fuse them by means of prisms. In spite of the theoretical objection that a special prism is needed for each visual direction or none at all needed when the eye looks toward the healthy side, prisms have shown themselves serviceable in many cases. Such cases have a decided range of fusion. Suppose the left external rectus to be paralyzed and an extensive range of fusion present, a prism of 4°, 6°, or 8°, base outward, may produce single vision for a part of the visual field lying to the left, while in looking straight ahead or toward the right fusion may be main-

Digitized by the Internet Archive in 2010 with funding from University of Toronto

tained by contraction of the two interni, that is, by intentional convergence.

In other but less common cases the harmony of eye movements may be restored by weakening (tenotomy) the power of an associated muscle of the sound eye; much more importance is, however, attached to the use of the eyes than to their excursion. Suppose a left superior oblique to be half paralyzed; ought an oblique muscle or the inferior rectus of the right eye to be tenotomized? Obviously the latter, for since both oblique muscles have an abducting factor, it would only increase the tendency to convergence and homonymous double images if a remaining, unaffected oblique muscle were weakened; while to weaken the right inferior rectus, which is an adductor, would decrease the moderate tendency to convergence and still more decrease the difference in elevation of the double images, than would a tenotomy of a right oblique muscle—an operation, it may be remarked, very difficult to perform. In studying this rotatory factor we learn that the superior oblique of one eye is associated in movement with the inferior rectus of the other.

In the majority of cases of lasting eye-muscle paralysis nothing can be done beyond excluding the paralyzed eye from vision by a bandage or an opaque glass in the spectacle frame. If secondary contracture develops during the disease the treatment is to be that of concomitant squint given on *p. 445*; but an attempt should be made to oppose the development of this contracture by Michel's method, which consists in stretching the antagonist of the paralyzed muscle. This is done by seizing a fold of the conjunctiva in fixation forceps and then repeatedly rotating the eye toward the side of the paralyzed muscle.

II. STRABISMUS CONCOMITANS, Concomitant Squint, with Particular Reference to Convergent Squint.

1. VISION IN STRABISMUS.

Convergent squint develops nearly always in early childhood. In the beginning it shows itself only at intervals as *strabismus periodicus*, and, as attentive mothers may observe, usually when the child is looking at a near object. The squinting position becomes more frequent until it has finally, even if after years, become constant.

Digitized by University of Illinois College of Optometry

In case the same eye always deviates, the condition is called *strabismus unilateralis;* if both eyes are alternately used for fixation, first one and then the other deviating, the condition is called *strabismus alternans.* The demonstration and the measurement of the eye's deviation has already been given on *p. 89.* With reference to the diagnosis only the differences between paralytic squint and concomitant squint need be here emphasized.

In paralytic squint there is:—
(1) Contraction of the Field of Vision;
(2) Secondary deviation greater than the primary;
(3) Disturbance with double images.

In concomitant squint there is:—
(1) Displacement of the Field of Vision, but no contraction;
(2) Secondary deviation equal to the primary;
(3) No disturbance with double images.

The first point needs nothing more than what is said on *p. 89.* The second needs a short, but the third an elaborate explanation.

(2) In concomitant squint the position of the eyes in relation to each other is faulty, but the movements of the eyes are quite normal. For example, suppose there is convergent squint with the left eye squinting. If the right (the fixing) eye is turned to the right, an equally strong impulse, according to the rule of association between eye muscles, is sent to the internal rectus of the left eye, and the result is that both eyes are turned toward the right with unchanged degree of convergence. If the right eye is now covered and the left induced to fix, the latter must pass out of its position of squint by an impulse sent to its external rectus. This is not possible without sending an equally strong impulse to the internal rectus of the right eye, in consequence of which the right eye also turns to the left an equal amount, that is, an amount equal to the angle of squint. This "secondary deviation" of the right eye is, therefore, just as great as the "primary deviation" of the left eye.

(3) Having confirmed what has been said (*p. 70*) about projection of retinal images and (*p. 428*) the conditions in muscle paralysis, we might suppose that in concomitant squint there would also be double images—homonymous in convergent, heteronymous in divergent squint. Experience shows that this is not so, but that the patient does not see at all with the squinting eye the object fixed by the normal eye, or, in other words, that the retinal image of the squinting eye remains unperceived. This does not mean that the squinting eye is entirely excluded from participation in the

Digitized by the College of Optometry

visual act. It can be easily demonstrated that objects within the visual field of the squinting eye are partly seen, partly not seen,—that there is a "regional exclusion." At all events, the squinting eye perceives everything lying within that part of the total visual field belonging to the squinting eye alone. Since in divergent squint the individual fields coincide in a smaller area than normal, the total visual field must, therefore, be greater; in convergent squint, for a corresponding reason, it must be smaller than normal. Objects lying within that part of the visual field common to both eyes are not all necessarily excluded from the squinting eye, but only those that would disturb the vision of the healthy eye. For example, many squinting patients say that when reading they see double at the beginning or end of a line, that is, that the image in the squinting eye is not suppressed if it appears on the background of white paper, but that it is suppressed when it appears at a spot where letters are seen by the healthy eye. Reading would, of course, be quite impossible if each eye projected different letters to the same spot in space; diplopia for objects seen at one side causes, however, little disturbance, a condition explainable by what has been said about the presence of physiological double images (*p. 75*). It is easy to understand, too, that the fixing eye will conquer when there is a struggle between images of different objects for the same spot in space. The normal eye, on the one hand, has a better visual acuity (*p. 444*), and, on the other hand, it uses in the struggle its most sensitive retinal area, while the squinting eye must be content with eccentric vision from a more peripheral and less sensitive retinal area.

This suppression of retinal images on certain areas is the means adopted by the eye for freeing itself from the disturbance of diplopia. The process is a psychical, although an unconscious one, accomplished by association of action in the two eyes. This, and other conditions also, may be established from the fact that the double images unnoticed by the patient are, in most cases, made perceptible by simple means. Many who squint see double as soon as their attention is called to it. Others may be made to see double by placing a dark-colored glass in front of the eye with the better vision. If this does not suffice, a prism, with base down or up, should be placed in front of the deviating eye, while the dark-colored glass remains in front of the fixing eye. In the deviating eye there will then be formed an image of the object fixed by the healthy eye, this image falling upon a retinal area where retinal images have not as yet been suppressed because they arose from objects seen peripherally by the healthy eye also. We have now a condition which the squinting eye has not learned to treat to its best advantage. In some cases double images cannot be produced by any artifice whatever.

The preceding statement in no way contradicts the laws of projection already given

Digitized by Illinois College of Optometry

(*p.* 70), but only shows that nature can evade such laws in the interest of single vision. There are, however, some squinting persons in whom retinal images are really projected otherwise than ought to be expected from the law of projection. Many such patients, after double vision has been produced by the use of a co ored glass, assert that there is such a distance between the two images as would show a direct contradiction to the actual position of squint, since this distance must be too small for the demonstrable angle of squint. There are even cases with binocular fusion in spite of a squint, that is, cases in which the retinal image on the fovea centralis of the fixing eye is fused with the image formed on a peripheral (unequal and weaker) retinal area of the other eye. It is seen, therefore, that the law of "identical retinal areas" is anatomically favored by equal visual acuity of identical areas and is perpetuated by use of such eyes, but that this law can be violated by a continued position of squint. Such violation is unnatural. This may be seen in the results of overcoming convergence by an operation; at first crossed double images appear, as if divergence were present instead of the normal position, but this condition does not last long; after a few days the natural association of retinal images masters the acquired association and the double images disappear.

2. CAUSES.

The eyes when closed are in a position of equilibrium. The form and direction of the orbits, the length, thickness, and attachment of the eye muscles, the shape of the eyeball, in short, the anatomical relations of the eye, its soft and its bony surroundings, all have their influence on this position of equilibrium. As a rule, though not always, these anatomical relations are the same for both eyes. On account of the distinctly appreciable divergence of the orbits this position of equilibrium might also be divergent, but as divergence of the visual axes is not used in vision, the position is rather that of parallelism, or even of convergence for near work. Since the use to which an organ is put has a decided influence on its anatomical structure, it is probable that the eye muscles develop during early childhood so as to make parallelism of the visual axes the position of equilibrium. Parallelism of that exactness requisite for distant vision is, however, confirmed by anatomical relations only in the rarest cases.

From the above it may be deduced that *squint depends upon a deviation of one or both eyes from the normal position of equilibrium.*

We must, then, find out whether the disturbance of equilibrium is produced by anatomical conditions alone, or by physiological conditions as well, perhaps by an habitually over-strong nervous impulse to the internal muscles.

It must be remembered that the need of proper adjustment of the eyes exists only for the sake of binocular single vision. If this need is lacking, or if the eye is influenced by unequal visual

Digitized by Illinois College of Optometry

acuity[1] or unequal refractive condition, it is evident that the least disturbance of muscular equilibrium must lead to squint. Conversely, if visual acuity and refractive conditions are equal, and if the will power is strong enough, a considerable disturbance of muscular equilibrium may be present without causing squint, because the impulse or, in certain cases, the desire for binocular simple vision can, in a physiological manner, take the place of a muscular equilibrium not supplied anatomically. In this sense we may speak of inequality in visual acuity as direct cause of squint.

It must be further remembered that a second influencing factor lies in the association of convergence and accommodation (*p. 79*). The proper position of the eyes can be thereby induced, even if, on account of weaksightedness, there is no need for it. But this very factor becomes a cause of squint if refractive error is present. Hyperopia calls out an abnormally strong accommodation with its consequent convergence, which is greater than is necessary for the distance of the object fixed. Conversely, in myopia the accommodation is not so great as normal and the convergence is insufficient, so that a divergent position is assumed in fixing a near objeet. Although convergent squint in hyperopia, or divergent squint in myopia, is often enough prevented by the impulse for binocular fusion (or by the favorable anatomical conditions in the first case), there are, nevertheless, numerous examples of squint caused by refractive errors, the more naturally, of course, the less interest there is for binocular fusion. The question as to the cause of the squint is, therefore, in such cases—and they are the majority—completely answered.

There yet remains a minority of cases where refractive errors are not present, or where the form of squint does not correspond to them,—cases, for example, where hyperopia is associated with divergent, myopia with convergent squint. Rare cases of upward or downward squint are not of themselves necessarily due to refractive errors. For all such cases we assume that they depend either

[1] Reduced visual acuity in the squinting eye is so common as to be the rule. It depends either upon corneal opacities, lens opacities, astigmatism, or—in most cases—has no discoverable cause. Such an amblyopia is either the cause or the effect of the squint, or it may be both. Congenital amblyopia of one eye may as naturally induce squint as acquired amblyopia. Cases have been reported in which the deviating eye was at first normal, but became weak after some years. This is, of course, amblyopia ex anopsia (*p. 383*).

Digitized by Illinois College of Optometry

upon improper innervation, as convergent squint due to an habitually stronger innervation of one or both interni; or upon anatomical conditions, as a greater diameter of the internal or external rectus, and, perhaps, an insertion of the muscle closer to the cornea; or, finally, upon a restoration of normal physiological or anatomical relations.

The circumstance that many a squint disappears in sleep, during narcosis, or after death gives support to the assumption that concomitant squint may be caused by improper innervation of one or both interni. And since cases have been reported where the squint continued partially or entirely after death, we may likewise derive support for the assumption that such cases were due to anatomical causes.

Further examples of squint through nervous influences are found in those cases that begin reflexly as the result of conjunctival or corneal irritation. Moreover, cases of concomitant squint developing from paralytic squint (*p. 433*) are to be indirectly attributed to a nervous influence, since a muscle released from the counterbalance of its (paralyzed) antagonist takes a condition of indirect contraction.

3. TREATMENT.

Treatment must always, if possible, attack the cause. If the visual acuity of the deviating eye is weak, an attempt must be made to improve it. At times this can be done by neutralizing an astigmatism or by an iridectomy, or in amblyopia without cause by exercising that eye. Exercise of a weak eye is most easily accomplished by occasionally bandaging the other, but success may be expected only when this exercise is begun in early childhood.

In case a refractive error is the cause of squint, we have a remedy for it in neutralizing glasses, and we actually see many a manifest, convergent squint disappear after a few months' use of neutralizing lenses. If this result is not attained the treatment must be operative. Nevertheless, it must always be remembered that the convergent squint of children quite often heals of itself, either because the hyperopia becomes emmetropia or irrespective of it. The operation should, therefore, not be done before the seventh year, and only then if squint has existed some years and has defied treatment with glasses. In divergent squint a spontaneous cure does not take place.

The operations are:—

(1) Tenotomy of the muscle acting too powerfully;

(2) Advancement of the muscle acting too weakly;

(3) A combination of the two.

In convergent strabismus of slight to moderate degree—*3* to *7*

mm.—tenotomy of one or both interni may not only restore the correct position, but effect the normal mobility of the eyes. If the tendon of a rectus muscle is cut close to its insertion in the sclera it retracts only *3.5* to *5 mm.* and heals there; farther retraction is prevented by its peripheral attachments, that is, by the connective-tissue fibers that pass from the side of the muscle or tendon sheath to the eyeball and establish a loose connection with it. Obviously the adduction of the eye decreases by about the amount to which the tendon is set back. This does not signify the actual loss, since the adductive power was above normal, and the loss of adduction will, to a great extent, appear again in the gain of abduction. If the retraction of one internal rectus does not suffice, of course we may resort to the same operation on the healthy eye, for the association of the two muscles in the horizontal meridian has the effect of giving to the operation on the healthy eye the same result in the mutual position of the two as the same operation has on the deviating eye.

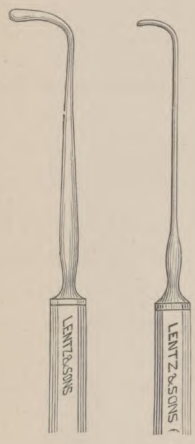

FIG. 155.

(*a*) Large, (*b*) Small strabismus hook.

In very pronounced squint even a double tenotomy will not suffice to reproduce the normal position. Under such circumstances the rectus internus must be severed and allowed to retract, and the rectus externus must be advanced, that is, sutured by its tendon closer to the cornea than the original insertion. It is advisable to perform the advancement of the externus about a week after the tenotomy of the internus, so that the latter will then have firmly healed; the simultaneous performance of both operations allows too much retraction of the tendon of the internus, and the loss of adduction is too great.

Tenotomy of Rectus Internus.—Instruments (*p. 347*): lid speculum, fixation forceps, dissection forceps without lock, blunt scissors curved on the flat, the so-called Louis' scissors, a large (*a*) and a small (*b*, *Fig. 155*) strabismus hook, needles and thread, cocain. Disinfection of physician, assistants, all instruments, and the field of operation.

The patient looks straight ahead, and an assistant, with the fixation forceps, seizes a fold of conjunctiva near the external corneal margin and rolls the eye gently outward. The surgeon, with the other forceps, seizes a parallel fold of conjunctiva in front on the insertion of the tendon [1] of the internus and cuts perpendicularly upon it. Then with

[1] The line of insertion of the internus is *10.3 mm.* long and *5.5 mm.* from the corneal margin; of the externus it is *9.2 mm.* long and *6.9 mm.* from the corneal margin (*Fig. 151*).

Digitized by the Internet Archive

short strokes of the scissors beneath the conjunctiva he undermines it in the direction of the nose. He thus uncovers the anterior end of the internus tendon. Next he passes the larger strabismus hook, held flat against the eye, beneath the tendon, draws it up slightly, and with the scissors severs it from the sclera. He now takes the small strabismus hook and carries it close behind the insertion of the tendon into the upper and lower corner of the wound, in order to find any remaining fibers that ought to be severed.

After the operation is finished the result is tested by comparing the loss of adduction (*p. 90*) with the predominance of adduction that was present before. If the loss of adduction is greater than was intended, the result may be reduced by taking a broad horizontal conjunctival suture. Since tendon and muscle are still connected with the conjunctiva farther back, such a conjunctival suture will draw forward the muscle which is too much retracted. If the result is insufficient, a second operation may be performed six weeks later.

A conjunctival suture may be needed if the sclera has been denuded. In case the suture is taken for such a purpose, the result of the operation will not be affected if the edges of the wound are seized very gently or if the suture is carried perpendicularly.

Advancement.—A severed tendon may be advanced by a broad and tightly drawn suture through the conjunctiva, and the new insertion of the tendon will lie nearer the corneal margin than the original insertion. Tenotomy can, therefore, be changed to an advancement by a proper conjunctival suture. As a rule, however, such a suture is not relied upon, but the tendon itself is sutured, close to the corneal margin, either to the conjunctiva remaining or to the sclera, through the upper layers of which the threads pass.

Recently many surgeons have preferred to advance "Tenon's capsule" instead of the muscle itself. This name is used to describe a connective-tissue sheath, in which the eye rests like the end of a bone in its capsule at a joint. This sheath is connected with the eyeball by loose and elastic connective-tissue strands; but near the cornea on the one hand, and near the entrance of the ciliary arteries and nerves at the posterior pole on the other hand, this connection becomes more intimate. The external surface of Tenon's capsule, that is, the surface from the eyeball, is continued into the connective-tissue envelope of the orbital fat. The eye muscles, therefore, are outside of the capsule, and their tendons must pierce it in order to reach the eyeball. They do not, however, pass through a smooth aperture, but are embraced posteriorly by a fold of this capsule, hence the expression, "peripheral attachments" (*p. 446*). To advance Tenon's capsule, Wecker excises a semilunar flap from the conjunctiva, in front of the insertion of the too weak muscle, *5 mm.* broad and *10 mm.* high. Then he cuts into Tenon's capsule, releases the muscle from its surrounding attachments without separating tendon from sclera, and advances Tenon's capsule to the corneal margin by means of two sutures that close the conjunctival wound at the same time.

Digitized by Harvard College of Dentistry

4. AFTER-TREATMENT AND RESULTS.

The operation for squint endeavors to reaccomplish normal, binocular single vision, that is, the fusion into one visual perception of the two retinal images formed of one external object. It can be tested by the stereoscope whether this fusion takes place, by showing parts of a figure to the right eye alone and other parts of the same figure to the left eye alone; for example, a horizontal line to the right eye and a perpendicular line to the left eye; if binocular fusion is accomplished the figure will appear as a cross. This result is, however, not always obtained. The position of the two eyes can, in the best cases, be made about right by one or more operations, but complete restoration of function depends upon the energy of the two eyes to respond to the impulse for binocular fusion. If the visual acuity of the eyes is unequal—as it is in most cases of squint—the prompting to such an effort is lacking and the result of the operation must be restricted to its cosmetic effect, beautifying the patient. That is usually about all she asks for.

For complete assurance of the success of the operation we must use methods by which a desire for binocular fusion may be aroused or encouraged. The best visual acuity possible must be obtained by spherical or cylindrical lenses, and exercise in fusion of retinal images must be supplied by a stereoscope. Supplementary aid may be given by favoring convergence if the position of the eyes is slightly divergent, or by favoring divergence if the eyes are slightly convergent. Convergence is encouraged by looking at near objects, by stimulating the accommodation with concave lenses, and by lowering the visual plane. Divergence is encouraged by resting the eyes, by relaxing accommodation with convex lenses, and by elevating the visual plane. Lasting success for an operation, no matter how successful it seemed at first, can be expected only when binocular fusion is completely reproduced. If binocular fusion is faulty it often happens that the squint returns after a year or more —the danger being that divergent squint will relapse into its original condition and that a convergent squint will relapse into the opposite condition and become divergent. It is best, therefore, in operating for convergent squint to do too little rather than too much, especially since a trifling convergence, say of *1 mm.*, is not displeasing, or certainly less displeasing than an equal amount of divergence. To complete and to retain the result of an operation, if binocular vision has always been lacking, one must often be

Digitized by Harvard College Library

content to encourage or to overcome convergence by any of the methods mentioned above.

III. LATENT STRABISMUS, WITH PARTICULAR REFERENCE TO DIVERGENT SQUINT.

By latent strabismus is understood a disturbance of the muscular equilibrium, which is suppressed for the sake of binocular single vision. There may be either convergent, divergent, upward, or downward squint. Latent divergent squint is by far the commonest. Occasionally divergence and convergence may be associated, convergence for distance and divergence for near. Three points must be satisfied to make the squint latent:—

(1) Both eyes must be placed correctly when they are used for looking at an object;

(2) One eye must deviate when it is excluded from vision by covering it;

(3) There must be no restriction of the muscular excursion.

Latent, and especially divergent squint, causes at first no symptoms, but as the deviation increases the symptoms of "muscular asthenopia" (*p. 368*) appear; they finally disappear in turn as latent squint becomes manifest.

Causes.—In some cases latent squint depends upon refractive errors (*p. 443*). Divergence is quite frequently the result of myopia. But latent divergent squint is no rarity in emmetropia or even in hyperopia. The reason for it may be found in a weakness of the recti interni, and many authors designate latent divergent squint as *insufficiency of the interni*. That weakness is actually present is seen by the increase of the latent squint when there are such conditions as physical exhaustion, lack of sleep, indulgence in alcohol, or illness of any kind, which reduce the tone and energy of the whole body. Whether this weakness is of the muscles, or of the nervous impulse to them, is a disputed point. That it is rather a nervous trouble is suggested by the fact that the internal recti still perform their function to the full extent of peripheral excursions.

Treatment.—Every latent squint does not cause symptoms. Very high degrees are occasionally found, which dwindle to very slight degrees when the fixation object is approached to the eye. In such cases treatment is unnecessary. But if latent squint and

Digitized by Illinois College of Optometry

symptoms of asthenopia (*p. 368*) exist side by side, it is unwise to conclude at once that there is any causal relationship between the two, but rather that asthenopic symptoms more commonly depend upon refractive errors than upon latent squint. If refractive errors, conjunctival (*p. 183*) and retinal asthenopia (*p. 307*) can be excluded, or if the connection between symptoms and squint are made undoubted by the nature of the patient's complaint (occasional diplopia, disappearance of distress when one eye is closed), then treatment should be tried by the prescription of suitable glasses. In the divergent squint of myopia the neutralizing concave lenses often suffice, since they demand accommodative effort and thereby increase the instinct to convergence, while they also admit of work at a greater distance, which implies a less claim on convergence. If this remedy is not sufficient, or if, on account of emmetropia or hyperopia, is not suitable, we must abandon the attempt to produce normal convergence, and resort to the use of prismatic lenses (*Fig. 33, p. 91*) in order to bring about binocular fusion with a relatively divergent position. For example, suppose an emmetrope has a latent divergent squint at the usual reading distance of *30 cm.*, and that this squint can be neutralized by a prism of *8°* base inward; then with glasses having a prism of *4°* on each side the patient will be enabled to read continuously, without effort at fusion, at *30 cm.* distance. If the patient wears glasses on account of myopia or hyperopia, a prismatic effect may be added to the lenses by giving them a greater or smaller distance apart than the pupillary interval calls for. Suppose a patient to have myopia of *4.0 D*, the neutralizing lenses of *4.0 D* will diminish the latent divergent squint, but will not altogether overcome it; but if the lenses are placed so far apart that the patient must look through the inner half of them, the effect becomes that of prisms in the position of abduction, the effect being greater the nearer he looks through the edge of the glass. It must be kept in mind, however, that the dispersing power of the edge of a lens is greater than that of the center. By testing with A. Graefe's equilibrium test (*p. 92*), the suitable distance for the glasses may be decided on.

It is hardly advisable to prescribe prismatic lenses stronger than *4°*, since the glasses are then too heavy and the chromatic aberration too strong. If the squint becomes more pronounced than corresponds to a prism of *8°*, an operation must be performed to allow the externus to retract by section of its tendon. If the muscle

retracts it obviously grows weaker and the question comes up whether the improved convergence for near objects may not have been obtained at the cost of diplopia when looking at distant objects on the side of the retracted muscle. The question may be answered as follows: In looking at distant objects, parallelism, but never divergence, of the visual axes is necessary; the capability for real divergence—facultative divergence—may, therefore, be sacrificed by retraction of one or both externi without causing any disadvantage to the patient. The capability for real divergence is measured by the strongest prism in the position of abduction (base toward the nose) with which binocular fusion can be maintained continuously and without effort. The approximate equality between facultative divergence for distant objects and insufficiency when looking at near objects (both being measured by prisms) gives a clue for the successful resort to tenotomy. For example, suppose that divergence equal to a prism of *16°* is possible for distant objects, and at reading distance an equilibrium with prism of *20°* in the position of abduction is established; we may, without further investigation, perform a tenotomy on one externus, since experience teaches that the final result of the operation is about equal to the action of a prism of *16°*. Parallelism of visual axes will then be possible for distant objects, while for near objects there will be a latent divergence of *4°*, which may be tolerated without any trouble, or can be corrected by prismatic glasses of *2°* on each eye.

If the conditions are less favorable, that is, if the facultative divergence is small, or at least smaller than the insufficiency for near objects, it is better to advance an internus without performing tenotomy of the externus at the same time. There is thus no loss but rather a gain in the range of movement.

The operation itself is very simple, but success may be difficult to achieve because the difference between the immediate and final results of the operation varies greatly in individuals. The most important data for judging of the condition immediately after the operation are:—

(1) The amount of restriction of movement, and

(2) Equilibrium in the "position of election."

This term was used by v. Graefe to describe the direction of vision *15°* toward the side of the eye not tenotomized, and *15°* below the horizon. At this position, and with the fixation point at least *3 m.* distant, equilibrium will be maintained immediately after

Digitized by Illinois College of Optometry

the operation, that is, there will be neither convergent nor divergent squint. The restriction of movement in the tenotomized eye should amount to *3* or at most *6.5 mm.*, according to the amount of facultative divergence; a greater restriction would require a conjunctival suture to overcome the result proportionately.

The final outcome of the operation for latent squint is better than it is in that for concomitant squint, because the desire for binocular single vision is present in latent squint and acts as an important factor in reëstablishing the normal muscular relations.

[**Heterophoria.**—By reading the two preceding sections and the paragraphs on the methods of examination (*p. 92*), it will be seen that the condition of squint is closely allied to heterophoria, and that the latter may pass, by nearly imperceptible gradations, into the former. There is, however, one distinction that must be carefully made: Squint may always be detected objectively by the observer, and it sometimes annoys the patient by the production of diplopia, although in concomitant squint he easily neglects the image in one eye; but heterophoria can never be detected objectively, the patient is never aware of diplopia, and there is no suppression of the image in either eye. Squint is, therefore, a condition often detected by the patient, heterophoria a condition diagnosticated only by the ophthalmologist.

The causes of heterophoria are the same as those given for latent squint (*p. 449*), although the tendency of the visual lines may be either outward (exophoria), or inward (esophoria), or upward and downward (hyperphoria).

Some confusion may arise by finding heterophoria of one kind for near work, and of another kind for far work; but it is best to treat only that kind causing the greater trouble. In *exophoria* headache and eye-strain are most intense after near work, but the power of accommodation may be increased. The ability to overcome adducting prisms varies, but is usually quite pronounced. In *esophoria*, headache and eye-strain are most apt to appear after excessive use of the eyes in distant work, such as visits to the theater or picture gallery, and after long rides in the cars; the power of accommodation may be lessened, while the ability to overcome abducting prisms is usually pronounced. In *hyperphoria*, all sorts of conditions may be present, and the statements of the patient may be unsatisfactory and confusing. There is here more amblyopia, however, and more muscular or nervous irritation manifested by

spasm of lids, twitching of facial muscles, neuralgia, and lacrimation; while the ability to overcome a prism (base either up or down) is sure to be increased.

Treatment naturally divides itself into—

(1) *General*,

(2) *Optical*, and

(3) *Operative*.

(*1*) Every element which may impair visual acuity or keep the patient's health below par must be persistently combated. Rest to the eyes, atropin, electricity locally applied, change of occupation and surroundings,—all have their place.

(*2*) Optical treatment implies more than the correction of refractive errors, which must, of course, be the initial therapeutic measure, although it not infrequently happens that the symptoms of heterophoria disappear after the eyes have been relieved of the strain from ametropia. Should these symptoms continue, the use of prisms should be immediately tried; prisms may be prescribed either to be worn constantly, or to be used as a means of exercise. In the former case, the desired result may be obtained either by adding the prismatic effect to correcting lenses by decentering, or by adding an actual prismatic form to the lenses prescribed. In the latter case, the patient is treated by graduated prismatic exercise at the physician's office, or he is given prisms of increasing power which he can use at home to develop the weak muscle by strengthening the impulse to overcome them. "There can be no doubt that ample experience has shown the helpfulness of weak (1° to 5°) prisms continuously worn for moderate degrees of muscular error, and this method should precede the use of gymnastic prisms or of the various other palliative measures. In giving prisms, the rule may be formulated that the base should be placed toward the image whose position is to be corrected; this corresponds to the weak muscle, provided the physiological or functional activity of the muscle is regarded. The apex of the prism like a knife edge indicates the muscle which should be weakened, and the base denotes the muscle to be strengthened" (Noyes). But in no individual case can an inflexible rule be applied. For a weakness of adduction (exophoria) prisms (base in) would seem *a priori* to be indicated, but the expected result is not always obtained, while in rare cases the very opposite prismatic effect (base out) has given relief. The same may be said of weakness of

Digitized by Illinois College of Optometry

abduction (esophoria); prisms (base out) are indicated, but do not always relieve, while the opposite prismatic effect (base in) ameliorates the distress. It is probable that when such contradictory results are obtained there will be found exophoria for distant, and esophoria for near work, and that the relief is experienced because the patient really uses his eyes most in the position for which the prisms meet the indication according to the rule. Every case, therefore, must be treated on its merits, and neither examination nor treatment can be said to be complete until every possible variation in the working power of the muscles has been thoroughly tested.

(3) Operative treatment consists of the mechanical (surgical) weakening of the over-strong muscle by a tenotomy. Such an operation may be total, the same as is performed for strabismus (*p. 446*), or a graduated tenotomy, in which the effort is made to restore equilibrium by section of a few fibers at the insertion of the tendon. A tenotomy for heterophoria does give, in selected cases, the most brilliant results, but the surgeon should always remember that operative interference is the treatment of last resort, not to be undertaken till all other means have failed; that however favorable the momentary results may be, there is apt to follow them a distressing diplopia due to weakness of the muscle which was originally too strong; and that he must be ready, at the time of operating, to control his tenotomy, either by a conjunctival suture (*p. 447*), or by a supplementary tenotomy of the muscle which becomes over-active after the primary tenotomy. For these reasons it is wise for him to adhere to the following rules: always operate with a local anesthetic only (cocain); sever the tendon at its scleral attachment, rather than the muscular fibers; divide the total result wished for between the two eyes, so that a muscle of each eye bears only half the correction; make repeated examinations during the operation to see when the heterophoria has disappeared; and be ready to correct an exaggerated result at once, by a conjunctival suture, remembering that too radical an operation may have the opposite effect to that which he seeks to correct, while it is always easier to repeat the first operation on the same muscle than to perform a second operation on its antagonist.—H.]

Digitized by Illinois College of Optometry

IV. NYSTAGMUS.

Spasmodic, involuntary, jerking movements of the eyes, which do not interfere with, but accompany, the normal, voluntary movements of the eyes, are termed nystagmus. Three forms are distinguished according to the direction of this twitching :—

(*a*) *Nystagmus oscillatorius*, twitching to the right and left, horizontally, or upward and downward, perpendicularly ;

(*b*) *Nystagmus mixtus*, oblique twitching ;

(*c*) *Nystagmus rotatorius*, rotations about the visual axis. These may be quite distinct, or in combination with horizontal, perpendicular, or oblique twitchings, so as to produce directions of movement which, in contradistinction to (*a*) and (*b*) are in no sense physiological.

There is often squint along with nystagmus. Often, too, there is noticeable a moderate shaking of the head in the same direction and with uniform speed with the nystagmus. This shaking of the head has been held to be a compensatory movement for the nystagmus, although a compensation for an eye movement to the right by an equally strong head movement to the left cannot be demonstrated in individual cases, on account of the rapidity with which they are made.

In certain diseases nystagmus changes remarkably both in rapidity and character of the movements ; if the patient knows he is closely watched, or if he labors under any excitement, the phenomena are increased, while during sleep or narcosis they are lessened or altogether stopped. Many patients can themselves inhibit the movements by taking some definite position for their eyes, say a pronounced convergence. Many healthy patients can voluntarily produce a nystagmus. This disorder may be divided into three classes according to the causes :—

(*a*) **Nystagmus from Weak Sight in Both Eyes.**—This is the commonest form. It begins in early childhood as the result of corneal or lens opacities, or of astigmatism, of microphthalmos, of amblyopia without cause. Such pathological conditions cannot be a matter of indifference for position and movement of the eyes in early childhood, since an exact binocular fusion must be of decided significance in the development of normal eye movements. This amblyopia does not, however, explain the nystagmus completely, since there are cases of nystagmus without amblyopia, and cases of

Digitized by the College of Optometry

bilateral amblyopia without nystagmus. There must be some factor which influences the eye muscles themselves; an indication for this is found in the fact that at one time the external and internal recti muscles, and at another time the elevator and depressor muscles, are to be blamed for the nystagmus; while another fact must be noticed, namely, that certain visual directions are, by means of corresponding movements of the head, preferably used by the patient, because all other directions are more difficult for him.

This first form of nystagmus causes no trouble, and especially no apparent movement of the object looked at; therefore no treatment is needed unless it be to improve the visual acuity.

(*b*) **Nystagmus of miners** comes in paroxysms, and is accompanied by apparent movement of the object looked at, and by vertigo. These paroxysms are caused by exhaustion from trying to see in an insufficiently lighted space (coal shaft), and from uncomfortable positions of the eyes like exaggerated elevation, less often exaggerated depression of the visual plane.

The disease is to be considered as a paresis of the levator muscles due to overstimulation, so that they contract only spasmodically. This paresis is favored by everything that tends to make work for the eyes under such circumstances difficult, such as poor vision, insufficiency of the interni, or physical prostration.

The character of eye movement in miners' nystagmus is usually a circular or elliptical rotation. This may be demonstrated by means of a "reflection test:" a luminous point in a dark room will appear to the patient during an attack as a circle or an ellipse, for the same reason that a luminous point rapidly revolved appears as a circle to the healthy person. The distress is often so great that the patient must abandon his vocation. A successful **treatment**, apart from simple rest, has not yet been devised.

(*c*) **Nystagmus from brain disease** has only symptomatic significance. It is of especial importance in the diagnosis of multiple sclerosis, that cerebro-spinal disease characterized by the appearance of numerous gray, fibrillary connective-tissue foci in brain and cord. The three important signs of this disease are:—

(1) "Intention trembling"—appearing during voluntary, intentional movements;

(2) "Scanning speech;"

(3) Nystagmus, which may be analogous to intention trembling, since it sets in during fixation and during intentional eye movements.

Digitized by the Internet Archive in 2010 with funding from University of California

DISEASES OF THE ORBIT.

INTRODUCTION.

In most cases of diseases of the orbit there is *exophthalmos*. This term implies a protrusion of the eyeball outside its natural position in the orbit. This depends upon a restriction in the space within, either because the eye is too large for the orbit, as the "pop-eye" of myopia (*p. 369*), or because the otherwise normal contents of the orbit has increased, such as the fat tissue in general adiposity, and the quantity of blood if the vessels are dilated, or because bloody, serous or purulent exudations crowd the eyeball forward.

The opposite of exophthalmos, retraction of the eye within the orbit, *enophthalmos*, is at times observed. It depends upon absorption of the orbital fat or upon decrease in blood contents of the orbital vessels, or upon great loss of fluid from the body resulting from intense purging, as in cholera.

It is not quite clear to me how enophthalmos depends upon disappearance of the orbital fat. We often see old persons who have grown so thin and "hollow-eyed" that the finger can be pushed in deep between the eyeball and wall of the orbit, but notwithstanding all this, there is no trace of enophthalmos! As the eyeball lies in the orbit, the fat is only a filling, while the connective tissue is the net in which the eye is suspended.

To measure the amount of exophthalmos H. Cohn and others have devised special instruments. The exophthalmometer has not become popular, because the position of the eyeball changes within physiological limits so markedly that a statement that the corneal apex is so many millimeters in front of a certain point on the edge of the orbit cannot be taken to mean that a pathological degree of exophthalmos is present. A comparison between the two eyes is of more value. This is obtained by measuring how many millimeters the corneal apex of each eye lies behind the same point, say the bridge of the nose. There may be differences here, of course, depending upon asymmetry of the cranium, and these would have no pathological significance. As a rule, a simple guess will answer. It must be remembered, however, that a wide palpebral fissure may simulate exophthalmos, a narrow fissure or a moderate ptosis may simulate enophthalmos.

Digitized by Harvard College Library

1. INJURIES.

(*a*) Injury by a blunt weapon may cause a fracture of the bony wall of the orbit. On account of the concealed position of the bones of the orbit, the well-known signs of fracture—abnormal motility, pain on pressure, crepitation—can be made out only in exceptional cases. As a rule we must be content with the history of the case and the demonstration of the presence of blood in the orbital cavity. This will be evidenced by exophthalmos and, perhaps, by subsequent subconjunctival and palbebral hemorrhage (*p. 146*). The diagnosis is established when the fracture is associated with one of an adjacent air space (the nasal, temporal sinus or the antrum of Highmore), which produces an emphysema of the conjunctiva and lids, or when the injury to the orbit leads to nasal hemorrhage; in this latter case we may conclude that the fracture involves the median wall of the orbit. Injuries by a blunt weapon not infrequently result in inflammation of the bone or periosteum. This is especially the case in scrofulous or syphilitic individuals.

Fractures of the orbital wall may be occasioned without direct contact of the weapon, as from a fall upon the back of the head, for example. In such cases life is so endangered by other injuries, such as fractures at the base of the skull, that the effect on the eye becomes subordinate.

Quite exceptionally enophthalmos instead of exophthalmos results from injury to the orbit. This "enophthalmos traumaticus" is explained in various ways. It seems to me most probable that the cause is to be sought for in a laceration or rupture of connective-tissue fibers that pass from Tenon's capsule to different points of the orbit, and act as suspensory ligaments of the eyeball.

(*b*) Injury by a penetrating weapon always leads to more or less laceration of the soft parts. The most common objects causing injury are pitchforks, the horns of cattle, umbrellas, canes, knives, and shot of all kinds. In many cases the diagnosis is established by finding adipose tissue exposed in a conjunctival wound. In other cases the injury may be diagnosticated from the nature and extent of the disturbance of eye movement. The character of the weapon causing the injury must be considered in deciding whether it has remained wholly or in part within the wound. To avoid error, it is best to introduce the point of the finger between eye and orbital wall, and to explore the whole orbit. If touch reveals nothing, the wound should be sounded, but with most careful anti-

Digitized by Illinois College of Optometry

sepsis. If the foreign body has carried any germs with it, there is inflammation, suppuration, and orbital abscess to be feared.

Treatment.—Injuries by a blunt weapon are to be treated by rest and cooling compresses. The wound must be disinfected and bandaged. All foreign bodies must be removed. Since they often lodge in the bony wall of the orbit, the extraction sometimes demands the use of strong forceps, but in case the foreign body lies at the roof of the orbit, the proximity of the brain should never be forgotten. Small aseptic foreign bodies, like shot, usually heal encapsulated; they should not, therefore, be removed without good reasons for it.

(*c*) **Luxatio Bulbi.**—If a wedge-shaped foreign body, the thumb, for example, is crowded between eyeball and external wall of the orbit, it can, by using the external wall as fulcrum, squeeze the eyeball out of its bed. In parts of Bavaria and America (Virginia, among the negroes) this device is resorted to by contestants to render the opponent incapable of fighting. In Uganda, in Central Africa, masters make their slaves one-eyed in this way, the one-eyed appearance serving as a livery. After the luxation the eye lies in front of the orbit, and the lids are closed in a spasm behind it. The muscles are somewhat lacerated, and stretched so much that eye movements are impossible. Vision is lost, either directly through stretching of the optic nerve, or through the anemia caused by this stretching. **Treatment** consists in reposition and bandage. Vision may return.

2. INFLAMMATIONS.

(*a*) **Periostitis Orbitæ.**—The disease attacks scrofulous children and syphilitics, in preference. A blow or a fall upon the edge of the orbit is usually the exciting cause. Since the upper outer and the lower outer edges are most exposed to injuries, these points are most commonly the seat of the inflammation. The disease begins with a dull pain increased by pressure upon a certain spot of the orbital edge. A swelling is gradually developed, which is painful, immovable, and strikingly hard. The skin covering the swelling is red and edematous. A small portion of the swelling now becomes soft and fluctuates, and with perforation there is an escape of thin, watery, foul-smelling pus. If a sound is introduced into the fistula, it strikes rough bone,—caries. Foul-smelling pus

Digitized by Illinois College of Optometry

is continuously poured out of the fistula till, after months or years, all necrosed bone is expelled. Cicatrization of the fistula involving the skin, generally that of the lid, follows. Ectropion and its consequences result (*p. 163*).

Treatment must be antiphlogistic at the beginning. Leeches to the temple (not on the lid, see *p. 146*) and cold compresses may help to "scatter" the inflammation. This expectation is not unwarranted, and the treatment may succeed if the periostitis is syphilitic, and is subsequently treated with mercury and iodids. If suppuration is unavoidable, however, the treatment should be with heat, incision, and drainage—proper surgical methods.

(*b*) **Orbital Abscess.**—This distinct form of the disease may develop from a periostitis if the wall of the orbit instead of its edge is involved. With the pain there is then fever, general prostration, swelling, and redness of the lids, particularly the upper one, ptosis, chemosis of the conjunctiva bulbi, exophthalmos, restriction in eye movement, dilatation of the pupil, and visual disturbance. The patient has an appearance that suggests a blennorrhea (*p. 188*) or a panophthalmitis (*p. 296*). The lack of discharge from the conjunctiva excludes blennorrhea positively. The unimpaired or relatively normal condition of the interior of the eye (to the ophthalmoscope) is against the diagnosis of panophthalmitis. The pus spreading in the cellular tissue of the orbit, with an increase in all the symptoms, gradually makes its way to the surface and finds an opening either into the conjunctival sac or upon the lids. As soon as the pus escapes the patient obtains relief, but it takes a long time before the normal condition is restored. An unfavorable result is obviously not excluded, since optic neuritis, sloughing of the cornea and even of the whole eye may cause blindness, or if the inflammation reaches the brain, it may end in death.

Not only periostitis orbitæ, but also any suppurative or even inflammatory process in the vicinity of the eye, may lead to abscess within the orbit. As examples we have empyema of the orbit, septic thrombosis of a cranial sinus from caries of the inner ear, ulcers of the nose, furuncle and erysipelas of the face, and inflammations about the roots of the teeth.

A third group is the metastatic orbital abscess, traceable to infection of the general system by glanders, anthrax, or to pyemia. In the second and third group there is usually a number of small abscesses scattered along the orbital veins.

Digitized by Illinois College of Optometry

The fourth and largest group embraces those cases in which the pus-causing germs have been introduced on the weapon or foreign body producing the injury, and in preantiseptic times on the surgeon's instruments, as in squint operations. In some cases it is impossible to discover a direct cause.

The prognosis depends upon the cause. Metastatic orbital abscesses generally lead to death. In periostitis of the roof of the orbit there is always danger of perforation into the cranial cavity, since the bone in this region is as thin as paper. In other cases the prognosis is favorable.

Treatment consists in finding the spot where perforation is to be expected and then in incision and drainage. As a rule an incision must be made before periostitis can be demonstrated by probing for bare bone.

3. DISTURBANCES OF THE CIRCULATION.

(*a*) Pulsating Exophthalmos.—

The internal carotid artery, after passing from the carotid canal in the temporal bone and running by the side of the body of the sphenoid, enters the cavernous sinus, a venous space in the substance of the dura divided by fibrous cords into many compartments (*Fig. 156*). The artery lies on the wall of this sinus and half of its own bulk protrudes unprotected into the lumen of the sinus. If the carotid should be lacerated at this spot the result would be a flow of blood into the sinus and spaces connected with it; that is, an aneurisma arterio-venosum would be produced.

The most important connections of the sinus are with the brain and orbit. Since the cerebral veins are prevented from any noticeable expansion by the already well-filled membranes of the brain, the effect of an arterial hemorrhage into the cavernous sinus makes itself felt in the ophthalmic veins and its branches, producing a pathological picture called *pulsating exophthalmos*. The nerves of the orbits (abducens, oculomotorius, trochlearis, and ramus ophthalmicus of the trigeminus) also suffer, since they pass in part through the cavernous sinus (*Fig. 156*), in part above it.

Pulsating exophthalmos has the following signs: There is exophthalmos, usually with displacement of the eye downward, presumably because the vena ophthalmica inferior does not enter the cavernous sinus, or because of its connections with the veins in the sphenoidal fissure (*Fig. 157*) it is not affected by the stasis. The lids are red, swollen, and marked by dilated veins coming from the vicinity of the eye,—there is ptosis. The conjunctiva is very chemotic and marked by strongly dilated veins. The cornea is

Digitized by the Osteopathic College of Chiropractic

normal or faintly cloudy, and its sensitiveness is reduced. The pupil is dilated and rigid or at least sluggish.

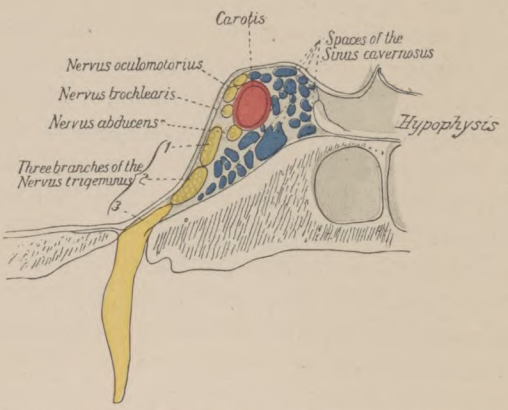

FIG. 156.—FRONTAL SECTION THROUGH THE SINUS CAVERNOSUS. (*After Merkel, drawn by L. Schroeter.*)

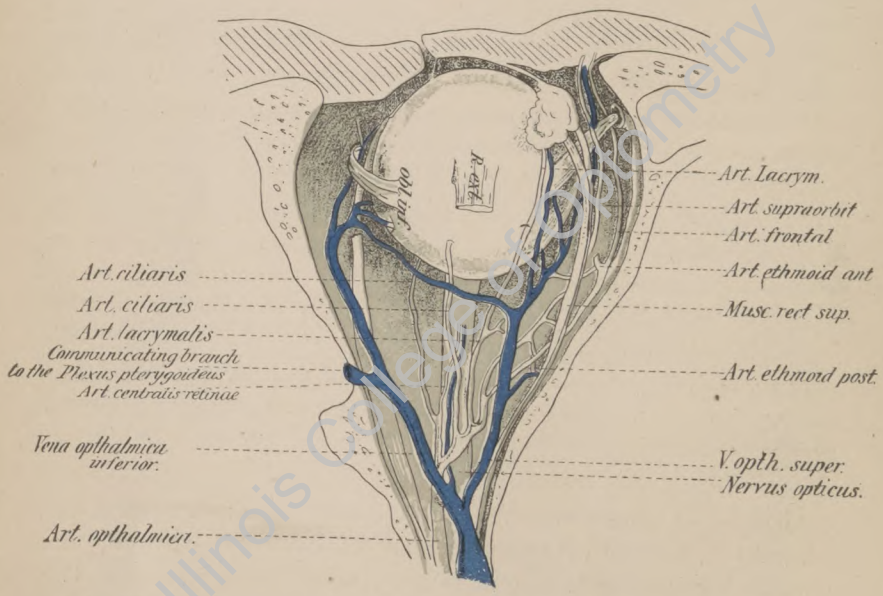

FIG. 157.—THE VEINS OF THE ORBITAL CAVITY. (*After Merkel, drawn by L. Schroeter.*)

If a finger is placed on the protruding eyeball, there is felt a pulsation and at times a thrill with every heart beat. Near the eye there may be a pulsating tumor. A moderate pressure suffices to

Digitized by Illinois College of Optometry

replace the eye within the orbit, but on removing the finger the former condition at once reappears.

The third diagnostic sign is discovered by means of auscultation on the eye, the forehead, or the temple. With the pulse there is also heard a vesicular murmur that fades away to a faint sigh during the diastole of the heart.

The ophthalmoscope shows a thinness of the retinal arteries, great dilatation and varicosity of the veins; and choked disc in many instances. In spite of these changes visual acuity may be normal, but it is often reduced or obliterated. The patient complains of pain in the orbit, forehead, and temple, changing in severity, and of subjective noises that may be so loud as to affect hearing and prevent sleep. Compression of the common carotid in the neck may stop the symptoms at once, but, of course, only so long as compression is maintained.

What can cause a rupture of the internal carotid within the cavernous sinus?

(*1*) An injury, either direct, as a puncture through the orbit, or a penetrating shot; or indirect, as a fracture at the base of the brain;

(*2*) Disease of the arterial wall (arterio-sclerosis, syphilis), which yields to an accidental rise in blood pressure produced by movement, cough, or the like.

The prognosis is doubtful. The eye may be blinded by keratitis neuroparalytica (*p. 238*), keratitis e lagophthalmo, or by neuroretinitis or ischemia retinæ. Life may be endangered by severe and repeated nasal hemorrhages, or by further changes in the brain. The perforation in the carotid may, however, be blocked by a thrombus and healing result.

Treatment.—What happens spontaneously in favorable cases—thrombosis of the cavernous sinus—must be produced if possible by treatment:—

(*1*) Reduction of blood pressure in the internal carotid by quiet living, rest in bed, restricted diet, and avoidance of liquids;

(*2*) Interference with the circulation by

(*a*) Compression, or

(*b*) Ligation of the common carotid.

In many cases, particularly in those resulting without injury, regulation of life, combined with compression, will bring about a cure. If the cause was an injury, ligation of the common carotid must be resorted to.

Digitized by Illinois College of Optometry

(*b*) **Thrombosis of the Ophthalmic Vein** is not a disease but a symptom. There are septic and marasmatic thromboses. Septic thromboses belong or rather lead to the condition of orbital abscess (*p. 460*). The marasmatic thromboses are but symptoms of a sinus thrombosis, which is characterized by coagulation of blood within the cerebral sinuses extending outward from the brain through the veins leading to it, or producing symptoms of stasis in the territory of these veins. Stasis in the territory of the ophthalmic vein may arise from sinus thrombosis, and this may be assumed if other symptoms are present as well, such as general marasmus of the patient, disturbance of cerebral functions, bilateral appearance of the eye symptoms, and edema behind the ear. The disposition to this bilateral involvement depends upon the fact that both sinuses are connected by oblique passages, and that consequently a clot in one sinus can easily spread into the other. The involvement of the region of the mastoid depends upon the fact that the mastoid vein leads to the descending arm of the transverse sinus, which is in direct connection with the cavernous sinus. Sinus thrombosis always leads to death.

(*c*) **Exophthalmic Goiter, Basedow's Disease, Grave's Disease.**—This must be briefly mentioned here, since, although it is not an essential disease of the eyes, it has noticeable eye symptoms of importance to the diagnosis, which often lead the patient to consult the ophthalmologist first. The disease has three principal signs:—

(*1*) Rapid pulse;

(*2*) Enlargement of the thyroid gland;

(*3*) Bilateral exophthalmos.

The pulse beats 100 or more to the minute in full bodily and mental repose, while the least physical exertion or mental excitement may raise it to 140 and beyond. The large vessels in the neck are dilated and have a pulsation that is quite noticeable in comparison to the weak radial pulse. The area of heart dulness is increased, the apex beat is stronger and labored.

The thyroid gland is moderately enlarged, soft, has a visible and palpable pulsation, and shows a systolic murmur on auscultation. This may all be taken as evidence that enlargement depends chiefly upon dilatation of the blood-vessels rather than upon hyperplasia of tissue.

The exophthalmos varies, not only in different cases, but at times in the same patient. The eyes may be pressed back into the orbits by gentle pressure, an evidence that the cause of the exophthalmos is a dilatation of the blood-vessels in the orbit. Even where the exophthalmos is not remarkable there is a decided expansion of the palpebral fissure, and winking is incomplete and infrequent, a condition due to lessened reflex sensitiveness of the cornea and conjunctiva—*Stellwag's symptom.* In looking downward the upper

Digitized by Illinois College of Optometry

lid does not, as it normally should, descend, but lags behind and the " white of the eye " becomes, therefore, visible above the cornea, giving the patient a peculiar appearance—*v. Graefe's symptom.* The incompleteness of closure of the lid causes complaints and such danger as comes from irritation or inflammation of cornea or conjunctiva. The exophthalmos makes convergence difficult; in one of my cases this was the only reason the patient gave for coming to a physician. In high degrees of exophthalmos there is lagophthalmos (*p. 160*), and at times there are disturbances of lacrimal secretion, it being either too much or too little. Besides the symptoms in heart, neck, and eye there are numerous other disturbances of the nervous and digestive systems which are discussed in the text-books of internal medicine.

The nature of the disease we may, with Friedreich and Sattler, assume to be an injury to certain closely approximate nerve centers, particularly the vagus nucleus (heart), the vasomotor centers controlling the blood-vessels of neck and head, and, finally, the centers for the coördination between looking downward and closing the lids, and for reflex lid movements. These centers can be located in the gray matter of the third and fourth ventricles. The nature of the change in these centers is not yet known. The causes of the disease are as little known. It has been noticed that excision of the thyroid gland, or even the production of artificial atrophy by ligation of its arteries, may either cure or, to some extent, improve this disease. On this fact is based the theory that the cause of the disease is to be found in a pathological secretion of the thyroid, a kind of autoinfection. The whole matter is still very obscure, but, according to this theory, the involvement of the thyroid is the first phenomenon, everything else being results of it.

The prognosis is doubtful. The majority of cases recover after an illness of years. This is particularly true of women, who are also more frequently attacked than men. In men, especially in advanced life, the prognosis is unfavorable, since the disease not infrequently leads to death from exhaustion. An acute course of the disease has been observed, ending in either cure or death.

Treatment consists in good physical nourishment, mental calm, life in the country or at a sanitarium. This is not the ophthalmic surgeon's province; he has to do only with the affections of the cornea and conjunctiva, with the exophthalmos or lagophthalmos,

Digitized by Google

and with the muscular asthenopia, to the sections on which the student is referred.

4. TUMORS.

Every appreciable tumor of the orbit must cause an exophthalmos, and the direction in which the eye is displaced depends upon the seat of the tumor.

A second symptom is disturbance of motility, either because the tumor prevents eye movements mechanically, or because muscles and nerves are matted together and thereby prevented from functionating. Both conditions may, of course, occur simultaneously.

A third symptom is disturbance of vision; not always present, however. When present, it is due to pressure upon or involvement of the optic nerve, or to retinal or choroidal disease.

A fourth symptom is pain. If lacking, it implies benignancy of the tumor; if present, either benignancy or malignancy.

Although these four signs support the diagnosis of a tumor, this is not established until the tumor itself is demonstrable to the touch.

Tumors of all kinds have been observed. The most usual will be mentioned here. Tumors of the lacrimal gland are described on *p. 169*.

(*a*) **Tumors of the Orbital Wall.**

Osteoma is a lumpy, bony growth of ivory hardness. As a rule it arises from the roof of the orbit. The development is slow and painless. The diagnosis may be made from its hardness, immobility, and connection with the orbital wall. Syphilis has been assumed as cause in some cases. The prognosis is favorable, as far as life is concerned, even if the growth extends into the orbital cavity. The eyeball may be rendered useless by exophthalmos or lagophthalmos. **Treatment** consists in inunctions of mercury, etc., if syphilis is the cause. Extirpation is admissible, according to Berlin, only when the roof of the orbit—separating orbit from brain—is not involved. If removal is out of the question enucleation of the unavoidably useless eye will save the patient much distress.

Encephalocele, brain hernia, is a prolapse of dura through some congenital aperture between ethmoid and frontal bones, or through any congenital aperture in the orbital roof. This sac contains fluid or brain matter and forms a tumor lying, as a rule, at the inner upper angle of the orbit. The diagnosis is confirmed if the tumor can be dispelled by pressure, while at the same time symptoms of pressure on the brain, such as rolling the eyes and other spasms, are produced. Such a pathological condition leads sooner or later to death. If life is still maintained with such a tumor, nothing can be done to remove it.

(*b*) **Tumors of the Optic Nerve.**

Myxoma or *myxosarcoma* is a jelly-like tumor about a pigeon's or hen's egg in size. The diagnosis rests on a slowly increasing exophthalmos, relatively little disturbance of motility (because the tumor is within the funnel of the muscles), early blindness from

papillitis or optic nerve atrophy, and the discovery of a tumor near the optic nerve by introducing the finger between eyeball and orbital wall.

These tumors are benign and even after incomplete removal are not given to local relapses. **Treatment** consists in removal, with retention of eyeball, if possible. The best method of operation is Krönlein's osteoplasty—sawing through and turning back the temporal wall of the orbit. This permits full view of the space behind the eyeball, so that the tumor can be shelled out, after which the dislodged wall of the orbit is carefully replaced.

(*c*) **Tumors of the Cellular Tissue.**

These are cysts, sarcomata, and vascular tumors.

Among the *cysts*, dermoid and echinococcus vesicles are relatively the most common. Dermoid cysts are always congenital, and are, therefore, usually observed on children. Their contents are fluid or gelatinous; the presence of hairs, teeth, and other structures springing from the epidermic layer, proves that the condition is one in which the external skin has been turned in and subsequently incarcerated. The diagnosis of a cyst rests upon the evidence of an orbital tumor and fluctuation.

Echinococcus cyst is distinguished from the dermoid only by the fact that the former is not congenital, grows faster, causes pain, and endangers the eye.

Treatment consists in extirpation.

Vascular tumors are telangiectasia, cavernous angiomata, and aneurysms.

Telangiectasia of the orbit is the same as a "birth mark" on skin or lid (*p. 167*).

The *cavernous angioma* lies within the funnel of the muscles, and therefore does little damage to eye movements. The essential sign of it—apart from those characterizing all tumors—is the changing increase and decrease in size, noticed continuously or produced at will, by bending forward, for example, or by forced expiration; in short, by anything that retards the return of blood from the head. The exophthalmos accompanying it can be overcome by pressure on the eyeball. Prognosis is good so far as concerns life, but doubtful for the eye. However long the tumor may take in growing, the result is sure to be pressure atrophy of the optic nerve, or inflammation of the eye. **Treatment** must be extirpation.

Aneurysms have the above symptoms with the addition of pulsation. If they are quite large, they may produce the picture of pulsating exophthalmos. In such a case the same treatment is advisable (*p. 463*).

Sarcomata are usually within the eyeball (*p. 297*) or on its anterior surface (*p. 218*), and have therefore been already mentioned; a genuine orbital sarcoma is a great rarity. Its malignancy is betrayed by its rapid growth, pain, and early effect upon health. There is, besides, a disturbance quite out of proportion to the size of the tumor, due, of course, to involvement of the muscles within the growth; an innocent tumor merely pushes the muscles to one side and, therefore, affects movement only mechanically. The prognosis is bad,—the more unfavorable the younger the patient and the richer in cells the tumor is.

Treatment consists in evisceration of the orbit, exenteratio orbitæ; the operation is performed as follows: the external canthus is split and the lids drawn as widely apart as possible, in order to get space. A knife is then passed around the entire bony circumference of the orbit, and the orbital periosteum, beginning at the wound, is loosened by raspatorium or chisel; this is continued until the entire periosteum with all its contents is separated from the bony wall, being left adherent only at the apex of the orbit. A scissors curved on the flat is then introduced, and the stump of this mass of tissue is cut off close to the bone. Hemorrhage from the ophthalmic artery is best stopped by the actual cautery. If the lids are involved in the growth, the first incision should be carried beyond it into healthy skin, and lids removed with orbital contents.

Digitized by the Internet Archive in 2010 with funding from College of Optometry

Carl E. Ganz Memorial Library
Illinois College of Optometry

Digitized by Illinois College of Optometry

APPENDIX A.

ABBREVIATIONS USED IN OPHTHALMOLOGY.

(*Gould's Illustrated Dictionary, page x.*)

Acc. . . Accommodation.
Ah. . . Hyperopic Astigmatism.
Am. . . Myopic Astigmatism.
As. . . Astigmatism.
Ax. Axis.
B. D. . . Base (of prism) down.
B. I. . . " " " in.
B. O. . . " " " out.
B. U. . . " " " up.
cm. . . Centimeter.
Cyl. . . Cylinder, Cylindric Lens.
D. . . . Diopter.
E. . . . Emmetropia, Emmetropic.
F. . . . Formula.
H. . . . Hyperopia, Hyperopic, Horizontal.
L. D. . . Light Difference.
L. E. . . Left Eye.
L. M. . Light Minimum.
M. . . . Myopia, Myopic.
m. . . . Meter.
mm. . . Millimeter.
O. D. . . Oculus dexter—Right Eye.
O. S. . . Oculus sinister—Left Eye.
O. U. . . Oculi utrique—Both Eyes.
P. p. . . Punctum proximum, Near Point.
P. r. . . Punctum remotum, Far Point.
R. E. . . Right Eye.
Sph. . . Spheric, Spheric Lens.
Sym. . . Symmetric.
V. . . . Vision, Visual Acuity, Vertical.
+, —, = Plus, Minus, Equal to.
∞ . . . Infinity, 20 ft. distance.
⌒ . . . Combined with.
° . . . . Degree.

FIG. 158.—A. Centimeters. B. Inches.

Digitized by Illinois College of Optometry

TABLE FOR CONVERTING METRIC WEIGHTS INTO TROY (APOTHECARIES') WEIGHTS.

(*Gould's Illustrated Dictionary.*)

Grams.	Exact Equivalents in Grains.	Approximate Equivalents in Troy Weights.			
		Ounces.	Drams.	Scruples.	Grains.
0.01	0.1543	. .	. .	. .	$\frac{1}{6}$
0.02	0.3086	. .	. .	. .	$\frac{1}{3}$
0.03	0.4630	. .	. .	. .	$\frac{6}{13}$
0.04	0.6173	. .	. .	. .	$\frac{7}{11}$
0.05	0.7717	. .	. .	. .	$\frac{3}{4}$
0.06	0.9260	. .	. .	. .	$\frac{9}{10}$
0.07	1.0803	. .	. .	. .	1
0.08	1.2347	. .	. .	. .	$1\frac{1}{4}$
0.09	1.3890	. .	. .	. .	$1\frac{1}{3}$
0.1	1.543	. .	. .	. .	$1\frac{1}{2}$
0.2	3.086	. .	. .	. .	3
0.3	4.630	. .	. .	. .	$4\frac{2}{3}$
0.4	6.173	. .	. .	. .	$6\frac{1}{8}$
0.5	7.716	. .	. .	. .	$7\frac{3}{4}$
0.6	9.259	. .	. .	. .	$9\frac{1}{4}$
0.7	10.803	. .	. .	. .	$10\frac{3}{4}$
0.8	12.346	. .	. .	. .	$12\frac{1}{8}$
0.9	13.889	. .	. .	. .	14
1.0	15.432	. .	. .	. .	$15\frac{1}{2}$
2.0	30.865	. .	. .	1	$10\frac{4}{5}$
3.0	46.297	. .	. .	2	$6\frac{1}{4}$
4.0	61.729	. .	1	. .	$1\frac{3}{4}$
5.0	77.162	. .	1	. .	$17\frac{1}{6}$
6.0	92.594	. .	1	1	$12\frac{3}{5}$
7.0	108.026	. .	1	2	8
8.0	123.459	. .	2	. .	$3\frac{1}{2}$
9.0	138.891	. .	2	. .	$18\frac{9}{10}$
10.0	154.323	. .	2	1	$14\frac{1}{3}$
11.0	169.756	. .	2	2	$9\frac{3}{4}$
12.0	185.188	. .	3	. .	$5\frac{1}{5}$
13.0	200.621	. .	3	1	$\frac{1}{5}$
14.0	216.053	. .	3	1	16
15.0	231.485	. .	3	2	$11\frac{1}{2}$
16.0	246.918	. .	4	. .	$6\frac{9}{10}$
17.0	262.350	. .	4	1	$2\frac{1}{3}$
18.0	277.782	. .	4	1	$17\frac{4}{5}$
19.0	293.215	. .	4	2	$13\frac{1}{5}$
20.0	308.647	. .	5	. .	$8\frac{2}{3}$
21.0	324.079	. .	5	1	$4\frac{1}{10}$
22.0	339.512	. .	5	1	$19\frac{1}{2}$
23.0	354.944	. .	5	2	5
24.0	370.376	. .	6	. .	$10\frac{2}{5}$
25.0	385.809	. .	6	1	$5\frac{4}{5}$
26.0	401.241	. .	6	2	$1\frac{1}{4}$
27.0	416.673	. .	6	2	$16\frac{3}{4}$
28.0	432.106	. .	7	. .	$12\frac{1}{10}$
29.0	447.538	. .	7	1	$7\frac{1}{2}$
30.0	462.970	. .	7	2	3
31.0	478.403	. .	7	2	$18\frac{2}{5}$
32.0	493.835	1	. .	.	$13\frac{4}{5}$
40.0	617.294	1	2	. .	$17\frac{3}{10}$
45.0	694.456	1	3	1	$10\frac{1}{2}$
50.0	771.617	1	4	2	$11\frac{3}{5}$
60.0	925.941	1	7	1	6
70.0	1080.264	2	2	. .	$\frac{1}{4}$
80.0	1234.588	2	4	1	$14\frac{3}{5}$
90.0	1388.911	2	7	. .	9
100.0	1543.235	3	1	2	$3\frac{1}{4}$

Digitized by Illinois College of Optometry

APPENDIX B.

ETYMOLOGIES.

(Condensed from Gould's Illustrated Medical Dictionary, 2d Ed.)

A

Acne [*ἀχνη*, a point] a disease of the sebaceous glands.

Amaurosis [*ἀμανρόειν*, to darken] partial (or total) loss of vision.

Amblyopia [*αμβλύς*, dulled; *ἡ ὤψ*, the eye] subnormal acuteness of vision.

Ametropia [*ἀ* priv.; *μέτρον*, a measure; *ὄψις*, sight] the formation of an imperfect image on the retina, due to defective refractive power of the media (or to some abnormality of the eye).

Amyloid [*ἄμυλον*, starch; *εἶδος*, form] starch-like.

Anemia [*ἀ* priv.; *αἷμα*, blood] (bloodless); deficiency of blood; generally understood as being due to relative reduction in the number of red blood corpuscles.

Angioma [*ἀγγεῖον*, a vessel; *ὄμα*, a tumor] a tumor formed of blood-vessels.

Anisokoria [*ἄνισος*, unequal; *κορή*, pupil] inequality in the diameter of the pupils.

Anisometropia [*ἄνισος*, unequal; *μέτρον*, a measure; *ὤψ*, the eye] a difference of refraction in the two eyes.

Ankyloblepharon [*ἀγκύλη*, a loop; *βλέφαρον*, the eyelid] adhesion of the ciliary edges of the eyelids.

Anthrax [*ἄνθραξ*, a coal or carbuncle] inflammation in the cellular tissue, due to a specific bacillus.

Aphakia [*ἀ* priv.; *φακός*, the crystalline lens] the condition of the eye without the lens.

Aplanatic [*ἀ* priv.; *πλανάειν*, to wander] rectilinear lens, corrected for aberration of light and color.

Arcus senilis [*arcus*, a bow; *senilis*, of the old].

Asthenopia [*ἀ* priv.; *σθένος*, strength] weakness or speedy fatigue of visual power.

Astigmatism [*ἀ* priv.; *στίγμα*, a point] rays not brought to a point or focus.

Atrophy [*ἀ* priv.; *τροφή*, nourishment] a condition marked by wasting or innutrition.

B

Blennorrhea [*βλέννα*, mucus; *ῥέειν*, to flow] excessive mucous discharge.

Blepharadenitis [*βλέφαρον*, the eyelid; *ἀδήν*, a gland; *ιτις*, inflammation] inflammation of the Meibomian glands.

Blepharitis [*βλέφαρον*, the eyelid; *ιτις*, inflammation] inflammation of the eyelid.

Blepharophimosis [*βλεφαρον*, the eyelid; *φίμωσις*, shutting up] abnormal smallness of the palpebral fissure.

Bothriocephalus [*βοθρίον*, a pit; *κεφαλή*, head] a species of tapeworm.

Bullosa [*bulla*, a blister] with blisters or blebs.

Buphthalmos [*βοῦς*, an ox; *ὀφθαλμός*, eye] ox-eyed.

C

Cancroid [*cancer*, a crab] cancer-like, semi-malignant.

Cataract [*καταράκτης*, a falling down or over] opacity of the lens or its capsule.

Catarrh [*καταρρέειν*, to flow down] inflammation of a mucous membrane.

Chalazion [*χαλάζιον*, a small hailstone] a Meibomian cyst.

Chemosis [*χήμωσις*, a gaping] a swelling (sub-conjunctival).

Choroid [*χόριον*, skin; *εἶδος*, like] the vascular tunic of the eye.

Chromatic [*χρῶμα*, color] relating to color.

Chromidrosis [*χρῶμα*, color; *ἱδρώς*, sweat] colored sweat.

Coloboma [*κολοβόειν*, to mutilate] a fissure of parts of the eye, congenital or traumatic.

Coma [*κῶμα*, deep sleep] abnormally deep or prolonged sleep.

Corectopia [*κόρη*, the pupil; *ἔκτοπος*, misplaced] displacement of the pupil.

Cornea [*corneus*, horny] the anterior transparent segment of the eyeball.

Cyclitis [*κύκλος*, a circle (around the eye); *ιτις*, inflammation] inflammation of the ciliary body.

Cysticercus [*κύστις*, a bladder; *κέρκος*, a tail] scalex of the tapeworm. Hydatid.

D

Dacryocystitis [*δάκρυον*, a tear; *κύστις*, a sac] inflammation of the lacrimal sac.

Dacryocystoblennorrhea [*δάκρυον*, a tear; *κύστις*, a sac; *βλέννα*, mucus; *ῥοία*, a flow] flow of tears from the lacrimal sac.

Dacryolith [*δάκρυον*, a tear; *λίθος*, a stone] a lacrimal calculus.

Dacryops [*δάκρυον*, a tear; *ὠψ*, the eye] watery eye.

Daltonism [Dalton, an English physicist] color-blindness.

Dendritica [*δένδρον*, a tree] tree-like.

Dermoid [*δέρμα*, skin; *εἶδος*, like] like the skin.

Dialysis [*διά*, through; *λύειν*, to loose] passing through.

Diopter [*διά*, through; *ὄψεσθαι*, to see] the metric unit of measurement for optical lenses.

Distichiasis [*δίς*, double; *στίχος*, row] double row of eyelashes.

E

Ectasia [*ἔκτασις*, extension] abnormal distention or dilatation of a part.

Ectropium [*ἐκ*, out; *τρέπειν*, to turn] eversion (of an eyelid).

Eczema [*ἐκζέειν*, to boil over] a catarrhal inflammatory disease of the skin.

Edema [*οἴδημα*, a swelling] swelling, due to effusion of serous fluid into areolar tissues.

Emmetropia [*ἐν*, in; *μέτρον*, measure; *ὤψ*, eye] normal vision.

Emphysema [*ἐμφυσάειν*, to inflate] abnormal collection of air in the connective tissue.

Encephalocele [*ἐγκέφαλος*, brain; *κήλη*, tumor] a hernia of the brain through a cranial fissure.

Enophthalmos [*ἐν*, in; *ὀφθαλμός*, eye] recession of eyeball into the orbit.

Entozoon [*ἐντός*, within; *ζῶον*, an animal] an animal parasite within another animal.

Entropium [*ἐν*, in; *τρέπειν*, to turn] inversion (of the eyelid).

Epicanthus [*ἐπί*, on; *κανθός*, angle of the eye] a fold of skin passing from nose to eyebrow.

Epiphora [*ἐπί*, on; *φερείν*, to bear] a persistent overflow of tears.

Erythropsia [*ἐρυθρός*, red; *ὄψις*, vision] red vision.

Esophoria [*ἔσω* (or *εἴσω*), within; *φορείν*, to bear] tending of the visual line inward.

Exophoria [*ἔξω*, without; *φορείν*, to bear] tending of visual line outward.

Exophthalmos [*ἔξ*, out; *ὀφθαλμός*, eye] abnormal prominence of eyeball.

F

Furuncle [*furunculus*, Lat. (from Sanskrit), to burn] a boil.

G

Gerontoxicon [*γέρων*, an old man; *τόξον*, a bow]. See *Arcus senilis*.

Glaucoma [*γλαυκός*, sea-green] a disease of the eye; so-called on account of the green color.

Glioma [*γλία*, glue; *ὄμα*, tumor] a variety of round-celled sarcoma.

H

Hemeralopia [*ἡμέρα*, day; *ὤ*, eye] day-vision or night-blindness. (See note under *Nyctalopia*.)

Hemianopsia [*ἡμι*, half; *ἀν* priv.; *ὄψις*, sight] blindness in one-half of the visual field.

Digitized by Harris College of Optometry

Hemorrhage [*αἷμα*, blood; *ῥηγνύναι*, to burst forth] bleeding from wounded vessels.

Herpes zoster [*ἕρπης*, creeping; *ζωστήρ*, a girdle] an inflammatory skin disease, characterized by vesicles.

Heterochromia [*ἕτερος*, different; *χρώμα*, color] a difference in color (in the irides).

Heteronymous [*ἕτερος*, different; *ὄνυμα*, name] of a different name or character. Crossed. The opposite of homonymous.

Heterophoria [*ἕτερος*, different; *φορός*, tending] a tending of the visual lines other than to parallelism.

Hippus [*ἵππος*, the horse] spasmodic pupillary movements, independent of the action of light. (Natural in the horse.)

Homonymous [*ὁμός*, same; *ὄνυμα*, name] occurring on or within the same lateral half of the body.

Hordeolum [*hardeum*, barley] a stye.

Horopter [*ὅρος*, boundary; *ὀπτήρ*, an observer] a line representing the curve along which both eyes can join in sight.

Hyaline [*ὕαλος*, glass] resembling glass.

Hydrophthalmos [*ὕδωρ*, water; *ὀφθαλμός*, eye] increase in the fluid contents of the eye.

Hydrops [*ὕδρωψ*, dropsy] an abnormal collection of fluid in any part of the body.

Hyperemia [*ὑπέρ*, over; *αἷμα*, blood] a congestion of blood.

Hypermetropia [*ὑπέρ*, over; *μέτρον*, measure; *ὤψ*, eye]. See *Hyperopia*.

Hyperopia [*ὑπερ*, over; *ὤψ*, eye]. That condition of the refractive media of the eye in which, with suspended accommodation, the focus of parallel rays of light is behind the retina; it is due to an abnormally short antero-posterior diameter of the eye, or to a subnormal refractive power of its media.

Hyperphoria [*ὑπερ*, over; *φορός*, tending] a tendency of a visual line upward.

Hyphema [*ὑπό*, under; *αἷμα*, blood] a deposit of blood on the floor of the anterior chamber.

Hypophoria [*ὑπό*, under; *φορός*, tending] a tendency of a visual line downward.

Hypopyon [*ὑπό*, under; *πῦον*, pus] a collection of pus in the anterior chamber.

Hysteria [*ὑστέρα*, the womb] a nervous disorder, once supposed to arise from the womb.

I

Iridectomy [*ἶρις*, iris; *ἐκτομή*, excision] cutting out part of the iris.

Irideremia [*ἶρις*; *ἐρημία*, lack] absence of one or both irides.

Iridodialysis [*ἶρις*; *διαλύειν*, to liberate] release of iris at its ciliary border.

Iridodonesis [*ἶρις*; *δόνησις*, trembling] tremulousness of the iris.

Iridoplegia [*ἶρις*; *πληγή*, stroke] paralysis of sphincter of the iris.

Iridotomy [*ἶρις*; *τομή*, a cutting] incision into the iris.

Iris [*ἶρις*, a colored halo or circle] the anterior portion of the vascular tunic of the eye.

Iritis [*ἶρις*; *ιτις*, inflammation] inflammation of the iris.

Ischemia [*ἴσχειν*, to check; *αἷμα*, blood] bloodlessness.

K

Karyokinesis [*κάρυον*, a nut (= nucleus); *κίνησις*, change] changes accompanying maturation of the ovum.

Keratitis [*κέρας*, horn (= cornea); *ιτις*, inflammation] inflammation of the cornea.

Keratocele [*κέρας*, cornea; *κήλη*, tumor] a hernia of Descemet's membrane through the cornea.

Keratomalacia [*κέρας*, cornea; *μαλακία*, softness] softening of corneal tissue.

Keratoscopy [*κέρας*, cornea; *σκοπεῖν*, to observe] examination of the cornea.

Kopiopia [*κόπος*, straining; *ὤψ*, eye] eye-strain. Weariness of the eyes.

Korectopia [*κόρη*, the pupil of the eye (so-called, like the Latin *pupilla*, because an image appears in the eye); *ἐκτοπος*, misplaced] displacement of the pupil.

Digitized by the Internet Archive of Optometry

L

Lagophthalmos [λαγώς, hare; ὀφθαλμός, eye] inability to close the eyes (from the popular notion that the hare sleeps with his eyes open).

Lens [Lat., a lentil] a regularly shaped transparent object refracting luminous rays.

Leukemia [λευκός, white; αἷμα, blood] a condition of the blood, characterized by a relative increase in white corpuscles.

Leukoma [λεύκωμα, anything white] a white spot on the eye.

Leukosarcoma [λευκός, white; σάρκωμα, fleshy tumor] non-pigmented sarcoma.

Lithiasis [λίθος, a stone] a callosity within the eye-lid.

Lupus [Lat., a wolf] a skin disease due to the tubercle bacillus.

Luxatio [λόξος, slanting (Lat., *obliquus*)] dislocation.

M

Macropsia [μακρός, large; ὄψις, sight] apparent increase in the size of objects.

Malacia [μαλακία, softening] morbid softening of tissue.

Marantic [μαραίναιν, to make lean] marasmus; general mal-nutrition.

Melanosarcoma [μέλας, black; σάρξ, flesh; ὄμα, tumor] pigmented sarcoma.

Metamorphopsia [μεταμορφόειν, to change shape; ὄψις, sight] apparent change in the form of objects.

Metamorphosis [μεταμορφόειν] structural change in passing from the embryo to the adult.

Microphthalmos [μικρός, small; ὀφθαλμός, eye] a small (not pathological) eye.

Micropsia [μικρός, small; ὄψις, sight] apparent decrease in the size of objects.

Miosis [μείωσις, a lessening] decrease in size of the pupil.

Mydriasis [μυδρίασις] abnormal dilatation of the pupil.

Myodesopsia [μυιοειδής, like a fly; ὄψις, vision] subjective appearance of muscæ volitantes.

Myopia [μύειν, to close; ὄψ, eye] near-sightedness. Because near-sighted people partially close the lids.

Myotomy [μύς, muscle; τομή, cutting] incision of a muscle.

Myxoma [μύξα, mucus; ὄμα, tumor] connective-tissue tumor.

N

Nyctalopia [νύξ, night; ὤψ, the eye] night-vision or day-blindness.

Night-vision; the condition in which the sight is better by night or in semi-darkness than by daylight. It is a symptom of central scotoma, the more dilated pupil at night allowing a better illumination of the peripheral portions of the retina. Dr. Greenhill and Mr. Tweedy have shown that according to the quite universal usage of modern times, the definitions of the words, *nyctalopia* and *hemeralopia*, have been the reverse of that of the early Greek and Latin writers. The proper derivation therefore of *nyctalopia* would be from νύξ, night, ἀλαός, blind, ὤψ, eye, the word meaning night-blindness. *Hemeralopia* was likewise derived from ἡμέρα, day, ἀλαός, blind, ὤψ, eye, and meant day-blindness. The attempt to reinstate the ancient usage can only result in utter confusion, and the words should therefore never be used. See *Hemeralopia*.

Nystagmus [νυσταγμός, nodding of the head] oscillatory movement of the eyeballs.

O

Œdema. See *Edema*.

Ophthalmometry [ὀφθαλμός, eye; μέτρον, measure] mensuration of the eyeball, or of the corneal curves.

Ophthalmoplegia [ὀφθαλμός; πληγή, stroke] paralysis of the ocular muscles.

Ophthalmoscope [ὀφθαλμός; σκοπεῖν, to observe] instrument for examining the interior of the eye.

Ophthalmotonometer [ὀφθαλμός; τόνος, tone; μέτρον, measure] instrument for measuring intraocular tension.

Optogram [ὀπτός, visible; γράφειν, to write] a faint image stamped on the retina for a brief period.

Orthophoria [ὀρθός, straight; φορός, tending] tending of the visual lines to parallelism.

Digitized by the Internet Archive in 2010 with funding from University of Illinois Urbana-Champaign

P

Pannus [Lat., cloth] vascularization of the cornea.

Panophthalmitis [πᾶς, all; ὀφθαλμός, eye; ιτις, inflammation] inflammation of all the tissues of the eye-ball.

Parallax [παρά, beside; ἄλλος, other] apparent displacement of an object.

Paralysis [παρά; λύειν, to loosen] loss of power of motion in a muscle.

Paresis [παρά, from; ἰέναι, to let go] partial loss of motion in a muscle.

Periscopic [περί, around; σκοπεῖν, to see] applied to lenses having a concave surface on one side and a convex on the other.

Phakomalacia [φακός, lens; μαλακία, softness] soft cataract.

Phimosis [φιμοῦν, to constrict] abnormal smallness (as of the palpebral fissure).

Phlyctenula [dim. of φλύκταινα, blister] a small vesicle or blister.

Photometer [φῶς, light; μέτρον, measure] instrument for measuring the intensity of light.

Pinguecula [Lat., *pinguis*, fat] a small tumor of the conjunctiva bulbi.

Polioencephalitis [πολιός, gray; ἐγκέφαλον, brain; ιτις, inflammation] inflammation of cortical gray matter.

Presbyopia [πρέσβυς, old; ὤψ, eye] "old-sight."

Pseudo-iso-chromatic [ψευδής, false; ἴσος, equal; χρῶμα, color] similarly colored only to those with color amblyobia.

Pterygium [πτέρυξ, wing] a triangular patch of thickened conjunctiva.

Ptosis [πτῶσις, πίπτειν, to fall] drooping of the upper eyelid.

Pyorrhea [πύον, pus; ῥοία, a flow] a purulent discharge.

R

Rhinorrhaphy [ῥις, the nose; ῥαφή, suture] reduction of the tissue of the nose by section.

S

Sarcoma [σάρξ, flesh; ὄμα, tumor] a connective-tissue tumor.

Sarcomatosum [σάρξ, flesh; ὄμα, tumor] of the nature of sarcoma.

Scintillans [*scintillare*, to sparkle] emitting sparks.

Scotoma [σκοτόειν, to darken] a fixed spot in the field of vision, corresponding to some abnormality in the retina or optic centers in the brain.

Seborrhea [*sebum*, suet; ῥοία, a flow] an increase of sebaceous secretion.

Skiascopy [σκία, shadow; σκοπεῖν, to observe] the shadow-test.

Staphyloma [σταφυλή, grape; ὄμα, tumor] a grape-like protuberance of cornea or sclera.

Stenopaic [στενός, narrow; ὀπαῖος, pierced] a disk with a narrow opening.

Strabismus [στραβίζειν, to squint] squint.

Synchisis [σύγχυσις, a mixing together] a confusing effect.

Synechia [σύν, together; ἔχειν, to hold] a morbid union of parts.

T

Tarsorrhaphy [ταρσός; ῥαφή, suture] an operation upon the eyelids.

Tarsus [ταρσός, the tarsus (a flat surface)] the cartilage of the eyelid.

Teichopsia [τεῖχος, wall; ὄψις, vision] temporary amblyopia, with subjective visual images like fortification angles.

Telangiectasis [τέλος, end; ἀγγεῖον, vessel; ἔκτασις, stretching] dilatation of capillaries.

Tenotomy [τένων, tendon; τέμνειν, to cut] tendon cutting.

Trachoma [τραχύς, rough] granular conjunctivitis.

Trichiasis [θρίξ, a hair] abnormal position of the eyelashes.

U

Uremia [οὖρον, urine; αἷμα, blood] symptoms of blood poisoning from retained urinary excretions.

Uvea [Lat., a grape (from its color)] the middle tunic of the eye.

X

Xanthelasma [ξανθός, yellow; ἔλασμα, a plate (lamina)] spots of yellowish discoloration.

Xanthoma [ξανθός, yellow; ὄμα, tumor] a yellowish new growth on the skin.

Xerosis [ξήρωσις, dry] a dry condition.

Digitized by Illinois College of Optometry

Digitized by Illinois College of Optometry

INDEX.

A

Aberration, spherical, 343, 380
Abscess of cornea, 230
  of lid, 145
  of orbit, 460
Abscission of iris, 258
Accommodation, 17, 25
  binocular, 79
  decrease of, with age, 45
  measure of, 41
  paralysis of, 288
    by atropin, 270
  range of, 41
  spasm of, 289
Acne, 152
Acuity, visual, 33
  determination of, 34
  differences in, 34
  of the retinal periphery, 63
Adaptation, 56
Adenoid, of lacrimal gland, 169
Advancement of muscle, operation for, 447
  of *Tenon's* capsule, 447
Albinism, 283
Alcoholic amblyopia, 327
Amaurosis, 383
  from alcohol, 327
  from malarial fever, 389
  from quinin, 389
  from tobacco, 327
  from uremia, 389
  partialis fugax, 392
  progressive, 329
Amaurotic "cat's-eye," 319
Amblyopia, 383
  color, 385
  diabetic, 389
  ex anopsia (from disuse), 383
  from cerebral disease, 390
  intoxication, 327
  tobacco, 327
Ametropia, 22
Amyloid, of conjunctiva, 219
Anel's syringe, 178
Aneurysm, arterio-venous, 461
  of orbit, 467
Angioma of lids, 167
Angioma of orbit, 467
Angle, *alpha*, 83
  gamma, 83
  of deviation, 90
  of squint, 83
  of vision, 34
  refracting angle of prism, 91
Anisokoria, 269, 284
Anisometropia, 381
Ankyloblepharon, 156
Anterior capsular cataract, 225
  nodal point, 23
  synechia, 230
Anthrax, 145
Aphakia, 356
Apoplexia subconjunctivalis, 215
Arcus senilis, 251
Arteria centralis retinæ, 124
  hyaloidea persistens, 360
Arteriæ ciliares, 267
Arterial pulse, 305
Artery, embolism of retinal, 311, 312
Artificial eye, 422
  pupil (see Iridectomy)
Associated movements, disturbances of, 437
Asthenopia—
  accommodative, 363
  muscular, 368, 450
  nervous, 385
Astigmatism, 47, 376
  irregular, 379
  kinds of, 50
  measure of, 51
  physiological, 376
  regular, 47, 376
  with and against the rule, 377
Atrophic excavation of disc, 397
Atrophy, descending, 330
  optic nerve, 327
  simple, 329
Atropin, 270
  conjunctivitis from, 98
  follicles from, 98
  in iritis, 275
  in keratitis, 226
  to paralyze accommodation, 41
Axis of eye, 83

Digitized by Illinois College of Optometry

Axis of rotation, 78
of vision, 83
Axis-myopia, 373

B

Band (ribbon) opacity of cornea, 253
Basedow's (Grave's) disease, 464
Beer's knife, 348
Bettman's artificial ripening of cataract, 345
Binocular lens of *Aubert*, 99
of *Zehender-Westien*, 99
vision, 70
Birth-marks, 167, 467
Bladder worm, 408
Blennorrhea, 188
neonatorum, 190
of conjunctiva, 188
Blepharadenitis, 149
Blepharitis, 149
ciliaris, 149
hypertrophica, 149
simple, 149
squamosa, 150
ulcerosa, 149
Blepharophimosis, 156
Blepharospasm, 158
Blinding (dazzling) of retina, 320
Blindness (see also Amblyopia and Amaurosis)
color, 385
Blood-vessels in the uveal tract, 267
Body, ciliary, 267
Bothriocephalus, 411
Bowman's membrane, 220
sounds, 176
Brueçke's muscle, 267
Buphthalmos congenitus, 400
Burns of conjunctiva, 216
of cornea, 251

C

Canalis *Cloqueti*, 269
Petiti, 333
Schlemmii, 269
Cancer (see Carcinoma)
Canthoplasty, 158
Canthus externus and internus, 143
Carcinoma of conjunctiva, 219
of lid, 165
Cardinal points, 22
Caruncula lacrimalis, 143
Cataract (see also Cataracta), 333
artificial ripening of, 345
capsular, 333
causes of, 343
complete, 333
Cataract, extraction of, 347
in the capsule, 351
linear, 349
forms of, 335
from lightning, 343
naphthalin, 344
salt, 343
sugar, 344
hard, 335
instruments for, 347
lamellar, 342
soft, 339
treatment of, 344, 351
Cataracta accreta, 333
calcaria, 339
capsularis, 333
centralis, 341
posterior, 339
complicata, 333
congenitalis, 339
corticalis, 333
diabetica, 344
dura hypermatura, 338
gypsea, 339
hypermatura, 338
immatura maturescens, 337
incipiens, 337
juvenilis, 339
lactea, 339
lenticularis, 333
matura, 338
membranacea, 339
Morgagniana, 338
nigra, 332
nuclearis, 332
polaris posterior, 341
pyramidalis, 341
secondaria, 340, 354
accreta, 355
senilis, 335
stationaria, 341
traumatica, 339
Catarrhal ulcer of cornea, 234
Catarrhus siccus, 183
"Cat's-eye," 319
Cautery in corneal diseases, 227
Centering of refractive media, 18
Cerebrocele (see Encephalocele)
Chalazion, 154
terreum, 156
Chemosis conjunctivæ, 188
Chiasm, optic, 304
Chloroma, 169
Choked disc, 322
Choroid, anatomy of, 267
coloboma of, 301
detachment of, 300
diseases of, 290
prolapse of, 300

Digitized by Illinois College of Optometry

Choroid, rupture (laceration) of, 300
sarcoma of, 297
tuberculosis of, 296
warts of, 301
Choroidal ring, 122
Choroiditis areolaris, 293
centralis circumscripta, 293
diffusa, 291
disseminata, 291, 369
embolica, 296
exudativa, 290
metastatica, 296
septica, 296
suppurativa, 295
chronica, 296
Chororetinitis centralis, 293
syphilitica, 294
Chromidrosis, 148
Cicatricial opacity, 253
Cilia (see Lashes)
Ciliary body, 267
diseases of, 286
forceps, 150
injection, 222
muscle, 267
paralysis of, 288
paresis of, 288
spasm of, 289
neuralgia, 222
processes, 267
Circular rotation, 77
synechia, 274
Circulus arteriosus iridis minor, 266
major, 268
Circumcision, 242
Cocain, 270
in iritis, 276
opacity from, 252
Coloboma, artificial, 282
of choroid, 301
of iris, 283
of lid, 165
Color amblyopia, 385
blindness, 385
sense, 57
tests for, 58, 59
Commotio retinæ, 320
Cones of retina, 301
Conical cornea, 260
Conjugate deviation, 437
Conjunctiva, anatomy of, 181
burns of, 216
diseases of, 181
foreign bodies in, 214
hemorrhage of, 215
hyperemia of, 183
transplantation of, 217
tumors of, 218
wounds of, 215
Conjunctival catarrh, chronic, 183
Conjunctivitis blenorrhoica, 188
catarrhalis, 185
estiva, 206
chronica, 183
crouposa, 193
diphtheritica, 194
eczematosa, 207
follicularis, 196
gonorrhoica, 190
granulosa, 199
lymphatica, 207
membranacea, 193
phlyctenulosa, 207
purulenta, 188
scrofulosa, 207
sicca, 183
simplex, 185
trachomatosa, 199
tuberculosa, 206
Contractures, secondary, 433
Conus, 369
Convergent squint, 84, 440
Corectopia, 283
Cornea, abscess of, 230
anatomy of, 220
burns of, 251
eczema of, 231
facet of, 224
fistula of, 225
frigeration of, 251
inflammations of, 221
injuries of, 247
leukoma of, 254
macula of, 254
nubecula of, 254
opacities of, 251
perforation of, 225
phlyctenule of, 231
protrusions of, 257
puncture of, 228, 405
reflection from the, 96
staphyloma of, 257
transplantation of, 256
tumors of, 261
ulcers of, 222, 234
Corneal ellipse, 48, 84
necrosis, 240
opacities, 251
puncture, 405
ulcer, 234, 235
"Corpus alienum," 249
Corpus ciliare, 267
vitreum, 360
Cover points, 72
Crab's eye, 214
Crede's method, 191
Creeping corneal ulcer (see Ulcus serpens)

Digitized by Illinois College of Optometry

Cyclitis, 286
plastica, 287
serosa, 287
suppurativa, 288
Cyst of conjunctiva, 218
of iris, 282
of lid edge, 166
Cysticercus, 407
Cystitome, 347
Cystoid scars, 406, 407

D

Dacryocystitis, 172, 174
Dacryocystoblennorrhea, 172
Dacryolith, 172
Dacryops, 170
Dacryorrhea, 188
Daltonism, 385
Dark spot, 69
Daviel's incision, 348
spoon, 348
Dayblindness (see Nyctalopia)
Dazzling of retina, 320
Decussation of optic nerves, 303
Deposits on *Descemet's* membrane, 247
Depression (for cataract), 346
Dermoid, of conjunctiva, 218
cyst of orbit, 467
Descemet's membrane, 221
deposits on, 247
Detachment of choroid, 300
of retina, 315
Deviation, angle of, 90
primary, 441
secondary, 441
Diabetic amblyopia, 389
cataract, 344
Dieffenbach's operation, 165
Diffusion theory, 317
Dilatator pupillæ, 266
Diopter, 32
Diphtheria of conjunctiva, 194
Diphtheritic corneal ulcer, 235
Diplopia (in squint), 425
Disc, optic (see Optic disc)
Discission, 340, 346
Dislaceration, 355
Distichiasis, 153
Divergence, facultative, 451
Divergent squint, 449
Double images (in paralysis), 425 *et seq.*
Douche for eye, 185
Dry catarrh, 183
Duboisin, 270

E

Echinococcus cyst of orbit, 467
Ectasia, 264
ciliaris, 264
equatorialis, 264
intercalata, 264
of sclera, 263
Ectopia lentis, 358
Ectropium, 163
cicatricial, 164
sarcomatosum, 163
Eczema from sublimate, 145
of conjunctiva, 207
of cornea, 231
of lid, 144
ulcer from, 232
Edema of lid, 147
Egyptian ophthalmia, 199
Election, position of, 451
Embolism of retinal artery, 311, 312
Emmetropia, 22
Emphysema of lids, 148, 458
Encephalocele, 466
Enophthalmos, 457
traumaticus, 458
Entozoa (see Parasites), 401
Entropium, 161
Enucleation, 421, 422
Epicanthus, 165
Epiphora, 170
Episcleritis, 262
migrans, 262
Equilibrium, test for muscular, 92
Errors of refraction, 362
Erythropsia, 358
Eserin, 270
in glaucoma, 404
Esophoria, examination for, 93
treatment of, 453
Estimation of refractive conditions, 125
Evisceration, 467
Excavation of disc, atrophic, 397
glaucomatous, 398
physiological, 124, 397
Exclusion of image, 75
regional, 442
Excursional field, 82
Exenteratio bulbi, 296, 422
orbiti, 467
Exophoria, examination for, 93
treatment of, 453
Exophthalmia fungosa, 319
Exophthalmic goiter, 464
Exophthalmometer, 457
Exophthalmos, 160, 433, 457
pulsating, 461

Digitized by Illinois College of Optometry

Exostosis of orbit, 466
Extraction of cataract, 347
Eyeball, injuries to, 411
rupture of, 414
Eye douche, 185
foreign bodies within the, 415
movements of, 76, 425
muscles, action of, 78

F

Facultative divergence, 451
Fädchen-Keratitis, 238
False projection, 71
Far point, 30
Farsightedness (see Hyperopia)
Fatty tumor of conjunctiva, 211
Fick's tonometer, 138
Field of excursion (see Excursional field)
of vision (see Visual field)
Filaria, 411
Filtration angle, 269
scar, 407
Fissure, interpalpebral, 156
narrowed, 156
widened, 159
Fistula of cornea, 225
of lacrimal gland, 170
of lacrimal sac, 174
Flarer's incision, 162
"Flying specks," 361
Fluidity of vitreous, 362
Fluorescin test, 222
in wounds of conjunctiva, 216
of cornea, 222
Focal distance of lenses, 32
illumination, 98
interval, 50
line, 48
point, anterior, 21
posterior, 20
Follicular catarrh, 196
Foreign body in conjunctiva, 214
in cornea, 249
in eyeball, 415
in iris, 280
in orbit, 458
Fossa patellaris, 331
Fracture of orbital bones, 458
Frigeration of cornea, 251
Fukala, extraction of lens in myopia, 376
Function tests, 17
Fundus, normal, 123
examination of, 119
Furuncle, 145
Fusion, range of, 80

G

Gaillard's suture, 162
Galvanocautery in corneal ulcer, 227
Gelsemin, 270
Gerontoxon, 251
Glands, lacrimal, 167
Meibomian, 143
Mollian, 143
Glaucoma, 392
absolutum, 396
acutum, 395
evolutum, 395
fulminans, 396
hemorrhagicum, 403
infantile, 400
inflammatorium, 395
pathology of, 401
primary, 395
secondary, 400
simplex, 396
theories of, 402
treatment of, 403
varieties of, 395
Glioma retinæ, 318
Goiter, exophthalmic, 160
Gonococcus of *Neisser*, 190, 464
Graefe's and *v. Graefe's* tests, 92
incision for cataract, 349
symptom, 465
Granulations (see Trachoma)
Granuloma of iris, 279
Grave's disease, 464
Green cataract (see Glaucoma)
Gumma of ciliary body, 286
of iris, 279

H

Haab's magnet operation, 418
reflex, 270
Hartnack's lenses, 99
Hemeralopia, 56, 294, 313, 383
Hemianopsia, 390
transient, 392
Hemophthalmos externus, 146
Hemorrhage—
into anterior chamber, 280
into conjunctiva, 215
into lid, 146
Hernia, cerebral, 466
Herpes febrilis (*Horner*), 236
zoster corneæ, 235
ophthalmicus, 143
Heterochromia, 283
Heterophoria, 93, 452
Hippus, 286
Hirschberg's magnet operation, 418
measurement of squint, 90

Digitized by Illinois College of Optometry

Holmgren's color test, 58
Homatropin, 270
Hordeolum, 152
Horopter, 73
"*Hutchinson's* teeth," 244
Hyaline degeneration, 220
Hyaloid, 220
Hydrophthalmos congenitus, 400
Hydrops of lacrimal sac, 172, 175
of optic nerve-sheath, 323
Hyoscyamin, 270
Hyperemia of conjunctiva, 183
of iris, 271
of retina, 306
Hypermetropia (see also Hyperopia), 37
Hyperopia, 363
absolute, 367
facultative, 366
kinds of, 37
latent, 40
manifest, 40
Hyperphoria, 93, 452
Hypertrophia epithelialis estiva, 206
Hyphema, 280
Hypophoria, 93
Hypopyon in cyclitis suppurativa, 288
in iritis suppurativa, 278
keratitis, 229

I

Identical retinal points, 72
Illumination, oblique or focal, 98
Images, retinal, displacement of, 71
Incision of *Daviel*, 348
of *Flarer*, 162
of *Jacobson*, 351
Infantile glaucoma, 400
Injury to eye as a whole, 411
to orbit, 458
Insufficiency of externi (see Esophoria)
of interni, 449
Intention trembling, 456
Intermarginal portion of lid, 142
Intoxication amblyopia, 389
Inverted image, 106
Iridectomy—the operation, 280
for glaucoma, 405
for optical purposes, 256
Irideremia, 283
Iridocyclitis, 286
serosa, 277
Iridocyclochoroiditis, 286, 291
Iridodialysis, 280
Iridodonesis, 286, 413
Iridoplegia, 280, 413
Iris, anatomy of, 265
Iris, cysts of, 282
hyperemia of, 271
inflammations of, 271
injuries of, 280
paralysis of, 280
physiology of, 268
prolapse of, 225
tremulans, 286
tumors of, 283
Iris-shadow test, 337
Iritis gummosa, 279
nodosa, 279
papulosa, 275
plastica, 272
purulenta, 272
serosa, 277
simplex, 272
suppurativa, 278
syphilitica, 275, 279
traumatica, 275
tuberculosa, 279

J

Jacobson's incision for cataract, 351
Jequirity, 193, 196

K

Keratektasia, 261
Keratitis bullosa, 239
dendritica, 237
e lagophthalmo, 239
eczematosa, 231
fascicularis, 231
filamentosa, 238
from pressure, 253
interstitialis diffusa, 243
lymphatica, 231
neuroparalitica, 238
parenchymatosa, 243
circumscripta, 246
phlyctenulosa, 231
punctata profunda, 246
superficialis, 235
scleroticans, 246
scrofulosa, 231
striata, 252
superficialis vasculosa, 232
trachomatosa, 234
traumatica, 248
vasculosa superficialis, 232
Keratocele, 225
Keratoconus, 259
Keratoglobus, 261
Keratomalacia infantum, 240
Keratome, 213, 281
Keratoplasty, 256, 259

Digitized by Illinois College of Optometry

Keratoscope of *Wecker-Masselon*, 97
Keratoscopy, 96
Klebs-Lœffler bacillus, 195
Kopiopia hysterica, 387

L

Lacrimal apparatus, anatomy of, 167
canal, 168
caruncle, 143
fistula, 170, 172
glands, diseases of, 169
passage, diseases of, 170
punctum, 168
sac, diseases of, 172
sound, 176
Lacrimation (see Epiphora)
Lagophthalmos, 160
Lamina cribrosa, 122
suprachorioidea, 267
Lashes, diseases of, 149
Laurence's strabometer, 90
Lens (crystalline), 331
anatomy of, 331
astigmatism of, 380
capsule of, 331
cataract of, 333
changes of position of, 358
displacement of, 359
embryology of, 332,
increase in size of, 337
Lenses, 32
cylindrical, 52, 378
Leukoma adherens, 225
corneæ, 254
Level, differences of, 135
Lid, abscess of, 145
anatomy of, 143
cartilage of, 143
coloboma of, 165
diseases of, 143
eczema of, 144
edema of, 147
hemorrhage into, 146
spasm of, 157
Lid edge, diseases of, 149
forceps for, 155
Ligamentum suspensorium lentis, 333
Light minimum, 53
sense, 53
of the retinal periphery, 63
Lightning, cataract from, 343
Line, visual (see Visual line)
Lipoma of conjunctiva, 218
Lithiasis palpebralis, 156, 184
Localization of opacities, 118
of paralyses, 428
Loss of working power in damaged eyes, 423-425
Lupus, 166
Luxatio bulbi, 459
lentis, 359
Lymph follicles, 199

M

Macropsia, 289
Macula corneæ, 254
Maddox rod, 94
Magnet operation of *Haab*, 418
of *Hirschberg*, 418
Magnification of ophthalmoscopic field in inverted image, 109
in upright image, 107
Malarial fever, blindness from, 389
Malingering (see Simulation)
Mariotte's spot, 69
Massage in eczema of conjunctiva, 210
in glaucoma, 404
Masson's disk, 55
Medullated nerve-fibers, 321
Meibomian glands, 143
Membrana pupillaris perseverans, 283, 284
Membrane of *Bowman*, 220
of *Descemet*, 221
Meniscus glass, 367
Meridian asymmetry, 48
Meridians, principal, 47
Metamorphopsia, 293, 294, 368
Meter angle, 79
lens, 32
Meyer's (*H.*), color test, 59
Microphthalmos, 455
Micropsia, 289
Miotics, 270
in glaucoma, 404
Moll's glands, 143
Morgagni's cataract, 338
drops, 336
Morphin, 270
Motility of lens, 359
Mouches volantes, 360
Movements of eye, 76
Mueller's horopter, 73
muscle, 267
Multiple sclerosis, 456
vision, 260
Muscæ volitantes, 360
Muscarin, 270
Muscles, action of, 78
Muscular asthenopia, 368, 450
squint, 85 *et seq.*
Musculus ciliaris, 267
Mydriatics, 270
Myelin, 336
Myodesopsia, 360
Myopia, 28, 367

Digitized by Illinois College of Optometry

Myopia, axis, 373
forms of, 29
measurement of, 31
progressive, 371
school, 373
stationary, 371
Myotomy, 434
Myxoma of optic nerve, 466
Myxosarcoma, 466

N

Nagel's experiment, 432
Naphthalin cataract, 344
Nasal duct, stenosis of, 180
Near point, 35
Nerve, optic, diseases of, 322
Nervous asthenopia, 385
Neurectomia opticociliaris, 420
Neuritis optica, 323, 324
Neurotomia opticociliaris, 420
Nevus (see Telangiectasia)
Nictitatio, 157
Night-blindness (see Hemeralopia)
shadows (see Hemeralopia)
Neurectomy, optico-ciliary, 420
Neuritis descendens, 325
intoxication, 327
myopum, 370
optica, 324
retrobulbar, 326
Neuroglia, 318
Neuron, 302
Neurotomy, optico-ciliary, 420
Nicotin, 270
Nodal point, 23
Nubecula corneæ, 254
Nuclear paralysis, 437
sclerosis, 344
Nyctalopia, 326
Nystagmus, 455
from brain disease, 456
from weak sight, 455
of minors, 456

O

Oblique illumination, 98
Œdema (see Edema)
"Old-sight" (see Presbyopia)
Opacitates corneæ, 251
corporis vitrei, 360
Opacity in the lens, diagnosis of, 335
Opaque nerve-fibers, 321
Operation of *Dieffenbach*, 165
of *Flarer*, 162
of *Pagenstecher*, 351
Operation of *Saemisch*, 228
Ophthalmometer, 98
Ophthalmoplegia, 434
externa, 434
interna, 434
totalis, 434
Ophthalmoscope, 101
of *Coccius*, 115
of *Helmholtz*, 114
of *Liebreich*, 115
of *Zehender*, 116
theory of, 101
uses of, 117
Ophthalmoscopic field, 110
in inverted image, 110
in upright image, 112
Ophthalmotonometer, 138
Optic disc, 121
physiological excavation of, 124, 397
nerve, diseases of, 322
anatomy of, 303
atrophy of, 327
inflammation of, 324
neuritis, 324
radiation, 302, 305
tracts, 305
vesicle, primary, 332
Optogram, 321
Optometer, 44
Orbiculus ciliaris, 267
Orbit, abscess of, 460
injuries to, 458
sarcoma of, 467
tumors of, 466
Orthophoria, 92
Osteoma of orbit, 466
Osteoplasty, 467

P

Pagenstecher's operation, 351
salve, 151
Pannus, 240
carnosus, 241
crassus, 241
eczematosus, 242
tenuis, 241
trachomatosus, 242
traumaticus, 242
Panophthalmitis, 288, 296
Papilla nervi optici, 122
Papillary body, 181
Papillitis, 324
Papillo-retinitis, 309, 324
Parallax, 135
Paralysis, nuclear, 437
of accommodation, 288

Digitized by Illinois College of Optometry

Paralysis of ciliary muscle, 288
of eye muscles, 425
Parasites, 407
Paresis, 288, 426
Pars ciliaris retinæ, 267
Pemphigus, 219
Pericorneal injection, 222, 272
Perimeter, 66
Periostitis orbitæ, 459
Peripheral linear extraction, 349
Petit, canal of, 333
Pflueger's color tests, 59
Phacomalacia, 339
Phlegmon, 146
Phlyctena pallida, 206
Phlyctenula of conjunctiva, 207
of cornea, 231
pallida, 206
Photometer, 54
Photophobia in iritis, 272
in keratitis, 234
Phthisis bulbi, 226
Physiological excavation, 124, 397
Pigment degeneration, 313
epithelium, 266
Pilocarpin, 270
Pinguecula, 211
Point, far, 30
near, 35
nodal, 23
principal, 22
Polyopia (see also Multiple vision), 260
monocularis, 335
Polypi of conjunctiva, 218
" Pop-eye," 457
" Position of election," 451
Posterior synechia, 230, 273, 287, 405
Presbyopia, 46
Pressure bandage, 227
effect on cornea, 253
Primary deviation, 441
glaucoma, 395
Principal meridians, 47
planes, 22
points, 22
Prisms, 91
refracting angle of, 91
uses of, 93, 450, 453
Probe, lacrimal, 176
Processus ciliaris, 267
Progressive amaurosis, 329
Projection of images, 75
Prolapse of iris, 225
of vitreous, 350
Protrusions of the cornea, 257
Pseudo-erysipelas, 146
Pseudo-glioma, 320
Pseudo-isochromatic cards, 58
Pterygium, 211
advancing, 212
stationary, 212
Ptosis, 157
Pulsating exophthalmos, 461
Punctum lachrymale, 168
proximum, 35, 41
remotum, 30
Puncture of cornea, 228, 405
Pupil, 265
changes in, 284
closure of, 472
contraction of, 266
dilatation of, 266
influence of size of, upon ophthalmoscopic field, 110
Purkinje-Sanson's images, 26, 100, 356
Pyoktanin, 227
Pyorrhea, 188

Q

Quinin, blindness from, 389

R

Range of accommodation, 41
of fusion, 80
Rays of construction, 21
of direction, 23
Reclination (for cataract), 346
Red blindness, 57
vision after cataract, 358
Reflex from vessels, 124
in fundus, 125
nuclear, 100
of *Haab*, 270
Refraction, 17
errors of, 362
of lenses, 356
of prisms, 91
ophthalmoscope, 116
Reichert's membrane, 220
Relation between accommodation and convergence, 81
Relative range of accommodation, 80
of fusion, 82
Retina, anatomy of, 301
detachment of, 315
diseases of, 306
glioma of, 318
hemorrhage from, 307
hyperemia of, 306
inflammations of, 308
injuries of, 320
physiology of, 301

Digitized by Illinois College of Optometry

Retina, vessels of, 304
Retinitis albuminurica, 308
diabetica, 310
hemorrhagica, 308
leukemica, 310
pigmentosa, 313
syphilitica, 311
Retrobulbar neuritis, 326
Ribbon-like opacities, 253
Rod optometer, 43
Rods and cones, 302
Rupture of eyeball, 414

S

Saemisch's operation, 228
Sarcoma of conjunctiva, 218
of choroid, 297
of iris, 283
of orbit, 467
"Scanning speech," 456
Scheiner's experiment, 24
Schmidt-Rimpler's refractometer, 130
School myopia, 373
Sclera, anatomy of, 221
diseases of, 262
protrusions of, 263
tumors of, 265
wounds of, 265
Scleral border, 221
ring, 122
Sclerectasia anterior, 262
posterior, 290, 369
Scleritis, 262
Sclerochoroiditis anterior, 262, 290
posterior, 290, 369
Sclerotomy, 406
Sclerosis of the lens nucleus, 344
Scopalamin, 270
Scotoma, physiological, 69
circumscribed, 294
Seborrhea, 149
fluida, 149
sicca, 149
Secondary contractures, 433
deviation, 441
glaucoma, 400
Seebeck's (*Holmgren's*) color tests, 58
Senile ectropion, 164
macular changes, 321
Sense of color (see Color sense)
Sense of distance, 71
Septic embolism, 312
Serpiginous ulcer, 229
Shadow of iris in diagnosticating cataract, 337
Shadow test (see Skiascopy)
Shortsightedness (see Myopia)
Silver, nitrate of, in conjunctivitis, 191, 192
Simulation, 387
Sinus cavernosus, 462
thrombosis, 464
Skiascopy, 131
Snellen's suture, 164
Snow blindness, 384
Soft cataract, 339
Sounds, lacrimal, 176
Spasm of ciliary muscle, 289
Spherical aberration, 343, 380
Sphincter pupillæ, 266
Spring catarrh, 207
Spud for removing foreign bodies, 250
Squint (see also Strabismus), 70, 83
angle of, 83
convergent, 440
downward, 85
inward, 84
latent, 449
manifest, 84
muscular, 85 *et seq.*
outward, 84
paralytic, 425
upward, 85
Staphyloma, 264
corneæ, 257
posticum, 264, 290, 369
scleræ, 264
Stauungspapille, 322
Stellwag's symptom, 464
Stenopaic glasses, 380
slit, 51
Stereoscope, 448
Stiff neck, 427
Strabismus (see also Squint), 83
alternans, 441
concomitans, 89, 440
deorsum vergens, 85
divergens, 449
paralyticus, 85, 425
periodicus, 440
sursum vergens, 85
unilateralis, 441
vision in, 440
Strabometer, 90
Stricture of lacrimal passages, 172
Stricturotomy, 177
Sty, 152
Sublimate eczema, 145
Suction (for cataract), 346
Suppression of retinal images, 75
Suspensory ligament, 333
Suture, *Gaillard's*, 162
Snellen's, 164
Symblepharon, 217
Sympathetic ophthalmia, 418
Synchysis, 362

Digitized by Illinois College of Optometry

Synchysis scintillans, 362
Synechia anterior, 230
posterior, 230, 273, 287
totalis, 274

T

Tænia solium, 407
Tapetum cellulosum, 319
Tarsitis, 156
Tarsorrhaphy, 160
Tarsus, diseases of, 154
Tatooing, 255
Tear (see Lacrimal)
Teichopsia, 392
Telangiectasia, 167, 467
Tenon's capsule, 447
advancement of, 447
Tenotomy for heterophoria, 454
for paralysis, 440
for strabismus, 445, 452
Tension in glaucoma, 392
measurement of, 137
Tensor choroideæ, 267
Test frame, 379
lenses, 32
Thread-worms, 411
Thrombosis, marasmatic, 464
of vena centralis retinæ, 313
of vena ophthalmica, 464
septic, 464
Tobacco amblyopia, 327
Tonometer, 139
Torpor retinæ, 316
Torticollis, 427
Total posterior synechia, 274
Trachoma, 199
corneal ulcer in, 234
follicles in, 200
Transillumination, 118
Transplantation of ciliary floor, 163
of conjunctiva, 217
of cornea, 256
Traumatic cataract, 339
keratitis, 248
pannus, 242
Trichiasis, 149, 153
Tuberculosis of choroid, 296
of conjunctiva, 206
of iris, 279
of lid, 166
Tumors of conjunctiva, 218
of cornea, 261
of iris, 283
of lid, 165
of orbit, 466
of retina, 318
of sclera, 265
Tunica media, 265
uvea, 265

U

Ulcer of cornea, 222
of lid-edge, 152
Ulcus corneæ, 222
rodens, 230
serpens, 229
Upright image (direct method), 104
Uremic amaurosis, 389
retinitis, 308
Uvea, 265
Uveal tunic, 265

V

Vaccination pustule, 152
Vascular network around cornea, 221
Vena centralis retinæ, 124
Venæ ciliares, 268
vorticosæ, 268
Venous pulse, 305
Verrucæ (see Warts)
Vertigo in squint, 425
Vision, acuteness of, 17, 33
binocular, 70
indirect, 61
monocular, 365
multiple, 260
principles of, 17
Visual angle, 34
acuity, 33
field, 65, 304
color limits in, 69
line, 83
Visus reticulatus, 295
Vitreous, abscess of (see Panophthalmitis)
anatomy of, 360
central canal of, 269, 360
fluidity of, 362
opacities in, 360
prolapse of (in cataract operation), 350
Vorticose veins, 268

W

Warts of choroid, 301
of lid, 166
Weaksightedness, cerebral, 390
Weber's lacrimal sound, 176
scoop, 349
Wolfberg's test for color sense, 60
Wool test for color sense, 58
Worms (see Parasites)
Wounds of choroid, 300
of conjunctiva, 215
of cornea, 247

Digitized by Illinois College of Optometry

Wounds of eyeball, 411
of orbit, 458

X

Xanthelasma, 167
Xanthoma, 167
Xerosis bacilli, 213
epithelialis, 213
marantica, 240
Xerosis of conjunctiva, 213
parenchymatosa, 195, 202

Y

Yellow ointment, 151

Z

Zonula of *Zinn*, 333

Digitized by Illinois College of Optometry

READ "SPECIAL NOTE" BELOW.

CATALOGUE No. 1.

AUGUST, 1899.

CATALOGUE

OF

MEDICAL, DENTAL,

Pharmaceutical, and Scientific Publications,

WITH A SUBJECT INDEX,

OF ALL BOOKS PUBLISHED BY

P. BLAKISTON'S SON & CO.

(ESTABLISHED 1843),

PUBLISHERS, IMPORTERS, AND BOOKSELLERS,

1012 WALNUT ST., PHILADELPHIA.

SPECIAL NOTE.

The prices as given in this catalogue are absolutely net, no discount will be allowed retail purchasers under any consideration. This rule has been established in order that everyone will be treated alike, a general reduction in former prices having been made to meet previous retail discounts. Upon receipt of the advertised price any book will be forwarded by mail or express, **all charges prepaid.**

We keep a large stock of Miscellaneous Books relating to Medicine and Allied Sciences, published in this country and abroad. Inquiries in regard to prices, date of edition, etc., will receive prompt attention.

The following Catalogues sent free upon application:—

CATALOGUE No. 1.—A complete list of the titles of all our publications on Medicine, Dentistry, Pharmacy, and Allied Sciences, with Classified Index.

CATALOGUE No. 3.—Pharmaceutical Books.

CATALOGUE No. 4.—Books on Chemistry and Technology.

CATALOGUE No. 5.—Books for Nurses and Lay Readers.

CATALOGUE No. 6.—Books on Dentistry and Books used by Dental Students.

CATALOGUE No. 7.—Books on Hygiene and Sanitary Science; Including Water and Milk Analysis, Microscopy, Physical Education, Hospitals, etc.

CATALOGUE No. 8.—List of about 300 Standard Books classified by Subjects.

SPECIAL CIRCULARS.—Morris' Anatomy; Gould's Medical Dictionaries; Moullin's Surgery; Books on the Eye; The ? Quiz Compends ? Series, Visiting Lists, etc. We can also furnish **sample pages** of many of our publications.

P. Blakiston's Son & Co.'s publications may be had through the booksellers in all the principal cities of the United States and Canada, or any book will be sent, postpaid, upon receipt of the price, or forwarded by express, C. O. D. No discount can be allowed retail purchasers under any circumstances. Money should be remitted by express or post-office money order, registered letter, or bank draft.

See Page 4, Gould's Medical Dictionaries.

THE PRICES OF ALL BOOKS ARE NET.

CLASSIFIED LIST, WITH PRICES,

OF ALL BOOKS PUBLISHED BY

P. BLAKISTON'S SON & CO., PHILADELPHIA.

When the price is not given below, the book is out of print or about to be published. Cloth binding, unless otherwise specified. For full descriptions see following Catalogue.

ANATOMY.

Ballou. Veterinary Anat. $0.80
Broomell. Anatomy and Histol. of Mouth and Teeth. 4.50
Eckley. Practical Anatomy. 3.50
Gordinier. Anatomy of Nervous System. Illustrated. 6.00
Heath. Practical. 7th Ed. 4.25
Holden. Dissector.
——— Osteology. 8th Ed. 5.25
——— Landmarks. 4th Ed. 1.00
Macalister's Text-Book. - 5.00
Marshall's Phys. and Anat. Diagrams. 40.00 and 60.00
Morris. Text-Book of. 790 Illus. Clo , 6.00; Sh., 7.00; ½ Rus., 8.00
Potter. Compend of. 6th Ed. 133 Illustrations. - .80
Wilson's Anatomy. 11th Ed. 5.00
Windle. Surface Anatomy. 1.00

ANESTHETICS.

Buxton. Anæsthetics. -
Turnbull. 4th Ed. - 2.50

BRAIN AND INSANITY.

Blackburn. Autopsies. - 1.25
Gowers. Diagnosis of Diseases of the Brain. 2d Ed. 1.50
Horsley. Brain and S. Cord. 2.50
Lewis (Bevan). Mental Diseases. 2d Ed. - 7 00
Mann's Psychological Med. 3.00
Régis. Mental Medicine. - 2.00
Stearns. Mental Dis. Illus. 2.75
Tuke. Dictionary of Psychological Medicine. 2 Vols. 10.00
Wood. Brain and Overwork. .40

CHEMISTRY.

See Technological Books, Water.

Allen. Commercial Organic Analysis. New Revised Editions. Volume I. 3d Ed. 4.50
——— Vol. II. Part I. 3d Ed. 3.50
——— Vol. II. Part II. 3d Ed.
——— Volume III. Part I.
——— Volume III. Part II. 4.50
——— Volume III. Part III. 4.50
——— Volume IV. - - 4.50
Bartley. Medical and Pharmaceutical. 5th Ed. - 3.00
——— Clinical Chemistry. 1.00
Bloxam's Text-Book. 8th Ed. 4.25
Caldwell. Qualitative and Quantitative Analysis. - 1.50
Groves and Thorp. Chemical Technology. Vol. I. Fuels 5.00
——— Vol. II. Lighting. - 4.00
Holland. Urine, Gastric Contents, Poisons and Milk Analysis. 5th Ed. - - - 1.00
Leffmann's Compend. - .80
——— Milk Analysis. - - 1.25
——— Structural Formulæ. - 1.00
Muter. Pract. and Anal. 1.25
Oettel. Electro-Chem. - .75
——— Electro-Chem. Exper. .75
Richter's Inorganic. 4th Ed. 1.75
——— Organic. 3d Ed. 2 Vols.
Vol. I. Aliphatic Series. 3.00
Vol. II Carbocylic Series.
Smith. Electro-Chem. Anal. 1.25
Smith and Keller. Experiments. 3d Ed. Illus. .60
Stammer. Chem. Problems. .50
Sutton. Volumetric Anal. 4.50
Symonds. Manual of. 2.00
Traube. Physico-Chem. Meth. 1.50
Ulzer and Fraenkel. Technical Chemical Analysis. 1.25
Woody. Essentials of. 4th Ed.

CHILDREN.

Cautley. Feeding of Infants. 2.00
Hale. Care of. - .50
Hatfield. Compend of. .80
Meigs. Milk Analysis. - .50
Power. Surgical Diseases of. 2.50
Smith. Wasting Diseases of. $2.00
Starr. Digestive Organs of. 2.00
——— Hygiene of the Nursery. 1.00
Taylor and Wells. Manual. 4.00

CLINICAL CHARTS.

Griffiths. Temp't're Charts. Pads of 50 - - - .50
Keen. Outline Drawings of Human Body. - - 1.00
Schreiner. Diet Lists. Pads, .75

COMPENDS

And The Quiz-Compends.

Ballou. Veterinary Anat. .80
Brubaker's Physiol. 9th Ed. .80
Gould and Pyle. The Eye. .80
Hall. Pathology. Illus. .80
Hatfield. Children. - .80
Horwitz. Surgery. 5th Ed. .80
Hughes. Practice. 2 Pts. Ea. .80
Landis. Obstetrics. 6th Ed. .80
Leffmann's Chemistry. 4th Ed. .80
Mason. Electricity. - .75
Potter's Anatomy, 6th Ed. .80
——— Materia Medica. 6th Ed. .80
Schamberg. Skin Diseases. .80
Stewart, Pharmacy. 5th Ed. .80
Warren. Dentistry. 3d Ed. .80
Wells. Gynæcology. - .80

CONSUMPTION.

Harris and Beale. Pulmonary Consumption. - - 2.50
Knopf. Pulmon. Tuberculosis. 3.00
Powell. Diseases of Lungs, including Consumption. - 4.00
Tussey. High Altitude Treatment of. - - - - 1.50

DENTISTRY.

Barrett. Dental Surg. - 1.00
Blodgett. Dental Pathology. 1.25
Broomell. Anat. and Hist. of Mouth and Teeth. - - 4.50
Fillebrown. Op. Dent. Illus. 2.25
Gorgas. Dental Medicine. 4.00
Harris. Principles and Prac. 6.00
——— Dictionary of. 5th Ed. 4.50
Heath. Dis. of Jaws. 4.50
——— Lectures on Jaws. Bds. .50
Richardson. Mech. Dent. 5.00
Sewell. Dental Surg. - 2.00
Smith. Dental Metallurgy. 1.75
Taft. Index of Dental Lit. 2.00
Talbot. Irregularity of Teeth. 3.00
Tomes. Dental Surgery. 4.00
——— Dental Anatomy. 4.00
Warren's Compend of. - .80
——— Dental Prosthesis and Metallurgy. Illus. - 1.25
White. Mouth and Teeth. .40

DIAGNOSIS.

Brown. Medical. 4th Ed. 2.25
Fenwick. Medical. 8th Ed. 2.50
Tyson's Manual. 3d Ed. Illus. 1.50

DICTIONARIES.

Gould's Illustrated Dictionary of Medicine, Biology, and Allied Sciences, etc. Leather, *Net*, $10.00; Half Russia, Thumb Index, - *Net*, 12 00
Gould's Student's Medical Dictionary. ½ Lea., 10th Ed., 3.25; ½ Mor., Thumb Index. 4.00
Gould's Pocket Dictionary—28,000 medical words. 3d Edition. Enlarged. Leather, 1.00
Harris' Dental. Clo. 4.50; Shp. 5.50
Longley's Pronouncing. .75
Maxwell. Terminologia Medica Polyglotta. - - 3.00
Treves. German-English. 3.25

EAR.

Burnett. Hearing, etc. .40
Dalby. Diseases of. 4th Ed. 2.50
Hovell. Treatise on. -
Pritchard. Diseases of. 3d Ed. 1.50
Woakes. Deafness, Giddiness, and Noises in the Head. 2.00

ELECTRICITY.

Bigelow. Plain Talks on Medical Electricity. 43 Illus. $1.00
Mason's Electricity and its Medical and Surgical Uses. .75
Jones. Medical Electricity. 3d Ed. Illus. -

EYE.

Arlt. Diseases of. - - 1.25
Donders. Refraction. - 1.25
Fick. Diseases of the Eye. 4.50
Gould and Pyle. Compend. .80
Gower's Ophthalmoscopy. 4.00
Harlan. Eyesight. - .40
Hartridge. Refraction. 9th Ed. 1.50
——— Ophthalmoscope. 3d Ed. 1.50
Hansall and Reber. Muscular Anamolies of the Eye. 1.50
Hansell and Bell. Clinical Ophthalmology. 120 Illus. 1.50
Jessop's Manual of Diseases of Eye. - - - - 3.00
Morton. Refraction. 6th Ed. 1.00
Ohlemann. Ocular Therap. 1.75
Phillips. Spectacles and Eyeglasses. 49 Illus. 2d Ed. 1.00
Swanzy's Handbook. 6th Ed. 3.00
Thorington. Retinoscopy. 1.00
——— Refraction. -
Walker. Student's Aid. 1.50

FEVERS.

Collie, On Fevers. - 2.00
Goodall and Washbourn. 3.00

HEALTH AND DOMESTIC MEDICINE.

Bulkley. The Skin. - .40
Burnett. Hearing. - .40
Cohen. Throat and Voice. .40
Dulles. Emergencies. 5th Ed. 1.00
Harlan. Eyesight. - .40
Hartshorne. Our Homes. .40
Osgood. Dangers of Winter. .40
Packard. Sea Air, etc. .40
Richardson's Long Life. .40
Westland. The Wife and Mother. - - - 1.50
White. Mouth and Teeth. .40
Wilson. Summer and its Dis. .40
Wood. Overwork. - .40

HISTOLOGY.

Stirling. Histology. 2d Ed. 2.00
Stöhr's Histology. Illus. - 3.00

HYGIENE.

Canfield. Hygiene of the Sick-Room. - - - - 1.25
Coplin and Bevan. Practical Hygiene. Illus. -
Fox. Water, Air, Food. 3.50
Kenwood. Public Health Laboratory Guide. - 2.00
Lincoln. School Hygiene. .40
McNeill. Epidemics and Isolation Hospitals. - - 3.50
Notter and Firth. - 7.00
Parkes' (L. C.), Manual. 2.50
——— Elements of Health. 1.25
Starr. Hygiene of the Nursery. 1.00
Stevenson and Murphy. A Treatise on Hygiene. In 3 Vols. *Circular* Vol. I, 6.00
upon application. Vol. II, 6.00
Vol. III, 5.00
Wilson's Handbook. 8th Ed. 3.00
Weyl. Coal-Tar Colors, 1.25

MASSAGE.

Kleen and Hartwell. - 2.25
Murrell. Massage. 6th Ed. -
Ostrom. Massage. 105 Illus. 1.00
Ward. Notes on. Paper Cov. 1.00

MATERIA MEDICA.

Biddle. 13th Ed. Cloth, 4.00
Bracken. Materia Med. 2.75
Coblentz. Newer Remedies. 1.00
Davis. Essentials of. - 1.50
Gorgas Dental. 5th Ed. 4.00
Groff. Mat. Med. for Nurses. 1.25

Heller. Essentials of. - $1.50
Potter's Compend of. 6th Ed. .80
Potter's Handbook of. 7th Ed. Cloth, 5.00; Sheep, 6.00
Sayre. Organic Materia Med. and Pharmacognosy. - ——
White & Wilcox. Mat. Med., Pharmacy, Pharmacology, and Therapeutics. 4th Ed. Enlarged. Cloth, 3.00; Sh. 3.50

MEDICAL JURISPRUDENCE.

Mann. Forensic Med. - 6.50
Reese. Medical Jurisprudence & Toxicology, 5th Ed. 3.00; Sh. 3.50

MICROSCOPE.

Beale. How to Work with. 6.50
—— In Medicine. - 6.50
Carpenter. The Microscope. 8th Ed. 800 Illus. - ——
Lee. Vade Mecum of. - 4.00
Reeves. Med. Microscopy. 2.50
Wethered. Medical Microscopy. Illus. - - - 2.00

MISCELLANEOUS.

Black. Micro-organisms. .75
Bramwell. Anæmia. - 2.50
Burnet. Food and Dietaries. 1.50
Duckworth. On Gout. - 6.00
Garrod. Rheumatism, etc. 5.00
Gould. Borderland Studies. 2.00
Gowers. Dynamics of Life. .75
Haig. Uric Acid. - - 3.00
—— Diet and Food. - - 1.00
Hare. Mediastinal Disease. 2.00
Hemmeter. Dis. of Stomach. 6 00
Henry. Anæmia. - - .50
Leffmann. Coal Tar Products. 1.25
Lizars. On Tobacco - .40
Marshall. Women's Med. Col. 1.50
New Sydenham Society's Publications, each year. - 8.00
Parrish. Inebriety. - 1.00
St. Clair. Medical Latin. 1.00
Sansom. Dis. of Heart. - 6.00
Treves. Physical Education. .75

NERVOUS DISEASES, Etc.

Beevor. Nervous Diseases. 2.50
Gordinier. Anatomy of Central Nervous System. - 6.00
Gowers. Manual of. 530 Illus. Vol. I, 4.00; Vol. 2, - 4.00
—— Syphilis and the Nervous System. - - - 1.00
—— Diseases of Brain. 1.50
—— Clinical Lectures. 2.00
—— Epilepsy. New Ed. ——
Horsley. Brain and Spinal Cord. Illus. - - - 2.50
Ormerod. Manual of. - 1.00
Osler. Cerebral Palsies. 2.00
—— Chorea. - - 2.00
Preston. Hysteria. Illus. 2.00
Watson. Concussions. 1.00

NURSING.

Brown. Physiology for Nurses. .75
Canfield. Hygiene of the Sick-Room. - - - - 1.25
Cuff. Lectures on. 2d Ed. 1.25
Cullingworth. Manual of. .75
—— Monthly Nursing. .40
Domville's Manual. 8th Ed. .75
Fullerton. Obst. Nursing. 1.00
—— Surgical Nursing. 1.00
Gould. Pocket Medical Dictionary. Limp Morocco. 1.00
Groff. Mat. Med. for Nurses. 1.25
Humphrey. Manual. 16th Ed. 1.00
Shawe. District Nursing. 1.00
Starr. Hygiene of the Nursery. 1.00
Temperature Charts. - .50
Voswinkel. Surg. Nursing. 1.00

OBSTETRICS.

Bar. Antiseptic Midwifery. 1.00
Cazeaux and Tarnier. Text-Book of. Colored Plates. 4.50
Davis. Obstetrics. 3d Ed. ——
Landis. Compend. 6th Ed. .80
Schultze. Obstetric Diagrams. 20 Plates, map size. *Net*, $26.00
Strahan. Extra-Uterine Preg. .75
Winckel's Text-book. 5.00

PATHOLOGY.

Barlow. General Pathology. 5.00
Blackburn. Autopsies. 1.25
Blodgett. Dental Pathology 1.25
Coplin. Manual of. 3d Ed. ——
Gilliam. Essentials of. - .75
Hall. Compend. Illus. 2d Ed. .80
Hewlett. Bacteriology. - 3.00
Virchow. Post-mortems. .75
Whitacre. Lab. Text-book. 1.50
Williams. Bacteriology. 1.50

PHARMACY

Beasley's Receipt-Book. - 2.00
—— Formulary. - - 2.00
Coblentz. Manual of Pharm. 3.50
Proctor. Practical Pharm. 3.00
Robinson. Latin Grammar of. 1.75
Sayre. Organic Materia Med. and Pharmacognosy. - ——
Scoville. Compounding. 2.50
Stewart's Compend. 5th Ed. .80
U. S. Pharmacopœia. 7th Revision. Cl. 2.50; Sh., 3.00
Select Tables from U. S. P. .25

PHYSIOLOGY.

Birch. Practical Physiology. 1.75
Brown. Physiol. for Nurses. .75
Brubaker's Compend. Illustrated. 9th Ed. - - .80
Kirke's New 15th Ed. (Halliburton.) Cloth, 3.00; Sh., 3.75
Landois' Text-book. 845 Illustrations. - - - - ——
Starling. Elements of. - 1.00
Stirling. Practical Phys. 2.00
Tyson's Cell Doctrine. - 1.50

POISONS.

Murrell. Poisoning. - 1.00
Reese. Toxicology. 4th Ed. 3.00
Tanner. Memoranda of. .75

PRACTICE.

Beale. Slight Ailments. 1.25
Fowler's Dictionary of. - 3.00
Hughes. Compend. 2 Pts. ea. .80
—— Physicians' Edition. 1 Vol. Morocco, Gilt edge. 2.25
Roberts. Text-book. 9th Ed. 4.50
Taylor's Manual of. - 4.00
Tyson. The Practice of Medicine. Illus. Cl. 5.50; Sheep, 6.50

PRESCRIPTION BOOKS.

Beasley's 3000 Prescriptions. 2.00
—— Receipt Book. - 2.00
Davis. Materia Medica and Prescription Writing. - 1.50

SKIN.

Bulkley. The Skin. - .40
Crocker. Dis. of Skin. Illus. ——
Impey. Leprosy. - - 3.50
Schamberg. Compend. .80
Van Harlingen. Diagnosis and Treatment of Skin Dis. 3d Ed. 60 Illus. - - 2.75

SURGERY AND SURGICAL DISEASES.

Cripps. Ovariotomy and Abdominal Surgery. - - 8.00
Deaver. Appendicitis. - 3.50
—— Surgical Anatomy. - 21.00
Dulles. Emergencies. - 1.00
Hamilton. Tumors. 3d Ed. 1.25
Heath's Minor. 10th Ed. 1.25
—— Diseases of Jaws. - 4.50
—— Lectures on Jaws. .50
Horwitz. Compend. 5th Ed. .80
Jacobson. Operations of. - 3.00
Lane. Surgery of Head. 5.00
Macready on Ruptures - 6.00
Maylard. Surgery of the Alimentary Canal. - - 7.50
Morris. Renal Surgery. 2.00
Moullin. Complete Text-book 3d Ed. by Hamilton, 600 Illustrations and Colored Plates. Cl. 6.00; Sh. 7.00
Roberts' Fractures. - $1.00
Smith. Abdominal Surg. 10.00
Swain. Surgical Emer. - 1.75
Voswinkel. Surg. Nursing. 1.00
Walsham. Practical Surg. 3.00
Watson's Amputations. 5.50

TECHNOLOGICAL BOOKS.

Cameron. Oils & Varnishes. 2.25
—— Soap and Candles. 2.00
Gardner. Brewing, etc. 1.50
Gardner. Bleaching and Dyeing. - - - - 1.50
Groves and Thorp. Chemical Technology. Vol. I. Mills on Fuels. - Cl. 5.00
Vol. II. Lighting. - 4.00
Vol. III. Lighting Contin'd. ——

THERAPEUTICS.

Allen, Harlan, Harte, Van Harlingen. Local Thera. 3.00
Biddle. 13th Edition - 4 00
Field. Cathartics and Emetics. 1.75
Mays. Theine. - - .50
Napheys' Therapeutics. Vol. 1. Medical and Disease of Children. - Cloth, 4.00
——Vol. 2. Surgery, Gynæc. & Obstet. - Cloth, 4.00
Potter's Compend. 6th Ed. .80
——, Handbook of. 5.00; Sh. 6.00
Waring's Practical. 4th Ed. 2.00
White and Wilcox. Mat. Med., Pharmacy, Pharmacology, and Thera. 4th Ed. 3.00

THROAT AND NOSE.

Cohen. Throat and Voice. .40
Hall. Nose and Throat. - 2.50
Hollopeter. Hay Fever. 1.00
Hutchinson. Nose & Throat. ——
Mackenzie. Throat Hospital Pharmacopœia. 5th Ed. 1.00
McBride. Clinical Manual, Colored Plates. 2d Ed. - 6.00
Potter. Stammering, etc. 1.00

URINE & URINARY ORGANS.

Acton. Repro. Organs. 1.75
Allen. Diabetic Urine. 2.25
Beale. Urin. Deposits. Plates. 2.00
Holland. The Urine, Milk and Common Poisons. 5th Ed. 1.00
Memminger. Diagnosis by the Urine. 2d Ed. Illus. 1.00
Morris. Renal Surgery. 2.00
Moullin. The Prostate. - ——
—— The Bladder. - 1.50
Thompson. Urinary Organs. 3.00
Tyson. Exam. of Urine. 1.25
Van Nüys. Urine Analysis. 1.00

VENEREAL DISEASES.

Cooper. Syphilis. 2d Ed. - 5.00
Gowers. Syphilis and the Nervous System. - - 1.00
Jacobson. Diseases of Male Organs. Illustrated. - 6.00

VETERINARY.

Armatage. Vet. Rememb. 1.00
Ballou. Anat. and Phys. .80
Tuson. Pharmacopœia. 2.25

VISITING LISTS.

Lindsay & Blakiston's Regular Edition. 1.00 to 2.25
—— Perpetual Ed. 1.25 to 1.50
—— Monthly Ed. .75 to 1.00
Send for Circular.

WATER.

Leffmann. Examination of. 1.25

WOMEN, DISEASES OF.

Byford (H. T.). Manual. 2d Edition. 341 Illustrations. 3.00
Byford (W. H.). Text-book. 2.00
Dührssen. Gynecological Practice. 105 Illustrations. 1.50
Lewers. Dis. of Women. 2.50
Wells. Compend. Illus. .80

☞ BASED ON RECENT MEDICAL LITERATURE.

Gould's Medical Dictionaries

BY GEORGE M. GOULD, A.M., M.D.,

EDITOR PHILADELPHIA MEDICAL JOURNAL; PRESIDENT, 1893-94, AMERICAN ACADEMY OF MEDICINE.

THE STANDARD MEDICAL REFERENCE BOOKS.

The Illustrated Dictionary of Medicine, Biology, and Allied Sciences.

INCLUDING THE PRONUNCIATION, ACCENTUATION, DERIVATION, AND DEFINITION OF THE TERMS USED IN MEDICINE AND THOSE SCIENCES COLLATERAL TO IT: BIOLOGY (ZOOLOGY AND BOTANY), CHEMISTRY, DENTISTRY, PHARMACOLOGY, MICROSCOPY, ETC. With many Useful Tables and numerous Fine Illustrations. Large, Square Octavo. 1633 pages. Fourth Edition now ready.

Full Sheep, or Half Dark-Green Leather, $10.00; with Thumb Index, $11.00
Half Russia, Thumb Index, $12.00

The Student's Medical Dictionary. Tenth Edition

INCLUDING ALL THE WORDS AND PHRASES GENERALLY USED IN MEDICINE, WITH THEIR PROPER PRONUNCIATION AND DEFINITIONS, BASED ON RECENT MEDICAL LITERATURE. With Tables of the Bacilli, Micrococci, Leucomains, Ptomains, etc., of the Arteries, Muscles, Nerves, Ganglia, and Plexuses; Mineral Springs of the U. S., etc. Small Octavo. 700 pages.

Half Dark Leather, $3.25; Half Morocco, Thumb Index, $4.00

☞ This edition has been completely rewritten, and is greatly enlarged and improved over former editions.

"We know of but one true way to test the value of a dictionary, and that is to use it. We have used the volume before us, as much as opportunity would permit, and in our search have never suffered disappointment. The definitions are lucid and concise, and are framed in the terms supplied by the latest authoritative literature, rather than by purely philological method. Obsolete words are omitted, and this has made the dimensions of the book convenient and compact. In making a dictionary, the author confesses that he has found out the labor consists in eliminating the useless, rather than adding the superfluous. The value of the work before us is increased by the large number of useful reference tables in anatomy, ptomains, micrococci, etc."—*The Physician and Surgeon, Ann Arbor.*

The Pocket Pronouncing Medical Lexicon.

THIRD EDITION, REVISED AND ENLARGED. JUST READY.

28,000 WORDS PRONOUNCED AND DEFINED.

Containing all the Words, their Definition and Pronunciation, that the Student generally comes in contact with; also elaborate Tables of the Arteries, Muscles, Nerves, Bacilli, etc., etc.; a Dose List in both English and Metric Systems, etc., arranged in a most convenient form for reference and memorizing. New Edition, from new type. *The System of Pronunciation in this book is very simple.* Thin 64 mo. 775 pages.

Full Limp Leather, Gilt Edges, $1.00; Thumb Index, $1.25.

These books may be ordered through any bookseller, or upon receipt of price the publishers will deliver free to the purchaser's address. *Full descriptive circulars and sample pages sent free upon application.*

90,000 COPIES OF GOULD'S DICTIONARIES HAVE BEEN SOLD.

☞ **All prices are net. No discount can be allowed retail purchasers.**

P. BLAKISTON'S SON & CO.'S

Medical and Scientific Publications,

No. 1012 WALNUT ST., PHILADELPHIA.

ACTON. The Functions and Disorders of the Reproductive Organs in Childhood, Youth, Adult Age and Advanced Life, considered in their Physiological, Social and Moral Relations. By WM. ACTON, M.D., M.R.C.S. 8th Edition. Cloth, $1.75

ALLEN, HARLAN, HARTE, VAN HARLINGEN. Local Therapeutics. Being a practical description of all those agents used in the local treatment of diseases of the Eye, Ear, Nose, Throat, Mouth, Skin, Vagina, Rectum, etc., such as Ointments, Plasters, Powders, Lotions, Inhalations, Suppositories, Bougies, Tampons, and the proper methods of preparing and applying them. By HARRISON ALLEN, M.D., late Laryngologist to the Rush Hospital for Consumption. GEORGE C. HARLAN, M.D., Surgeon to the Wills Eye Hospital, and Eye and Ear Department of the Pennsylvania Hospital. RICHARD H. HARTE, M.D., Surgeon to the Episcopal and St. Mary's Hospital; Ass't Surg. University Hospital; and ARTHUR VAN HARLINGEN, M.D., Professor of Diseases of the Skin in the Philadelphia Polyclinic and College for Graduates in Medicine; Dermatologist to the Howard Hospital. Cloth, $3.00; Sheep, $4.00; Half Russia, $5.00

ALLEN. Commercial Organic Analysis. New Revised Editions. A Treatise on the Properties, Proximate Analytical Examination and Modes of Assaying the Various Organic Chemicals and Products employed in the Arts, Manufactures, Medicine, etc., with Concise Methods for the Detection and Determination of Impurities, Adulterations and Products of Decomposition, etc. Revised and Enlarged. By ALFRED H. ALLEN, F.C.S., Public Analyst for the West Riding of Yorkshire; Past President Society of Public Analysts of England, etc.

Vol. I. Preliminary Examination of Organic Bodies. Alcohols, Neutral Alcoholic Derivatives, Ethers, Starch and its Isomers, Sugars, Acid Derivatives of Alcohols and Vegetable Acids, etc. Third Edition, with numerous additions by the author, and revisions and additions by DR. HENRY LEFFMANN, Professor of Chemistry and Metallurgy in the Pennsylvania College of Dental Surgery, and in the Wagner Free Institute of Science, Philadelphia, etc., with many useful tables. 8vo. *Just Ready.* Cloth, $4.50

Vol. II—Part I. Fixed Oils, Fats, Waxes, Glycerol, Soaps, Nitroglycerin, Dynamites and Smokeless Powders, Wool-Fats, Dégras, etc. Third Edition, with many useful tables. Revised by DR. HENRY LEFFMANN, with numerous additions by the author. 8vo. *Just Ready.* Cloth, $3.50

Vol. II—Part II. Hydrocarbons, including Terpenes, Resins and Camphors, Benzene Derivatives, Phenols, etc. Third Edition, Revised by DR. HENRY LEFFMANN, with additions by the author. *Nearly Ready.*

Vol. III—Part I. Acid Derivatives of Phenols, Aromatic Acids, Dyes and Coloring Matters. Third Edition, Revised by I. MERRITT MATHEWS, Professor of Chemistry and Dyeing at the Philadelphia Textile School, with many additions by the author. *In Preparation.*

Vol. III—Part II. The Amines and Ammonium Bases, Hydrazines and Derivatives. Bases from Tar. The Antipyretics, etc. Vegetable Alkaloids, Tea, Coffee, Cocoa, Kola, Cocaïne, Opium, etc. Second Edition. 8vo. 1892. Cloth, $4.50

Vol. III—Part III. Vegetable Alkaloids concluded, Non-Basic Vegetable Bitter Principles. Animal Bases, Animal Acids, Cyanogen and its Derivatives, etc. Second Edition. 8vo. 1896. Cloth, $4.50

Vol. IV. The Proteids and Albuminous Principles. Proteoïds or Albuminoïds. Second Edition, with elaborate appendices and a large number of useful tables. *Just Ready.* Cloth, $4.50

SPECIAL NOTICE. These editions of Allen are issued by us in connection with him and his London Publishers; they include much new material and copyright matter, and are the only authorized and up-to-date editions. Circular upon application.

ARLT. Clinical Studies on Diseases of the Eye. By Dr. FERD. RITTER VON ARLT, Authorized Translation by LYMAN WARE, M.D., Surgeon to the Illinois Charitable Eye and Ear Infirmary, Chicago. Illustrated. 8vo. Cloth, $1.25

ARMATAGE. The Veterinarian's Pocket Remembrancer. By GEORGE ARMATAGE, M.R.C.V.S. Second Edition. 32mo. Boards, $1.00

BALLOU. Veterinary Anatomy and Physiology. By WM. R. BALLOU, M.D., Late Prof. of Equine Anatomy, New York Coll. of Veterinary Surgeons, Physician to Bellevue Dispensary, and Lecturer on Genito-Urinary Surgery, New York Polyclinic, etc. With 29 Graphic Illustrations. 12mo. *No. 12 ? Quiz-Compend ? Series.* Cloth, .80. Interleaved, for the addition of Notes, $1.25

BAR. Antiseptic Midwifery. The Principles of Antiseptic Methods Applied to Obstetric Practice. By Dr. PAUL BAR, Paris. Authorized Translation by HENRY D. FRY, M.D., with an Appendix by the author. Octavo. Cloth, $1.00

BARRETT. Dental Surgery for General Practitioners and Students of Medicine and Dentistry. Extraction of Teeth, etc. By A. W. BARRETT, M.D. Third Edition. 86 Illustrations. 12mo. Cloth, $1.00

BARTLEY. Medical and Pharmaceutical Chemistry. Fifth Edition. A Textbook for Medical and Pharmaceutical Students. By E. H. BARTLEY, M.D., Professor of Chemistry and Toxicology at the Long Island College Hospital; Dean and Professor of Chemistry, Brooklyn College of Pharmacy; President of the American Society of Public Analysts; Chief Chemist, Board of Health, of Brooklyn, N. Y. Revised and Improved. With Illustrations. Glossary and Complete Index. 12mo. Cloth, $3.00; Leather, $3.50

Clinical Chemistry. The Chemical Examination of the Saliva, Gastric Juice, Feces, Milk, Urine, etc., with notes on Urinary Diagnosis, Volumetric Analysis and Weights and Measures. Illustrated. 12mo. Cloth, $1.00

BEALE. On Slight Ailments; their Nature and Treatment. By LIONEL S. BEALE, M.D., F.R.S., Professor of Practice, King's Medical College, London. Second Edition. Enlarged and Illustrated. 8vo. Cloth, $1.25

The Use of the Microscope in Practical Medicine. With full directions for examining secretions, etc. 4th Edition. 500 Illus. 8vo. Cloth, $6.50

How to Work with the Microscope. A Complete Manual of Microscopical Manipulation. Fifth Edition. Over 400 Illustrations. 8vo. Cloth, $6.50

One Hundred Urinary Deposits, on eight sheets, for the Hospital, Laboratory, or Surgery. New Edition. 4to. Paper, $2.00

BEASLEY'S Book of Prescriptions. Containing over 3100 Prescriptions, collected from the Practice of the most Eminent Physicians and Surgeons—English, French, and American; a Compendious History of the Materia Medica, Lists of the Doses of all Officinal and Established Preparations, and an Index of Diseases and their Remedies. By HENRY BEASLEY. Seventh Edition. Cloth, $2.00

Druggists' General Receipt Book. Comprising a copious Veterinary Formulary; Recipes in Patent and Proprietary Medicines, Druggists' Nostrums, etc.; Perfumery and Cosmetics; Beverages, Dietetic Articles and Condiments; Trade Chemicals, Scientific Processes, and an Appendix of Useful Tables. Tenth Edition. Revised. Cloth, $2.00

Pharmaceutical Formulary and Synopsis of the British, French, German, and United States Pharmacopœias. Comprising Standard and Approved Formulæ for the Preparations and Compounds Employed in Medical Practice. Twelfth Edition. Cloth, $2.00

BEEVOR. Diseases of the Nervous System and Their Treatment. By CHAS. EDWARD BEEVOR, M.D., F.R.C.P., Physician to the National Hospital for Paralyzed and Epileptic; Formerly Assistant Physician University College Hospital, London. Illustrated. 12mo. Cloth, $2.50

Digitized by Google

BIDDLE'S Materia Medica and Therapeutics. Including Dose List, Dietary for the Sick, Table of Parasites, and Memoranda of New Remedies. By Prof. JOHN B. BIDDLE, M.D., Late Prof. of Materia Medica in Jefferson Medical College, Philadelphia. Thirteenth Edition, thoroughly revised in accordance with new U. S. P., by CLEMENT BIDDLE, M.D., Assistant Surgeon, U. S. Navy. With 64 Illustrations and a Clinical Index. Octavo. Cloth, $4.00; Sheep, $5.00

BIGELOW. Plain Talks on Medical Electricity and Batteries, with a Therapeutic Index and a Glossary. By HORATIO R. BIGELOW, M.D., Fellow of the British Gynæcological Society, etc. 43 Illus., and a Glossary. 2d Ed. Cloth, $1.00

BIRCH. Practical Physiology. An Elementary Class Book. Including Histology, Chemical and Experimental Physiology. By DE BURGH BIRCH, M.D., C.M., F.R S.E., Professor of Physiology in the Yorkshire College of the Victoria University; Examiner in Victoria University; additional Examiner in Edinburgh University, etc. With 62 Illustrations. 12mo. Cloth, $1.75

BLACK. Micro-Organisms. The Formation of Poisons. A Biological study of the Germ Theory of Disease. By G. V. BLACK, M.D., D.D.S. Cloth, .75

BLACKBURN. Autopsies. A Manual of Autopsies, Designed for the use of Hospitals for the Insane and other Public Institutions. By I. W. BLACKBURN, M.D., Pathologist to the Government Hospital for the Insane. Illustrated. Cloth, $1.25

BLODGETT'S Dental Pathology. By ALBERT N. BLODGETT, M.D., Late Prof. of Pathology and Therapeutics, Boston Dental Coll. 33 Illus. 12mo. Cloth, $1.25

BLOXAM. Chemistry, Inorganic and Organic. With Experiments. By CHARLES L. BLOXAM. Edited by J. M. THOMPSON, Professor of Chemistry in King's College, London, and A. G. BLOXAM, Head of the Chemistry Department, Goldsmiths' Institute, London. Eighth Edition. Revised and Enlarged. 281 Engravings, 20 of which are new. 8vo. Cloth, $4.25; Leather, $5.25

BRACKEN. Outlines of Materia Medica and Pharmacology. By H. M. BRACKEN, Professor of Materia Medica and Therapeutics and of Clinical Medicine, University of Minnesota. 8vo. Cloth, $2.75

BRAMWELL. Anæmia and Some of the Diseases of the Blood-forming Organs and Ductless Glands. By BYROM BRAMWELL, M.D., F.R.C.P. (Ed.), F.R.S. (Ed.), Physician to the Royal Infirmary, Edinburgh; Lecturer on the Principles and Practice of Medicine and on Clinical Medicine in the School of the Royal Colleges, Edinburgh, etc., etc. Octavo. 450 pages. Cloth, $2.50

BROOMELL. Anatomy and Histology of the Human Mouth and Teeth. By DR. I. N. BROOMELL, Professor of Dental Anatomy, Dental Histology, and Prosthetic Technics in the Pennsylvania College of Dental Surgery. With 284 Handsome Illustrations, the majority of which are original. Large Octavo. Cloth, $4.50

BROWN. Medical Diagnosis. A Manual of Clinical Methods. By J. J. GRAHAM BROWN, M.D., F.R.C.P., Asst. Physician Royal Infirmary; Lecturer on Principles and Practice of Medicine in the School of Medicine of the Royal Colleges, Edinburgh, etc. Fourth Edition. 112 Illustrations. 12mo. Cloth, $2.25

BROWN. Elementary Physiology for Nurses. By MISS FLORENCE HAIG BROWN, Late in Charge Nurse Department, St. Thomas' Hospital, London. With many Illustrations. Cloth, .75

BRUBAKER. Physiology. A Compend of Physiology, specially adapted for the use of Students and Physicians. By A. P. BRUBAKER, M.D., Adjunct Professor of Physiology at Jefferson Medical College, Prof. of Physiology, Penn'a College of Dental Surgery, Philadelphia. Ninth Edition. Revised, Enlarged, and Illustrated. *No. 4, ? Quiz-Compend ? Series.* 12mo. Cloth, .80; Interleaved, $1.25

BULKLEY. The Skin in Health and Disease. By L. DUNCAN BULKLEY, M.D., Attending Physician at the New York Hospital. Illustrated. Cloth, .40

BURNET. Foods and Dietaries. A Manual of Clinical Dietetics. By R. W. BURNET, M.D., M.R.C.P., Physician to the Great Northern Central Hospital. With Appendix on Predigested Foods and Invalid Cookery. Full directions as to hours of taking nourishment, quantity, etc. Second Edition. Cloth, $1.50

BURNETT. Hearing, and How to Keep It. By CHAS. H. BURNETT, M.D., Prof. of Diseases of the Ear at the Philadelphia Polyclinic. Illustrated. Cloth, .40

BUXTON. On Anesthetics. A Manual. By DUDLEY WILMOT BUXTON, M.R.C.S., M.R.C.P., Ass't to Prof. of Med., and Administrator of Anesthetics, University College Hospital, London. Third Edition, Illustrated. 12mo. *In Press.*

BYFORD. Manual of Gynecology. A Practical Student's Book. By HENRY T. BYFORD, M.D., Professor of Gynecology and Clinical Gynecology in the College of Physicians and Surgeons of Chicago; Professor of Clinical Gynecology, Women's Medical School of Northwestern University, and in Post-Graduate Medical School of Chicago, etc. Second Edition, Enlarged. With 341 Illustrations, many of which are from original drawings and several of which are colored. 12mo. 596 pages. Cloth, $3.00

BYFORD. Diseases of Women. By the late W. H. BYFORD, A.M., M.D. Fourth Edition. 306 Illustrations. Octavo. Cloth, $2.00

CALDWELL. Chemical Analysis. Elements of Qualitative and Quantitative Chemical Analysis. By G. C. CALDWELL, B.S., PH.D., Professor of Agricultural and Analytical Chemistry in Cornell University, Ithaca, New York, etc. Third Edition. Revised and Enlarged. Octavo. Cloth, $1.50

CAMERON. Oils and Varnishes. A Practical Handbook, by JAMES CAMERON, F.I.C. With Illustrations, Formulæ, Tables, etc. 12mo. Cloth, $2.25

Soap and Candles. A New Handbook for Manufacturers, Chemists, Analysts, etc. 54 Illustrations. 12mo. Cloth, $2.00

CANFIELD. Hygiene of the Sick-Room. A book for Nurses and others. Being a Brief Consideration of Asepsis, Antisepsis, Disinfection, Bacteriology, Immunity, Heating and Ventilation, and kindred subjects, for the use of Nurses and other Intelligent Women. By WILLIAM BUCKINGHAM CANFIELD, A.M., M.D., Lecturer on Clinical Medicine and Chief of Chest Clinic, University of Maryland, Physician to Bay View Hospital and Union Protestant Infirmary, Baltimore. 12mo. Cloth, $1.25

CARPENTER. The Microscope and Its Revelations. By W. B. CARPENTER, M.D., F.R.S. Eighth Edition. By Rev. DR. DALLINGER, F. R. S. Revised and Enlarged, with 800 Illustrations and many Lithographs. Octavo. *Preparing.*

CAUTLEY. Feeding of Infants and Young Children by Natural and Artificial Methods. By EDMUND CAUTLEY, M.D., Physician to the Belgrave Hospital for Children, London. 12mo. Cloth, $2.00

CAZEAUX and TARNIER'S Midwifery. With Appendix, by Mundé. The Theory and Practice of Obstetrics, including the Diseases of Pregnancy and Parturition, Obstetrical Operations, etc. By P. CAZEAUX. Remodeled and rearranged, with revisions and additions, by S. TARNIER, M.D. Eighth American, from the Eighth French and First Italian Edition. Edited by ROBERT J. HESS, M.D., Physician to the Northern Dispensary, Phila., etc., with an Appendix by PAUL F. MUNDÉ, M.D., Professor of Gynecology at the New York Polyclinic. Illustrated by Chromo-Lithographs, Lithographs, and other Full-page Plates and numerous Wood Engravings. 8vo. Cloth, $4.50; Full Leather, $5.50

COBLENTZ. Manual of Pharmacy. A Text-Book for Students. By VIRGIL COBLENTZ, A.M., PH.D., F.C.S., Professor of Chemistry and Physics; Director of Pharmaceutical Laboratory, College of Pharmacy of the City of New York. Second Edition, Revised and Enlarged. 437 Illustrations. Octavo. 572 pages. Cloth, $3.50; Sheep, $4.50; Half Russia, $5.50

The Newer Remedies. Including their Synonyms, Sources, Methods of Preparation, Tests, Solubilities, and Doses as far as known. Together with Sections on Organo-Therapeutic Agents and Indifferent Compounds of Iron. Third Edition, very much enlarged. Octavo. *Just Ready.* Cloth, $1.00

COHEN. The Throat and Voice. By J. SOLIS-COHEN, M.D. Illus. 12mo. Cloth, .40

COLLIE, On Fevers. A Practical Treatise on Fevers, Their History, Etiology, Diagnosis, Prognosis, and Treatment. By ALEXANDER COLLIE, M.D., M.R.C.P., Lond., Medical Officer of the Homerton and of the London Fever Hospitals. With Colored Plates. 12mo. Cloth, $2.00

COOPER. Syphilis. By ALFRED COOPER, F.R.C.S., Senior Surgeon to St. Mark's Hospital; late Surgeon to the London Lock Hospital, etc. Edited by EDWARD COTTERELL, F.R.C.S., Surgeon London Lock Hospital, etc. Second Edition. Enlarged and Illustrated with 20 Full-Page Plates containing many handsome Colored Figures. Octavo. Cloth, $5.00

COPLIN. Manual of Pathology. Including Bacteriology, the Technic of Post-Mortems, and Methods of Pathologic Research. By W. M. LATE COPLIN, M.D., Professor of Pathology and Bacteriology, Jefferson Medical College; Pathologist to Jefferson Medical College Hospital and to the Philadelphia Hospital; Bacteriologist to the Pennsylvania State Board of Health. Third Edition, Rewritten and Enlarged. 275 Illustrations, many of which are original. 12mo. *Nearly Ready.*

COPLIN and BEVAN. Practical Hygiene. By W. M. L. COPLIN, M.D., and D. BEVAN, M.D., Ass't Department of Hygiene, Jefferson Medical College; Bacteriologist, St. Agnes' Hospital, Philadelphia, with an Introduction by Prof. H. A. HARE, and articles on Plumbing, Ventilation, etc., by Mr. W. P. Lockington. 138 Illustrations. 8vo. Second Edition. *In Preparation.*

CRIPPS. Ovariotomy and Abdominal Surgery. By HARRISON CRIPPS, F.R.C.S., Surgical Staff, St. Bartholomew's Hospital, London. With 17 Plates, several of which are Colored and 115 other Illustrations. Large Octavo. Cloth, $8.00

CROCKER. Diseases of the Skin. Their Description, Pathology, Diagnosis, and Treatment, with special reference to the Skin Eruptions of Children. By H. RADCLIFFE CROCKER, M.D., Physician to the Dept. of Skin Diseases, University College Hospital, London. 92 Illustrations. Third Edition. *Preparing.*

CUFF. Lectures on Medicine to Nurses. By HERBERT EDMUND CUFF, M.D., Late Ass't Medical Officer, Stockwell Fever Hospital, England. Second Edition, Revised. With 25 Illustrations. Cloth, $1.25

CULLINGWORTH. A Manual of Nursing, Medical and Surgical. By CHARLES J. CULLINGWORTH, M.D., Physician to St. Thomas' Hospital, London. Third Revised Edition. With Illustrations. 12mo. Cloth, .75

A Manual for Monthly Nurses. Third Edition. 32mo. Cloth, .40

DALBY. Diseases and Injuries of the Ear. By SIR WILLIAM B. DALBY, M.D., Aural Surgeon to St. George's Hospital, London. Illustrated. Fourth Edition. With 38 Wood Engravings and 8 Colored Plates. Cloth, $2.50

DAVIS. A Manual of Obstetrics. Being a complete manual for Physicians and Students. By EDWARD P. DAVIS, A.M., M.D., Professor of Obstetrics in the Jefferson Medical College; Professor of Obstetrics in the Philadelphia Polyclinic; Clinical Professor of Pediatrics in the Woman's Medical College of Philadelphia; Attending Obstetrician to the Philadelphia Hospital and to the Jefferson Hospital; Member of the American Gynæcological Society, of the American Pediatric Society, of the International Congress of Gynæcology and Obstetrics, of the College of Physicians of Philadelphia, of the Philadelphia Obstetrical Society, etc. Third Edition, Revised. With many Colored and other Illustrations, a large number of which have been drawn for this edition by a special artist. 12mo. *Preparing.*

DAVIS. Essentials of Materia Medica and Prescription Writing. By J. AUBREY DAVIS, M.D., Ass't Dem. of Obstetrics and Quiz Master in Materia Medica, University of Pennsylvania; Ass't Physician, Home for Crippled Children, Philadelphia. 12mo. $1.50

DOMVILLE. Manual for Nurses and others engaged in attending to the sick. By ED. J. DOMVILLE, M.D. Eighth Edition. Revised. With Recipes for Sick-room Cookery, etc. 12mo. Cloth, .75

DONDERS. Refraction. An Essay on the Nature and the Consequences of Anomalies of Refraction. By F. C. DONDERS, M.D., late Professor of Physiology and Ophthalmology in the University of Utrecht. Authorized Translation. Revised and Edited by CHARLES A. OLIVER, A.M., M.D. (Univ. Pa.), one of the Attending Surgeons to the Wills Eye Hospital; one of the Ophthalmic Surgeons to the Philadelphia Hospital, etc. With a Portrait of the Author and a series of Explanatory Diagrams. Octavo. *Just Ready.* Half Morocco, Gilt, $1.25

DEAVER. Surgical Anatomy. A Treatise on Human Anatomy in its Application to the Practice of Medicine and Surgery. By JOHN B. DEAVER, M.D., Assistant Professor of Applied Anatomy, University of Pennsylvania; Surgeon-in-chief to the German Hospital; Surgeon to the Children's Hospital, and to the Philadelphia Hospital; Consulting Surgeon to St. Agnes', St. Timothy's, and Germantown Hospitals, etc. With about 400 very handsome full-page Illustrations engraved from original drawings made by special artists from dissections prepared for the purpose in the dissecting rooms of the University of Pennsylvania. Three large volumes. Royal square octavo. Sold by Subscription. Orders taken for complete sets only. Vol. I now ready. Description upon Application.
Cloth, $21.00; Half Morocco or Sheep, $24.00; Half Russia, $27.00

Appendicitis. Its History, Anatomy, Etiology, Pathology, Symptoms, Diagnosis, Prognosis, Treatment, Complications, and Sequelæ. A Systematic Treatise, with Colored Illustrations of Methods of Procedure in Operating and Plates of Typical Pathological Conditions drawn specially for this work. 32 Full-Page Plates. 8vo. Cloth, $3.50

DUCKWORTH. On Gout. Illustrated. A treatise on Gout. By SIR DYCE DUCKWORTH, M.D. (Edin.), F.R.C.P., Physician to, and Lecturer on Clinical Medicine at, St. Bartholomew's Hospital, London. With Chromo-lithographs and Engravings. Octavo. Cloth, $6.00

DÜHRSSEN. A Manual of Gynecological Practice. By DR. A. DÜHRSSEN, Privat-docent in Midwifery and Gynecology in the University of Berlin. Translated from the Fourth German Edition and Edited by JOHN W. TAYLOR, F.R.C.S., Surgeon to the Birmingham and Midlands Hospital for Women; Vice-President of the British Gynecological Society; and FREDERICK EDGE, M.D., M.R.C.P., F.R.C.S., Surgeon to the Wolverhampton and District Hospital for Women. With 105 Illustrations. 12mo. Cloth, $1.50

DULLES. What to Do First In Accidents and Poisoning. By C. W. DULLES, M.D. Fifth Edition, Enlarged, with new Illustrations. 12mo. Cloth, $1.00

ECKLEY. Practical Anatomy. Including a Special Section on the Fundamental Principles of Anatomy. A Manual for the Use of Students in the Dissecting Room. Based upon Morris' Text-Book of Anatomy. By W. T. ECKLEY, M.D., Professor of Anatomy in the College of Physicians and Surgeons; Professor of Anatomy in the Dental Department, Northwestern University, Chicago, etc., and CORRINNE BUFORD ECKLEY, Professor of Anatomy in the Northwestern University Women's Medical School; Professor of Anatomy in the Chicago School of Anatomy and Physiology, etc. With 340 Illustrations, many of which are colored. Octavo. Cloth, $3.50; Water-Proof, $4.00

FENWICK. Guide to Medical Diagnosis. By SAMUEL FENWICK, M.D., F.R.C.P., Consulting Physician to the London Hospital; and W. S. FENWICK, M.D., M.R.C.P., Physician to the Out-Patients, Evelina Hospital for Children. Eighth Edition. In great part rewritten, with several new chapters. 135 Illustrations.
Cloth, $2.50

FICK. Diseases of the Eye and Ophthalmoscopy. A Handbook for Physicians and Students. By DR. EUGEN FICK, University of Zurich. Authorized Translation by A. B. HALE, M.D., Ophthalmic Surgeon, United Hebrew Charities; Consulting Ophthalmic Surgeon, Charity Hospital, Chicago; late Vol. Assistant, Imperial Eye Clinic, University of Kiel. With a Glossary and 158 Illustrations, many of which are in colors. 8vo. Cloth, $4.50; Sheep, $5.50; Half Russia, $6.50

FIELD. Evacuant Medication—Cathartics and Emetics. By HENRY M. FIELD, M.D., Professor of Therapeutics, Dartmouth Medical College, Corporate Member Gynæcological Society of Boston, etc. 12mo. 288 pp. Cloth, $1.75

FILLEBROWN. A Text-Book of Operative Dentistry. Written by invitation of the National Association of Dental Faculties. By THOMAS FILLEBROWN, M.D., D.M.D., Professor of Operative Dentistry in the Dental School of Harvard University; Member of the American Dental Assoc., etc. Illus. 8vo. Clo. $2.25

FOWLER'S Dictionary of Practical Medicine. *By Various Writers.* An Encyclopedia of Medicine. Edited by JAMES KINGSTON FOWLER, M.A., M.D., F.R.C.P., Senior Asst. Physician to, and Lecturer on Pathological Anatomy at, the Middlesex Hospital, London. 8vo. Cloth, $3.00; Half Morocco, $4.00

FULLERTON. Obstetric Nursing. By ANNA M. FULLERTON, M.D., Demonstrator of Obstetrics in the Woman's Medical College; Physician in charge of, and Obstetrician and Gynecologist to, the Woman's Hospital, Philadelphia, etc. 41 Illustrations. Fifth Edition. Revised and Enlarged. 12mo. Cloth, $1.00

Surgical Nursing. Comprising the Regular Course of Lectures upon Abdominal Surgery, Gynecology, and General Surgical Conditions delivered at the Training School of the Woman's Hospital, Philadelphia. Third Edition, Revised. 69 Illustrations. 12mo. Cloth, $1.00

GARDNER. The Brewer, Distiller and Wine Manufacturer. A Handbook for all Interested in the Manufacture and Trade of Alcohol and Its Compounds. Edited by JOHN GARDNER, F.C.S. Illustrated. Cloth, $1.50

Bleaching, Dyeing, and Calico Printing. With Formulæ. Illustrated. $1.50

GARROD. On Rheumatism. A Treatise on Rheumatism and Rheumatic Arthritis. By ARCHIBALD EDWARD GARROD, M.A. (Oxon.), M.D., M.R.C.S. (Eng.), Asst. Physician, West London Hospital. Illustrated. Octavo. Cloth, $5.00

GILLIAM'S Pathology. The Essentials of Pathology; a Handbook for Students. By D. TOD GILLIAM, M.D., Professor of Physiology, Starling Medical College, Columbus, O. With 47 Illustrations. 12mo. Cloth, .75

GOODALL and WASHBOURN. A Manual of Infectious Diseases. By EDWARD W. GOODALL, M.D. (London), Medical Superintendent Eastern (Fever) Hospital, Homerton, London, etc., and J. W. WASHBOURN, F.R.C.P., Assistant Physician to Guy's Hospital and Physician to the London Fever Hospital. Illustrated with Charts, Diagrams, and Full-Page Plates. Cloth, $3.00

GOULD. The Illustrated Dictionary of Medicine, Biology, and Allied Sciences. Being an Exhaustive Lexicon of Medicine and those Sciences Collateral to it, Biology (Zoology and Botany), Chemistry, Dentistry, Pharmacology, Microscopy: etc. By GEORGE M. GOULD, M.D., Editor of *The Philadelphia Medical Journal*; President, 1893–94, American Academy of Medicine, etc. With many Useful Tables and numerous Fine Illustrations. Large, Square Octavo. 1633 pages. Fourth Edition now Ready. Full Sheep, or Half Dark-Green Leather, $10.00; With Thumb Index, $11.00; Half Russia, Thumb Index, $12.00

The Student's Medical Dictionary. Tenth Edition. Enlarged. Including all the Words and Phrases generally used in Medicine, with their proper Pronunciation and Definitions, based on Recent Medical Literature. With Tables of the Bacilli, Micrococci, Leucomains, Ptomains, etc., of the Arteries, Muscles, Nerves, Ganglia and Plexuses; Mineral Springs of U. S., etc. Re-written, Enlarged, and set from new Type. Small octavo, 700 pages. Half Dark Leather, $3.25; Half Morocco, Thumb Index, $4.00

The Pocket Pronouncing Medical Lexicon. Third Edition. (28,000 Medical Words Pronounced and Defined.) A Student's Pronouncing Medical Lexicon. Containing all the Words, their Definition and Pronunciation, that the Student generally comes in contact with; also elaborate Tables of the Arteries, Muscles, Nerves, Bacilli, etc., etc.; a Dose List in both English and Metric Systems, **a new table of Clinical Eponymic Terms,** etc., arranged in a most convenient form for reference and memorizing. A new edition, completely revised and set from new type. 225 pages new material. Thin 64mo. (6 x 3¾ inches.) *The System of Pronunciation used in this book is very simple.* Full Limp Leather, Gilt Edges, $1.00; Thumb Index, $1.25

*** *Sample pages and descriptive circulars sent free upon application. See page 4.*

Borderland Studies. Miscellaneous Addresses and Essays Pertaining to Medicine and the Medical Profession, and Their Relations to General Science and Thought. By GEORGE M. GOULD, M.D. 350 pages. 12mo. Cloth, $2.00

Compend of Diseases of the Eye and Refraction. Including Treatment and Operations, with a Section on Local Therapeutics. By GEORGE M. GOULD, M.D., and W. L. PYLE, M.D. With Formulæ, Glossary, and several Tables. 111 Illustrations, several of which are Colored. *Being No. 8 ? Quiz-Compend ? Series.* Cloth, .80. Interleaved for Notes, $1.25

GORDINIER. The Gross and Minute Anatomy of the Central Nervous System. By H. C. GORDINIER, A.M., M.D., Professor of Physiology and of the Anatomy of the Nervous System in the Albany Medical College; Member American Neurological Association. With 48 full-page Plates and 213 other Illustrations, a number of which are printed in colors and many of which are original. Large 8vo. Handsome Cloth, $6.00; Sheep, $7.00; Half Russia, $8.00

GORGAS'S Dental Medicine. A Manual of Materia Medica and Therapeutics. By FERDINAND J. S. GORGAS, M.D., D.D.S., Professor of the Principles of Dental Science, Oral Surgery and Dental Mechanism in the Dental Dep. of the Univ. of Maryland. Sixth Edition. Revised and Enlarged, with many Formulæ. 8vo. Cloth, $4.00; Sheep, $5.00; Half Russia, $6.00

GRIFFITH'S Graphic Clinical Chart. Designed by J. P. CROZER GRIFFITH, M.D., Instructor in Clinical Medicine in the University of Pennsylvania. *Printed in three colors.* Sample copies free. Put up in loose packages of 50, .50
Price to Hospitals, 500 copies, $4.00; 1000 copies, $7.50. With name of Hospital printed on, 50 cents extra.

GROFF. Materia Medica for Nurses. With Questions for Self-Examination and a very complete Pronouncing Glossary. By JOHN E. GROFF, Pharmacist Rhode Island Hospital, Providence. 12mo. 235 pages. Cloth, $1.25

GROVES and THORP. Chemical Technology. A new and Complete Work. The Application of Chemistry to the Arts and Manufactures. Edited by CHAS. E. GROVES, F.R.S., and WM. THORP, B.Sc., F.I.C., assisted by many experts. In about 8 volumes, with numerous illustrations. *Each volume sold separately.*
Vol. I. FUEL AND ITS APPLICATIONS. 607 Illustrations and 4 Plates. Octavo. Cloth, $5.00; Half Morocco, $6.50
Vol. II. LIGHTING. Illustrated. Octavo. Cloth, $4.00; Half Morocco, $5.50
Vol. III. LIGHTING—Continued. *In Press.*

GOWERS. Manual of Diseases of the Nervous System. A Complete Text-book. By WILLIAM R. GOWERS, M.D., F.R.S., Physician to National Hospital for the Paralyzed and Epileptic; Consulting Physician, University College Hospital; formerly Professor of Clinical Medicine, University College, etc. Revised and Enlarged. With many new Illustrations. Two Volumes. Octavo.
VOL. I. **Diseases of the Nerves and Spinal Cord.** Third Edition. Cloth, $4.00; Sheep, $5.00; Half Russia, $6.00
VOL. II. **Brain and Cranial Nerves; General and Functional Diseases.** Second Edition. Cloth, $4.00; Sheep, $5.00; Half Russia, $6.00
*** This book has been translated into German, Italian, and Spanish. It is published in London, Milan, Bonn, Barcelona, and Philadelphia.

Syphilis and the Nervous System. Being a revised reprint of the Lettsomian Lectures for 1890, delivered before the Medical Society of London. 12mo. Cloth, $1.00

Diagnosis of Diseases of the Brain. 8vo. Second Ed. Illus. Cloth, $1.50

Medical Ophthalmoscopy. A Manual and Atlas, with Colored Autotype and Lithographic Plates and Wood-cuts, comprising Original Illustrations of the changes of the Eye in Diseases of the Brain, Kidney, etc. Third Edition. Revised, with the assistance of R. MARCUS GUNN, F.R.C.S., Surgeon, Royal London Ophthalmic Hospital, Moorfields. Octavo. Cloth, $4.00

The Dynamics of Life. 12mo. Cloth, .75

Clinical Lectures. A new volume of Essays on the Diagnosis, Treatment, etc., of Diseases of the Nervous System. Cloth, $2.00

Epilepsy and Other Chronic Convulsive Diseases. Second Edition. *In Press*

HAIG. Causation of Disease by Uric Acid. A Contribution to the Pathology of High Arterial Tension, Headache, Epilepsy, Mental Depression, Gout, Rheumatism, Diabetes, Bright's Disease, Anæmia, etc. By ALEX. HAIG, M.A., M.D. (Oxon.), F.R.C.P., Physician to Metropolitan Hospital, London. 65 Illustrations. Fourth Edition. Cloth, $3.00

Diet and Food. Considered in relation to Strength and Power of Endurance. Cloth, $1.00

Digitized by Google

HALE. On the Management of Children in Health and Disease. Cloth, .50

HALL. Compend of General Pathology and Morbid Anatomy. By H. NEWBERY HALL, PH.G., M.D., Professor of Pathology, Post-Graduate Medical School, Chicago. 91 Illus. 2d Edition. *No. 15 ? Quiz-Compend ? Series. Preparing.*

HALL. Diseases of the Nose and Throat. By F. DE HAVILLAND HALL, M.D., F.R.C.P. (Lond.), Physician in charge Throat Department Westminster Hospital; Joint Lecturer on Principles and Practice of Medicine, Westminster Hospital Medical School, etc. Two Colored Plates and 59 Illus. 12mo. Cloth, $2.50

HAMILTON. Lectures on Tumors from a Clinical Standpoint. By JOHN B. HAMILTON, M.D., LL.D., Professor of Surgery in Rush Medical College, Chicago; Professor of Surgery, Chicago Polyclinic; Surgeon Presbyterian Hospital, etc. Third Edition, Revised with new Illustrations. 12mo. Cloth, $1.25

HANSELL and REBER. Muscular Anomalies of the Eye. By HOWARD F. HANSELL, A.M., M.D., Clinical Professor of Ophthalmology, Jefferson Medical College; Professor of Diseases of the Eye, Philadelphia Polyclinic, etc., and WENDELL REBER, M.D., Instructor in Ophthalmology, Philadelphia Polyclinic, etc. With 1 Plate and 28 other Illustrations. 12mo. Cloth, $1.50

HANSELL and BELL. Clinical Ophthalmology. By HOWARD F. HANSELL, A.M., M.D., and JAMES H. BELL, M.D. With Colored Plate of Normal Fundus and 120 Illustrations. 12mo. Cloth, $1.50

HARE. Mediastinal Disease. The Pathology, Clinical History and Diagnosis of Affections of the Mediastinum other than those of the Heart and Aorta. By H. A. HARE, M.D., Professor of Materia Medica and Therapeutics in Jefferson Medical College, Philadelphia. 8vo. Illustrated by Six Plates. Cloth, $2.00

HARLAN. Eyesight, and How to Care for It. By GEORGE C. HARLAN, M.D., Prof. of Diseases of the Eye, Philadelphia Polyclinic. Illustrated. Cloth, .40

HARRIS'S Principles and Practice of Dentistry. Including Anatomy, Physiology, Pathology, Therapeutics, Dental Surgery and Mechanism. By CHAPIN A. HARRIS, M.D., D.D.S., late President of the Baltimore Dental College, Author of "Dictionary of Medical Terminology and Dental Surgery." Thirteenth Edition. Revised and Edited by FERDINAND J. S. GORGAS, A.M., M.D., D.D.S., Author of "Dental Medicine;" Professor of the Principles of Dental Science, Oral Surgery, and Dental Mechanism in the University of Maryland. 1250 Illustrations. 1180 pages. 8vo. Cloth, $6.00; Leather, $7.00; Half Russia, $8.00

Dictionary of Dentistry. Including Definitions of such Words and Phrases of the Collateral Sciences as Pertain to the Art and Practice of Dentistry. Sixth Edition. Rewritten, Revised and Enlarged. By FERDINAND J. S. GORGAS, M.D., D.D.S., Author of "Dental Medicine;" Editor of Harris's "Principles and Practice of Dentistry;" Professor of Principles of Dental Science, Oral Surgery, and Prosthetic Dentistry in the University of Maryland. Octavo. Cloth, $5.00; Leather, $6.00

HARRIS and BEALE. Treatment of Pulmonary Consumption. By VINCENT DORMER HARRIS, M.D. (Lond.), F.R.C.P., Physician to the city of London Hospital for Diseases of the Chest; Examining Physician to the Royal National Hospital for Diseases of the Chest, Ventnor, etc., and E. CLIFFORD BEALE, M.A., M.B. (Cantab.), F.R.C.P., Physician to the City of London Hospital for Diseases of the Chest, etc. 12mo. Cloth, $2.50

HARTRIDGE. Refraction. The Refraction of the Eye. A Manual for Students. By GUSTAVUS HARTRIDGE, F.R.C.S., Consulting Ophthalmic Surgeon to St. Bartholomew's Hospital, etc. 104 Illustrations and Sheet of Test Types. Ninth Edition. Revised and Enlarged by the Author. Cloth, $1.50

On The Ophthalmoscope. A Manual for Physicians and Students. Third Edition. With Colored Plates and 68 Wood-cuts. 12mo. Cloth, $1.50

HARTSHORNE. Our Homes. Their Situation, Construction, Drainage, etc. By HENRY HARTSHORNE, M.D. Illustrated. Cloth, .40

HATFIELD. Diseases of Children. By MARCUS P. HATFIELD, Professor of Diseases of Children, Chicago Medical College. With a Colored Plate. Second Edition. *Being No. 14, ? Quiz-Compend ? Series.* 12mo. Cloth, .80
Interleaved for the addition of notes, $1.25

HELLER. Essentials of Materia Medica, Pharmacy, and Prescription Writing. By EDWIN A. HELLER, M.D., Quiz-Master in Materia Medica and Pharmacy at the Medical Institute, University of Pennsylvania. 12mo. Cloth, $1.50

HEATH. Minor Surgery and Bandaging. By CHRISTOPHER HEATH, F.R.C.S., Holme Professor of Clinical Surgery in University College, London. Tenth Edition. Revised and Enlarged. With 158 Illustrations, 62 Formulæ, Diet List, etc. 12mo. Cloth, $1.25

Practical Anatomy. A Manual of Dissections. Eighth London Edition. 300 Illustrations. Cloth, $4.25

Injuries and Diseases of the Jaws. Fourth Edition. Edited by HENRY PERCY DEAN, M.S., F.R.C.S., Assistant Surgeon London Hospital. With 187 Illustrations. 8vo. Cloth, $4.50

Lectures on Certain Diseases of the Jaws, delivered at the Royal College of Surgeons of England, 1887. 64 Illustrations. 8vo. Boards, .50

HEMMETER. Diseases of the Stomach. Their Special Pathology, Diagnosis, and Treatment. With Sections on Anatomy, Analysis of Stomach Contents, Dietetics, Surgery of the Stomach, etc. By JOHN C. HEMMETER, M.D., PHILOS.D., Clinical Professor of Medicine in the University of Maryland; Consultant to the University Hospital; Director of the Clinical Laboratory, etc.; formerly Clinical Professor of Medicine at the Baltimore Medical College, etc. With Colored and other Illustrations. Cloth, $6.00; Leather, $7.00; Half Russia, $8.00

HENRY. Anæmia. A Practical Treatise. By FRED'K P. HENRY, M.D., Physician to Episcopal Hospital, Philadelphia. Half Cloth, .50

HEWLETT. Manual of Bacteriology. By R. T. HEWLETT, M.D., M.R.C.P., Asst. Bacteriologist British Institute of Preventive Medicine, etc. With 75 Illustrations. Octavo. Cloth, $3.00

HOLLOPETER. Hay Fever and Its Successful Treatment. By W. C. HOLLOPETER, A.M., M.D., Clinical Professor of Pediatrics in the Medico-Chirurgical College of Philadelphia, Physician to the Methodist Episcopal, Medico-Chirurgical, and St. Joseph Hospitals, etc. Second Edition, Enlarged. 12mo. Cloth, $1.00

HOLDEN'S Anatomy. Seventh Edition. A Manual of the Dissections of the Human Body. By JOHN LANGTON, F.R.C.S., Surgeon to, and Lecturer on Anatomy at, St. Bartholomew's Hospital. Carefully Revised by A. HEWSON, M.D., Demonstrator of Anatomy, Jefferson Medical College, etc. 311 Illustrations. 12mo. 800 pages. *Preparing.*

Human Osteology. Comprising a Description of the Bones, with Colored Delineations of the Attachments of the Muscles. The General and Microscopical Structure of Bone and its Development. 8th Ed., carefully Revised. With Lithographic Plates and Numerous Illustrations. Cloth, $5.25

Landmarks. Medical and Surgical. 4th Edition. 8vo. Cloth, $1.00

HOLLAND. The Urine, the Gastric Contents, the Common Poisons and the Milk. Memoranda, Chemical and Microscopical, for Laboratory Use. By J. W. HOLLAND, M.D., Professor of Medical Chemistry and Toxicology in Jefferson Medical College, of Philadelphia. Fifth Edition, Enlarged. Illustrated and Interleaved. 12mo. Cloth, $1.00

HORWITZ'S Compend of Surgery, including Minor Surgery, Amputations, Fractures, Dislocations, Surgical Diseases, and the Latest Antiseptic Rules, etc., with Differential Diagnosis and Treatment. By ORVILLE HORWITZ, B.S., M.D., Professor of Genito-Urinary Diseases, late Demonstrator of Surgery, Jefferson Medical College. Fifth Edition. Very much Enlarged and Rearranged. Over 300 pages. 167 Illustrations and 98 Formulæ. 12mo. *No. 9 ? Quiz-Compend ? Series.* Cloth, .80. Interleaved for notes, $1.25

*** *A Spanish translation of this book has recently been published in Barcelona.*

HORSLEY. The Brain and Spinal Cord. The Structure and Functions of. By VICTOR A. HORSLEY, M.B., F.R.S., etc., Asst. Surg., University College Hospital, London, etc. Illustrated. Cloth, $2.50

HOVELL. Diseases of the Ear and Naso-Pharynx. A Treatise including Anatomy and Physiology of the Organ, together with the treatment of the affections of the Nose and Pharynx which conduce to aural disease. By T. MARK HOVELL, F.R.C.S. (Edin.), M.R.C.S. (Eng.), Aural Surgeon to the London Hospital, for Diseases of the Throat, etc. 122 Illus. Second Edition. *Preparing.*

HUMPHREY. A Manual for Nurses. Including general Anatomy and Physiology, management of the sick-room, etc. By LAURENCE HUMPHREY, M.A., M.B., M.R.C.S., Assistant Physician to, and Lecturer at, Addenbrook's Hospital, Cambridge, England. Sixteenth Edition. 12mo. Illustrated. Cloth, $1.00

HUGHES. Compend of the Practice of Medicine. Sixth Edition. Revised and Enlarged. By DANIEL E. HUGHES, M.D., Chief Resident Physician Philadelphia Hospital; formerly Demonstrator of Clinical Medicine at Jefferson Medical College, Philadelphia. In two parts. *Being Nos. 2 and 3, ? Quiz-Compend ? Series.*

PART I.—Continued, Eruptive and Periodical Fevers, Diseases of the Mouth, Stomach, Intestines, Peritoneum, Biliary Passages, Liver, Kidneys, Blood, etc., Parasites, etc., and General Diseases, etc.

PART II.—Physical Diagnosis, Diseases of the Respiratory System, Circulatory System, Diseases of the Brain and Nervous System, Mental Diseases, etc.

Price of each Part, in Cloth, .80; interleaved for the addition of Notes, $1.25

Physicians' Edition.—In one volume, including the above two parts, a section on Skin Diseases, and an index. *Sixth revised and enlarged Edition. 575 pages.* Full Morocco, Gilt Edge, $2.25

"Carefully and systematically compiled."—*The London Lancet.*

HUTCHINSON. The Nose and Throat. A Manual of the Diseases of the Nose and Throat, including the Nose, Naso-Pharynx, Pharynx and Larynx. By PROCTER S. HUTCHINSON, M.R.C.S., Ass't Surgeon to the London Hospital for Diseases of the Throat. Illustrated by Lithograph Plates and 40 other Illus., many of which have been made from original drawings. 12mo. 2d Ed. *In Press.*

IMPEY. A Handbook on Leprosy. By S. P. IMPEY, M.D., M.C., Late Chief and Medical Superintendent, Robben Island Leper and Lunatic Asylums, Cape Colony, South Africa. Illustrated by 37 Plates and a Map. Octavo. Cloth, $3.50

JACOBSON. Operations of Surgery. By W. H. A. JACOBSON, B.A. (Oxon.), F.R.C.S., (Eng.); Ass't Surgeon, Guy's Hospital; Surgeon at Royal Hospital for Children and Women, etc. With over 200 Illust. Cloth, $3.00; Leather, $4.00

Diseases of the Male Organs of Generation. 88 Illustrations. Cloth, $6.00

JESSOP. Manual of Ophthalmic Surgery and Medicine. By WALTER H. H. JESSOP, M.B. (Cantab.), F.R.C.S., Ophthalmic Surgeon to and Lecturer on Ophthalmic Medicine and Surgery at St. Bartholomew's Hospital, London. With 5 Colored Plates, Test Types, and 110 other Illustrations. 12mo. Cloth, $3.00

JONES. Medical Electricity. A Practical Handbook for Students and Practitioners of Medicine. By H. LEWIS JONES, M.A., M.D., M.R.C.P., Medical Officer in Charge Electrical Department, St. Bartholomew's Hospital. Third Edition of Steavenson and Jones' Medical Electricity. Revised and Enlarged. 112 Illustrations. 12mo. *Preparing.*

KEEN. Clinical Charts. A series of seven Outline Drawings of the Human Body, on which may be marked the course of any Disease, Fractures, Operations, etc. By W. W. KEEN, M.D., Professor of the Principles of Surgery and Clinical Surgery, Jefferson Medical College, Philadelphia. Put up in pads of 50, with explanations. Each pad, $1.00. Each Drawing may also be had separately gummed on back for pasting in case book. 25 to the pad. Price, 25 cents.

*** *Special Charts will be printed to order. Samples free.*

KIRKE'S Physiology. (*15th Authorized Edition. 12mo. Dark Red Cloth.*) A Handbook of Physiology. Fourteenth London Edition, Revised and Enlarged. By W. D. HALLIBURTON, M.D., F.R.S., Professor of Physiology King's College, London. Thoroughly Revised and in many parts Rewritten. 668 Illus., many of which are printed in Colors. 872 pages. 12mo. Cloth, $3.00; Leather, $3.75

IMPORTANT NOTICE. This is the identical Edition of "Kirke's Physiology," as published in London by John Murray, the sole owner of the book. It is the only edition containing the revisions and additions of Dr. Halliburton, and the new and original illustrations included at his suggestion. This edition has been carefully and thoroughly revised.

KENWOOD. Public Health Laboratory Work. By H. R. KENWOOD, M.B., D.P.H., F.C.S., Instructor in Hygienic Laboratory, University College, late Assistant Examiner in Hygiene, Science and Art Department, South Kensington, London, etc. With 116 Illustrations and 3 Plates. Cloth, $2.00

KLEEN. Handbook of Massage. By EMIL KLEEN, M.D., PH.D., Stockholm and Carlsbad. Authorized Translation from the Swedish, by EDWARD MUSSEY HARTWELL, M.D., PH.D., Director of Physical Training in the Public Schools of Boston. With an Introduction by Dr. S. WEIR MITCHELL, of Philadelphia. Illustrated by Photographs made specially for the American Edition. 8vo. Cloth, $2.25

KNOPF. Pulmonary Tuberculosis: Its Modern Prophylaxis and the Treatment in Special Institutions and at Home. By S. A. KNOPF, M.D., Physician to the Lung Department of the New York Throat and Nose Hospital; former Assistant Physician to Prof. Dettweiler, Falkenstein Sanatorium, Germany, etc. Illustrated. Octavo. Cloth, $3.00

LANDIS' Compend of Obstetrics; especially adapted to the Use of Students and Physicians. By HENRY G. LANDIS, M.D. Sixth Edition. Revised by WM. H. WELLS, M.D., Instructor of Obstetrics, Jefferson Medical College; Member Obstetrical Society of Philadelphia, etc. With 47 Illustrations. *No. 5 ? Quiz-Compend ? Series.* Cloth, .80; interleaved for the addition of Notes, $1.25

LANDOIS. A Text-Book of Human Physiology; including Histology and Microscopical Anatomy, with special reference to the requirements of Practical Medicine. By DR. L. LANDOIS, Professor of Physiology and Director of the Physiological Institute in the University of Greifswald. Fifth American, translated from the last German Edition, with additions, by WM. STIRLING, M.D., D.Sc., Brackenbury Professor of Physiology and Histology in Owen's College, and Professor in Victoria University, Manchester; Examiner in Physiology in University of Oxford, England. With 845 Illustrations, many of which are printed in Colors. 8vo. *In Press.*

LANE. Surgery of the Head and Neck. By L. C. LANE, A.M., M.D., M.R.C.S. (Eng.), Professor of Surgery in Cooper Medical College, San Francisco. Second Edition, with 110 Illustrations. Octavo. Cloth, $5.00

LAZARUS-BARLOW. General Pathology. By W. S. LAZARUS-BARLOW, M.D., Demonstrator of Pathology at the University of Cambridge, England. 795 pages. Octavo. Cloth, $5.00

LEE. The Microtomist's Vade Mecum. Fourth Edition. A Handbook of Methods of Microscopic Anatomy. By ARTHUR BOLLES LEE, formerly Ass't in the Russian Laboratory of Zoology, at Villefranche-sur-Mer (Nice). 887 Articles. Enlarged and Revised, and in many portions greatly extended. 8vo. Cloth, $4.00

LEFFMANN'S Compend of Medical Chemistry, Inorganic and Organic. Including Urine Analysis. By HENRY LEFFMANN, M.D., Prof. of Chemistry in the Woman's Medical College in the Penna. College of Dental Surgery and in the Wagner Free Institute of Science, Philadelphia; Pathological Chemist Jefferson Medical College. *No. 10 ? Quiz-Compend ? Series.* Fourth Edition. Rewritten. Cloth, .80. Interleaved for the addition of Notes, $1.25

The Coal-Tar Colors, with Special Reference to their Injurious Qualities and the Restrictions of their Use. A Translation of Theodore Weyl's Monograph. 12mo. Cloth, $1.25

Examination of Water for Sanitary and Technical Purposes. Fourth Edition. Enlarged. Illustrated. 12mo. Cloth, $1.25

LEFFMANN'S Analysis of Milk and Milk Products. Arranged to suit the needs of Analytical Chemists, Dairymen, and Milk Inspectors. Second Edition, Revised and Enlarged, with Illustrations. 12mo. Cloth, $1.25

Handbook of Structural Formulæ for the Use of Students, containing 180 Structural and Stereo-chemic Formulæ. 12mo. Interleaved. Cloth, $1.00

LEWERS. On the Diseases of Women. A Practical Treatise. By Dr. A. H. N. LEWERS, Assistant Obstetric Physician to the London Hospital; and Physician to Out-patients, Queen Charlotte's Lying-in Hospital; Examiner in Midwifery and Diseases of Women to the Society of Apothecaries of London. With 146 Engravings. Fifth Edition, Revised. Cloth, $2.50

LEWIS (BEVAN). Mental Diseases. A text-book having special reference to the Pathological aspects of Insanity. By BEVAN LEWIS, L.R.C.P., M.R.C.S., Medical Director, West Riding Asylum, Wakefield, England. 26 Lithograph Plates and other Illustrations. Second Ed., Revised and Enlarged. 8vo. Cloth, $7.00

LINCOLN. School and Industrial Hygiene. By D. F. LINCOLN, M.D. Cloth, .40

LIZARS (JOHN). On Tobacco. The Use and Abuse of Tobacco. Cloth, .40

LONGLEY'S Pocket Medical Dictionary. Giving the Definition and Pronunciation of Words and Terms in General Use in Medicine, with an Appendix, containing Poisons and their Antidotes, Abbreviations Used in Prescriptions, etc. By ELIAS LONGLEY. Cloth, .75; Tucks and Pocket, $1.00

MACALISTER'S Human Anatomy. 800 Illustrations. Systematic and Topographical, including the Embryology, Histology and Morphology of Man. With special reference to the requirements of Practical Surgery and Medicine. By ALEX. MACALISTER, M.D., F.R.S., Professor of Anatomy in the University of Cambridge, England. 816 Illustrations. Octavo. Cloth, $5.00; Leather, $6.00

MACKENZIE. The Pharmacopœia of the London Hospital for Diseases of the Throat. By SIR MORELL MACKENZIE, M.D. Fifth Edition. Revised and Improved by F. G. HARVEY, Surgeon to the Hospital. Cloth, $1.00

MACREADY. A Treatise on Ruptures. By JONATHAN F. C. H. MACREADY, F.R.C.S., Surgeon to the Great Northern Central Hospital; to the City of London Hospital for Diseases of the Chest; to the City of London Truss Society, etc. With 24 full-page Plates and numerous Wood-Engravings. Octavo. Cloth, $6.00

MANN. Forensic Medicine and Toxicology. A Text-Book by J. DIXON MANN, M.D., F.R.C.P., Professor of Medical Jurisprudence and Toxicology in Owens College, Manchester; Examiner in Forensic Medicine in University of London, etc. Illustrated. Octavo. Cloth, $6.50

MANN'S Manual of Psychological Medicine and Allied Nervous Diseases. Their Diagnosis, Pathology, Prognosis and Treatment, including their Medico-Legal Aspects; with chapter on Expert Testimony, and an abstract of the laws relating to the Insane in all the States of the Union. By EDWARD C. MANN, M.D. With Illustrations. Octavo. Cloth, $3.00

MARSHALL'S Physiological Diagrams, Life Size, Colored. Eleven Life-size Diagrams (each 7 feet by 3 feet 7 inches). Designed for Demonstration before the Class. By JOHN MARSHALL, F.R.S., F.R.C.S., Professor of Anatomy to the Royal Academy; Professor of Surgery, University College, London, etc.

In Sheets, $40.00 Backed with Muslin and Mounted on Rollers, $60.00

Ditto, Spring Rollers, in Handsome Walnut Wall Map Case (Send for Special Circular), ... $100.00

Single Plates, Sheets, $5.00; Mounted, $7.50; Explanatory Key, 50 cents.

Purchaser must pay freight charges.

No. 1—The Skeleton and Ligaments. No. 2—The Muscles and Joints, with Animal Mechanics. No. 3—The Viscera in Position. The Structure of the Lungs. No. 4—The Heart and Principal Blood-vessels. No. 5—The Lymphatics or Absorbents. No. 6—The Digestive Organs. No. 7—The Brain and Nerves. Nos. 8 and 9—The Organs of the Senses. Nos. 10 and 11—The Microscopic Structure of the Textures and Organs. (*Send for Special Circular.*)

MARSHALL. The Woman's Medical College of Pennsylvania. An Historical Outline. By CLARA MARSHALL, M.D., Dean of the College. 8vo. Cloth, $1.50

MASON'S Compend of Electricity, and its Medical and Surgical Uses. By CHARLES F. MASON, M.D., Assistant Surgeon U. S. Army. With an Introduction by CHARLES H. MAY, M.D., Instructor in the New York Polyclinic. Numerous Illustrations. 12mo. Cloth, .75

MAXWELL. Terminologia Medica Polyglotta. By Dr. THEODORE MAXWELL, assisted by others in various countries. 8vo. Cloth, $3.00

The object of this work is to assist the medical men of any nationality in reading medical literature written in a language not their own. Each term is usually given in seven languages, viz.: English, French, German, Italian, Spanish, Russian and Latin.

MAYLARD. The Surgery of the Alimentary Canal. By ALFRED ERNEST MAYLARD, M.B., B.S., Senior Surgeon to the Victoria Infirmary, Glasgow. With 27 Full-Page Plates and 117 other Illustrations. Octavo. Cloth, $7.50

MAYS' Theine in the Treatment of Neuralgia. By THOMAS J. MAYS, M.D. 16mo. ½ bound, .50

McBRIDE. Diseases of the Throat, Nose and Ear. A Clinical Manual for Students and Practitioners. By P. MCBRIDE, M.D., F.R.C.P. (Edin.), Surgeon to the Ear and Throat Department of the Royal Infirmary; Lecturer on Diseases of Throat and Ear, Edinburgh School of Medicine, etc. With Colored Illustrations from Original Drawings. 2d Edition. Octavo. Handsome Cloth, Gilt top, $6.00

McNEILL. The Prevention of Epidemics and the Construction and Management of Isolation Hospitals. By DR. ROGER MCNEILL, Medical Officer of Health for the County of Argyll. With numerous Plans and other Illustrations. Octavo. Cloth, $3.50

MEIGS. Milk Analysis and Infant Feeding. A Treatise on the Examination of Human and Cows' Milk, Cream, Condensed Milk, etc., and Directions as to the Diet of Young Infants. By ARTHUR V. MEIGS, M.D. 12mo. Cloth, .50

MEMMINGER. Diagnosis by the Urine. The Practical Examination of Urine, with Special Reference to Diagnosis. By ALLARD MEMMINGER, M.D., Professor of Chemistry, Urinology, and Hygiene in the Medical College of the State of South Carolina; Visiting Physician in the City Hospital of Charleston, etc. Second Edition, Enlarged and Revised. 24 Illus. 12mo. Cloth, $1.00

MORRIS. Text-Book of Anatomy. Second Edition. 790 Illustrations, many in Colors. A complete Text-book. Edited by HENRY MORRIS, F.R.C.S., Surg. to, and Lect. on Anatomy at, Middlesex Hospital, assisted by J. BLAND SUTTON, F.R C.S., J. H. DAVIES-COLLEY, F.R.C.S., WM. J. WALSHAM, F.R.C.S., H. ST. JOHN BROOKS, M.D., R. MARCUS GUNN, F.R.C.S., ARTHUR HENSMAN, F.R.C.S., FREDERICK TREVES, F.R.C.S., WILLIAM ANDERSON, F.R.C.S., and Prof. W. H. A. JACOBSON. One Handsome Octavo Volume, with 790 Illustrations, of which many are printed in colors. Cloth, $6.00; Leather, $7.00; Half Russia, $8.00

"Taken as a whole, we have no hesitation in according very high praise to this work. It will rank, we believe, with the leading Anatomies. The illustrations are handsome and the printing is good."—*Boston Medical and Surgical Journal.*

"The work as a whole is filled with practical ideas, and the salient points of the subject are properly emphasized. The surgeon will be particularly edified by the section on the topographical anatomy, which is full to repletion of excellent and useful illustrations."—*The Medical Record, New York.*

Handsome circular, with sample pages and colored illustrations, will be sent free to any address.

Renal Surgery. With Special Reference to Stone in the Kidney and Ureter, and to the Surgical Treatment of Calculous Anuria, together with a Critical Examination of Subparietal Injuries of the Ureter. Illustrated. 8vo. Cloth, $2.00

MORTON on Refraction of the Eye. Its Diagnosis and the Correction of its Errors. With Chapter on Keratoscopy, and Test Types. By A. MORTON, M.B. Sixth Edition, Revised and Enlarged. Cloth, $1.00

MOULLIN. Surgery. Third Edition, by Hamilton. A Complete Text-book. By C. W. MANSELL MOULLIN, M.A., M.D. (Oxon.), F.R.C.S., Surgeon and Lecturer on Physiology to the London Hospital; formerly Radcliffe Traveling Fellow and Fellow of Pembroke College, Oxford. Third American Edition. Revised and edited by JOHN B. HAMILTON, M.D., LL.D., Professor of the Principles of Surgery and Clinical Surgery, Rush Medical College, Chicago; Professor of Surgery, Chicago Polyclinic; Surgeon, formerly Supervising Surgeon-General, U. S. Marine Hospital Service; Surgeon to Presbyterian Hospital; Consulting Surgeon to St. Joseph's Hospital and Central Free Dispensary, Chicago, etc. 600 Illustrations, over 200 of which are original, and many of which are printed in Colors. Royal Octavo. 1250 pages.

Handsomely bound in Cloth, $6.00; Leather, $7.00; Half Russia, $8.00

"The aim to make this valuable treatise practical by giving special attention to questions of treatment has been admirably carried out. Many a reader will consult the work with a feeling of satisfaction that his wants have been understood, and that they have been intelligently met. He will not look in vain for details, without proper attention to which he well knows that the highest success is impossible."—*The American Journal of Medical Sciences.*

Handsome circular, with sample pages and colored illustrations, will be sent to any address upon application.

Enlargement of the Prostate. Its Treatment and Radical Cure. Illustrated. Second Edition, Enlarged. Octavo. *Nearly Ready.*

Inflammation of the Bladder and Urinary Fever. Octavo. Cloth, $1.50

MURRELL. Massotherapeutics. Massage as a Mode of Treatment. By WM. MURRELL, M.D., F.R.C.P., Lecturer on Pharmacology and Therapeutics at Westminster Hospital. Sixth Edition. Revised. 12mo. *Preparing.*

What To Do in Cases of Poisoning. Eighth Edition, Enlarged and Revised. 64mo. Cloth, $1.00

MUTER. Practical and Analytical Chemistry. By JOHN MUTER, F.R.S., F.C.S., etc. Second American from the Eighth English Edition. Revised, to meet the requirements of American Medical and Pharmaceutical Colleges. 56 Illus. Cloth, $1.25

NAPHEYS' Modern Therapeutics. Ninth Revised Edition, Enlarged and Improved. In Two Handsome Volumes. Edited by ALLEN J. SMITH, M.D., Professor of Pathology, University of Texas, Galveston, late Ass't Demonstrator of Morbid Anatomy and Pathological Histology, Lecturer on Urinology, University of Pennsylvania; and J. AUBREY DAVIS, M.D., Ass't Demonstrator of Obstetrics, University of Pennsylvania; Ass't Physician to Home for Crippled Children, etc.

VOL. I.—**General Medicine and Diseases of Children.** Handsome Cloth binding, $4.00

VOL. II.—**General Surgery, Obstetrics, and Diseases of Women.** Handsome Cloth binding, $4.00

NEW SYDENHAM SOCIETY Publications. Three to Six Volumes published each year. *List of Volumes upon application.* Per annum, $8.00

NOTTER and FIRTH. The Theory and Practice of Hygiene. A Complete Treatise by J. LANE NOTTER, M.A., M.D., F.C.S., Fellow and Member of Council of the Sanitary Institute of Great Britain; Professor of Hygiene, Army Medical School; Examiner in Hygiene, University of Cambridge, etc., and R. H. FIRTH, F.R.C.S., Assistant Professor of Hygiene, Army Medical School, Netly. Illustrated by 10 Lithographic Plates and 135 other Illustrations, and including many Useful Tables. Octavo. 1034 pages. Cloth, $7.00

*** This volume is based upon Parkes' Practical Hygiene, which will not be published hereafter.

OETTEL. Practical Exercises in Electro-Chemistry. By DR. FELIX OETTEL. Authorized Translation by EDGAR F. SMITH, M.A., Professor of Chemistry, University of Pennsylvania. Illustrated. Cloth, .75

Introduction to Electro-Chemical Experiments. Illustrated. By same Author and Translator. Cloth, .75

OHLEMANN. Ocular Therapeutics for Physicians and Students. By M. OHLEMANN, M.D., late Physician in the Ophthalmological Clinical Institute, Royal Prussian University of Berlin, etc. Translated and Edited by CHARLES A. OLIVER, A.M., M.D., Attending Surgeon to Wills Eye Hospital; Ophthalmic Surgeon to the Philadelphia and to the Presbyterian Hospitals; Fellow of the College of Physicians of Philadelphia, etc. 12mo. Cloth, $1.75

ORMEROD. Diseases of Nervous System, Student's Guide to. By J. A. ORMEROD, M.D. (Oxon.), F.R.C.P., Physician to National Hospital for Paralyzed and Epileptic and to City of London Hospital for Diseases of the Chest, etc. With 66 Wood Engravings. 12mo. Cloth, $1.00

OSGOOD. The Winter and Its Dangers. By HAMILTON OSGOOD, M.D. Cloth, .40

OSLER. Cerebral Palsies of Children. A Clinical Study. By WILLIAM OSLER, M.D., F.R.C.P. (Lond.), Professor of Medicine, Johns Hopkins University, etc. 8vo. Cloth, $2.00

Chorea and Choreiform Affections. 8vo. Cloth, $2.00

OSTROM. Massage and the Original Swedish Movements. Their Application to Various Diseases of the Body. A Manual for Students, Nurses and Physicians. By KURRE W. OSTROM, from the Royal University of Upsala, Sweden; Instructor in Massage and Swedish Movements in the Hospital of the University of Pennsylvania, and in the Philadelphia Polyclinic and College for Graduates in Medicine, etc. Fourth Edition, Enlarged. With 105 Illustrations, many of which were drawn especially for this purpose. 12mo. Cloth, $1.00

PACKARD'S Sea Air and Sea Bathing. By JOHN H. PACKARD, M.D. Cloth, .40

PARKES' Practical Hygiene. By EDWARD A. PARKES, M.D. Superseded by "Notter and Firth" Treatise on Hygiene. See previous page.

PARKES. Hygiene and Public Health. A Practical Manual. By LOUIS C. PARKES, M.D., D.P.H. Lond. Univ., Lect. on Public Health at St. George's Hospital, Medical Officer of Health, Parish of Chelsea, London, etc. Fifth Edition, Enlarged and Revised. 80 Illustrations. 12mo. Cloth, $2.50

The Elements of Health. An Introduction to the Study of Hygiene. Illustrated. Cloth, $1.25

PARRISH'S Alcoholic Inebriety. From a Medical Standpoint, with Illustrative Cases from the Clinical Records of the Author. By JOSEPH PARRISH, M.D., President of the Amer. Assoc. for Cure of Inebriates. Cloth, $1.00

PHILLIPS. Spectacles and Eyeglasses, Their Prescription and Adjustment. By R. J. PHILLIPS, M.D., Instructor on Diseases of the Eye, Philadelphia Polyclinic, Ophthalmic Surgeon, Presbyterian Hospital. Second Edition, Revised and Enlarged. 49 Illustrations. 12mo. Cloth, $1.00

"This little work now appears in the form of a revised second edition of 101 pages. It is of convenient size and is excellently printed. The book is issued as an aid to those who prescribe and who sell eyeglasses and spectacles, for the purpose of enabling them to reach the most satisfactory and beneficial results in the adjustment of lenses to the eyes of patients. Since the proper adjustment of spectacles and eyeglasses is of very great importance, it is desirable that the rules and suggestions contained in this little volume should be familiar to every oculist and optician."—*The Medical Record, New York.*

Digitized by Google

PHYSICIAN'S VISITING LIST. Published Annually. Forty-eighth Year (1899) of its Publication.

Hereafter all styles will contain the interleaf or special memoranda page, except the Monthly Edition, and the sizes for 75 and 100 Patients will come in two volumes only. **The Sale of this Visiting List increased over ten per cent. in 1896.**

REGULAR EDITION.

For 25 Patients weekly.				Tucks, pocket and pencil, Gilt Edges,					$1.00
50	"	"		"	"	"	"	"	1.25
50	"	" 2 vols.	Jan. to June / July to Dec.	"	"	"	"	"	2.00
75	"	" 2 vols.	Jan. to June / July to Dec.	"	"	"	"	"	2.00
100	"	" 2 vols.	Jan. to June / July to Dec.	"	"	"	"	"	2.25

Perpetual Edition, without Dates and with Special Memorandum Pages.

For 25 Patients, interleaved, tucks, pocket and pencil, ... $1.25
50 " " " " " " 1.50

Monthly Edition, without Dates. Can be commenced at any time and used until full. Requires only one writing of patient's name for the whole month. Plain binding, without Flap or Pencil, .75. Leather cover, Pocket and Pencil, $1.00

EXTRA Pencils will be sent, postpaid, for 25 cents per half dozen.

☞ This List combines the several essential qualities of strength, compactness, durability and convenience. It is made in all sizes and styles to meet the wants of all physicians. It is not an elaborate, complicated system of keeping accounts, but a plain, simple record, that may be kept with the least expenditure of time and trouble—hence its popularity. A special circular, descriptive of contents will be sent upon application.

POTTER. A Handbook of Materia Medica, Pharmacy, and Therapeutics, including the Action of Medicines, Special Therapeutics of Disease, Official and Practical Pharmacy, and Minute Directions for Prescription Writing, etc. Including over 600 Prescriptions and Formulæ. By SAMUEL O. L. POTTER, M.A., M.D., M.R.C.P. (Lond.), Professor of the Principles and Practice of Medicine and Clinical Medicine in the College of Physicians and Surgeons, San Francisco; Brigade Surgeon U. S. Vol. Seventh Edition, Revised and Enlarged. 8vo. *With Thumb Index in each copy.* Cloth, $5.00; Leather, $6.00; Half Russia, $7.00

Compend of Anatomy, including **Visceral Anatomy.** Sixth Edition. Revised, and greatly Enlarged. With 16 Lithographed Plates and 117 other Illustrations. *Being No. 1 ? Quiz-Compend ? Series.* Cloth, .80; Interleaved for taking Notes, $1.25

Compend of Materia Medica, Therapeutics and Prescription Writing, with special reference to the Physiological Action of Drugs. Sixth Revised and Improved Edition, with Index, based upon U. S. P. 1890. *Being No. 6 ? Quiz-Compend ? Series.* Cloth, .80. Interleaved for taking Notes, $1.25

Speech and Its Defects. Considered Physiologically, Pathologically and Remedially; being the Lea Prize Thesis of Jefferson Medical College, 1882. Revised and Corrected. 12mo. Cloth, $1.00

POWELL. Diseases of the Lungs and Pleuræ, Including Consumption. By R. DOUGLAS POWELL, M.D., F.R.C.P., Physician to the Middlesex Hospital, and Consulting Physician to the Hospital for Consumption and Diseases of the Chest at Brompton. Fourth Edition. With Colored Plates and Wood Engravings. 8vo. Cloth, $4.00

POWER. Surgical Diseases of Children and their Treatment by Modern Methods. By D'Arcy Power, M.A., F.R.C.S. (Eng.), Demonstrator of Operative Surgery, St. Bartholomew's Hospital; Surgeon to the Victoria Hospital for Children. Illustrated. 12mo. Cloth, $2.50

PRESTON. Hysteria and Certain Allied Conditions. Their Nature and Treatment. With special reference to the application of the Rest Cure, Massage, Electro-therapy, Hypnotism, etc. By GEORGE J. PRESTON, M.D., Professor of Diseases of the Nervous System, College of Physicians and Surgeons, Baltimore; Visiting Physician to the City Hospital; Consulting Neurologist to Bay View Asylum and the Hebrew Hospital; Member American Neurological Association, etc. With Illustrations. 12mo. Cloth, $2.00

PRITCHARD. Handbook of Diseases of the Ear. By URBAN PRITCHARD, M.D., F.R.C.S., Professor of Aural Surgery, King's College, London, Aural Surgeon to King's College Hospital, Senior Surgeon to the Royal Ear Hospital, etc. Third Edition, Enlarged. Many Illustrations and Formulæ. 12mo. Cloth, $1.50

PROCTOR'S Practical Pharmacy. Lectures on Practical Pharmacy. With Wood Engravings and 32 Lithographic Fac-simile Prescriptions. By BARNARD S. PROCTOR. Third Edition. Revised and with elaborate Tables of Chemical Solubilities, etc. Cloth, $3.00

REESE'S Medical Jurisprudence and Toxicology. A Text-book for Medical and Legal Practitioners and Students. By JOHN J. REESE, M.D., Editor of Taylor's Jurisprudence, Professor of the Principles and Practice of Medical Jurisprudence, including Toxicology, in the University of Pennsylvania Medical Department. Fifth Edition. Revised and Edited by HENRY LEFFMANN, M.D., Pathological Chemist, Jefferson Medical College Hospital; Chemist, State Board of Health; Professor of Chemistry, Woman's Medical College of Penna., etc. 12mo. 645 pages. Cloth, $3.00; Leather, $3.50

"To the student of medical jurisprudence and toxicology it is invaluable, as it is concise, clear, and thorough in every respect."—*The American Journal of the Medical Sciences.*

REEVES. Medical Microscopy. Illustrated. A Handbook for Physicians and Students, including Chapters on Bacteriology, Neoplasms, Urinary Examination, etc. By JAMES E. REEVES, M.D., Ex-President American Public Health Association, Member Association American Physicians, etc. Numerous Illustrations, some of which are printed in colors. 12mo. Handsome Cloth, $2.50

RÉGIS. Mental Medicine. A Practical Manual. By DR. E. RÉGIS, formerly Chief of Clinique of Mental Diseases, Faculty of Medicine of Paris; Physician of the Maison de Santé de Castel d'Andorte; Professor of Mental Diseases, Faculty of Medicine, Bordeaux, etc. With a Preface by M. BENJAMIN BALL, Clinical Professor of Mental Diseases, Faculty of Medicine, Paris. Authorized Translation from the Second Edition by H. M. BANNISTER, M.D., late Senior Assistant Physician, Illinois Eastern Hospital for the Insane, etc. With an Introduction by the Author. 12mo. 692 pages. Cloth, $2.00

RICHARDSON. Long Life, and How to Reach It. By J. G. RICHARDSON, Prof. of Hygiene, University of Pennsylvania. Cloth, .40

RICHARDSON'S Mechanical Dentistry. A Practical Treatise on Mechanical Dentistry. By JOSEPH RICHARDSON, D.D.S. Seventh Edition. Thoroughly Revised and in many parts Rewritten by DR. GEO. W. WARREN, Chief of the Clinical Staff, Pennsylvania College of Dental Surgery, Philadelphia. With 691 Illustrations, many of which are from original Wood Engravings. Octavo. 675 pages. Cloth, $5.00; Leather, $6.00; Half Russia, $7.00

ROBERTS. Practice of Medicine. The Theory and Practice of Medicine. By FREDERICK ROBERTS, M.D., Professor of Therapeutics at University College, London. Ninth Edition, with Illustrations. 8vo. Cloth, $4.50; Leather, $5.50

ROBERTS. Fractures of the Radius. A Clinical, Pathological, and Experimental Study. By JOHN B. ROBERTS, M.D., Professor of Anatomy and Surgery in the Philadelphia Polyclinic, etc. 33 Illustrations. 8vo. Cloth, $1.00

Digitized by Google

RICHTER'S Inorganic Chemistry. A Text-book for Students. By Prof. VICTOR VON RICHTER, University of Breslau. Fourth American, from Sixth German Edition. Authorized Translation by EDGAR F. SMITH, M.A., PH.D., Prof. of Chemistry, University of Pennsylvania, Member of the Chemical Societies of Berlin and Paris. 89 Illustrations and a Colored Plate. 12mo. Cloth, $1.75

Organic Chemistry. The Chemistry of the Carbon Compounds. Third American Edition, translated from the Eighth German by EDGAR F. SMITH, M.A., PH.D., Professor of Chemistry, University of Pennsylvania. Revised and Enlarged. Illus. 2 vols. 12mo. Vol. I. Aliphatic Series. 625 pages. Cloth, $3.00

Vol. II. Carbocylic Series. *In Press.*

ROBINSON. Latin Grammar of Pharmacy and Medicine. By D. H. ROBINSON, PH.D., Professor of Latin Language and Literature, University of Kansas. Introduction by L. E. SAYRE, PH.G., Professor of Pharmacy in, and Dean of the Dept. of Pharmacy, University of Kansas. Third Edition. Revised with the help of Prof. L. E. SAYRE, of University of Kansas, and Dr. CHARLES RICE, of the College of Pharmacy of the City of New York. 12mo. Cloth, $1.75

ST. CLAIR. Medical Latin. Designed expressly for the Elementary Training of Medical Students. By W. T. ST. CLAIR, Instructor in Latin in the Kentucky School of Medicine and in the Louisville Male High School. 12mo. Cloth, $1.00

SANSOM. Diseases of The Heart. The Diagnosis and Pathology of Diseases of the Heart and Thoracic Aorta. By A. ERNEST SANSOM, M.D., F.R.C.P., Physician to the London Hospital, etc. With Illustrations. 8vo. Cloth, $6.00

SAYRE. Organic Materia Medica and Pharmacognosy. An Introduction to the Study of the Vegetable Kingdom and the Vegetable and Animal Drugs. Comprising the Botanical and Physical Characteristics, Source, Constituents, and Pharmacopœial Preparations. With Chapters on Synthetic Organic Remedies, Insects Injurious to Drugs, and Pharmacal Botany. By L. E. SAYRE, PH.G., Professor of Pharmacy and Materia Medica in the University of Kansas, Member of the Committee of Revision of the U. S. Pharmacopœia, 1890. A Glossary and 543 Illustrations. Second Edition. *In Press.*

SCHAMBERG. Compend of Diseases of the Skin. By JAY F. SCHAMBERG Associate in Skin Diseases, Philadelphia Polyclinic; Quiz-Master at University of Pennsylvania. 99 Illustrations. Cloth, .80. Interleaved, $1.25

SCHREINER. Diet List. Arranged in the Form of a Chart on which Articles of Diet can be indicated for any Disease. By E. R. SCHREINER, M.D, Ass't Dem. of Physiology, University of Penna. Put up in Pads of 50 with Pamphlet of Specimen Dietaries. Per Pad, .75

SCHULTZE. Obstetrical Diagrams. Being a Series of 20 Colored Lithograph Charts, imperial map size, of Pregnancy and Midwifery, with accompanying explanatory (German) text, illustrated by wood-cuts. By DR. B. S. SCHULTZE, Professor of Obstetrics, University of Jena. Second Revised Edition.
Price, in Sheets, $26.00; Mounted on Rollers, Muslin Backs, $36.00

SCOVILLE. The Art of Compounding. A Text-book for Students and a Reference Book for Pharmacists. By WILBUR L. SCOVILLE, PH.G., Professor of Applied Pharmacy and Director of the Pharmaceutical Laboratory in the Massachusetts College of Pharmacy. Second Edition, Enlarged and Improved.
Cloth, $2.50; Sheep, $3.50; Half Russia, $4.50

SEWELL. Dental Surgery, including Special Anatomy and Surgery. By HENRY SEWELL, M.R.C.S., L.D.S. President Odontological Society of Great Britain. 3d Edition, greatly enlarged, with about 200 Illustrations. Cloth, $2.00

SHAWE. Notes for Visiting Nurses, and all those interested in the working and organization of District, Visiting, or Parochial Nurse Societies. By ROSALIND GILLETTE SHAWE, District Nurse for the Brooklyn Red Cross Society. With an Appendix explaining the organization and working of various Visiting and District Nurse Societies, by HELEN C. JENKS, of Philadelphia. 12mo. Cloth, $1.00

SMITH. Abdominal Surgery. Being a Systematic Description of all the Principal Operations. By J. GREIG SMITH, M.A., F.R.S.E., Surg. to British Royal Infirmary. 224 Illustrations. Sixth Edition. Enlarged and Thoroughly Revised by JAMES SWAIN, M.D. (Lond.), F.R.C.S., Professor of Surgery, University College, Bristol, etc. 2 Volumes. Octavo. Cloth, $10.00

SMITH. Electro-Chemical Analysis. By EDGAR F. SMITH, Professor of Chemistry, University of Pennsylvania. Second Edition, Revised and Enlarged. 27 Illustrations. 12mo. Cloth, $1.25

*** *See also Oettel and Richter.*

SMITH and KELLER. Experiments. Arranged for Students in General Chemistry. By EDGAR F. SMITH, Professor of Chemistry, University of Pennsylvania, and Dr. H. F. KELLER, Professor of Chemistry, Philadelphia High School. Third Edition. 8vo. Illustrated. Cloth, .60

SMITH. Dental Metallurgy. A Manual. By ERNEST A. SMITH, F.C.S., Asst. Instructor in Metallurgy Royal College of Science, London. Illustrated. 12mo. Cloth, $1.75

SMITH. Wasting Diseases of Infants and Children. By EUSTACE SMITH, M.D., F.R.C.P., Physician to the East London Hospital for Children, etc. Sixth Edition, Revised. Cloth, $2.00

STAMMER. Chemical Problems, with Explanations and Answers. By KARL STAMMER. Translated from the Second German Edition, by Prof. W. S. HOSKINSON, A.M., Wittenberg College, Springfield, Ohio. 12mo. Cloth. .50

STARLING. Elements of Human Physiology. By ERNEST H. STARLING, M.D. LOND., M.R.C.P., Joint Lecturer on Physiology at Guy's Hospital, London, etc. With 100 Illustrations. 12mo. 437 pages. Cloth, $1.00

STARR. The Digestive Organs in Childhood. Second Edition. The Diseases of the Digestive Organs in Infancy and Childhood. With Chapters on the Investigation of Disease and the Management of Children. By LOUIS STARR, M.D., late Clinical Prof. of Diseases of Children in the Hospital of the University of Penn'a; Physician to the Children's Hospital, Phila. Second Edition. Revised and Enlarged. Illustrated by two Colored Lithograph Plates and numerous Wood Engravings. Crown Octavo. Cloth, $2.00

The Hygiene of the Nursery, including the General Regimen and Feeding of Infants and Children, and the Domestic Management of the Ordinary Emergencies of Early Life, Massage, etc. Sixth Edition. Enlarged. 25 Illustrations. 12mo. 280 pages. Cloth, $1.00

STEARNS. Lectures on Mental Diseases. By HENRY PUTNAM STEARNS, M.D., Physician Superintendent at the Hartford Retreat, Lecturer on Mental Diseases in Yale University, Member of the American Medico-Psychological Ass'n, Honorary Member of the British Medico-Pyschological Society. With a Digest of Laws of the Various States Relating to Care of Insane. Illustrated. Cloth, $2.75; Sheep, $3.25

STEVENSON and MURPHY. A Treatise on Hygiene. By Various Authors. Edited by THOMAS STEVENSON, M.D., F.R.C.P., Lecturer on Chemistry and Medical Jurisprudence at Guy's Hospital, London, etc., and SHIRLEY F. MURPHY, Medical Officer of Health to the County of London. In Three Octavo Volumes.

Vol. I. With Plates and Wood Engravings. Octavo. Cloth, $6.00
Vol. II. With Plates and Wood Engravings. Octavo. Cloth, $6.00
Vol. III. Sanitary Law. Octavo. Cloth, $5.00

*** *Special Circular upon application.*

STEWART'S Compend of Pharmacy. Based upon "Remington's Text-Book of Pharmacy." By F. E. STEWART, M.D., PH.G., Quiz-Master in Chem. and Theoretical Pharmacy, Phila. College of Pharmacy; Lect. in Pharmacology, Jefferson Medical College. Fifth Ed. Revised in accordance with U. S. P., 1890. Complete tables of Metric and English Weights and Measures. *? Quiz-Compend ? Series.* Cloth, .80; Interleaved for the addition of notes, $1.25

STIRLING. Outlines of Practical Physiology. Including Chemical and Experimental Physiology, with Special Reference to Practical Medicine. By W. STIRLING, M.D., Sc.D., Professor of Physiology and Histology, Owens College, Victoria University, Manchester. Examiner in Physiology, Universities of Edinburgh and London. Third Edition. 289 Illustrations. Cloth, $2.00

STIRLING. Outlines of Practical Histology. 368 Illustrations. Second Edition. Revised and Enlarged, with new Illustrations. 12mo. Cloth, $2.00

STÖHR. Text-Book of Histology, Including the Microscopical Technic. By DR. PHILIPP STÖHR, Professor of Anatomy at University of Würzburg. Authorized Translation by EMMA L. BILLSTEIN, M.D., Demonstrator of Histology and Embryology, Woman's Medical College of Pennsylvania. Edited, with Additions, by DR. ALFRED SCHAPER, Demonstrator of Histology and Embryology, Harvard Medical School, Boston. Second American from the Eighth German Edition, Enlarged and Revised. 292 Illustrations. Octavo. Cloth, $3.00

STRAHAN. Extra-Uterine Pregnancy. The Diagnosis and Treatment of Extra-Uterine Pregnancy. Being the Jenks Prize Essay of the College of Physicians of Philadelphia. By JOHN STRAHAN, M.D. (Univ. of Ireland), late Res. Surgeon Belfast Union Infirmary and Fever Hospital. Octavo. Cloth, .75

SUTTON'S Volumetric Analysis. A Systematic Handbook for the Quantitative Estimation of Chemical Substances by Measure, Applied to Liquids, Solids and Gases. Adapted to the Requirements of Pure Chemical Research, Pathological Chemistry, Pharmacy, Metallurgy, Photography, etc., and for the Valuation of Substances Used in Commerce, Agriculture, and the Arts. By FRANCIS SUTTON, F.C.S. Seventh Edition, Revised and Enlarged, with 112 Illustrations. 8vo. Cloth, $4.50

SWAIN. Surgical Emergencies, together with the Emergencies Attendant on Parturition and the Treatment of Poisoning. A Manual for the Use of Student, Practitioner, and Head Nurse. By WILLIAM PAUL SWAIN, F.R.C.S., Surgeon to the South Devon and East Cornwall Hospital, England. Fifth Edition. 12mo. 149 Illustrations. Cloth, $1.75

SWANZY. Diseases of the Eye and their Treatment. A Handbook for Physicians and Students. By HENRY R. SWANZY, A.M., M.B., F.R.C.S.I., Surgeon to the National Eye and Ear Infirmary; Ophthalmic Surgeon to the Adelaide Hospital, Dublin. Sixth Edition, Thoroughly Revised and Enlarged. 158 Illustrations, one Plain Plate, and a Zephyr Test Card. 12mo. Cloth, $3.00

"Is without doubt the most satisfactory manual we have upon diseases of the eye. It occupies the middle ground between the students' manuals, which are too brief and concise, and the encyclopedic treatises, which are too extended and detailed to be of special use to the general practitioner."—*Chicago Medical Recorder.*

SYMONDS. Manual of Chemistry, for Medical Students. By BRANDRETH SYMONDS, A.M., M.D., Ass't Physician Roosevelt Hospital, Out-Patient Department; Attending Physician Northwestern Dispensary, New York. Second Edition. 12mo. Cloth, $2.00

TAFT. Index of Dental Periodical Literature. By JONATHAN TAFT, D.D.S. 8vo. Cloth, $2.00

TALBOT. Irregularities of the Teeth, and Their Treatment. By EUGENE S. TALBOT, M.D., Professor of Dental Surgery Woman's Medical College, and Lecturer on Dental Pathology in Rush Medical College, Chicago. Second Edition, Revised. Octavo. 234 Illustrations. 261 pages. Cloth, $3.00

TANNER'S Memoranda of Poisons and their Antidotes and Tests. By THOS. HAWKES TANNER, M.D., F.R.C.P. 7th American, from the Last London Edition. Revised by JOHN J. REESE, M.D., Professor Medical Jurisprudence and Toxicology in the University of Pennsylvania. 12mo. Cloth, .75

TAYLOR. Practice of Medicine. A Manual. By FREDERICK TAYLOR, M.D., Physician to, and Lecturer on Medicine at, Guy's Hospital, London; Physician to Evelina Hospital for Sick Children, and Examiner in Materia Medica and Pharmaceutical Chemistry, University of London. Fifth Edition. Cloth, $4.00

TAYLOR AND WELLS. Diseases of Children. A Manual for Students and Physicians. By JOHN MADISON TAYLOR, A.B., M.D., Professor of Diseases of Children, Philadelphia Polyclinic; Assistant Physician to the Children's Hospital and to the Orthopedic Hospital; Consulting Physician to the Elwyn and the Vineland Training Schools for Feeble-Minded Children; Neurologist to the Howard Hospital, etc.; and WILLIAM H. WELLS, M.D., Adjunct-Professor of Obstetrics and Diseases of Infancy in the Philadelphia Polyclinic; late Assistant Demonstrator of Clinical Obstetrics and Diseases of Infancy in Jefferson Medical College. With 8 Plates and numerous other Illustrations. 12mo. 743 pages. Cloth, $4.00

SYNOPSIS OF CONTENTS.—Physiology of the Infant and Child—Diseases Occurring At or Near Birth—General Hygiene of Infants and Children—Feeding and Food of Infants and Children—The Breeds of Cows Best Adapted for Infant Feeding—Diet of Children; Artificial Foods; Recipes, etc.—Diseases of the Digestive Organs—Diseases of the Peritoneum—Diseases of the Liver—Diseases of the Genito-Urinary System—Diseases of the Genital Organs—Diseases of the Blood—General Diseases—Diseases of the Heart—Diseases of the Respiratory Organs—Diseases of the Nervous System—The Acute Infectious Diseases—Diseases of the Skin—General Considerations on Physical Development—Diseases and Accidents Requiring Surgical Procedures.

TEMPERATURE Charts for Recording Temperature, Respiration, Pulse, Day of Disease, Date, Age, Sex, Occupation, Name, etc. Put up in pads; each .50

THOMPSON. Urinary Organs. Diseases of the Urinary Organs. Containing 32 Lectures. By Sir HENRY THOMPSON, F.R.C.S., Emeritus Professor of Clinical Surgery in University College. Eighth London Edition. 121 Illustrations. Octavo. 470 pages. Cloth, $3.00

THORINGTON. Retinoscopy (The Shadow Test) in the Determination of Refraction at One Metre Distance with the Plane Mirror. By JAMES THORINGTON, M.D., Adjunct Professor of Diseases of the Eye in the Philadelphia Polyclinic; Assistant Surgeon Wills Eye Hospital; Ophthalmologist to the Elwyn and Vineland Training Schools; Lecturer on the Anatomy, Physiology, and Care of the Eyes in the Philadelphia Manual Training Schools, etc. With 38 Illustrations, several of which are Colored. Third Edition, Enlarged. 12mo. Cloth, $1.00

Refraction and How to Refract. With many Illustrations, most of which are made from original Drawings. *In Press.*

TOMES' Dental Anatomy. A Manual of Dental Anatomy, Human and Comparative. By C. S. TOMES, D.D.S. 263 Illustrations. 5th Ed. 12mo. Cloth, $4.00

Dental Surgery. A System of Dental Surgery. By JOHN TOMES, F.R.S. Fourth Edition, Thoroughly Revised. By C. S. TOMES, D.D.S. With 289 Illustrations. 12mo. 717 pages. Cloth, $4.00

TRAUBE. Physico-Chemical Methods. By DR. J. TRAUBE, Privatdocent in the Technical High School of Berlin. Authorized Translation by W. D. HARDIN, Harrison Senior Fellow in Chemistry, University of Pennsylvania. With 97 Illustrations. 8vo. Cloth, $1.50

TREVES. German-English Medical Dictionary. By FREDERICK TREVES, F.R.C.S., assisted by DR. HUGO LANG, B.A. (Munich). 12mo. ½ Russia, $3.25

Physical Education, Its Effects, Value, Methods, etc. Cloth, .75

TUKE. Dictionary of Psychological Medicine. Giving the Definition, Etymology, and Synonyms of the Terms used in Medical Psychology, with the Symptoms, Pathology, and Treatment of the recognized forms of Mental Disorders, together with the Law of Lunacy in Great Britain and Ireland. Edited by D. HACK TUKE, M.D., LL.D., Examiner in Mental Physiology in the University of London. Two Volumes. Octavo. 1477 pages. Cloth, $10.00

"This is an elaborate and valuable contribution t the literature of medical psychology, and will be found a valuable work of reference. . . . A comprehensive standard book."—*The British Medical Journal.*

TURNBULL'S Artificial Anæsthesia. A Manual of Anesthetic Agents in the Treatment of Diseases also their Employment in Dental Surgery; Modes of Administration; Considering their Relative Risks; Tests of Purity; Treatment of Asphyxia; Spasms of the Glottis; Syncope, etc. By LAURENCE TURNBULL, M.D., PH.G., Aural Surgeon to Jefferson College Hospital, etc. Fourth Edition, Revised and Enlarged. 54 Illustrations. 12mo. Cloth, $2.50

TUSON. Veterinary Pharmacopœia, including the outlines of Materia Medica and Therapeutics. By RICHARD V. TUSON, late Professor at the Royal Veterinary College. Fifth Edition. Revised and Edited by JAMES BAYNE, F.C.S., Professor of Chemistry and Toxicology at the Royal Veterinary College. 12mo. Cloth, $2.25

TUSSEY. High Altitude Treatment for Consumption. The Principles or Guides for a Better Selection or Classification of Consumptives Amenable to High Altitude Treatment, and to the Selection of Patients who may be More Successfully Treated in the Environment to which They were Accustomed Previous to Their Illness. By A. EDGAR TUSSEY, M.D., Adjunct Professor of Diseases of the Chest in the Philadelphia Polyclinic and School for Graduates in Medicine, etc. 12mo. Cloth, $1.50

TYSON. The Practice of Medicine. A Text-Book for Physicians and Students, with Special Reference to Diagnosis and Treatment. By JAMES TYSON, M.D., Professor of Clinical Medicine in the University of Pennsylvania, Physician to the University and to the Philadelphia Hospitals, etc. With Colored Plates and many other Illustrations. 8vo. Cloth, $5.50; Leather, $6.50; Half Russia, $7.50

"Few teachers in the country can claim a longer apprenticeship in the laboratory and at the bedside, none a more intimate acquaintance with students, since in one capacity or another he has been associated with the University of Pennsylvania and the Philadelphia Hospital for nearly thirty years. Moreover, he entered medicine through the portal of pathology, a decided advantage in the writer of a text-book. . . . The typography is decidedly above works of this class issued from our publishing houses. There is no American Practice of the same attractive appearance. The print is unusually sharp and clear, and the quality of the paper particularly good. . . . It is a piece of good, honest work, carefully conceived and conscientiously carried out."—*University Medical Magazine.*

*** **Sample Pages and Illustrations Sent Free upon Application.**

Guide to the Examination of Urine. Ninth Edition. For the Use of Physicians and Students. With Colored Plate and Numerous Illustrations Engraved on Wood. Ninth Edition. Revised. 12mo. 276 pages. Cloth, $1.25

*** *A French translation of this book has recently appeared in Paris.*

Handbook of Physical Diagnosis. 3d Edition. Revised and Enlarged. With Colored and other Illustrations. 12mo. 278 pages. Cloth, $1.50

Cell Doctrine. Its History and Present State. Second Edition. Cloth, $1.50

UNITED STATES PHARMACOPŒIA. 1890. Seventh Decennial Revision. Cloth, $2.50 (Postpaid, $2.77); Sheep, $3.00 (Postpaid, $3.27); Interleaved, $4.00 (Postpaid, $4.50); printed on one side of page only. Unbound, $3.50 (Postpaid, $3.90).

Select Tables from the U. S. P. (1890). Being Nine of the Most Important and Useful Tables, printed on Separate Sheets. Carefully put up in Patent Envelope. .25

ULZER and FRAENKEL. Introduction to Chemical-Technical Analysis. By Prof. F. ULZER and Dr. A. FRAENKEL, Directors of the Testing Laboratory of the Royal Technological Museum, Vienna. Authorized Translation by HERMANN FLECK, Nat. Sc.D., Instructor in Chemistry and Chemical Technical Analysis in the John Harrison Laboratory of Chemistry, University of Pennsylvania, with an Appendix by the Translator relating to Food Stuffs, Asphaltum and Paint. 12 Illustrations. 8vo. Cloth, $1.25

VAN NÜYS on The Urine. Chemical Analysis of Healthy and Diseased Urine, Qualitative and Quantitative. By T. C. VAN NÜYS, Professor of Chemistry Indiana University. 39 Illustrations. Octavo. Cloth, $1.00

VAN HARLINGEN on Skin Diseases. A Practical Manual of Diagnosis and Treatment with special reference to Differential Diagnosis. By ARTHUR VAN HARLINGEN, M.D., Professor of Diseases of the Skin in the Philadelphia Polyclinic; Clinical Lecturer on Dermatology at Jefferson Medical College. Third Edition. Revised and Enlarged. With Formulæ and Illustrations, several being in Colors. 580 pages. Cloth, $2.75

"As would naturally be expected from the author, his views are sound, his information extensive, and in matters of practical detail the hand of the experienced physician is everywhere visible."—*The Medical News.*

VIRCHOW'S Post-mortem Examinations. A Description and Explanation of the Method of Performing them in the Dead-House of the Berlin Charité Hospital, with especial reference to Medico-legal Practice. By Prof. VIRCHOW. Translated by Dr. T. P. SMITH. Illustrated. Third Edition, with Additions. Cloth, .75

VOSWINKEL. Surgical Nursing. A Manual for Nurses. By BERTHA M. VOSWINKEL, Graduate Episcopal Hospital, Philadelphia; Nurse in Charge Children's Hospital, Columbus, O. Second Edition, Revised and Enlarged. 111 Illustrations. 12mo. Cloth, $1.00

WALKER. Students' Aid in Ophthalmology. By GERTRUDE A. WALKER, A.B., M.D., Clinical Instructor in Diseases of the Eye at Woman's Medical College of Pennsylvania. 40 Illustrations and Colored Plate. 12mo. Cloth, $1.50

WALSHAM. Surgery; its Theory and Practice. For Students and Physicians. By WM. J. WALSHAM, M.D., F.R.C.S., Senior Ass't Surg. to, and Dem. of Practical Surg. in, St. Bartholomew's Hospital, Surg. to Metropolitan Free Hospital, London. Sixth Edition, Revised and Enlarged. With 410 Engravings. Clo., $3.00

WARD. Notes on Massage; Including Elementary Anatomy and Physiology. By JESSIE M. WARD, Instructor in Massage in the Pennsylvania, Philadelphia, Jefferson, and Woman's Hospitals; Clinical Lecturer at Philadelphia Polyclinic, etc. 12mo. Interleaved. Paper Cover, $1.00

WARING. Practical Therapeutics. A Manual for Physicians and Students. By EDWARD J. WARING, M.D. Fourth Edition. Revised, Rewritten, and Rearranged. Crown Octavo. Cloth, $2.00; Leather, $3.00

WARREN. Compend Dental Pathology and Dental Medicine. Containing all the most noteworthy points of interest to the Dental Student and a Chapter on Emergencies. By GEO. W. WARREN, D.D.S., Clinical Chief, Penn'a College of Dental Surgery, Phila. Third Edition, Enlarged. Illustrated. *Being No. 13 ? Quiz-Compend ? Series.* 12mo. Cloth, .80

Interleaved for the addition of Notes, $1.25

Dental Prosthesis and Metallurgy. 129 Illustrations. Cloth, $1.25

WATSON on Amputations of the Extremities and Their Complications. By B. A. WATSON, M.D. 250 Illustrations. Cloth, $5.50

Concussions. An Experimental Study of Lesions arising from Severe Concussions. 8vo. Paper cover, $1.00

WELLS. Compend of Gynecology. By WM. H. WELLS, M.D., Instructor of Obstetrics, Jefferson Medical College, Philadelphia; Fellow of the College of Physicians of Philadelphia. 150 Illustrations. *? Quiz-Compend ? Series No. 7.* 12mo. Cloth, .80; Interleaved for Notes, $1.25

WESTLAND. The Wife and Mother. A Handbook for Mothers. By A. WESTLAND, M.D., late Resident Physician, Aberdeen Royal Infirmary. Clo. $1.50

WETHERED. Medical Microscopy. A Guide to the Use of the Microscope in Practical Medicine. By FRANK J. WETHERED, M.D., M.R.C.P., Demonstrator of Practical Medicine, Middlesex Hospital Medical School; Assistant Physician, late Pathologist, City of London Hospital for Diseases of Chest, etc. With a Colored Plate and 101 Illustrations. 406 Pages. 12mo. Cloth, $2.00

WEYL. Sanitary Relations of the Coal-Tar Colors. By THEODORE WEYL. Authorized Translation by HENRY LEFFMANN, M.D., PH.D. 12mo. 154 pages. Cloth, $1.25

Digitized by Google

WHITACRE. Laboratory Text-Book of Pathology. By HORACE J. WHITACRE, M.D., Demonstrator of Pathology, Medical College of Ohio, Cincinnati. Illustrated with 121 original Illustrations. 8vo. Cloth, $1.50

WHITE. The Mouth and Teeth. By J. W. WHITE, M.D., D.D.S. Cloth, .40

WHITE AND WILCOX. Materia Medica, Pharmacy, Pharmacology, and Therapeutics. A Handbook for Students. By W. HALE WHITE, M.D., F.R.C.P., etc., Physician to and Lecturer on Materia Medica and Therapeutics, Guy's Hospital; Examiner in Materia Medica to the Conjoint Board, etc. Fourth American Edition. Revised by REYNOLD W. WILCOX, M.A., M.D., LL.D., Professor of Clinical Medicine and Therapeutics at the New York Post-Graduate Medical School and Hospital; Visiting Physician St. Mark's Hospital; Assistant Visiting Physician Bellevue Hospital. Fourth Edition, thoroughly Revised. 12mo. 704 pages. Cloth, $3.00; Leather, $3.50

WILLIAMS. Manual of Bacteriology. By HERBERT U. WILLIAMS, M.D., Professor of Pathology and Bacteriology, Medical Department University of Buffalo. With 78 Illustrations. 12mo. Cloth, $1.50

WILSON. Handbook of Hygiene and Sanitary Science. By GEORGE WILSON, M.A., M.D., F.R.S.E., Medical Officer of Health for Mid-Warwickshire, England. With Illustrations. Eighth Edition. 12mo. Cloth, $3.00

WILSON. The Summer and its Diseases. By JAMES C. WILSON, M.D., Prof. of the Practice of Med. and Clinical Medicine, Jefferson Med. Coll., Phila. Cloth, .40

WILSON. System of Human Anatomy. 11th Revised Edition. Edited by HENRY EDWARD CLARK, M.D., M.R.C.S. 492 Illustrations, 26 Colored Plates, and a Glossary of Terms. Thick 12mo. Cloth, $5.00

WINCKEL. Text-Book of Obstetrics; Including the Pathology and Therapeutics of the Puerperal State. By Dr. F. WINCKEL, Professor of Gynecology and Director of the Royal University Clinic for Women in Munich. Authorized Translation by J. CLIFTON EDGAR, A.M., M.D., Adjunct Professor to the Chair of Obstetrics, Medical Department, University City of New York. With nearly 200 Handsome Illustrations, the majority of which are original with this work. Octavo. Cloth, $5.00; Leather, $6.00

WINDLE. Surface Anatomy and Landmarks. By B. C. A. WINDLE, D.Sc., M.D., Professor of Anatomy in Mason College, Birmingham, etc. Second Edition, Revised by T. MANNERS SMITH, M.R.C.S., with Colored and other Illustrations. 12mo. Cloth, $1.00

WOAKES. Deafness, Giddiness, and Noises in the Head. By EDWARD WOAKES, M.D., Senior Aural Surgeon, London Hospital; assisted by CLAUD WOAKES, M.R.C.S., Assistant Surgeon to the London Throat Hospital. Fourth Edition. Illustrated. 12mo. Cloth, $2.00

WOOD. Brain Work and Overwork. By Prof. H. C. WOOD, Clinical Professor of Nervous Diseases, University of Pennsylvania. 12mo. Cloth, .40

WOODY. Essentials of Chemistry and Urinalysis. By SAM E. WOODY, A.M., M.D., Professor of Chemistry and Public Hygiene, and Clinical Lecturer on Diseases of Children, in the Kentucky School of Medicine. Fourth Edition. Illustrated. 12mo. *In Press.*

Digitized by Illinois College of Pharmacy

From the Southern Clinic.

"We know of no series of books issued by any house that so fully meets our approval as these ? Quiz-Compends ?. They are well arranged, full, and concise, and are really the best line of text-books that could be found for either student or practitioner."

BLAKISTON'S ? QUIZ-COMPENDS ?

The Best Series of Manuals for the Use of Students.

Price of each, Cloth, .80. Interleaved for taking Notes, $1.25.

☞ These Compends are based on the most popular text-books and the lectures of prominent professors, and are kept constantly revised, so that they may thoroughly represent the present state of the subjects upon which they treat. The authors have had large experience as Quiz-Masters and attachés of colleges, and are well acquainted with the wants of students. They are arranged in the most approved form, thorough and concise, containing over 600 fine illustrations, inserted wherever they could be used to advantage. Can be used by students of *any* college, and contain information nowhere else collected in such a condensed, practical shape.

ILLUSTRATED CIRCULAR FREE.

No. 1. HUMAN ANATOMY. Sixth Revised and Enlarged Edition. Including Visceral Anatomy. Can be used with either Morris's or Gray's Anatomy. 117 Illustrations and 16 Lithographic Plates of Nerves and Arteries, with Explanatory Tables, etc. By SAMUEL O. L. POTTER, M.D., Professor of the Practice of Medicine, College of Physicians and Surgeons, San Francisco; late A. A. Surgeon, U. S. Army.

No. 2. PRACTICE OF MEDICINE. Part I. Sixth Edition, Revised, Enlarged, and Improved. By DAN'L E. HUGHES, M.D., Physician-in-Chief, Philadelphia Hospital, late Demonstrator of Clinical Medicine, Jefferson Medical College, Philadelphia.

No. 3. PRACTICE OF MEDICINE. Part II. Sixth Edition, Revised, Enlarged, and Improved. Same author as No. 2.

No. 4. PHYSIOLOGY. Ninth Edition, with new Illustrations and a table of Physiological Constants. Enlarged and Revised. By A. P. BRUBAKER, M.D., Professor of Physiology and General Pathology in the Pennsylvania College of Dental Surgery; Demonstrator of Physiology, Jefferson Medical College, Philadelphia.

No. 5. OBSTETRICS. Sixth Edition. By HENRY G. LANDIS, M.D. Revised and Edited by WM. H. WELLS, M.D., Instructor of Obstetrics, Jefferson Medical College, Philadelphia. Enlarged. 3 Plates and 47 other Illustrations.

No. 6. MATERIA MEDICA, THERAPEUTICS, AND PRESCRIPTION WRITING. Sixth Revised Edition (U. S. P. 1890). By SAMUEL O. L. POTTER, M.D., Professor of the Practice of Medicine, College of Physicians and Surgeons, San Francisco.

No. 7. GYNECOLOGY. By WM. H. WELLS, M.D., Instructor of Obstetrics, Jefferson Medical College, Philadelphia. 150 Illustrations.

No. 8. DISEASES OF THE EYE AND REFRACTION. A New Book. Including Treatment and Surgery and a Section on Local Therapeutics. By GEORGE M. GOULD, M.D., and W. L. PYLE, M.D. With Formulæ, Glossary, several useful Tables, and 111 Illustrations, several of which are colored.

No. 9. SURGERY, Minor Surgery, and Bandaging. Fifth Edition, Enlarged and Improved. By ORVILLE HORWITZ, B.S., M.D., Clinical Professor of Genito-Urinary Surgery and Venereal Diseases in Jefferson Medical College; Surgeon to Philadelphia Hospital, etc. With 98 Formulæ and 167 Illustrations.

No. 10. MEDICAL CHEMISTRY. Fourth Edition. Including Urinalysis, Animal Chemistry, Chemistry of Milk, Blood, Tissues, the Secretions, etc. By HENRY LEFFMANN, M.D., Professor of Chemistry in Pennsylvania College of Dental Surgery and in the Woman's Medical College, Philadelphia.

No. 11. PHARMACY. Fifth Edition. Based upon Prof. Remington's Text-Book of Pharmacy. By F. E. STEWART, M.D., PH.G., late Quiz-Master in Pharmacy and Chemistry, Philadelphia College of Pharmacy; Lecturer at Jefferson Medical College.

No. 12. VETERINARY ANATOMY AND PHYSIOLOGY. Illustrated. By WM. R. BALLOU, M.D., Professor of Equine Anatomy at New York College of Veterinary Surgeons; Physician to Bellevue Dispensary, etc. With 29 graphic Illustrations.

No. 13. DENTAL PATHOLOGY AND DENTAL MEDICINE. Third Edition, Illustrated. Containing all the most noteworthy points of interest to the Dental Student and a Section on Emergencies. By GEO. W. WARREN, D.D.S., Chief of Clinical Staff, Pennsylvania College of Dental Surgery, Philadelphia.

No. 14. DISEASES OF CHILDREN. Colored Plate. By MARCUS P. HATFIELD, Professor of Diseases of Children, Chicago Medical College. Second Edition, Enlarged.

No. 15. GENERAL PATHOLOGY AND MORBID ANATOMY. 91 Illustrations. By H. NEWBERRY HALL, PH.G., M.D., Professor of Pathology and Medical Chemistry, Chicago Post-Graduate Medical School. Second Edition.

No. 16. DISEASES OF THE SKIN. By JAY F. SCHAMBERG, M.D., Instructor t Philadelphia Polyclinic. 99 Illustrations.

Price, each, strongly bound in cloth, .80. Interleaved for taking Notes, $1.25.

PUBLISHED ANNUALLY FOR 48 YEARS.

THE PHYSICIAN'S VISITING LIST.

(LINDSAY & BLAKISTON'S.)

Issued in November of each Year.

In order to improve and simplify this Visiting List we have done away with the two styles hitherto known as the "25 and 50 Patients plain." We have allowed more space for writing the names, and added to the special memoranda page a column for the "Amount" of the weekly visits and a column for the "Ledger Page." To do this without increasing the bulk or the price, we have condensed the reading matter in the front of the book and rearranged and simplified the memoranda pages, etc., at the back.

The Lists for 75 Patients and 100 Patients will also have special memoranda page as above, and hereafter will come in two volumes only, dated January to June, and July to December. While this makes a book better suited to the pocket, the chief advantage is that it does away with the risk of losing the accounts of a whole year should the book be mislaid.

The changes and improvements made in 1896 met with such general favor that the sale increased more than ten per cent. over the previous year.

CONTENTS.

PRELIMINARY MATTER.—Calendar, 1899–1900—Table of Signs, to be used in keeping records—The Metric or French Decimal System of Weights and Measures—Table for Converting Apothecaries' Weights and Measures into Grams—Dose Table, giving the doses of official and unofficial drugs in both the English and Metric Systems—Asphyxia and Apnea—Complete Table for Calculating the Period of Utero-Gestation—Comparison of Thermometers.

VISITING LIST.—Ruled and dated pages for 25, 50, 75, and 100 patients per day or week, with blank page opposite each on which is an amount column, column for ledger page, and space for special memoranda.

SPECIAL RECORDS for Obstetric Engagements, Deaths, Births, etc., with special pages for Addresses of Patients, Nurses, etc., Accounts Due, Cash Account, and General Memoranda.

SIZES AND PRICES.

REGULAR EDITION, as Described Above.

BOUND IN STRONG LEATHER COVERS, WITH POCKET AND PENCIL.

For 25	Patients weekly, with Special Memoranda Page,						$1 00
50	"	"	"	"	"		1 25
50	"	"	"	"	"	2 vols. { January to June / July to December }	2 00
75	"	"	"	"	"	2 vols. { January to June / July to December }	2 00
100	"	"	"	"	"	2 vols. { January to June / July to December }	2 25

PERPETUAL EDITION, without Dates.

No. 1. Containing space for over 1300 names, with blank page opposite each Visiting List page. Bound in Red Leather cover, with Pocket and Pencil, ... $1 25

No. 2. Same as No. 1. Containing space for 2600 names, with blank page opposite, ... 1 50

MONTHLY EDITION, without Dates.

No. 1. Bound, Seal leather, without Flap or Pencil, gilt edges, ... 75

No. 2. Bound, Seal leather, with Tucks, Pencil, etc., gilt edges, ... 1 00

☞ All these prices are net. No discount can be allowed retail purchasers.

Circular and sample pages upon application.

MORRIS'
Text-Book of Anatomy

SECOND EDITION

Thoroughly Revised and Greatly Improved

790 Illustrations, of which many are in Colors

Royal Octavo. Cloth, $6.00; Sheep, $7.00; Half Russia, $8.00

Two Reviews Recently Published by Two Leading Medical Journals

From

The Medical Record, New York.

"The reproach that the English language can boast of no treatise on anatomy deserving to be ranked with the masterly works of Henle, Luschka, Hyrtl, and others, is fast losing its force. During the past few years several works of great merit have appeared, and among these Morris's "Anatomy" seems destined to take the first place in disputing the palm in anatomical fields with the German classics. The nomenclature, arrangement, and entire general character resemble strongly those of the above-mentioned handbooks, while in the beauty and profuseness of its illustrations it surpasses them. This edition offers but few changes; a chapter on the skin has been added, and a useful list of vestigial and abnormal structures has been compiled. Sections especially worthy of praise are those on surgical and topographical anatomy, and the chapter on the nervous system is presented with great clearness and fullness. The ever-growing popularity of the book with teachers and students is an index of its value, and it may safely be recommended to all interested."

From

The Philadelphia Medical Journal.

"Of all the text-books of moderate size on human anatomy in the English language, Morris is undoubtedly the most up-to-date and accurate. The changes from the first edition are not marked; perhaps the most noticeable feature is that there are twenty less cuts than in the first edition. Those which have been omitted, however, will not be greatly missed. The saving of space by the omission of a discussion of histology is a decided advantage, giving room for much matter of importance in these days when every student is obliged to own a special treatise on histology. To enumerate the numerous differences which are noticeable in the descriptions given by this book from those in many of the older anatomies would require too much space. The changes, however, almost without exception, tend toward an improved nomenclature and greater accuracy. This is particularly noticeable in the parts devoted to descriptions of the abdominal viscera and the joints. . . . For the student, the surgeon, or for the general practitioner who desires to review his anatomy, Morris is decidedly the book to buy."

***** The illustrations in number, correctness, and excellence of execution are equaled by no similar treatise, about $1000 having been expended on new and improved blocks for this edition alone. Handsome circular free.**

Digitized by Google

Digitized by Illinois College of Optometry

LIBRARY
of the
NORTHERN ILLINOIS
COLLEGE OF OPTOMETRY

Digitized by Illinois College of Optometry

107064

RE46
.F44
1896

2092

Digitized by Illinois College of Optometry

Digitized by Illinois College of Optometry